

# Comparative Effectiveness of the Homeopathic Preparation *Traumeel S* in Third Molar Extraction Surgery: A Preliminary Triple-Blind Clinical Trial

Glaciele Maria de Souza<sup>1</sup> Ighor Andrade Fernandes<sup>1</sup> Marcos Luciano Pimenta Pinheiro<sup>2</sup>  
Saulo Gabriel Moreira Falci<sup>3</sup> 

<sup>1</sup> Department of Dentistry, Federal University of Vales Jequitinhonha and Mucuri, Diamantina, Minas Gerais, Brazil

<sup>2</sup> Division of Pharmacology, Department of Dentistry, Federal University of Vales Jequitinhonha and Mucuri, Diamantina, Minas Gerais, Brazil

<sup>3</sup> Division of Oral and Maxillofacial Surgery, Department of Dentistry, Federal University of Vales Jequitinhonha and Mucuri, Diamantina, Minas Gerais, Brazil

Address for correspondence Saulo Gabriel Moreira Falci, DDS, MSc, PhD, Department of Dentistry, Federal University of Vales Jequitinhonha and Mucuri, 187 Street Rua da Glória, Centro, Diamantina City, Minas Gerais State 39100-000, Brazil (e-mail: saulofalci@hotmail.com).

Homeopathy 2021;110:229–235.

## Abstract

**Background and Aim** This preliminary study aimed to evaluate whether a homeopathic preparation (*Traumeel S*) might be a good option to control post-operative outcomes (pain, edema and trismus) associated with surgical removal of mandibular third molar teeth. The null hypothesis was that *Traumeel S* is not different from dexamethasone (gold standard) in controlling these post-operative inflammatory complications.

**Methods** A randomized, “split-mouth”, triple-blind clinical trial was conducted. Seventeen healthy patients with a mean age of 20.94 ( $\pm 5.83$ ) years had their lower asymptomatic bilateral third molars removed. Patients were randomized to receive *Traumeel S* or dexamethasone pre-operatively by injection into the masseter muscle; each patient acted as his/her own control. At 24, 48, 72 hours and 7 days after the surgery, the pain was evaluated according to a visual analog scale, edema through linear measurements of the face, and trismus through the maximum buccal opening. Wilcoxon statistics or paired *t*-test were used, and a significance level of 95% was adopted.

**Results** For pain, the results for *Traumeel S* were not different ( $p > 0.05$ ) from those of dexamethasone after 24 hours, 72 hours, and 7 days. For edema, the results for *Traumeel S* were not different ( $p > 0.05$ ) from those of dexamethasone at all post-operative evaluations. For mouth opening, the results for *Traumeel S* were not different ( $p > 0.05$ ) from those of dexamethasone at 72 hours and 7 days after third molar extraction.

**Conclusion** With the exception of some early post-operative findings, the null hypothesis is not rejected. *Traumeel S* might be a good alternative approach to dexamethasone for controlling pain, edema and trismus after third molar removal.

## Keywords

- ▶ *Arnica montana*
- ▶ dexamethasone
- ▶ homeopathy
- ▶ oral surgery
- ▶ third molar
- ▶ *Traumeel S*

received

September 16, 2020

accepted after revision

December 23, 2020

published online

March 25, 2021

© 2021. The Faculty of Homeopathy.

All rights reserved.

Georg Thieme Verlag KG,

Rüdigerstraße 14,

70469 Stuttgart, Germany

DOI <https://doi.org/>

10.1055/s-0041-1725038.

ISSN 1475-4916.

## Introduction

The surgical extraction of third molar (“wisdom”) teeth is a procedure commonly performed in oral surgery.<sup>1</sup> Depending on the surgical approach, excessive tissue trauma may occur, leading to non-infectious complications, such as pain, edema, and trismus.<sup>2,3</sup> The loose and vascularized connective tissue in the surgical area causes the release of exudates and mediators that induce cell migration to the traumatized area.<sup>4</sup> In this sense, the removal of third molars leads to an inflammatory process that, when exacerbated, causes pain, anxiety and phobia in patients.<sup>5</sup> To minimize this discomfort, drug protocols have been used to modulate the inflammatory process.<sup>6</sup>

The use of corticosteroids to control clinical signs of exaggerated inflammation in third molar surgery has been studied since 1950.<sup>7</sup> Corticosteroids avoid or suppress the immunologic and inflammatory process by blocking the release of acute inflammation mediators.<sup>8</sup> Dexamethasone is a powerful corticosteroid and is considered a gold standard in the control of post-operative parameters in third molar extractions.<sup>9–11</sup> Studies have shown that pre-operative corticosteroid administration is effective when compared with placebo in reducing edema and trismus after third molar removal.<sup>9–11</sup>

People are increasingly looking for alternative treatments to complement or substitute orthodox drugs. Homeopathic medicine, for example, seeks to cure an individual's morbidities through the active principles of plants, minerals, or animal products.<sup>12,13</sup> Thus, it is important to investigate homeopathic medicines to control pain, edema and trismus after third molar surgery. *Traumeel S* is a homeopathic preparation produced by Biologische Heilmittel Heel GmbH, Baden-Baden, Germany, and is composed of 12 botanical substances and two minerals<sup>14,15</sup>: *Arnica montana*, *Calendula officinalis*, *Hamamelis virginiana*, *Achillea millefolium*, *Atropa belladonna*, *Aconitum napellus*, *Chamomilla recutita*, *Symphytum officinale*, *Bellis perennis*, *Echinacea angustifolia*, *Echinacea purpurea*, *Hypericum perforatum*, *Mercurius solubilis*, and *Hepar sulphuris*.<sup>14</sup> This formulation has anti-inflammatory, anti-edematous, and anti-exudative properties. The efficacy of this drug has been demonstrated in several conditions such as rotator cuff syndrome, acute ankle twisting, mucositis, and strenuous physical exercise.<sup>15–18</sup> *Traumeel S* can be found in many pharmaceutical forms (ointment, drop solution, sublingual or injectable) and is indicated to alleviate mild to moderate pain associated with inflammatory processes, such as those caused by exodontia, through a polymodal action.<sup>14</sup>

The aim of this comparative effectiveness study was to evaluate whether the homeopathic preparation *Traumeel S* is a good alternative to control post-operative pain, edema and trismus after third molar tooth removal. The null hypothesis was that *Traumeel S* is not different from dexamethasone (gold standard) in controlling these post-operative complications.

## Materials and Methods

### Study Design

A preliminary randomized, “split-mouth”, triple-blind clinical trial was conducted in accordance with the recommen-

dations of CONSORT (Consolidated Standards of Reporting Trials).<sup>19</sup> The study was registered in the Clinical Trials website through the domain <<https://www.clinicaltrials.gov>>, number NCT03567369, and it was ethically conducted according to the Helsinki Declaration. The protocol (2.341.947) was approved by the Research Ethics Committee of the Federal University of Vales do Jequitinhonha e Mucuri (UFVJM), where this study was performed. All participants signed an informed consent agreement.

### Sample and Eligibility Criteria

We included 17 patients, older than 18 years and without compromised general health, with an indication for removal of asymptomatic bilateral mandibular third molar teeth, defined as impacted according to clinical and panoramic radiographic examination. We excluded from participation those who had a history of hypersensitivity to any of the drugs used in this study and/or who had used anti-inflammatory drugs within 15 days prior to surgery, those who were pregnant or lactating, had a history of pericoronitis, or withdrew their informed consent.

### Randomization and Blinding

The patients underwent two operations (right third molar removal or left third molar removal) at different times. Due to the washout period, the second surgery was performed only 15 days after the first one. One hour before the first surgery, randomization was performed. Initially, the side (right or left) that would be operated on first was drawn from an envelope (see below), and then the therapeutic protocol was drawn to determine which drug (*Traumeel S* or dexamethasone) would be administered before the first surgery. The second surgery was thus performed on the contralateral side and followed a drug protocol different from that of the first surgery. The randomization was done by author IAF by randomly drawing two opaque envelopes, each of which contained a piece of paper that indicated either the side of surgery or the encoded therapeutic protocol (protocol 1 or 2).

To conceal randomization and to ensure that the other researchers and the patient were blinded, the drug was administered by author IAF in a reserved room, in the absence of the researchers responsible for the surgery. Protocols were only decoded at the end of the research, after the statistical analysis.

### Drug Therapy and Surgical Procedures

The sample was randomized into two groups according to the therapeutic protocol, which was administered through the parenteral route (injection into the masseter muscle) in the immediate pre-operative period. Protocol 1: homeopathic preparation *Traumeel S* (*Arnica montana* [D2]; *Calendula officinalis* [D2]; *Hamamelis virginiana* [D1]; *Achillea millefolium* [D3]; *Atropa belladonna* [D2]; *Aconitum napellus* [D2]; *Chamomilla recutita* [D3]; *Symphytum officinale* [D6]; *Bellis perennis* [D2]; *Echinacea angustifolia* [D2]; *Echinacea purpurea* [D2]; *Hypericum perforatum* [D2]; *Mercurius solubilis* [D6]; *Hahnemanni* [D6]; *Hepar sulphuris* [D6]), 2.2 mg/2 mL. Protocol 2: dexamethasone 8 mg/2 mL.

After anesthetizing and blocking the patient's inferior alveolar nerve, the surgeon/author SGMF left the room, and IAF administered the protocol, ensuring that the surgeon and assistant were blinded. The technique consisted of intramuscular injection of 2 mL of the described medications at three different points, as described by Messer and Keller.<sup>20</sup> The drug of protocol 1 was administered in its standard form. For protocol 2, 1 mL of the drug was diluted in 1 mL of sterile saline solution to reach a volume of 2 mL of solution, and hence a final dexamethasone concentration of 4 mg/mL, ensuring patient blindedness and injection of the same volume of medication on both sides. Both drugs are clear and colorless. All surgical procedures were performed by only one surgeon, SGMF, and followed the same protocol performed in the previous study.<sup>11</sup>

### Variables

Variables (pain, edema, and trismus) were evaluated and calibrated (the intra-class correlation coefficients were 0.88 and 0.79 for edema and trismus, respectively), by the author GMS. The evaluator was blinded to the type of drug and surgical protocol used in each patient.

The variables edema and trismus were evaluated pre-operatively (baseline) to provide normal facial measurements. Edema was measured through linear facial measurements, and trismus through the maximum mouth opening (in mm). These measurements were performed following a procedure published previously by our research group.<sup>11</sup>

Patients were evaluated post-operatively at 24, 48, and 72 hours and 7 days for the variables pain, edema, and trismus. Post-operative pain was evaluated in all follow-ups through a visual analog scale (VAS) presented in a pre-defined evaluation form. The patients were instructed to draw a vertical line at the point between 0 and 10 that defined their degree of pain sensitivity. The distance from the left end of the line to the selected point was then measured in millimeters with a ruler. The resulting value was the level of a patient's pain at each time. The total number of analgesic tablets (paracetamol 500 mg) consumed by patients after 7 days of follow-up, and any extra medications, were recorded. The baseline values of facial measures and the maximum buccal opening were compared with the post-operative measurements to establish edema and trismus. The post-operative measurement methods were performed according to previous studies.<sup>11,21</sup> All collected values were recorded in a pre-established form.

### Statistical Analysis

Statistical analysis was performed using the Statistical Package for Social Science (SPSS), version 22.0. The Shapiro–Wilk Normality test was used to verify data distribution. To evaluate the inter-group difference, the Wilcoxon test for paired samples was used when data distribution was not Normal, and the paired *t*-test was used for data with a Normal distribution. The statistics for paired samples were used because the study design of this “split-mouth” randomized clinical trial considered each patient as his/her own control. It means that both drugs were used in the same patient, one on the right side and

the other on the left side, as determined in randomization. In case of loss to follow-up in the groups, a per-protocol analysis was performed. For statistical result interpretation, a significance level of 5% was adopted.

### Results

The present clinical trial was conducted between October 2017 and June 2018. The flow diagram in ►Fig. 1 shows the recruitment and selection of participants. Seventeen patients were included: 5 (29.4%) males and 12 (70.6%) females, with a mean age of  $20.94 \pm \text{SD } 5.83$  years. Between the two groups, there was no significant difference in the mean duration time of operations or the mean analgesic consumption (►Table 1). Details of the surgical procedures are presented in ►Table 2. A similar range of surgical procedures took place for both groups.

Among the randomized patients, two of them—one in the *Traumeel S* group and one in the dexamethasone group—used the anti-inflammatory drug nimesulide of their own initiative. Another patient in the *Traumeel S* group took ibuprofen by medical prescription for a throat infection after the sixth day of surgery, but he reported no pain at the surgery site at the time. One of the patients treated with dexamethasone had to undergo treatment for esophagitis between the two scheduled surgical procedures, with continuous use of a proton-pump inhibitor medication; without the necessary washout period she could therefore not undergo the surgical removal of the contralateral third molar. Another patient had an anxiety crisis 1 day after the surgical treatment in which dexamethasone was used; this patient was treated at a hospital, where 5 mg of intravenous diazepam was administered, but she was discharged immediately. The patient returned for the other removal procedure and did not report the use of other medications after that.

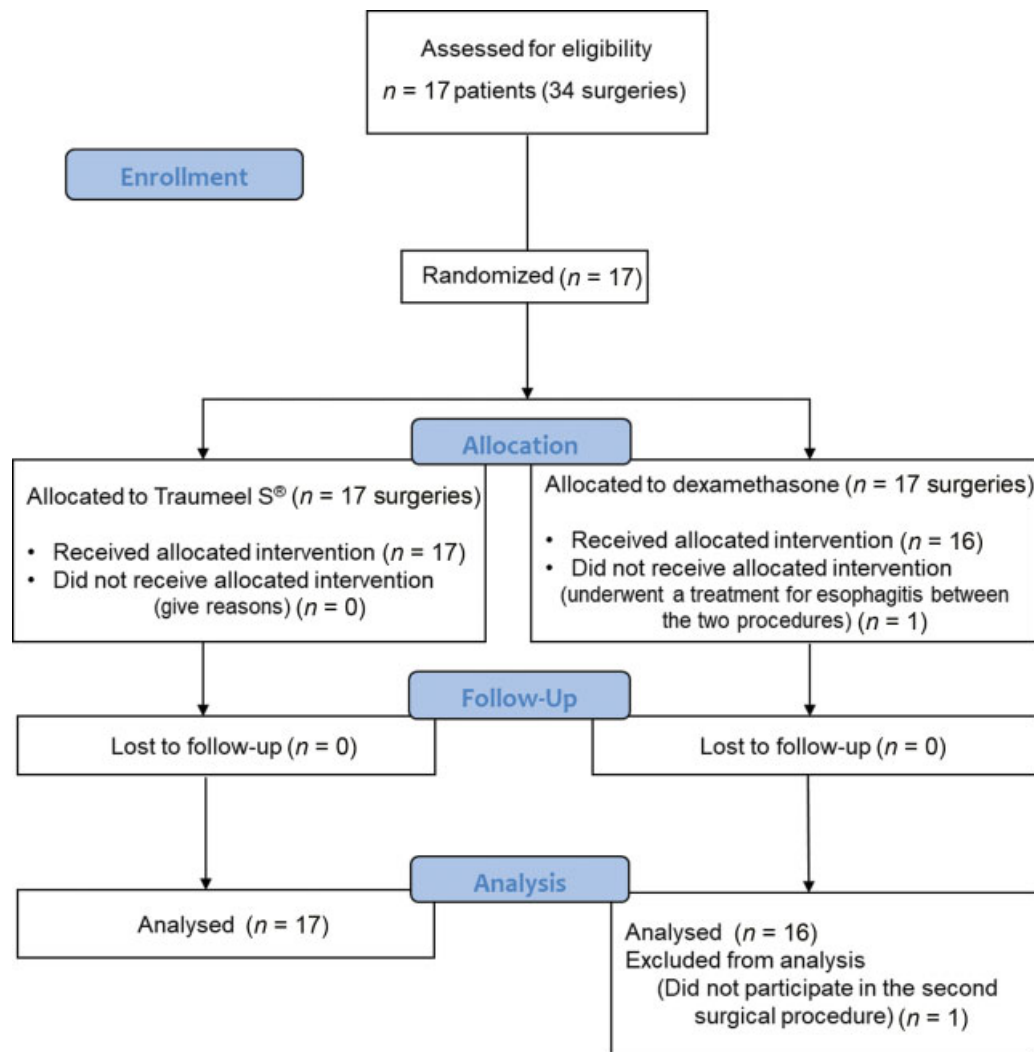
Regarding pain, the results for *Traumeel S* were not different from those of dexamethasone after 24 hours, 72 hours, and 7 days. After 48 hours of the procedure, *Traumeel S* was associated with significantly more pain than dexamethasone (►Table 1).

When the reduction in buccal opening was evaluated, the results for *Traumeel S* were not different from those of dexamethasone after 72 hours and 7 days of post-operative third molar extraction. When the patients were evaluated after 24 and 48 hours, *Traumeel S* was comparatively less effective than dexamethasone (►Table 1).

Regarding edema, the results for *Traumeel S* were not different from those of dexamethasone at all post-operative evaluations (►Table 1).

### Discussion

In this study, the pre-operative intramuscular administration of the homeopathic preparation *Traumeel S* was compared with pre-operative dexamethasone to control the inflammatory parameters after third molar extraction. The mechanisms of action of these two drugs are different. Thus, it was necessary to standardize all the procedures so



**Fig. 1** CONSORT flowchart. CONSORT, Consolidated Standards of Reporting Trials.

that differences found in the post-operative period could only be attributed to differing efficacies of the two drugs. The absence of a significant difference in surgery duration or average analgesic consumption between the groups showed that these two variables were not affected differently by each drug.

We compared the effect of the two drugs through the analysis of post-operative pain, edema and trismus at different chronological periods. We evaluated pain through VAS, which is a commonly used method in clinical studies.<sup>9,22-24</sup> This study concluded that there was no statistically significant difference in pain control between the protocols in the 24-hour, 72-hour, and 7-day follow-up periods. For the 48-hour evaluation, however, patients treated with dexamethasone presented lower average pain when compared with *Traumeel S*. These results resemble a study that compared the use of dexamethasone with the use of a placebo during third molar surgery.<sup>9</sup> An explanation for this result is that the half-life of dexamethasone may be longer than that of *Traumeel S*. In addition, pain after 72 hours and 7 days can be attributed to the patient's normal post-operative recovery. This statement is supported by a study that evaluated pain at 7 and

15 days after lower third molar surgery and did not find differences between the dexamethasone group and the no-medication group.<sup>22</sup> By contrast, in another study, patients who used intramuscular dexamethasone had a reduction in the mean pain after third molar removal only at 7 days, when compared with the control group in which no corticosteroid was used.<sup>25</sup> However, the result of this study<sup>25</sup> can be attributed to performance bias, because one of the operated sides did not receive corticosteroid, and blinding was not possible; therefore, patients may have modulated their response when filling in the pain scale, believing that the side receiving medication would have less pain.

A pilot clinical study showed the efficacy of injectable and/or orally administered *Traumeel S* in reducing pain in the elective surgery of hallux valgus over a period of 13 post-operative days.<sup>23</sup> Another clinical trial compared the pain level of patients undergoing dental implant installation surgery, using *Traumeel S* or ketoprofen in the pre- and post-operative periods.<sup>24</sup> The results of that study indicated that both drugs promoted similar pain control in the post-operative period of 24, 48, 72 and 96 hours.<sup>24</sup> Similar data were found in the study by Zurita and Vallejo-Rosero, in

**Table 1** Comparison of studied variables between the protocols (*Traumeel S* and Dexamethasone) during different postoperative evaluations

Variable	Traumeel (2.2 mg) Mean $\pm$ SD or Median (inter-quartile range)	Dexamethasone (8 mg) Mean $\pm$ SD or Median (inter-quartile range)	p-Value
Swelling (mm) <sup>a</sup>			
24 hours	38.47 $\pm$ 1.92	38.05 $\pm$ 1.87	0.30
48 hours	38.36 $\pm$ 1.83	38.10 $\pm$ 1.74	0.46
72 hours	38.52 $\pm$ 1.66	37.95 $\pm$ 1.72	0.06
7 days	38.56 $\pm$ 1.54	38.13 $\pm$ 1.74	0.14
Reduction in mouth opening (mm) <sup>b</sup>			
24 hours	21.52 (11.20–26.75)	13.09 (5.00–22.31)	0.03*
48 hours	16.17 (8.42–24.88)	9.64 (4.17–16.16)	0.008*
72 hours	16.10 (7.69–21.27)	10.04 (4.49–16.52)	0.30
7 days	6.68 (1.22–21.29)	5.29 (0.44–5.29)	0.14
Pain score <sup>b</sup>			
24 hours	4.84 (2.68–7.57)	1.73 (0.25–5.20)	0.06
48 hours	3.36 (1.20–5.99)	1.15 (0.10–2.23)	0.002*
72 hours	1.15 (0.20–5.04)	0.52 (0.00–2.07)	0.08
7 days	0.10 (0.00–0.87)	0.17 (0.00–1.31)	0.42
Duration of surgery (minutes) <sup>a</sup>	14.48 $\pm$ 7.33	16.56 $\pm$ 5.49	0.19
Analgesic consumption, rescue drugs (n) <sup>a</sup>	9.44 $\pm$ 5.73	6.88 $\pm$ 5.41	0.15

Abbreviation: SD, standard deviation.

<sup>a</sup>t-test.

<sup>b</sup>Wilcoxon test.

\* $p < 0.05$ .

which there was no statistically significant difference in pain after third molar extraction between patients who received either the homeopathic preparation (*Traumeel S*) or ibuprofen.<sup>26</sup> The results of these studies reveal that the pre-emptive action of *Traumeel S* for pain control resembles that of a conventional non-steroidal anti-inflammatory drug and, if re-applied at 24 and 48 hours after the surgical treatment, it may have satisfactory results for pain.

The consumption of rescue analgesics was also recorded to better differentiate the analgesic action of the tested drugs. The mean analgesic consumption in the *Traumeel S* group was non-significantly greater than in the dexamethasone group. Despite randomization, most patients were drawn to receive dexamethasone at the second surgery. In

**Table 2** Comparison of surgical procedures between the protocols (*Traumeel S* and Dexamethasone)

Details of the surgical procedures	Traumeel (2.2 mg)	Dexamethasone (8 mg)
Without osteotomy and odontosection	2	1
Only osteotomy	8	4
With osteotomy and odontosection	7	11

this way, we inferred that the mean analgesic consumption for the second surgery might have been lower if patients had not used this medication to avoid the same pain experience of the first surgery.

Another important caveat to be discussed is the use of non-prescribed medication by our patients. In the results of this study, this practice seemed to be consistent, since two patients from different treatment groups used another anti-inflammatory drug to treat post-operative complications. In addition, the reason for two other patients taking additional medication was not connected with complications of the surgical procedure.

No statistically significant difference was found between the groups for the control of edema at any of the post-operative time points. The results corroborate those presented in a study comparing post-operative edema between patients who received *Traumeel S* and ibuprofen in third molar extraction.<sup>26</sup> The action of *Traumeel S* in edema is attributed to the anti-exudative properties of *Mercurius solubilis* which, together with the other components of *Traumeel S*, would increase the vascular tone and decrease the vascular permeability and local hemostasis.<sup>14</sup> Other studies compared the effect of intramuscular dexamethasone with a control group (non-use of corticosteroid or placebo) in similar clinical procedures. Patients who received

dexamethasone presented less post-operative edema in the follow-up periods.<sup>9,10,25</sup> Thus, the presented results allow us to conclude that *Traumeel S* was as good as dexamethasone in preventing edema after third molar surgery. However, this conclusion must be interpreted with caution because, while the evaluation method was properly calibrated, edema is a three-dimensional quantity but it was evaluated with two-dimensional tools.<sup>6,11</sup>

Regarding trismus, at 24 and 48 hours of follow-up, dexamethasone was more effective in preventing the reduction in mouth opening when compared with *Traumeel S*. The results for the 72 hours and 7 days of follow-up were not significantly different between the two treatments. An overall positive conclusion about the comparative effectiveness of *Traumeel S* in the control of trismus from 72 hours of third molar surgery is feasible because intramuscular dexamethasone was better than placebo<sup>9</sup> or the non-use of drug<sup>25</sup> in patients undergoing third molar extractions when trismus was evaluated in the same kind of research. By contrast, in other research, *Traumeel S* showed a lower efficacy in controlling trismus after third molar extractions when compared with ibuprofen.<sup>26</sup> The explanation for this result is uncertain, since trismus is directly correlated to pain and edema, and the results of these variables were different in this study.

Homeopathic medicines are considered a good alternative because they have low cost and are well tolerated due to their low toxicity and low related adverse effects.<sup>27,28</sup> In our study, no adverse effects due to either of the drugs were reported.

A recent study related to oral surgery aimed to evaluate the advantages of the anti-inflammatory and analgesic properties of *Traumeel S* in periodontal surgery. That study concluded that *Traumeel S* was better than ibuprofen in controlling pain after periodontal flap surgery, with minimal or no side effects.<sup>29</sup> However, studies using *Traumeel S* in third molar extractions are scarce, and those few studies differ in their research methods. Comparative studies between *Traumeel S* and dexamethasone, or another corticosteroid, in third molar surgery have not been identified in the literature, which makes it difficult to compare results directly.

Another limitation of our study is the subjectivity of pain assessment by patients and the possibility for empirical measures they might adopt to ameliorate post-operative discomfort. Patients were instructed on such measures; however, the researchers cannot control patients' actions. New well-designed, and larger, clinical trials are suggested to better elucidate the results indicated in the present study.

## Conclusion

With the exception of results for some early post-operative assessments, we are unable to reject our null hypothesis that *Traumeel S* is not different from dexamethasone (gold standard) in the control of pain, edema and trismus after lower third molar extraction. Based on these preliminary findings, we conclude that *Traumeel S* might be a good alternative approach to dexamethasone for controlling post-operative inflammatory complications after third molar removal.

## Highlights

- The potential of the homeopathic preparation *Traumeel S* as anti-inflammatory in lower third molar surgery was tested in a preliminary triple-blind clinical trial.
- The effects of *Traumeel S* were not significantly different from those of dexamethasone for pain after 24 hours, 72 hours, and 7 days; for mouth opening after 72 hours and 7 days; and for edema at all post-operative evaluations.
- *Traumeel S* might be a good alternative to dexamethasone as an anti-inflammatory medication following lower third molar extraction.

## Funding

None.

## Conflicts of Interest

None declared.

## Acknowledgements

The authors would like to thank Guilherme Silva Salgado, the owner of Drogaria Arraia LTDA, for the subsidy in the acquisition of the drugs. This study was partly financed by the Coordination for the Improvement of Higher Education Personnel (CAPES), Brazil, Finance Code 001.

## References

- 1 Zupelari-Gonçalves P, Weckwerth GM, Calvo AM, et al. Efficacy of oral diclofenac with or without codeine for pain control after invasive bilateral third molar extractions. *Int J Oral Maxillofac Surg* 2017;46:621–627
- 2 Vicente A, Loffi AOB, Nesi H. Uso de corticosteroide no pré-operatório em cirurgia de terceiros molares. *Rev Bras Odontol* 2013;70:22–27
- 3 Martin MV, Kanatas AN, Hardy P. Antibiotic prophylaxis and third molar surgery. *Br Dent J* 2005;198:327–330
- 4 Laureano Filho JR, Maurette PE, Allais M, Cotinho M, Fernandes C. Clinical comparative study of the effectiveness of two dosages of Dexamethasone to control postoperative swelling, trismus and pain after the surgical extraction of mandibular impacted third molars. *Med Oral Patol Oral Cir Bucal* 2008;13:E129–E132
- 5 Braga AFA, D'Ottaviano LH, Braga FSS, et al. Extraction of retained third molar teeth under local anesthesia. Evaluation of anxiety, pain, hemodynamic and respiratory alterations. *Rev Fac Odontol Univ Nec (Cordoba)* 2010;51:9–14
- 6 Lima CAA, Favarini VT, Torres AM, da Silva RA, Sato FRL. Oral dexamethasone decreases postoperative pain, swelling, and trismus more than diclofenac following third molar removal: a randomized controlled clinical trial. *Oral Maxillofac Surg* 2017; 21:321–326
- 7 Montgomery MT, Hogg JP, Roberts DL, Redding SW. The use of glucocorticosteroids to lessen the inflammatory sequelae following third molar surgery. *J Oral Maxillofac Surg* 1990;48:179–187
- 8 Chappi D M, Suresh KV, Patil MR, et al. Comparison of clinical efficacy of methylprednisolone and serratiopeptidase for reduction of postoperative sequelae after lower third molar surgery. *J Clin Exp Dent* 2015;7:e197–e202
- 9 Al-Dajani M. Can preoperative intramuscular single-dose dexamethasone improve patient-centered outcomes following third molar surgery? *J Oral Maxillofac Surg* 2017;75:1616–1626
- 10 Dereci O, Tüzüner-Öncül AM, Kocer G, Yuce E, Askar M, Ozturk A. Efficacy of immediate postoperative intramasseptic

- dexamethasone injection on postoperative swelling after mandibular impacted third molar surgery: a preliminary split-mouth study. *J Pak Med Assoc* 2016;66:320–323
- 11 Alcântara CEP, Falci SGM, Oliveira-Ferreira F, Santos CR, Pinheiro ML. Pre-emptive effect of dexamethasone and methylprednisolone on pain, swelling, and trismus after third molar surgery: a split-mouth randomized triple-blind clinical trial. *Int J Oral Maxillofac Surg* 2014;43:93–98
  - 12 Sanadhya YK, Sanadhya S, Sharma N, et al. Homeopathy a compliment to dentistry—a review. *IJOCR* 2013;1:31–38
  - 13 Ho D, Jagdeo J, Waldorf HA. Is there a role for *Arnica* and *Bromelain* in prevention of post-procedure ecchymosis or edema? A systematic review of the literature. *Dermatol Surg* 2016;42:445–463
  - 14 Scientific Bio-Logics—Heel. *Traumeel®*. Accessed December 14, 2020 at: <http://www.healingedge.net/pdf/traumeel.pdf>
  - 15 Vanden Bossche L, Vanderstraeten G. A multi-center, double-blind, randomized, placebo-controlled trial protocol to assess *Traumeel* injection vs dexamethasone injection in rotator cuff syndrome: the *TRAumeel* in *ROTator* cuff syndrome (*TRARO*) study protocol. *BMC Musculoskelet Disord* 2015;16:8
  - 16 González de Vega C, Speed C, Wolfarth B, González J. *Traumeel* vs. diclofenac for reducing pain and improving ankle mobility after acute ankle sprain: a multicentre, randomised, blinded, controlled and non-inferiority trial. *Int J Clin Pract* 2013; 67:979–989
  - 17 Sencer SF, Zhou T, Freedman LS, et al. *Traumeel S* in preventing and treating mucositis in young patients undergoing SCT: a report of the Children's Oncology Group. *Bone Marrow Transplant* 2012; 47:1409–1414
  - 18 Muders K, Pilat C, Deuster V, et al. Effects of *Traumeel* (Tr14) on recovery and inflammatory immune response after repeated bouts of exercise: a double-blind RCT. *Eur J Appl Physiol* 2017; 117:591–605
  - 19 Moher D, Hopewell S, Schulz KF, et al. CONSORT 2010 explanation and elaboration: updated guidelines for reporting parallel group randomised trials. *BMJ* 2010;340:c869
  - 20 Messer EJ, Keller JJ. The use of intraoral dexamethasone after extraction of mandibular third molars. *Oral Surg Oral Med Oral Pathol* 1975;40:594–598
  - 21 Antunes AA, Avelar RL, Martins Neto EC, Frota R, Dias E. Effect of two routes of administration of dexamethasone on pain, edema, and trismus in impacted lower third molar surgery. *Oral Maxillofac Surg* 2011;15:217–223
  - 22 Rocha-Neto AM, Nogueira EFC, Borba PM, Laureano-Filho JR, Vasconcelos BC. Application of dexamethasone in the masseter muscle during the surgical removal of lower third molars. *J Craniofac Surg* 2017;28:e43–e47
  - 23 Singer SR, Amit-Kohn M, Weiss S, et al. Efficacy of a homeopathic preparation in control of post-operative pain—a pilot clinical trial. *Acute Pain* 2007;9:7–12
  - 24 Finsterbusch RM, Urrutia AMR. Comparación del control del dolor postoperatorio en la cirugía de implantes entre ketoprofeno y *traumeel s* [Online dissertation]. Chile: Universidad Nacional Andres Bello; 2013
  - 25 Nandini GD. Eventuality of dexamethasone injected intra-masseterically on post operative sequel following the surgical extraction of impacted mandibular third molars: a prospective study. *J Maxillofac Oral Surg* 2016;15:456–460
  - 26 Zurita P, Vallejo-rosero KA. Valoración del medicamento homeopático, como terapia post extracción del tercer molar inferior incluido. *Dom. Cien.* 2017;3:147–167
  - 27 Niño SLP, Díaz ACM, Mosquera MCS. Medicamentos Homeopáticos Útiles en el Tratamiento de Afecciones Presentes en el Sistema Estomatognático. Revisión de la Literatura. *Acta Odontol.* 2011;1:39–52
  - 28 Sales KCC, Sánchez EZ, Iglesias RA, et al. Effectiveness of homeopathy in the treatment of traumatic tooth extractions. *Revista Electrónica Dr. Zoilo E. Marinello Vidaurreta.* 2014;39:1–6
  - 29 Das R, Deshmukh J, Asif K, Sindhura H, Devarathanamma MV, Jyothi L. Comparative evaluation of analgesic and anti-inflammatory efficacy of ibuprofen and *traumeel* after periodontal flap surgery: a randomized triple-blind clinical trial. *J Indian Soc Periodontol* 2019;23:549–553