



Appendiceal Neuroendocrine Tumours – Experience of One Service

Tumores neuroendócrinos do apêndice – Experiência de um serviço

Vítor Devezas^{1,2} Laura Elisabete Barbosa^{1,2}

¹Department of Surgery, Centro Hospitalar Universitário de São João (CHUSJ), Porto, Portugal

²Department of Surgery, Faculdade de Medicina da Universidade do Porto (FMUP), Porto, Portugal

Address for correspondence Vítor Devezas, MD, Departamento de Cirurgia, Faculdade de Medicina da Universidade do Porto, Alameda Prof. Hernâni Monteiro, 4200-319, Porto, Portugal (e-mail: vitor.devezas7@gmail.com).

J Coloproctol 2021;41(2):152–155.

Abstract

Tumours of the appendix are rare and tend to be diagnosed incidentally, in cases of acute appendicitis. For some authors, appendiceal neuroendocrine tumours (ANETs) are the most frequent neoplasm of the appendix, observed in 0.3% to 0.9% of cases acute appendicitis. The present is a unicentric retrospective study conducted between January 2005 and March 2017. Out of a total of 3,007 surgeries for appendiceal pathologies performed in the adult population at the hospital where the present study was conducted, there were 70 (2.33%) malignant cases, 20 (28.6%) of which were ANETs. The patients had a median age of 44 years (range: 18 to 85 years), and were predominantly women (there were 1.9 times more women than men). In 16 cases (80%), a simple appendectomy was performed (1 patient was submitted to a right hemicolectomy later). The cases of ANETs had a good prognosis in our series: 85% of the patients are either alive today or were alive after 5 years of follow-up. Despite the fact that ANETs are described as the most frequent tumor of the appendix, this was not confirmed in our series, in which they only represented 28.6% of the cases; adenocarcinoma was the most frequent tumor (65.7%) among our sample.

Keywords

- ▶ appendix
- ▶ neuroendocrine tumors
- ▶ carcinoids
- ▶ appendectomy

Resumo

Tumores do apêndice são raros, e tendem a ser diagnosticados de forma incidental, em casos de apendicite aguda. Para alguns autores, tumores neuroendócrinos do apêndice (TNEAs) são as neoplasias mais frequentes do apêndice, e são observados em 0,3 a 0,9% de todos os casos agudos de apendicite. Este é um estudo monocêntrico e retrospectivo realizado entre janeiro de 2005 e março de 2017. Entre um total de 3.007 cirurgias para patologias do apêndice realizadas na população adulta no hospital em que o estudo foi conduzido, houve 70 (2,33%) casos de malignidade, 20 (28,6%) dos quais

Palavras-chave

- ▶ apêndice
- ▶ tumores neuroendócrinos
- ▶ carcinoides
- ▶ apendicectomia

received
August 14, 2020
accepted
July 7, 2020
published online
May 24, 2021

DOI <https://doi.org/10.1055/s-0041-1724064>.
ISSN 2237-9363.

© 2021. Sociedade Brasileira de Coloproctologia. All rights reserved.

This is an open access article published by Thieme under the terms of the Creative Commons Attribution-NonDerivative-NonCommercial-License, permitting copying and reproduction so long as the original work is given appropriate credit. Contents may not be used for commercial purposes, or adapted, remixed, transformed or built upon. (<https://creativecommons.org/licenses/by-nc-nd/4.0/>)

Thieme Revinter Publicações Ltda., Rua do Matoso 170, Rio de Janeiro, RJ, CEP 20270-135, Brazil

eram TNEAs. Os pacientes tinham uma idade média de 44 anos (gama: 18–85 anos), e eram predominantemente mulheres (havia 1,9 vezes mais mulheres do que homens). Em 16 casos (80%), realizou-se uma simples apendicectomia (1 paciente foi submetido a uma hemicolectomia direita mais tarde). Os casos de TNEAs tiveram um bom prognóstico em nossa série: 85% dos pacientes estão vivos hoje, ou estavam após um seguimento de 5 anos. Apesar de os TNEAs serem descritos como os tumores mais frequentes do apêndice, isso não foi confirmado nesta série, na qual eles representaram apenas 28,6% dos casos; adenocarcinoma foi o tumor mais frequente (65,7%) em nossa amostra.

Introduction

The incidence of appendiceal tumors is rare, of ~ 1.2 cases per 100 thousand inhabitants.¹ They most often present with acute appendicitis, and are diagnosed incidentally after a histological analysis.¹

Appendiceal tumors can be epithelial or non-epithelial. The non-epithelial tumors are appendiceal neuroendocrine tumours (ANETs) and lymphomas, and the epithelial tumors can be divided into mucinous adenocarcinomas and non-mucinous adenocarcinoma, also called colonic-type adenocarcinomas.^{1,2}

For some authors,^{3,4} neuroendocrine tumours (NETs), which form in neuroendocrine cells, represent ~ 80% of the neoplasms of the appendix, which is the most frequent site of tumor formation in the gastrointestinal tract. For other authors,⁵ adenocarcinomas are the most common type of primary appendiceal cancer, comprising 60% of all cases.

Colonic-type adenocarcinomas have a slight predominance in men, and tend to occur in the seventh decade of life. They originate from adenomas, are very similar to colorectal tumors,¹ and, when symptomatic, they present as a mass that metastasizes preferentially to the lymph nodes, the liver, the lungs, and the peritoneum.⁶

Mucinous adenocarcinomas do not occur more frequently among men than among women; the mean age of the patients at presentation is 60 years, and no clear risk factors or pre-malignant lesions that could cause the tumor to develop have been identified.¹ They present as a cystic enlargement of the organ, associated with abdominal distension and the presence of mucin in the peritoneum, sometimes inside abdominal-wall hernias.^{2,7} They are found in 0.2% to 0.3% of all cases of acute appendicitis.⁸

Appendiceal lymphomas are more predominant among men and Caucasians; the mean age of presentation is 50 years (with the exception of Burkitt lymphoma, which usually presents in the third decade of life), and they represent 0.015% of all gastrointestinal lymphomas.⁹

As for ANETs, they are more predominant among women (to the order of 1.7 times),¹⁰ and the mean age at presentation is between 32 and 51 years.^{11,12} The initial symptoms are usually nonspecific, and the patients become symptomatic when the tumor occludes the lumen of the appendix.¹² They are present in 0.3% to 0.9% of cases of acute appendicitis.¹³

However, in some cases, they can present with flushing and diarrhea (carcinoid syndrome), due the systemic effects of serotonin production, and, in rare cases of advanced disease (stage IV), the liver is the most common site of metastasis.^{1,14}

The purpose of the present paper is to review the cases of ANETs in a single tertiary hospital.

Material and Methods

We reviewed the cases of ANETs treated at a single central hospital between January 2005 and March 2017, and recorded demographic, histopathological and postoperative data.

Results

In total, 8,820 surgeries for pathologies of the appendix were performed, 3,007 of which in the adult population. Malignancy was diagnosed in 70 (2.33%) cases; the sample had a median of 58 years (range: 18 to 86 years) and equal gender distribution.

Among the 70 tumors, only 20 (28.6%) were ANETs: 17 were located in the distal third of the appendix; 1, in the middle third; and 2, in the proximal third. In total, 11 patients (55%) had tumors smaller than 10mm, and in 9 cases (45%) the tumors were smaller than 20mm. The median age at the diagnosis of ANET was of 44 years (range: 18 to 85years), and the sample was composed of 1.9 more women than men (13 women and 7 men).

As for the remaining 50 cases of malignancy, there were 3 (4.3%) cases of metastasis of gastric adenocarcinomas, 1 (1.4%) case of lymphoma; and 46 (65.7%) cases of adenocarcinomas: 10 (14.3%) mucinous adenocarcinomas, 24 (34.3%) cases of low-grade mucinous tumors, and 12 (17.1%) cases of colonic-type adenocarcinomas. ► **Fig. 1** shows the annual incidence of appendiceal tumors by histological type.

The clinical presentation among the cases of ANET in our sample was acute appendicitis in 14 (70%) cases, appendix mass in 1 case (5%), and inflammatory/ischemic colic events in 5 cases (25%). Simple appendectomies were performed in 16 patients (80%) (only 1 patient aged 18 years was submitted to a right hemicolectomy later, because of the presence of lymphovascular and perineural invasion and the patient's young age); in the other 4 patients (20%), 1 total (5%) colectomy and 3 (15%) ileocelectomies/right hemicolectomies were performed.

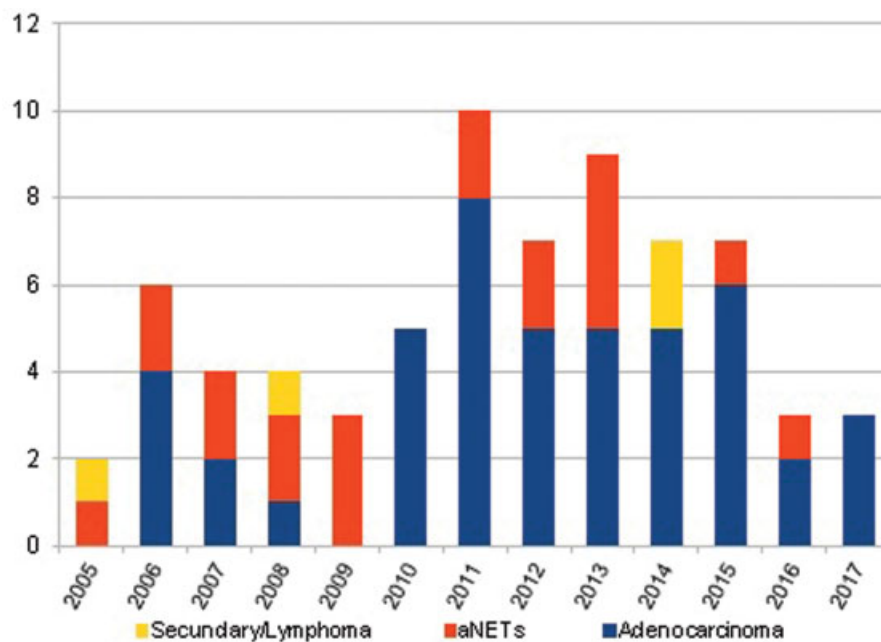


Fig. 1 Annual incidence of appendix tumors by histological type.

All patients were staged with computed tomography, and every case was discussed in a oncological group consultation. There were no recurrences to report; 2 (10%) patients died from complications of colonic ischemia (Clavien V), and in 5 cases (25%) there was wound infection or intra-abdominal abscess: 4 (20%) of those cases were treated with antibiotics (Clavien II), and 1 patient (5%) needed surgical drainage (Clavien IIIB)¹⁵ due to absence of radiological access for percutaneous drainage. In the follow-up, 1 (5%) more patient (aged 85 years) died due to comorbidities, and the remaining 17 (85%) are either alive today or were alive after 5 years of follow-up.

Discussion

Even though NETs can affect several organs, they present more frequently in the gastrointestinal tract, and the appendix is the third most common site (16.7% of the cases), after the small bowel (44.7%) and the rectum (19.6%).¹⁶

Appendiceal neuroendocrine tumors, or carcinoid tumors, originate from neuroendocrine cells, and can be divided into island-like carcinoids (which produce serotonin) or tubular carcinoids (which produce enteroglucagon and YY peptide).¹⁴ Neuroendocrine cells are present in the lamina propria and submucosa, and can be found in greater quantity at the distal appendix.¹⁷

Regarding the clinical presentation, ANETs can be observed in 50% of the cases of acute appendicitis, in cases of lumen obstruction, or if the tumors release vasoactive substances, with a carcinoid syndrome characterized by diarrhea, flushing, bronchoconstriction and right-valve disease, which occurs in less than 10% of the cases (usually associated with liver metastases).^{6,18-20} For Steffen et al.²¹ (2015), up to 15% of the patients present with a metastatic disease. In our series, 14 patients (70%) of the cases presented with acute

appendicitis, and none had carcinoid syndrome or metastatic disease.

The differential diagnosis with adenocarcinomas is performed using immunohistochemistry, with only ANETs being positive for chromogranin A and synaptophysin.²

ANETs can invade regionally and/or metastasize at a distance, and need to be staged according to two classifications: the one of the European Neuroendocrine Tumor Society (ENETS) and that of the American Joint Committee on Cancer (AJCC),²² which can help to establish the extension of the surgery, the complementary treatment, and the follow-up plan.¹⁴ In order to do so, the size, location, histopathological characteristics (like the Ki67 index), invasion of the mesoappendix, vascular/lymphatic/perineural invasion, as well as the presence of distant metastases must be evaluated.²³

ANETs are associated with synchronous and metachronous lesions in the gastrointestinal tract, so this must be investigated and monitored.²⁰

Moertel et al.²⁴ (1987), state that historically, ANETs smaller than 20 mm submitted to simple appendicectomy had a low risk of recurrence or metastasis. More aggressive interventions were indicated in cases of tumors larger than 20 mm, those extending to the mesoappendix, those located at the base of the appendix, tumors with subserous lymphatic invasion, and in cases involving younger patients. These criteria can also be applied to patients with tumors measuring 10 mm to 20 mm.²⁵

For some authors,²⁰ tumor size is the most important parameter to decide the type of surgery.

If the tumor is smaller than 10 mm, it is treated by simple appendicectomy. However, in cases of tumors measuring between 10 mm and 20 mm, other parameters must be evaluated, such as invasion of the mesoappendix, the Ki67 index, the mitotic index, the location of the tumor, lymphatic/venous permeation, and lymph-node invasions,^{4,14,20,23} to decide between simple appendicectomy or right hemicolectomy

with lymphadenectomy (with a minimum of 12 lymph nodes examined).²⁶

In tumors larger than 20 mm, right hemicolectomy with lymphadenectomy is indicated.²³ In the study by Groth et al.¹⁹ (2011), the risk of lymph-node metastasis was of 16.7%, 29.9% and 40.6%, if the tumor measured less than 10 mm, between 10 mm and 19 mm, and \geq 20 mm respectively.

Patients with metastatic disease and carcinoid syndrome can benefit from the treatment with octreotide (a somatostatin analog), which causes a decrease in symptoms in up to 88% of the cases.^{14,27} Other treatments include: the use of α interferon, hepatic artery occlusion with adjuvant chemotherapy, and embolization and/or radiofrequency ablation.^{17,20}

ANETs have a good prognosis, with a 5-year survival rate of more than 90%.^{21,28} In our series, 85% of the patients are either alive today or were alive after 5 years of follow-up.

In conclusion, despite the fact that ANETs are described as the most frequent tumors of the appendix, we could not confirm this in our series, in which they represented only 28.6% of the cases, with adenocarcinomas being the most frequent tumors (65.7%), which is in line with the study by McCusker et al.⁵ (2002).

Authors' Contributions

All authors equally contributed to this article and approved the final manuscript.

Conflict of Interests

The authors have no conflict of interests to declare.

References

- Kelly KJ. Management of appendix cancer. *Clin Colon Rectal Surg* 2015;28(04):247–255
- Shankar S, Ledakis P, El Halabi H, Gushchin V, Sardi A. Neoplasms of the appendix: current treatment guidelines. *Hematol Oncol Clin North Am* 2012;26(06):1261–1290
- Mércio AAP, Weindorfer M, Weber AL, Mano AC. Neoplasias Malignas Primárias de Apêndice Cecal. *Medicina (B Aires)* 1999; 32:193–198
- Grozinsky-Glasberg S, Alexandraki KI, Barak D, et al. Current size criteria for the management of neuroendocrine tumors of the appendix: are they valid? Clinical experience and review of the literature. *Neuroendocrinology* 2013;98(01):31–37
- McCusker ME, Coté TR, Clegg LX, Sobin LH. Primary malignant neoplasms of the appendix: a population-based study from the surveillance, epidemiology and end-results program, 1973–1998. *Cancer* 2002;94(12):3307–3312
- Leonards LM, Pahwa A, Patel MK, Petersen J, Nguyen MJ, Jude CM. Neoplasms of the appendix: pictorial review with clinical and pathologic correlation. *Radiographics* 2017;37(04): 1059–1083
- Panarelli NC, Yantiss RK. Mucinous neoplasms of the appendix and peritoneum. *Arch Pathol Lab Med* 2011;135(10):1261–1268
- Shaib WL, Assi R, Shamseddine A, et al. Appendiceal mucinous neoplasms: diagnosis and management. *Oncologist* 2017;22(09): 1107–1116
- Ayub A, Santana-Rodríguez N, Raad W, Bhora FY. Primary appendiceal lymphoma: clinical characteristics and outcomes of 116 patients. *J Surg Res* 2017;207:174–180
- Sadot E, Keidar A, Shapiro R, Wasserberg N. Laparoscopic accuracy in prediction of appendiceal pathology: oncologic and inflammatory aspects. *Am J Surg* 2013;206(05):805–809
- Pape UF, Niederle B, Costa F, et al; Vienna Consensus Conference participants. ENETS Consensus guidelines for neuroendocrine neoplasms of the appendix (excluding goblet cell carcinomas). *Neuroendocrinology* 2016;103(02):144–152
- Shaib WL, Assi R, Shamseddine A, et al. Appendiceal neuroendocrine neoplasms: diagnosis and management. *Oncologist* 2017; 22(09):1107–1116
- Murray SE, Lloyd RV, Sippel RS, Chen H, Oltmann SC. Postoperative surveillance of small appendiceal carcinoid tumors. *Am J Surg* 2014;207(03):342–345, discussion 345
- Abreu RPNS. Appendiceal neuroendocrine tumors: approach and treatment. *J Coloproctol (Rio J)* 2018;38(04):337–342
- Dindo D, Demartines N, Clavien PA. Classification of surgical complications: a new proposal with evaluation in a cohort of 6336 patients and results of a survey. *Ann Surg* 2004;240(02):205–213
- Tomioka K, Fukoe Y, Lee Y, et al. Primary neuroendocrine carcinoma of the appendix: a case report and review of the literature. *Anticancer Res* 2013;33(06):2635–2638
- Whitfield CG, Amin SN, Garner JP. Surgical management of primary appendiceal malignancy. *Colorectal Dis* 2012;14(12):1507–1511
- Charfi S, Sellami A, Affes A, Yaïch K, Mzali R, Boudawara TS. Histopathological findings in appendectomy specimens: a study of 24,697 cases. *Int J Colorectal Dis* 2014;29(08):1009–1012
- Groth SS, Virnig BA, Al-Refaie WB, Jarosek SL, Jensen EH, Tuttle TM. Appendiceal carcinoid tumors: Predictors of lymph node metastasis and the impact of right hemicolectomy on survival. *J Surg Oncol* 2011;103(01):39–45
- O'Donnell ME, Carson J, Garstin WI. Surgical treatment of malignant carcinoid tumours of the appendix. *Int J Clin Pract* 2007;61 (03):431–437
- Steffen T, Ebinger SM, Warschkow R, Lüthi C, Schmied BM, Clerici T. Long-term survival is not impaired after the complete resection of neuroendocrine tumors of the appendix. *World J Surg* 2015;39 (11):2670–2676
- Nakakura EK. Challenges staging neuroendocrine tumors of the pancreas, jejunum and ileum, and appendix. *Ann Surg Oncol* 2018;25(03):591–593
- Pape UF, Perren A, Niederle B, et al; Barcelona Consensus Conference participants. ENETS Consensus Guidelines for the management of patients with neuroendocrine neoplasms from the jejunum-ileum and the appendix including goblet cell carcinomas. *Neuroendocrinology* 2012;95(02):135–156
- Moertel CG, Weiland LH, Nagorney DM, Dockerty MB. Carcinoid tumor of the appendix: treatment and prognosis. *N Engl J Med* 1987;317(27):1699–1701
- Rothmund M, Kisker O. Surgical treatment of carcinoid tumors of the small bowel, appendix, colon and rectum. *Digestion* 1994;55 (03, Suppl 3):86–91
- Mehrvarz Sarshekeh A, Advani S, Halperin DM, et al. Regional lymph node involvement and outcomes in appendiceal neuroendocrine tumors: a SEER database analysis. *Oncotarget* 2017;8 (59):99541–99551
- Ruoff C, Hanna L, Zhi W, Shahzad G, Gotlieb V, Saif MW. Cancers of the appendix: review of the literatures. *ISRN Oncol* 2011;2011:728579
- Gaetke-Udager K, Maturen KE, Hammer SG. Beyond acute appendicitis: imaging and pathologic spectrum of appendiceal pathology. *Emerg Radiol* 2014;21(05):535–542