



Clinical Study of 107 Hospitalized Patients with Peritonsillar Abscess

Risa Wakisaka¹ Takumi Kumai^{1,2} Kan Kishibe¹ Miki Takahara¹ Akihiro Katada¹ Tatsuya Hayashi^{1,2}
Yasuaki Harabuchi¹

¹ Department of Otolaryngology—Head and Neck Surgery, Asahikawa Medical University, Hokkaido, Japan

² Department of Innovative Head and Neck Cancer Research and Treatment (IHNCRT), Asahikawa Medical University, Hokkaido, Japan

Address for correspondence Risa Wakisaka, MD, Department of Otolaryngology—Head and Neck Surgery, Asahikawa Medical University, 1-chōme-1-1 Higashi 2-jō Asahikawa, Hokkaido 078-8510, Japan (e-mail: r-wakisaka@asahikawa-med.ac.jp).

Int J Pract Otolaryngol 2021;4:e11–e16.

Abstract

We conducted a retrospective analysis of the data of 107 cases of peritonsillar abscess treated at our hospital between January 2014 and December 2018. Data on age, sex, affected site, duration of hospitalization, method of drainage, presence/absence of laryngeal edema, antibacterial drugs used, and isolated bacteria were analyzed. Of the 107 patients, 71 were males and 36 were females; the median age was 44 years (range: 18–88 years). The left side was affected in 55 patients, the right side in 50 patients, and both sides in two patients. The abscess was localized in the superior pole in 71 patients, and in the inferior pole in 36 patients. Thirty-five patients had laryngeal edema, of which three underwent tracheotomy. Recurrence of the abscess was observed in 15 cases, with the recurrence developing within 3 months in 7 cases, and over a period of 3 years in 4 cases. As for the sensitivity of the causative bacteria to antibacterial drugs, 17% of the causative bacteria showed resistance to clindamycin, while none showed resistance to ampicillin/sulbactam (ABPC/SBT). We concluded that ABPC/SBT might be suitable for the initial treatment of peritonsillar abscess, and that we need to bear in mind the possibility of long-term recurrence.

Keywords

- ▶ peritonsillar abscess
- ▶ laryngeal edema
- ▶ recurrence

Introduction

Peritonsillar abscess occurs when a tonsillar inflammation spreads beyond the tonsillar capsule, resulting in retention of the abscess between the palatine tonsillar capsule and pharyngeal constrictor muscle. It is an illness often encountered in daily otorhinolaryngology. However, when the abscess progresses downward and is complicated with laryngeal edema and deep neck abscesses, peritonsillar abscess can be fatal; hence, appropriate antibiotic therapy and pus drainage are necessary.

We investigated clinical features of 107 cases of peritonsillar abscess that were hospitalized and treated at our department, which are reported herein.

Subjects and Methods

Subjects included 107 inpatients with peritonsillar abscess that were treated at our department between January 2014 and December 2018.

The affected site was classified using computed tomography (CT) imaging following the method of Kawabata et al,¹ where the distance between the hard palate and epiglottic vallecula is divided into superior and inferior poles; it is classified as the superior type when the largest site of abscess was located in the superior pole, and as the inferior type when it was located in the inferior pole. Cases that developed deep neck abscess and other serious complications during

received
May 19, 2020
accepted
August 13, 2020

DOI <https://doi.org/10.1055/s-0041-1722857>.
ISSN 2569-1783.

© 2021. The Author(s).

This is an open access article published by Thieme under the terms of the Creative Commons Attribution-NonDerivative-NonCommercial-License, permitting copying and reproduction so long as the original work is given appropriate credit. Contents may not be used for commercial purposes, or adapted, remixed, transformed or built upon. (<https://creativecommons.org/licenses/by-nc-nd/4.0/>)

Georg Thieme Verlag KG, Rüdigerstraße 14, 70469 Stuttgart, Germany

hospital stay were excluded from the analysis because they required a different treatment modality.

At our department, the treatment plan is determined by identifying the abscess site on CT, performing paracentesis and incisional drainage, and then administering a penicillin drug (ampicillin/sulbactam [ABPC/SBT]; 3 g × 3 times daily by intravenous infusion) monotherapy. In the event of any epiglottic edema or arytenoid edema, even if it is mild, hydrocortisone succinate is administered intravenously at an initial dose of 200 mg, followed by 100 mg for the subsequent doses, once daily, which are added until the laryngeal edema disappears. The site of paracentesis for superior pole abscesses was located by finding the abscess on CT by reference to the Chiari and Thompson points identified on CT. Pus drainage by paracentesis is performed for inferior pole abscesses only if an oral approach is possible. Pus drained by paracentesis is subjected to a culture test using a sterile swab or anaerobic porter. While pus is expelled, nasal dressing forceps may be used to widen the incision site to continue drainage. The antibiotic's efficacy is assessed on day 3. If the treatment's efficacy is poor, an antibiotic switch can be considered based on the culture results. Steroids were administered for laryngeal edema according to laryngeal endoscopy findings of acute epiglottitis classified I or higher according to the criteria given by Katori and Tsukuda.² Recurrent cases or recurrent tonsillitis are recommended an elective tonsillectomy.

The present study investigated age, sex, affected site, abscess localization, laryngeal edema, tracheostomy, complications, identified bacteria, and drug-resistant bacteria. The relationship between localization and rate of laryngeal edema was analyzed using the chi-squared test and that between localization and length of hospital stay was analyzed using the Student's *t*-test. The relationship between

white blood cell at the initial examination and C-reactive protein (CRP) levels was analyzed using the Mann–Whitney U-test. Statistical significance was considered as $p < 0.05$.

Results

Age and Sex

The cases included 71 males (66%) and 36 females (34%), aged 18 to 88 years, with a median age of 44 years. The largest proportion of patients was in their 40s ($n = 29$, 27%), followed by patients in their 30s ($n = 19$, 18%; ▶Fig. 1).

Affected Site and Localization

The affected side was the left in 55 patients (51%), the right in 50 (47%), and bilateral in 2 (2%). The abscess was localized in the superior pole in 71 patients (66%) and in the inferior pole in 36 (34%). The mean length of hospital stay among patients with superior and inferior pole abscesses was 6.4 and 7.2 days, respectively; however, the difference in length of hospital stay between patients with different localizations was not significant (▶Fig. 2, $p = 0.12$). In terms of inflammation parameters on blood tests performed at admission, there was no significant difference in white blood cell count on admission between the patients with different localizations ($p = 0.41$), but CRP levels were significantly higher in patients with inferior pole abscesses (▶Fig. 3, $p = 0.005$).

Medical History

A total of 19 patients had previous tonsillitis (18%) and 11 had comorbid diabetes (10%).

Extent of Inflammation

A total 35 cases (33%) were complicated with laryngeal edema, among which 22 (63%) were inferior pole abscesses,

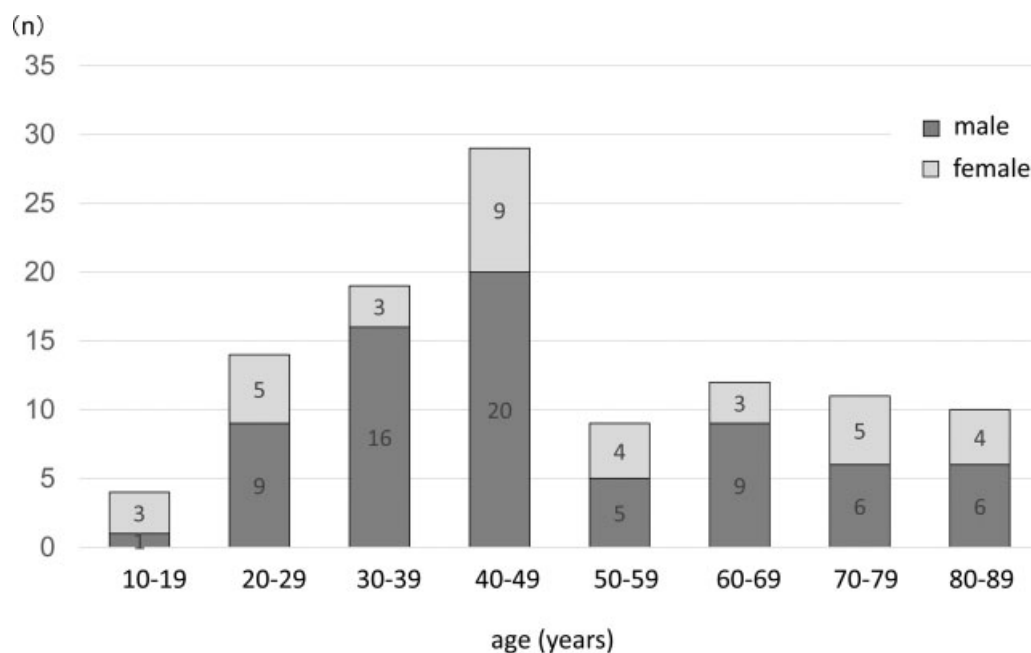


Fig. 1 Subjects (age and sex). The median age was 44 years, and most patients were in their 40s ($n = 29$).

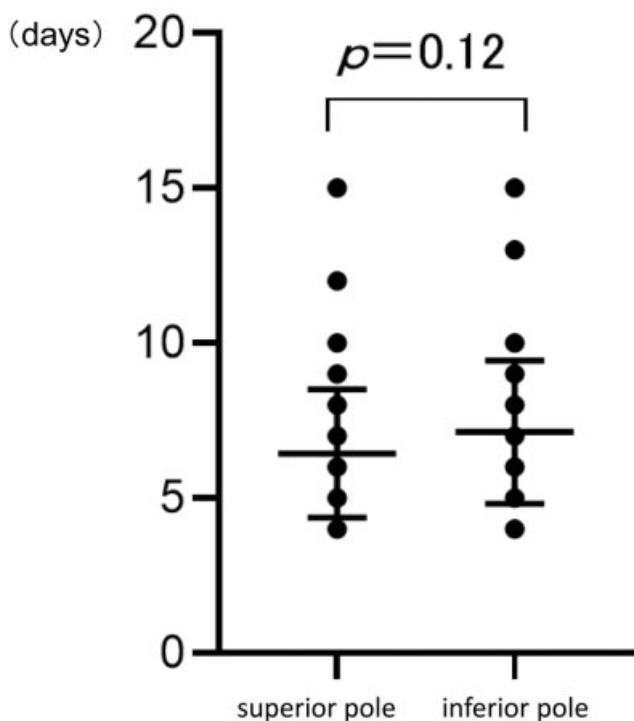


Fig. 2 Hospital stays. The mean hospital stay was 6.4 days. The mean hospital stay for cases of inferior pole abscesses was 7.2 days; there was no significant difference between hospital stays of cases with different abscess sites.

that is, the rate of laryngeal edema complication was significantly higher in cases of inferior pole abscesses (→Fig. 4, $p < 0.05$). Furthermore, three of the cases complicated with laryngeal edema required a tracheostomy (9%), all of which had inferior pole abscess.

Treatment Modality

Incisional drainage was performed at the time of admission on 80 patients (75%), paracentesis drainage with an injection

needle was performed on 21 patients (19%), and antibiotic therapy was used exclusively for treating six patients (7%).

Antibiotics were administered in all patients, which included ABPC/SBT monotherapy in 103 patients (96%). As the symptoms of four patients (4%) undergoing ABPC/SBT monotherapy for 3 days did not improve well, they were switched to meropenem thereafter. Hydrocortisone succinate was used in 43 patients (40%). Steroid therapy did not shorten the length of hospital stay significantly, as the mean length of hospital stay in patients administered steroids was 6.8 days, compared with 6.5 days for patients who were not administered steroids ($p = 0.48$).

Detected Bacteria and Drug Sensitivity

Of the 64 patients whose swab cultures were analyzed, aerobic bacteria were detected in the cultures of 36 patients (56%), and only anaerobic bacteria were detected in the cultures of six patients (11%). Additionally, 17 patients (25%) had a mixed infection of aerobic and anaerobic bacteria, one patient had a fungal infection (2%), and four patients had negative cultures (6%; →Fig. 5). Among the 74 bacterial strains detected, 18 consisted of the aerobic bacteria *α-streptococci* (24%). Among the anaerobic bacteria, *Fusobacteria* were the most common, accounting for nine strains (12%; →Fig. 6). Drug-resistant bacteria were detected in the cultures of 20 patients (31%), among which 12 strains were resistant to clarithromycin and erythromycin (39%, 32%), 10 strains were resistant to benzylpenicillin and ABPC (18%), 9 strains were resistant to clindamycin (CLDM; 17%), and 1 strain was resistant to levofloxacin (3%). Of the strains with known levels of sensitivity to various antibiotics, the rates of sensitivity are presented in →Fig. 7. None of the strains were resistant to ABPC/SBT, which is the first-line therapy used in our department.

Recurrent Cases

Recurrence was observed in 15 patients (14%), of which 5 were aged 10 to 29 years (33%), 7 were aged 30 to 39 years

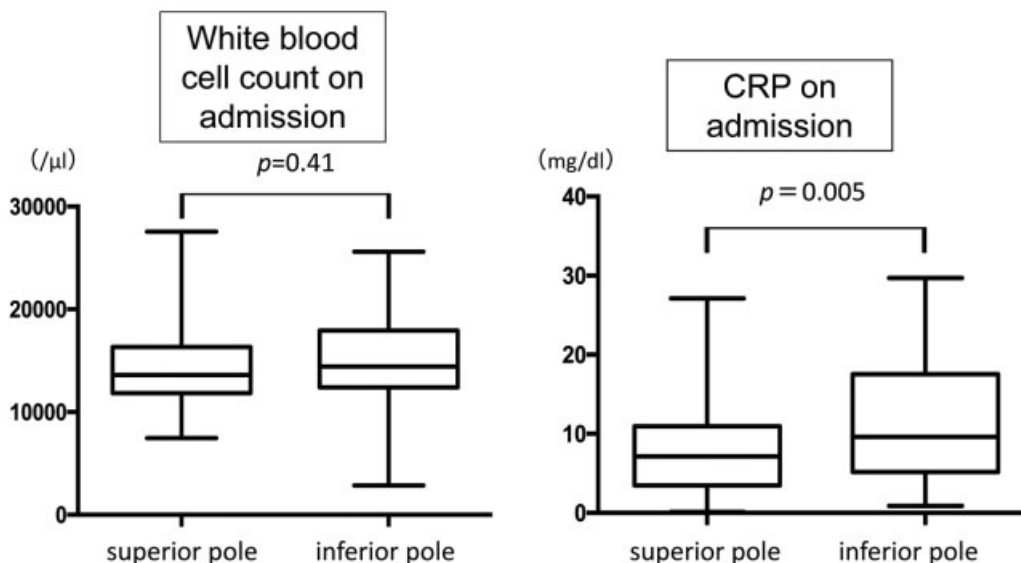


Fig. 3 White blood cell and CRP levels on admission. There was no significant difference in white blood cell count on admission, but CRP levels were significantly higher in cases of inferior pole abscesses. CRP, C-reactive protein.

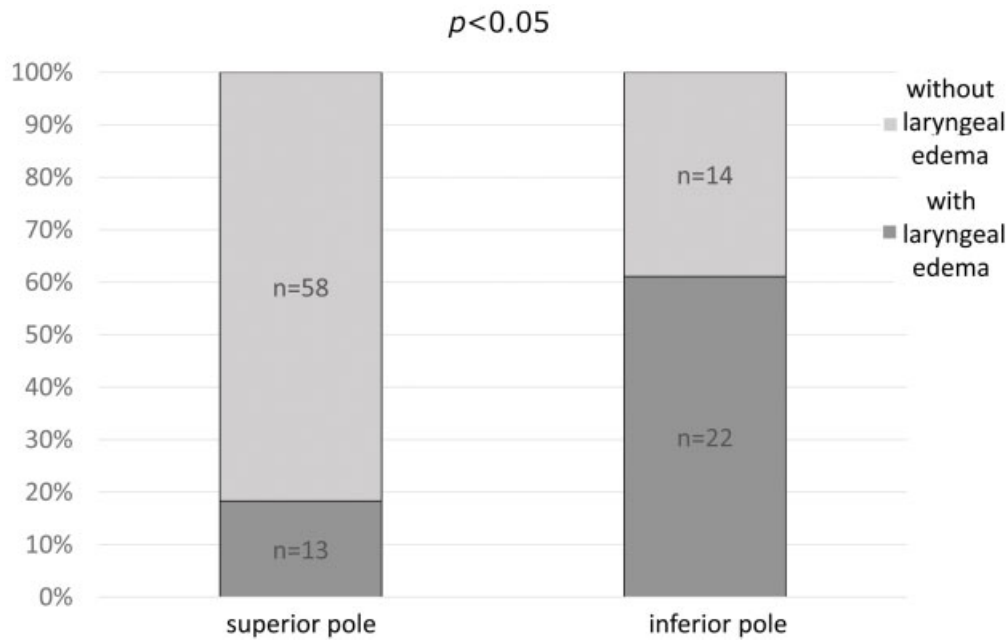


Fig. 4 Rate of abscesses complicated with laryngeal edema according to localization. Laryngeal edema was observed in 35 patients. Of these, 22 patients had abscess localized in the inferior pole, which was significantly higher.

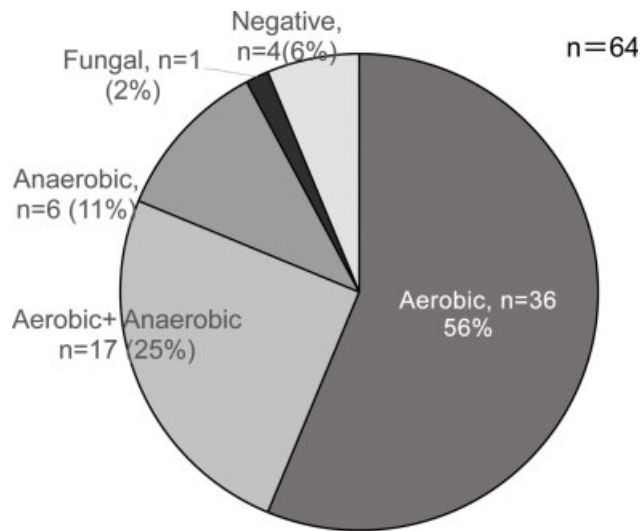


Fig. 5 Detected bacteria (n = 64). Only aerobic bacteria were detected in the cultures of 36 patients; only anaerobic bacteria were detected in 6 patients, and a mixed infection of aerobic and anaerobic bacteria was detected in 17 patients.

(47%), and 3 were aged 50 to 79 years (20%). Of the recurrent cases, none had comorbid diabetes. The period for recurrence was 1 to 3 months in seven patients (47%), but was up to ≥ 3 years in four patients (27%).

Discussion

Peritonsillar abscess is often reported to occur in males in their early to middle adulthood.^{1,3-7} Our study was consistent with the previous reports, as males accounted for 66% of the patients in our study; also, majority of them were in their 30s to 40s. The higher rates of male patients with this

condition can be attributed to the antiplasminogenic effects and anti-inflammatory properties of the female hormone estrogen.⁸

There were no differences in the affected side, although many studies report 0 to 3% bilateral abscesses.^{3,6} The abscesses are localized in the superior pole more frequently than in the inferior pole; the results of our study were similar to the results of previous studies in this regard. Greater depth and proximity to the capsule and infections of Weber's gland located anterosuperiorly are some of the proposed reasons for the higher incidence of abscesses in the superior pole.¹

Laryngeal edema is a frequent complication of peritonsillar abscesses of the inferior pole. Indeed, 61% of lower pole abscesses were complicated with laryngeal edema, and all cases that required a tracheostomy were localized in the inferior pole. However, 12.5% of superior pole abscess types are also complicated with laryngeal edema,⁴ as was observed in 13 patients with superior pole abscess (18%). In this investigation, cases of inferior pole abscesses had higher CRP levels in blood samples taken on admission and significantly higher rates of laryngeal edema than cases of superior pole abscesses. This is because the inferior tonsillar pole has a more fragile external wall than the superior pole, and the peritonsillar space is closed by the pharyngeal constrictor muscle, which tends to make laryngeal symptoms appear earlier and spread inflammation more easily.^{9,10}

When symptoms like peritonsillar swelling or uvular displacement typical in inferior pole abscesses are absent, or when the site is difficult to access for incisional drainage, progression to laryngeal edema can be rapid,¹¹ entailing the need for caution.

In our department, incisional drainage is performed for treatment as much as possible. Steroid therapy is effective for treating early subjective symptoms, eating, and reducing

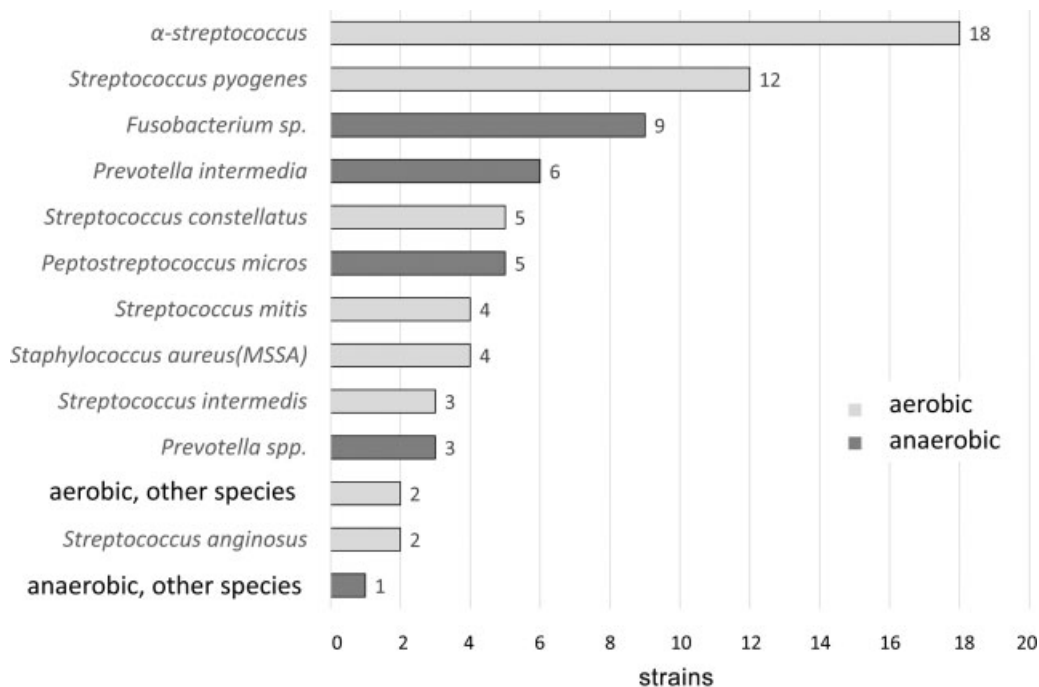


Fig. 6 Prevalence of detected bacterial strains. Among the aerobic strains, *α-streptococcus* (18 strains) was the most numerous, and among the anaerobic strains, *Fusobacterium* (9 strains) was the most numerous.

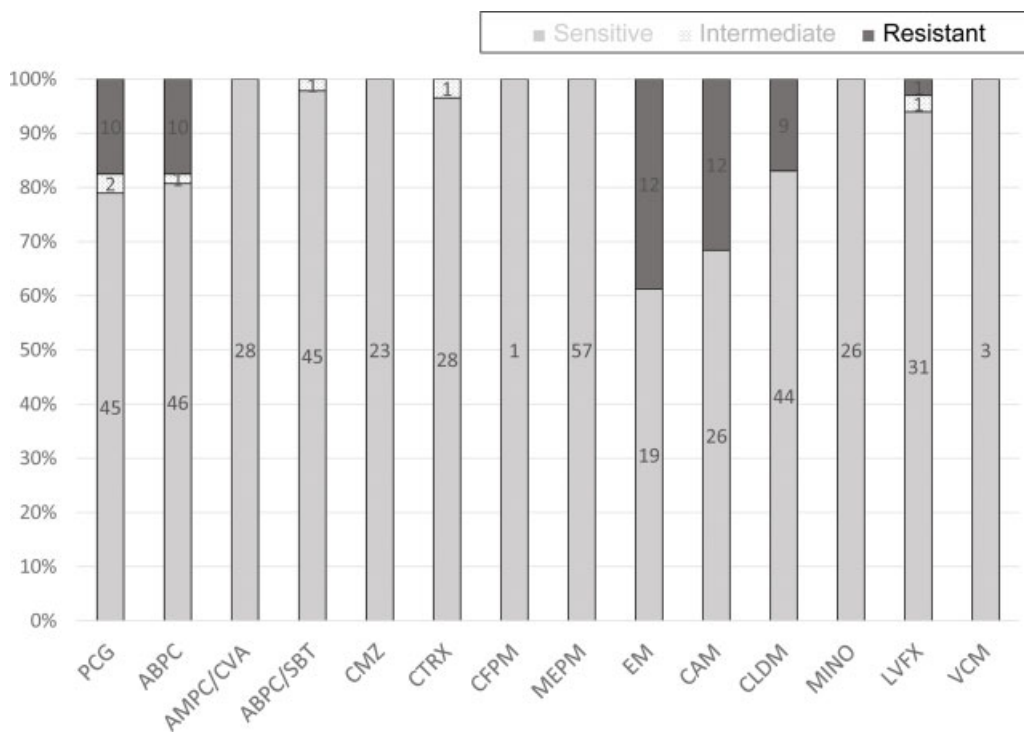


Fig. 7 Drug sensitivity and resistance according to antibiotic type. Resistant strains were resistant to CAM, EM, PCG, ABPC, CLDM, and LVFX. ABPC, ampicillin; ABPC/SBT, ampicillin/sulbactam; AMPC/CVA, amoxicillin/clavulanate; CAM, clarithromycin; CFPM, cefepime; CLDM, clindamycin; CMZ, cefmetazole; CTRX, ceftriaxone; EM, erythromycin; LVFX, levofloxacin; MEPM, meropenem; MINO, minocycline; PCG, benzylpenicillin; VCM, vancomycin.

hospital stay.¹² Hence, steroids are also administered in cases that are severe and those involving laryngeal edema. It was administered in 40% patients in this study; however, significantly shorter hospital stays were not achieved. Nonetheless, considering that steroids were only administered to severe

cases, we can interpret that the lengths of hospital stays were shortened to those more typical of mild cases.

According to one report, steroid use does not result in a difference in recurrence rate.¹³ Hence, steroid should be administered for short periods to shorten disease duration

for abscesses of the inferior pole or abscesses involving intense pharyngalgia, considering comorbidities such as diabetes.

Anaerobic bacteria have been isolated in approximately 30 of 60% cases, depending on facilities.^{3,6,14} Similar to previous studies, bacteria were detected in 36%, including mixed infections. Reports of CLDM-resistant bacterial strains have increased recently,^{3,14-16} and our investigation also detected 17% strains that were CLDM-resistant. None of the strains were resistant to ABPC/SBT, suggesting good therapeutic effects of ABPC/SBT monotherapy. In our department, ABPC/SBT is used as the first-line therapy. Although it is considered an appropriate choice of antibiotic, samples should be cultured as much as possible to select antibiotics based on the knowledge of drug sensitivity to prevent emergence of resistant strains in the future.

Recurrences have been reported to range between 3 and 24.7% in previous reports.^{3,5,17} In our study, recurrences occurred in 14% cases, which were somewhat more frequent in younger patients. Presence or absence of comorbidities, such as diabetes, investigated in our study did not have any correlation with recurrence. Also, 47% of recurrent cases occurred within 3 months. A previous study reported that recurrence occurred after ≥ 1 year in 40% of the recurrent cases.³ Among the patients in our study, seven had a recurrence after >1 year (47%), of which four had a recurrent abscess after >3 years (27%), suggesting the importance of informing patients about the possibility of recurrences occurring after long time periods.

Summary

- We retrospectively investigated 107 cases of peritonsillar abscess that required hospitalization for treatment at our department in the past 5 years.
- Peritonsillar abscesses occurred commonly in males in their 30s to 40s. Laryngeal edema was a complication that occurred in many cases of inferior pole abscesses, but also in 18% cases of superior pole abscesses. The three patients that required airway maintenance were cases of inferior lobe abscesses.
- No strains resistant to ABPC/SBT were detected, suggesting good therapeutic effects of ABPC/SBT monotherapy.
- Recurrences occurred in 15 patients (14%). The recurrence occurred in <3 months in seven cases (47%) and ≥ 3 years in four cases (27%), suggesting the importance of informing patients about the possibility of recurrences after long time periods.

Conflicts of Interest

None declared.

References

- 1 Kawabata M, Umakoshi M, Matsumoto H, et al. The clinical characteristics of inferior pole peritonsillar abscesses. *Stomatopharyngology* 2018;31:187-192
- 2 Katori H, Tsukuda M. Acute epiglottitis: analysis of factors associated with airway intervention. *J Laryngol Otol* 2005;119(12):967-972
- 3 Saiki T, Sakaki M, Watanabe F. Clinical study of 215 cases of peritonsillar abscess. *Practica Oto-Rhino-Laryngologica* 2010;11:1021-1027
- 4 Hara H, Tarumoto S, Sugawara K, et al. A clinical study of peritonsillar abscess with laryngeal edema. *J Jpn Soc Infect Dis Otolaryngol* 2011;29:37-40
- 5 Kurata N, Ishihara A, Sakamoto M, et al. A study on peritonsillar abscesses: severity of peritonsillar abscess and ambulatory care [in Japanese]. *Pract Otorhinolaryngol (Basel)* 2014;107:993-1001
- 6 Kato H, Wada I, Nakada H, et al. A clinical and statistical study of admitted peritonsillar abscess cases [in Japanese]. *Stomatopharyngology* 2006;18:421-428
- 7 Iida S, Murata K, Tamaki K, et al. Peritonsillar abscess: a review of 64 patients. *Practica Oto-Rhino-Laryngologica* 1989;82:1101-1107
- 8 Kraitrakul S, Sirithunyaporn S, Yimtae K. Distribution of minor salivary glands in the peritonsillar space. *J Med Assoc Thai* 2001;84(03):371-378
- 9 Ohori J, Umakoshi M, Miyashita K, Hayamizu Y, Harada M, Kurono Y. Computed tomography image analysis of peritonsillar abscess [in Japanese]. *Nippon Jibiinkoka Gakkai Kaiho* 2013;116(08):947-952
- 10 Licameli GR, Grillone GA. Inferior pole peritonsillar abscess. *Otolaryngol Head Neck Surg* 1998;118(01):95-99
- 11 Nishimoto K, Ohori J, Hayamizu Y, et al. Clinical aspects of superior and inferior pole peritonsillar abscess. *J Jpn Soc Infect Dis Otolaryngol* 2006;24:105-108
- 12 Koçak HE, Acipayam H, Elbistanlı MS, et al. Is corticosteroid a treatment choice for the management of peritonsillar abscess? *Auris Nasus Larynx* 2018;45(02):291-294
- 13 de Cassan S, Thompson MJ, Perera R, et al. Corticosteroids as standalone or add-on treatment for sore throat. *Cochrane Database Syst Rev* 2020;5:CD008268
- 14 Umibe A, Anazawa U, Kessoku H, et al. Clinical analyses of 115 patients with peritonsillar abscess [in Japanese]. *Nippon Jibiinkoka Gakkai Kaiho* 2015;118(10):1220-1225
- 15 Hasegawa H, Ito M, Yoshizaki T, et al. Optimal antibiotics for treating peritonsillar abscess [in Japanese]. *Practica Oto-Rhino-Laryngologica* 2013;106:609-613
- 16 Adachi M, Tobita T, Akizuki H. A Study on 140 hospitalized patients with peritonsillar abscess [in Japanese]. *Practica Oto-Rhino-Laryngologica* 2019;112:47-53
- 17 Ueyama T, Suzuki M, Shigemi H, et al. Clinical study of patients with peritonsillar abscess. *J Jpn Soc Infect Dis Otolaryngol* 1998;16:117-120