



# Avulsion Fracture of the Tibial Tuberosity in an Adolescent: Case Report

## *Fratura por avulsão da tuberosidade da tíbia em adolescente: relato de caso*

Giovani Manhabusqui Pacífico Júnior<sup>1</sup> Marcel Lobato Sauma<sup>1</sup> Lauro Augusto Veloso Costa<sup>1</sup>   
 Luiz Fabiano Presente Taniguchi<sup>1</sup> Francesco Camara Blumetti<sup>1</sup>

<sup>1</sup>Orthopedics and Traumatology Department, Hospital Israelita Albert Einstein, São Paulo, SP, Brazil

Address for correspondence: Giovani Manhabusqui Pacífico Júnior, Orthopedics Resident, Avenida Albert Einstein, 627, Bloco C, Sala 22, Programa Locomotor, Morumbi, São Paulo, SP, 05652-900, Brazil (e-mail: giovani.pacifico@einstein.br).

Rev Bras Ortop 2023;58(5):e808–e812.

### Abstract

The present study reports a rare case of avulsion fracture of the tibial tuberosity in an adolescent. A 14-year-old male patient sprained his left knee during a soccer match. At the first emergency-room visit, he presented pain in his left knee, 2+/4+ edema, and inability to walk and flex the affected knee, but no neurovascular changes or signs of compartment syndrome. Radiographs revealed a physeal fracture at the left proximal tibia, classified by Ogden, Tross and Murphy, and modified by Ryu and Debenham, as type IV, and complemented by Aerts et al. as type IV-B. Immobilization was performed with a plaster cast from the inguinal to malleolar regions, followed by analgesia. The patient was operated on the next day, when open reduction and internal fixation using 4.5-mm cannulated screws were performed. The patient was discharged one day after surgery, with plaster cast immobilization and load restraint for four weeks, and bone consolidation was radiologically confirmed three months after the procedure. The patient evolved with a range of motion similar to that of the contralateral limb, no length discrepancy in the lower limbs, and no complaints after one year of follow-up.

### Keywords

- ▶ tibial fractures
- ▶ fractures, avulsion
- ▶ knee injuries

### Resumo

O presente estudo tem como objetivo relatar um caso raro de fratura por avulsão da tuberosidade da tíbia em adolescente. Um paciente de 14 anos, do sexo masculino, sofreu entorse de joelho esquerdo durante partida de futebol. No primeiro atendimento em pronto-socorro, ele apresentava dor no joelho esquerdo, edema 2+/4+, incapacidade de deambulação e de flexo-extensão do joelho acometido, sem

*Study performed at the Department of Orthopedics and Traumatology from the Municipal Hospital Dr. Moysés Deutsch (M'Boi Mirim), administered by Hospital Israelita Albert Einstein, both located in São Paulo, SP, Brazil.*

received  
June 19, 2020  
accepted  
September 16, 2020

DOI <https://doi.org/10.1055/s-0040-1722596>  
ISSN 0102-3616.

© 2023. Sociedade Brasileira de Ortopedia e Traumatologia. All rights reserved.

This is an open access article published by Thieme under the terms of the Creative Commons Attribution-NonDerivative-NonCommercial-License, permitting copying and reproduction so long as the original work is given appropriate credit. Contents may not be used for commercial purposes, or adapted, remixed, transformed or built upon. (<https://creativecommons.org/licenses/by-nc-nd/4.0/>)

Thieme Revinter Publicações Ltda., Rua do Matoso 170, Rio de Janeiro, RJ, CEP 20270-135, Brazil

**Palavras-chave**

- fraturas da tíbia
- fratura por avulsão
- traumatismos do

alterações neurovasculares ou sinais de síndrome compartimental. Nas radiografias, identificou-se fratura fisária na tíbia proximal esquerda, classificada por Ogden, Tross e Murphy, com modificação por Ryu e Debenham, como tipo IV, e complementada por Aerts et al. como tipo IV-B. Foi realizada imobilização com tala gessada inguino-maleolar e analgesia, e o paciente submetido a cirurgia no dia seguinte, com redução aberta e fixação interna utilizando parafusos canulados 4,5 mm. O paciente recebeu alta no dia seguinte à cirurgia, sendo mantida a imobilização com tala gessada e a restrição de carga por quatro semanas, e apresentou consolidação óssea confirmada por radiografia com três meses do pós-operatório. O paciente evoluiu sem discrepância de comprimento dos membros inferiores, arco de movimento igual ao do membro contralateral, e sem queixas no seguimento de um ano.

**Introduction**

Even though the knees of adolescents are commonly exposed to violent trauma, avulsion fractures of the proximal tibial epiphysis are infrequent, with an incidence ranging from 0.3% to 2.7% of all physical injuries.<sup>1-3</sup> Trauma mechanisms include eccentric contraction of the quadriceps at the beginning of a jump or during landing,<sup>4</sup> in addition to torsion traumas.<sup>5</sup> These injuries are more frequent in males aged between 14 and 16 years.<sup>1</sup> The classification of these fractures was described by Watson-Jones<sup>6</sup> in 1955, and modified by Ogden, Tross and Murphy<sup>7</sup> and, later, by Ryu and Debenham.<sup>8</sup>

The present article is a report of the case of an adolescent with an atypical avulsion fracture of the tibial tuberosity and proximal epiphysis, with a one year of follow-up. The use of the data was approved by the institutional Ethics in Research Committee.

**Case Report**

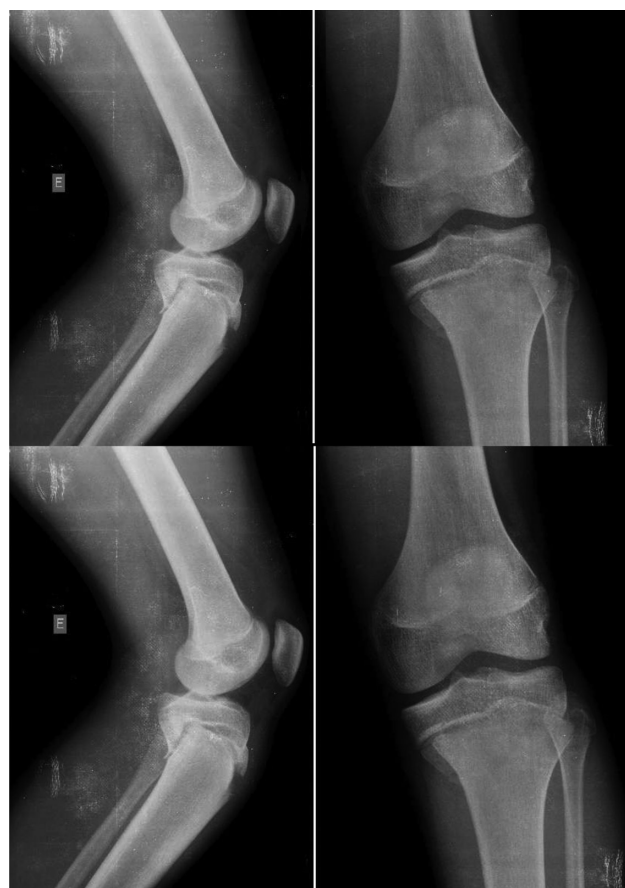A 14-year-old male patient sprained his left knee during a soccer match. He was first cared for at the emergency department of a secondary hospital. He had local pain in the left knee, 2+/4+ edema, and inability to walk and to perform flexion-extension of the knee, but had no neurovascular changes or signs of compartment syndrome. A radiographic series revealed a physical fracture in the left proximal tibia (► Fig. 1), classified as type IV by Ogden, Tross and Murphy,<sup>7</sup> with a modification, by Ryu and Debenham, and later classified as type IV-B by Aerts et al.<sup>5</sup>

Immobilization was initially performed with a plaster cast from the inguinal to malleolar regions, followed by analgesia. The patient was operated on the next day, when open reduction and internal fixation using 4.5-mm cannulated screws were performed (► Figs. 2A and 2B). The patient was discharged one day after surgery, with plaster cast immobilization and load restriction for four weeks. Then, partial load with crutches was allowed for two weeks, gradually progressing to full load with physical therapy to regain the range of motion of the knee. Bone consolidation was radiologically confirmed three months after the procedure (► Figs. 2C and 2D), when the patient was allowed to resume sports

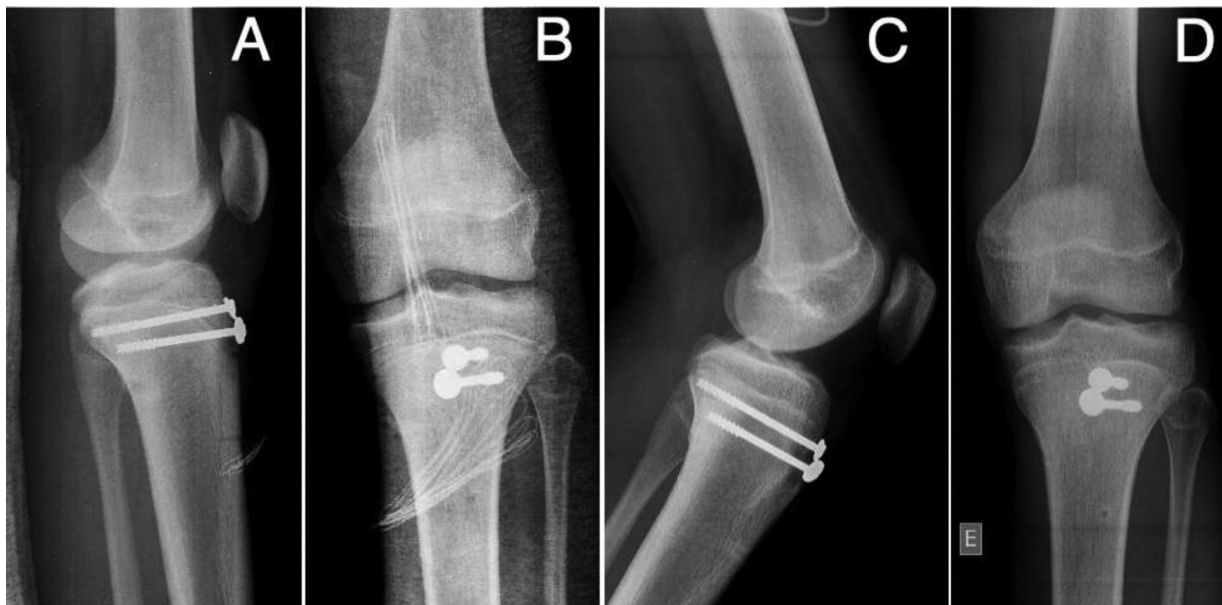activities. During the one-year follow-up, the patient evolved with no length discrepancy in the lower limbs nor the development of genu recurvatum, maintaining a range of motion similar to that of the contralateral limb (► Figs. 3 and 4).

**Discussion**

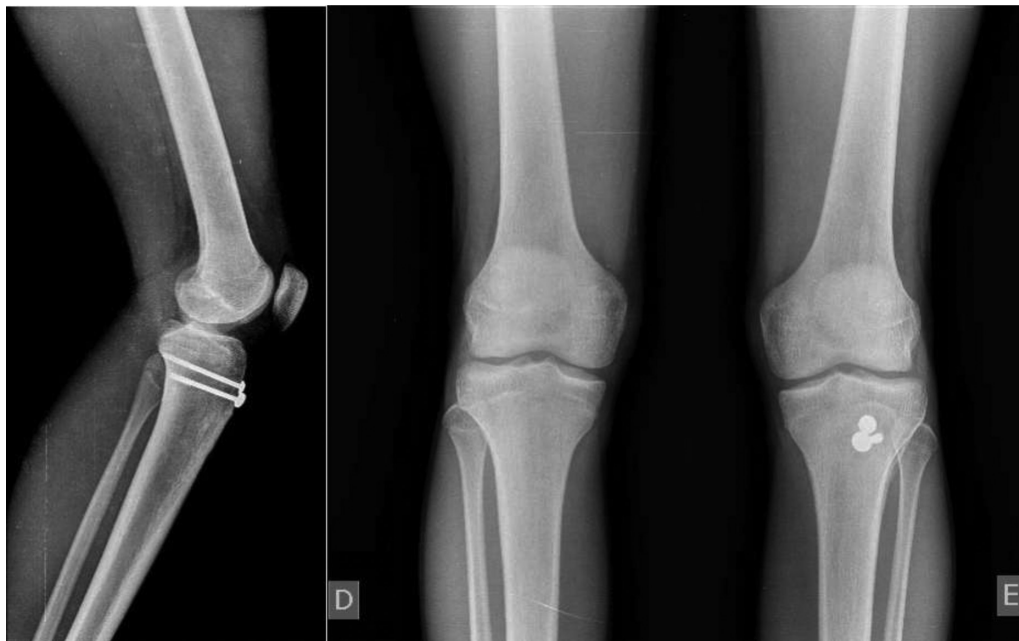The physis, which is not as stiff as the remaining bone tissue, is an area of the immature skeleton highly susceptible to injury. Since excessive physical activity increases the physal



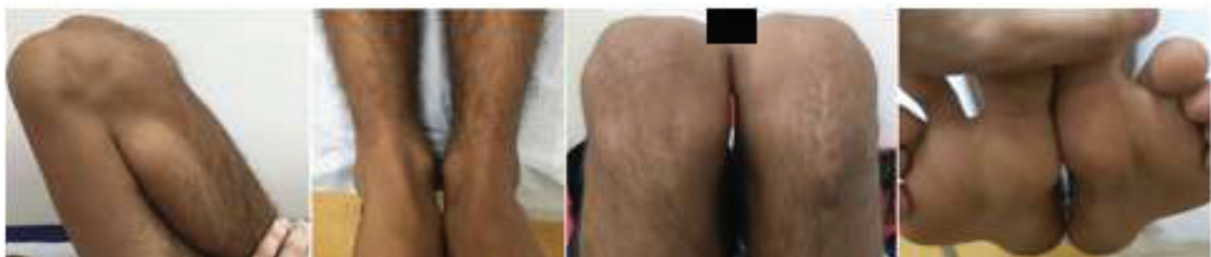**Fig. 1** Anteroposterior and lateral radiographs of the left knee showing avulsion fracture of the tibial tuberosity.



**Fig. 2** Anteroposterior and lateral radiographs at the immediate postoperative period (A,B); anteroposterior and lateral radiographs three months after surgery (C,D).



**Fig. 3** Radiographs one year after surgery.



**Fig. 4** Clinical images one year after surgery.

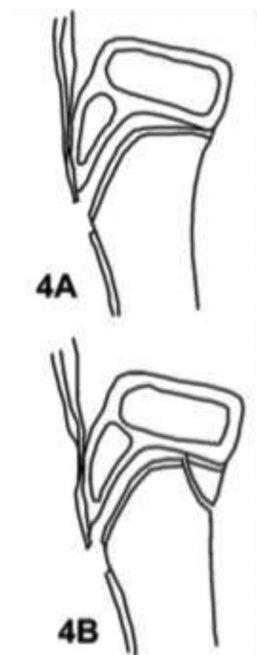
load, adolescent athletes present a higher risk of suffering proximal tibial injuries. The predisposing factors include low patella, shortened hamstrings, preexisting Osgood-Schlatter disease, and physeal abnormalities.<sup>9</sup>

The growth plate consists of four layers. Mechanically, the hypertrophic cell zone is the weakest region, and a common site for physical injury. The proximal tibial epiphysis is the second largest bone epiphysis of the body, following the distal epiphysis of the femur. It is fragile because of the dorsal cartilage of the apophysis (tibial tuberosity), which is influenced by traction forces throughout the ossification and fusion phases.<sup>5</sup> This fusion is not uniform, as the posterior region closes before the anterior region.<sup>2</sup> Since the anterior region is more vulnerable to traction forces because of the patellar tendon attachment, an avulsion fracture at a closed posterior region causes a posterior metaphyseal fracture (Salter-Harris type II),<sup>5</sup> as observed in the case herein reported. This lesion is believed to be rare because of the small ligament attachment at the tibial proximal epiphysis, making this bone free from varus and valgus strains to the knee.<sup>3</sup>

In 1995, Watson-Jones<sup>6</sup> classified proximal tibial physis injuries into 3 types. Type I is defined as an avulsion of the distal part of the tuberosity, distal to the proximal tibial physis. In type II, the injury extends across the entire physis, but does not reach the knee joint. Type III is an avulsion extending proximally to the knee physis.<sup>6</sup> This division was modified by Ogden, Tross and Murphy,<sup>7</sup> who created two groups to define fragment deviation (subtype A) and comminution (subtype B). Later, Ryu and Debenham<sup>8</sup> defined type IV, describing it as a fracture that extends through the physis and causes an avulsion of the entire proximal epiphysis. Aerts et al.<sup>5</sup> proposed the subdivision of type IV into type IV-A, in which there is avulsion of the entire epiphysis alone (Salter-Harris I), and type IV-B, in which, in addition to a complete physeal lesion, the posterior part of the metaphysis is involved, highlighting the well-known Thurston-Holland fragment (Salter-Harris II), as in the case herein described (► Fig. 5).

The treatment of these lesions presents some difficulty regarding reduction due to the constant force acting on the quadriceps. As most patients are in the final stage of physical growth, few growth changes are noticed.<sup>10</sup> In this case, there were no changes in the range of motion of the joint and in the length of the limb. An accepted treatment protocol is preconized by Frey et al.,<sup>4</sup> which defines the conservative therapy with immobilization in extension for four to six weeks in type-IA, -IB and -IIA fractures. The remaining types are treated with osteosynthesis with open reduction and internal fixation followed by immobilization for four to six weeks, as in the case herein described. Early diagnosis and treatment improve functional outcomes and return to activities.<sup>10</sup>

The complications include compartment syndrome, lesion to the cruciate ligaments or the meniscus, quadriceps rupture, quadriceps hypotrophy, hypertrophy or fracture of the tibial tuberosity, calcification of the patellar tendon, limb



**Fig. 5** Ryu and Debenham<sup>8</sup> classification of type IV, modified by Aerts et al.<sup>5</sup> to IV-B.

discrepancy, genu recurvatum, pseudoarthrosis, and low patella.<sup>8</sup> None occurred in the case herein reported.

## Conclusion

Avulsion fracture of the tibial tuberosity, although infrequent and potentially serious due to the important physeal involvement, presents good outcomes with the usual surgical treatment strategies. We describe a rare case of a type-IV-B fracture as classified by Aerts et al.<sup>5</sup> The clinical and functional outcomes were good, similar to those described in the literature.

## Financial Support

The present research received no specific funding from public, commercial, or not-for-profit sector agencies.

## Conflict of Interests

The authors have no conflicts of interest to declare.

## References

- Nanni M, Butt S, Mansour R, Muthukumar T, Cassar-Pullicino VN, Roberts A. Stress-induced Salter-Harris I growth plate injury of the proximal tibia: first report. *Skeletal Radiol* 2005;34(07):405-410
- Mudgal CS, Popovitz LE, Kasser JR. Flexon-type Salter-Harris I injury of the proximal tibial epiphysis. *J Orthop Trauma* 2000;14(04):302-305
- Rhemrev SJ, Sleeboom C, Ekkelkamp S. Epiphyseal fractures of the proximal tibia. *Injury* 2000;31(03):131-134
- Frey S, Hosalkar H, Cameron DB, Heath A, David Horn B, Ganley TJ. Tibial tuberosity fractures in adolescents. *J Child Orthop* 2008;2(06):469-474

- 5 Aerts BR, Ten Brinke B, Jakma TS, Punt BJ. Classification of proximal tibial epiphysis fractures in children: Four clinical cases. *Injury* 2015;46(08):1680–1683
- 6 Watson-Jones R. The classic: "Fractures and Joint Injuries" by Sir Reginald Watson-Jones, taken from "Fractures and Joint Injuries," by R. Watson-Jones. Vol. II, 4th ed. Baltimore: Williams and Wilkins Company; 1955. *Clin Orthop Relat Res* 1974;(105)4–10
- 7 Ogden JA, Tross RB, Murphy MJ. Fractures of the tibial tuberosity in adolescents. *J Bone Joint Surg Am* 1980;62(02):205–215
- 8 Ryu RK, Debenham JO. An unusual avulsion fracture of the proximal tibial epiphysis. Case report and proposed addition to the Watson-Jones classification. *Clin Orthop Relat Res* 1985;(194):181–184
- 9 Roy SP, Nag K. Simultaneous bilateral tibial tuberosity avulsion fractures in adolescence: case report and review of 60 years of literature. *Injury* 2013;44(12):1953–1955
- 10 Silva Júnior AT, da Silva LJ, da Silva Filho UC, Teixeira EM, Araújo HRS, Moraes FB. Fratura-avulsão tuberosidade anterior da tíbia em adolescente – Relato de dois casos. *Rev Bras Ortop* 2016;51(05):610–613