



Costovertebral Osteoarthritis: Rare Differential Diagnosis of Back pain in young patients. Case Report*

Osteoartrose costovertebral: diagnóstico diferencial raro de dorsalgia no paciente jovem. Relato de caso

João Ribeiro Afonso¹  Diogo Soares¹ Daniel Brás Lopes¹ Rui Milheiro Matos¹ Rui Peixoto Pinto¹

¹ Department of Orthopedics and Traumatology, Hospital Santa Maria, Porto, Portugal

Address for correspondence João Ribeiro Afonso, MD, Rua de Camões 906, 4049-025, Porto, Portugal (e-mail: jmafonso89@gmail.com).

Rev Bras Ortop 2022;57(2):345–347.

Abstract

The differential diagnosis of dorsal thoracic pain can be a challenge due to the proximity of the dorsal column to vital organs as well as to its unique anatomy, innervation, and rib joint. The patterns of referred visceral pain require, in most cases, extensive complementary diagnostic tests in order to exclude severe conditions. Referred pain patterns often result in numerous and expensive visceral workups in order to exclude serious conditions, and costovertebral joint osteoarthritis is usually only considered when the origin of the pain remains unexplained. The authors present the case of a 40-year-old man with disabling dorsal pain due to isolated costovertebral osteoarthritis. The symptomatology was controlled after injection of methylprednisolone guided by computed tomography. This clinical case aims to describe the clinical presentation of a rare entity that should be considered in the differential diagnosis of back pain.

Keywords

- ▶ osteoarthritis
- ▶ lumbar vertebrae
- ▶ thoracic vertebrae

Resumo

O diagnóstico diferencial de dorsalgia revela-se um desafio pela proximidade da coluna dorsal a órgãos vitais assim como por sua anatomia única, inervação e articulação com as costelas. Os padrões de dor referida visceral obrigam, na maioria das vezes, a extensivos exames complementares de diagnóstico de forma a excluir condições graves. A osteoartrose da articulação costovertebral é um diagnóstico pouco reconhecido, e habitualmente é somente considerado quando a fonte de dor continua sem explicação após extensa investigação. Os autores apresentam o caso de um homem de 40 anos de idade com dor dorsal incapacitante devido a osteoartrose costovertebral isolada. A sintomatologia foi controlada após a injeção de metilprednisolona guiada por tomografia computadorizada. Este caso clínico tem como objetivo descrever a apresentação clínica de uma entidade rara que deverá ser considerada no diagnóstico diferencial de dorsalgia.

Palavras-chave

- ▶ osteoartrite
- ▶ vértebras lombares
- ▶ vértebras torácicas

* Work developed in the Department of Orthopedics and Traumatology, Hospital Santa Maria, Porto, Portugal.

received
September 13, 2020
accepted
October 9, 2020
published online
March 31, 2021

DOI <https://doi.org/10.1055/s-0040-1722587>.
ISSN 0102-3616.

© 2021. Sociedade Brasileira de Ortopedia e Traumatologia. All rights reserved.
This is an open access article published by Thieme under the terms of the Creative Commons Attribution-NonDerivative-NonCommercial-License, permitting copying and reproduction so long as the original work is given appropriate credit. Contents may not be used for commercial purposes, or adapted, remixed, transformed or built upon. (<https://creativecommons.org/licenses/by-nc-nd/4.0/>)
Thieme Revinter Publicações Ltda., Rua do Matoso 170, Rio de Janeiro, RJ, CEP 20270-135, Brazil

Introduction

Back pain is a prevalent condition that is responsible for extensive direct and indirect costs as a result of healthcare systems utilization and absenteeism. Its etiological clarification can be imposed as a true diagnostic challenge given its proximity to vital organs and the phenomenon of referred pain that results from the neuronal convergence of visceral and somatic afferent fibers at the level of the dorsal spine.^{1,2} This explains the broad spectrum of differential diagnoses of back pain, including disc herniation, vertebral fracture, facet degenerative changes, intercostal neuralgia, rib fractures, and non-orthopedic forum pathologies, namely cardiac, spinal, pulmonary and abdominal.³

Although osteoarthrosis (OA) of the costovertebral joint is a common degenerative finding in geriatric patients,⁴ its isolated occurrence in young patients is rare, with it being poorly recognized in the genesis of dorsal pain.⁵ The authors present the case of a young patient with dorsal pain, irradiated to the left hemithorax, originating from OA of a costovertebral joint. This case highlights the complexity of the diagnosis of dorsal pain and aims to sensitize physicians to the existence of this diagnosis in order to avoid costly and often unnecessary negative visceral workups.

Case Description

A 40-year-old male patient reported chest pain with 4 weeks of evolution, of insidious appearance, irradiated to the left thorax. The pain motivated two visits to the emergency department, where the patient was evaluated by an internal medicine specialist and underwent electrocardiogram, chest X-ray, echocardiogram, abdominal ultrasonography, and analytical study (blood count, sedimentation speed and C-reactive protein). All tests were negative for cardiac, pulmonary, or abdominal pathology, and the patient's pain was interpreted as a lower trapezius muscle contracture. He was prescribed muscle relaxants, physiotherapy and subsequently referred for evaluation at our institution. The symptoms became progressively disabling with excruciating pain during trunk torsional movements, deep inspiration, or coughing, significantly limiting activities of daily living and sleep quality. The patient denied any history of trauma, fever, fatigue, or weight loss. He reported previous episodes of pain, similar to the current one, but of lower intensity and self-limited, susceptible to symptomatic relief with the use of antiinflammatory drugs. On objective examination, there were no asymmetries or thoracic masses. Palpation of thoracic spinous apophyses, interspinous ligament, and costovertebral junction was painless; however, compression of the left lower ribs triggered paravertebral pain. Neurological examination was normal.

Magnetic resonance imaging of the dorsal column revealed hyposignal in T1-weighted sequences and hypersignal in T2-weighted sequences at the level of the left D10 costovertebral joint. Intervertebral disc pathology was excluded. Due to the uncertain nature of the lesion, dorsal computed tomography (CT) scan and bone scintigraphy

were requested. The CT revealed the presence of degenerative alterations of the D10 costovertebral joint (►**Figure 1**) in agreement with a focal increase in the uptake of technetium-99m (Tc-99m) in the same location (►**Figure 2**), and the results were in favor of the diagnosis of costovertebral OA. The dosing of inflammatory markers (sedimentation rate and C-reactive protein), rheumatological markers (rheumatology factor, antinuclear antibody, anti-dsDNA antibodies), HLA-B27, viral markers, and blood cultures were all negative. Intralesional injection of CT-guided corticosteroids was proposed for diagnosis and therapy. The left D10 costovertebral joint was first properly identified by local injection of 1 mL of lidocaine (20 mg/mL), which resulted in immediate pain relief. The positive response to the local anesthetic allowed us not only to confirm the location of the lesion, but also to confirm the diagnosis. Subsequently, 2 mL of methylprednisolone (40 mg/mL) was administered locally of dorsal back pain remain poorly represented in the literature.

Progressive pain relief was observed over the following days, with complete resolution at 3 weeks after corticosteroid injection. Pain recurrence has not been observed in the last 2 years.

Discussion

The role of costovertebral OA in the genesis of dorsal back pain remain poorly represented in the literature. The high prevalence of costovertebral degenerative changes in asymptomatic patients requires a careful interpretation of imaging findings, and a clinical-imaging correlation is essential. Although these are quite common in geriatric age,⁴ their occurrence in young patients without rheumatic diseases is rare. Clinically, they have an extremely variable spectrum and may be asymptomatic or have a highly debilitating presentation, with patients reporting posterior chest pain, which may radiate to the chest or be felt along the respective rib.³ Pain may be exacerbated by provocative maneuvers, including deep inspiration, cough, chest flexion or rotation, and compression of the corresponding rib.

The most relevant publication on this is by Sales et al.,⁵ who presented a series of five cases of isolated costovertebral OA (mean age of 40.6 years) treated favorably by performing a rib resection arthroplasty.

The diagnostic validity of bone scintigraphy under degenerative conditions remains questionable.⁶ Verdoorn et al.⁷ evaluated the correlation between increased Tc-99m uptake in the costovertebral joints, the presence of local pain and favorable response to percutaneous injection of anesthetic and corticosteroids. The authors found that more than half of the cases with Tc-99m hyperuptake were asymptomatic, and there was no correlation between the presence of pain and the predictability of response to percutaneous injection treatment. These results are justified by the possibility of confusing painful points and the presence of more than one increased tc-99m uptake area, which reduces the diagnostic efficacy and predictability of favorable response to treatment with percutaneous corticosteroid injection.

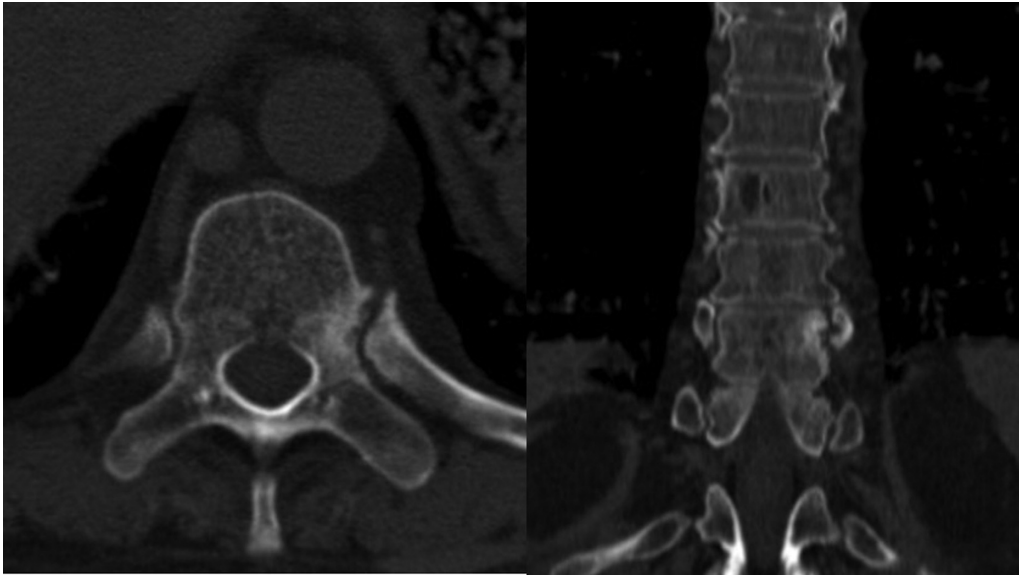


Fig. 1 Computed tomography. Axial (left) and coronal (right) cuts. The 10th left costovertebral joint presents significant degenerative changes, with sclerosis at the levels of the vertebral body, pedicle, and rib head.

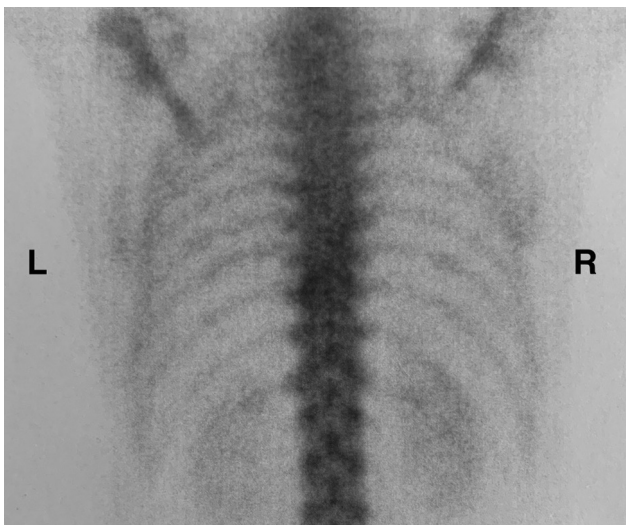


Fig. 2 Bone scintigraphy marked with Tc-99m. Isolated hyperuptake at the level of the 10th left costovertebral joint (L- left side; R-right side).

In our patient, it was possible to obtain a complete relief of symptoms with corticosteroid injection; however, according to the results reported by Sales et al.,⁵ a recurrence of symptoms in the medium/long term can be expected, and

resection arthroplasty can be considered in order to obtain lasting results.

Conflict of Interests

The authors declare that there is no conflict of interests.

References

- 1 Saker E, Graham RA, Nicholas R, et al. Ligaments of the Costovertebral Joints including Biomechanics, Innervations, and Clinical Applications: A Comprehensive Review with Application to Approaches to the Thoracic Spine. *Cureus* 2016;8(11):e874
- 2 Young BA, Gill HE, Wainner RS, Flynn TW. Thoracic costotransverse joint pain patterns: a study in normal volunteers. *BMC Musculoskelet Disord* 2008;9:140
- 3 Fruth SJ. Differential diagnosis and treatment in a patient with posterior upper thoracic pain. *Phys Ther* 2006;86(02):254–268
- 4 Nathan H, Weinberg H, Robin GC, Aviad I. The Costovertebral Joints, Anatomical-Clinical Observations in Arthritis. *Arthritis Rheum* 1964;7:228–240
- 5 Sales JR, Beals RK, Hart RA. Osteoarthritis of the costovertebral joints: the results of arthroplasty resection. *J Bone Joint Surg Br* 2007;89(10):1336–1339
- 6 From Maeseneer M, Lenchik L, Everaert H, et al. Evaluation of lower back pain with bone scintigraphy and SPECT. *Radiographics* 1999;19(04):901–912, discussion 912–914
- 7 Verdoorn JT, Lehman VT, Diehn FE, Maus TP. Increased 99mTc MDP activity in the costovertebral and costotransverse joints on SPECT-CT: is it predictive of associated back pain or response to percutaneous treatment? *Diagn Interv Radiol* 2015;21(04):342–347