



Enhancing Preoperative Planning in Orthopedic Trauma Surgery Using a Presentation Software*

Aprimoramento do planejamento pré-operatório na cirurgia de trauma ortopédico usando um software de apresentação

Alejandro Ordas-Bayon¹ David Cabrera Ortiz² Karl Logan¹ Rodrigo Pesantez³

¹ Department of Trauma and Orthopedic Surgery, Cambridge University Hospitals, Cambridge, United Kingdom

² Department of Trauma and Orthopedic Surgery, Universidad del Rosario, Bogotá, Colombia

³ Department of Orthopedics and Traumatology, Fundación Santa Fe de Bogotá, Bogotá, Colombia

Address for correspondence Alejandro Ordas Bayon, MD, Fellow of the European Board of Orthopedics and Traumatology (FEBOT), Department of Trauma and Orthopedic Surgery, Cambridge University Hospitals, Cambridge Biomedical Campus, Hills Road, CB2 0QQ, Cambridge, United Kingdom (e-mail: ordastrauma@gmail.com).

Rev Bras Ortop 2021;56(4):517–522.

Abstract

Keywords

- ▶ preoperative care
- ▶ orthopedics
- ▶ trauma
- ▶ surgery
- ▶ education

Preoperative planning (PP) is critical to ensure a successful outcome in orthopaedic trauma surgery. Since it was first described thirty years ago, no modifications have been made to the original preoperative planning (OPP) technique, which was written by hand using pen and paper. We believe that the use of presentation software (such as Microsoft PowerPoint, Microsoft Corp., Redmond, WA, US) can ease, improve and update the OPP and complement three-dimensional PP. The objective of the present paper is to describe our method for PP using a presentation software (PS).

Resumo

Palavras-chave

- ▶ cuidados pré-operatórios
- ▶ ortopedia
- ▶ trauma

O planejamento pré-operatório (PP) é fundamental para garantir um resultado bem-sucedido na cirurgia de trauma ortopédico. Desde que foi descrita pela primeira vez há trinta anos, não foram feitas modificações na técnica de planejamento pré-operatório original (PPO), que foi escrita à mão usando caneta e papel. Acreditamos que o uso de um software de apresentação (como o Microsoft PowerPoint, Microsoft Corp., Redmond, WA, EUA) pode facilitar, melhorar e atualizar o PPO e complementar o PP tridimensional. O objetivo deste artigo é apresentar nosso método de PP por meio de software de apresentação (SA).

* Work developed at the Department of Trauma and Orthopedic Surgery, Fundación Santa Fe, Bogotá, Colombia.

received
April 28, 2020
accepted
September 16, 2020
published online
April 15, 2021

DOI <https://doi.org/10.1055/s-0040-1721833>.
ISSN 0102-3616.

© 2021. Sociedade Brasileira de Ortopedia e Traumatologia. All rights reserved.
This is an open access article published by Thieme under the terms of the Creative Commons Attribution-NonDerivative-NonCommercial-License, permitting copying and reproduction so long as the original work is given appropriate credit. Contents may not be used for commercial purposes, or adapted, remixed, transformed or built upon. (<https://creativecommons.org/licenses/by-nc-nd/4.0/>)
Thieme Revinter Publicações Ltda., Rua do Matoso 170, Rio de Janeiro, RJ, CEP 20270-135, Brazil

Introduction

Preoperative planning (PP) is an essential step in orthopedic trauma surgery.¹⁻³ It enables the surgeon to reflect on the case in an environment free of pressure.⁴ It also helps to select the materials and implants needed for fracture reduction and fixation, and can therefore help anticipate problems, providing the opportunity to design alternative plans. To summarize, PP saves time and minimises complications, which translates into better patient outcomes.^{1,5}

The original preoperative planning (OPP) technique⁶ includes four sequential stages:

1. **Reconstruction** involves identifying and reassembling the fracture fragments, which are drawn on tracing paper using the uninjured side as a template.
2. **Decision-making** involves defining the surgical indication and addressing issues such as approach and fixation methods to minimise the damage to soft tissue.
3. **Fixation**. Implants are selected and templated physically on the previous drawing to enable the surgeon to determine their function, length and size, and whether they need to undergo modifications.
4. **Surgical tactic**: It is developed in four stages: listing the required *equipment*, *preparation* (surgical team, anesthesia, antibiotics, tourniquet, expected blood loss, estimated surgical time), a *stepwise list* of the whole procedure, and a *postoperative regime*.

The OPP yields three documents: the surgical tactic, the annotated drawing, and the equipment list.

This simple and reproducible method, which remains valid today, established the principles of PP in orthopedic trauma. We believe that this process can be updated and enhanced by the use of a ubiquitous digital tool such as a presentation software (PS).

Technique for PPPS

Preoperative planning with a presentation software (PPPS) follows the same principles as the OPP. We would encourage the reader to refer to the complementary videos to better understand the following processes.

Materials required for the PPPS:

1. **Hardware**: either PC (Windows or Linux), Mac, IOS and/or Android devices.
2. **Software**: PSs, such as PowerPoint, Keynote etc. The authors used Microsoft PowerPoint (Microsoft Corp., Redmond, WA, US), version 16.27 for Mac.

Basic Settings (► Video 1)

Video 1

Introduction to the PPPS and reconstruction. Online content including video sequences viewable at: https://s20.video-stream-hosting.de/tvg/ejournal/10.1055-s-00042410/10-1055-s-0040-1721833-rbo-20-00126-v1_360p.mp4.



Table 1 Presentation Layout for the preoperative planning with a presentation software

- Title slide Keywords and date identifying the case
- Medical history Patient information and mechanism of injury
- Soft-tissue status Pictures of the involved area
- Layout of the operating theater Single slide showing staff and theater layout (► Fig. 1)
- Imaging
- Reconstruction
- Decision-making
- Fixation
- Surgical tactic
◦ Equipment
◦ Preparation
◦ Stepwise plan

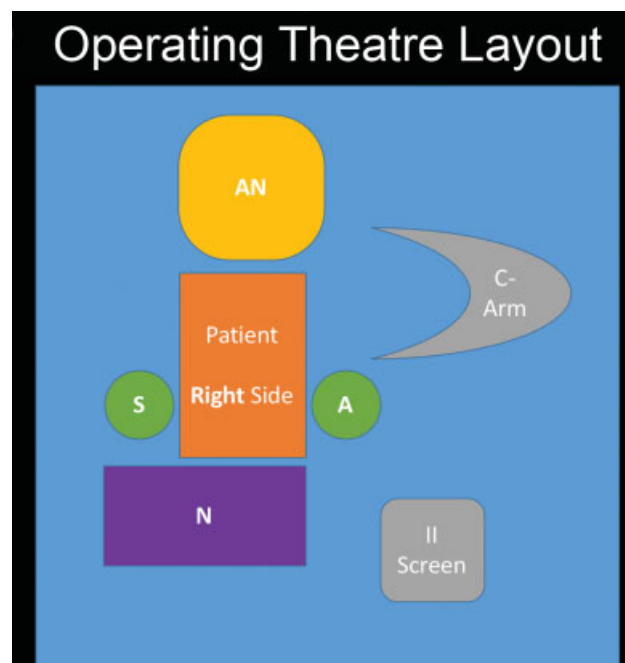


Fig. 1 Slide representing the layout of the operating theater. As it can be seen by the operating room personnel, it improves team communication and saves time. S = surgeon; A = assistant; N = nurse; AN = anesthesiologist; II screen = image intensifier screen.

Once the program is open, change the *Design* and select the black slide background with a white font, as this increases the contrast of the radiographs. Add the slides corresponding to the proposed PPPS layout (► **Table 1**) and operating theater layout (► **Fig. 1**).

Imaging

Preoperative relevant radiographs, computed tomography (CT) and/or magnetic resonance imaging (MRI) frames are

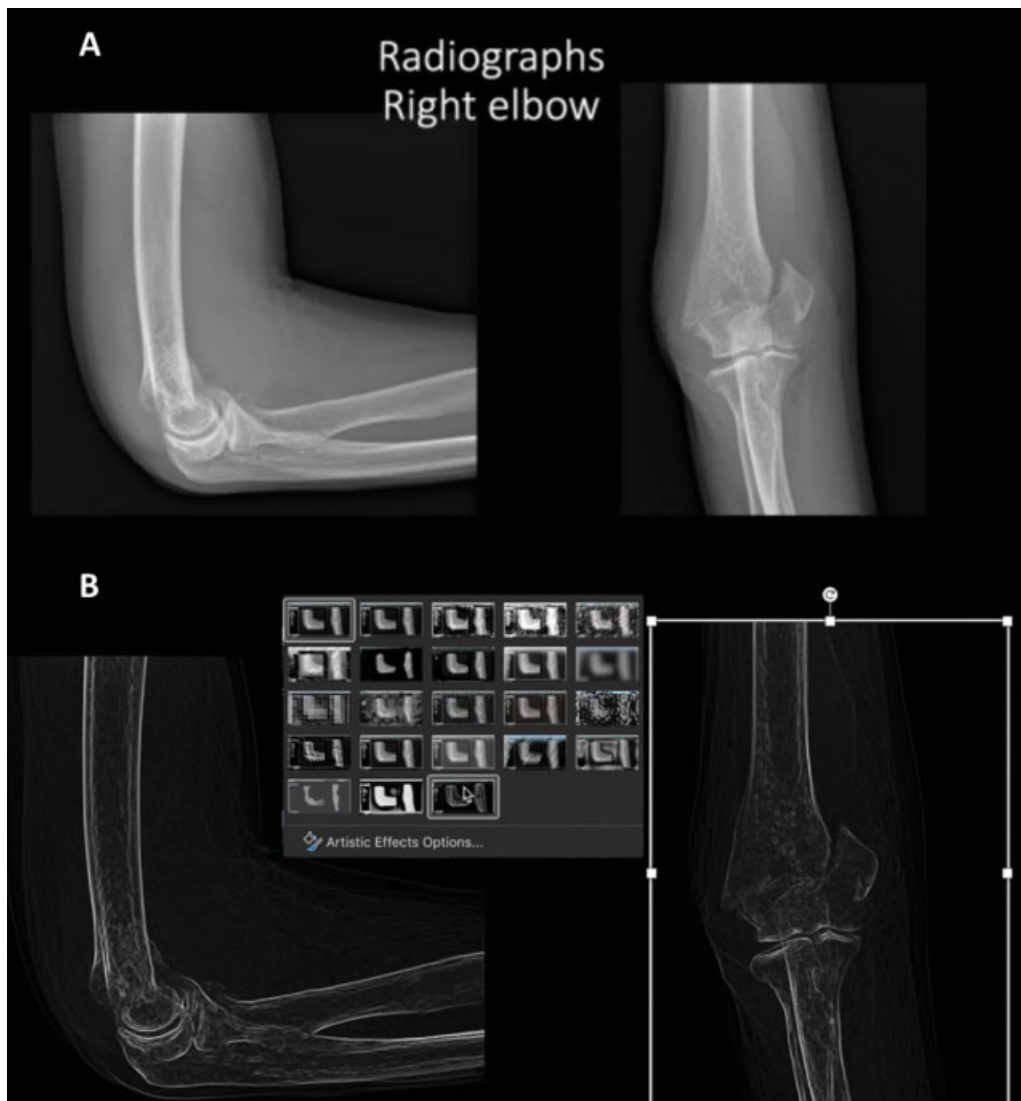

Fig. 2 Orthogonal views of a distal humerus fracture (A). The same images after applying the following commands: *Picture Format > Artistic Effects > Glow Edges* (B).

added to the presentation. Most picture archiving and communication system (PACS) viewers enable the user to export and save the images in generic format (.jpeg, .png, .tiff). This is our preferred method because the quality of the image is much higher. The alternative is to paste a screenshot of the images onto a slide and crop them (*Picture format > Crop*). We display orthogonal views of the fracture in one slide, which will then be used as a model to reconstruct and fix the fracture (**Fig. 2A**). The quality of the images can be enhanced if needed using *Picture Format > Corrections > Sharpen 50%*.

Reconstruction (**Video 1**)

To identify fracture fragments, the presentation software offers two options. The first is to select each image and go to *Picture Format > Artistic Effects > Glow Edges*. This effect simulates hand-drawing (**Fig. 2B**). The second option is to use the *Draw* tool, which enables the surgeon to draw directly onto the image.

Fracture fragments can then be individually isolated by selecting the image and clicking on *Picture Format > Remove*

Background. This enables the surgeon to delineate each fragment separately using both *Mark Areas to Keep* and *Mark Areas to Remove* (**Fig. 3 A, B, C, D**). After all main fracture fragments are isolated images, they can be pasted onto a new slide and manipulated by dragging and rotating them, so the fracture can be reduced and reconstructed (**Fig. 3E**). Alternatively, if contralateral radiographs are available, these can be mirrored, and the fracture can be reconstructed over them.

Fixation (**Video 2**)

Video 2

Fixation and equipment list. Online content including video sequences viewable at: https://s20.video-stream-hosting.de/tvg/ejournal/10.1055-s-00042410/10-1055-s-0040-1721833-rbo-20-00126-v2_360p.mp4.



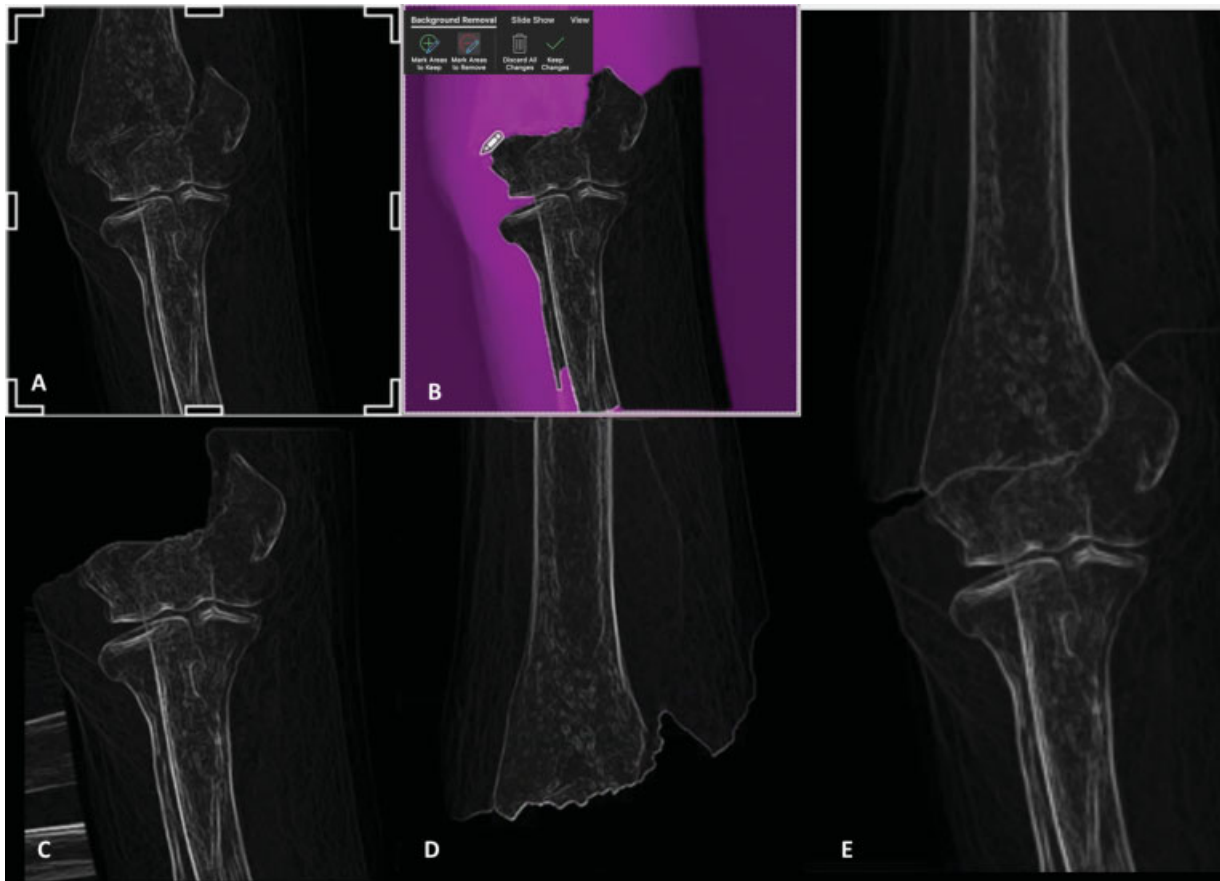

Fig. 3 An anteroposterior view of the fracture is cropped and pasted as a separate image (A). Using *Background Removal*, the distal (B, C) and proximal fragments (D) are delimited. Both images are fitted in together to reconstruct the fracture (E).

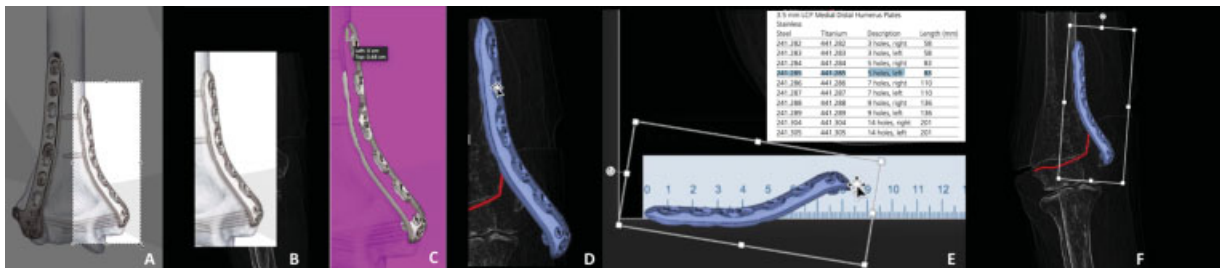


Fig. 4 A screenshot of the implant (medial distal humerus plate) from the operative technique is taken (A). The image is pasted onto a slide (B) and edited to have its background removed (C) and its color changed (D). The edited image is superimposed on the ruler to be accurately scaled, according to the implant's size chart (E). The final image is adjusted to fit the reconstructed fracture (F).

To design the fixation construct, the surgeon must have access to the implant surgical operative technique manual. Most can be downloaded in pdf format. These manuals contain both dimensions of the implants and pictures of them in various planes. These pictures are captured with screenshots (→Fig. 4A), pasted on a separate slide (→Fig. 4B), and modified to remove their background (*Picture Format > Remove Background*, →Fig. 4C). Following the OPP guidelines, the color of the implant can be changed to blue (*Picture Format > Color*, →Fig. 4D). For a more accurate prediction of the size, an image of a ruler is downloaded, and the implant is superimposed over the ruler until it matches its actual size (→Figs. 4E and 5C). Note that preoperative radiographs must be taken with a

radiologic marker to accurately scale the image. Finally, the implant image can be adjusted to fit the preoperative radiograph in *Format Picture > 3D rotation* (→Figs. 4F and 5). If many implants will be used, the **Transparency tool** (*Format Picture > Transparency*) enables the visualization of many implants in different layers (→Fig. 5D). Alternatively, fixation can be quickly schematized using the *Draw* tool.

Surgical Tactic (→Video 2)

Add slides describing how the proposed fixation is going to be achieved, the list of materials, tools and implants needed, and the postoperative plan given the proposed construct stability.

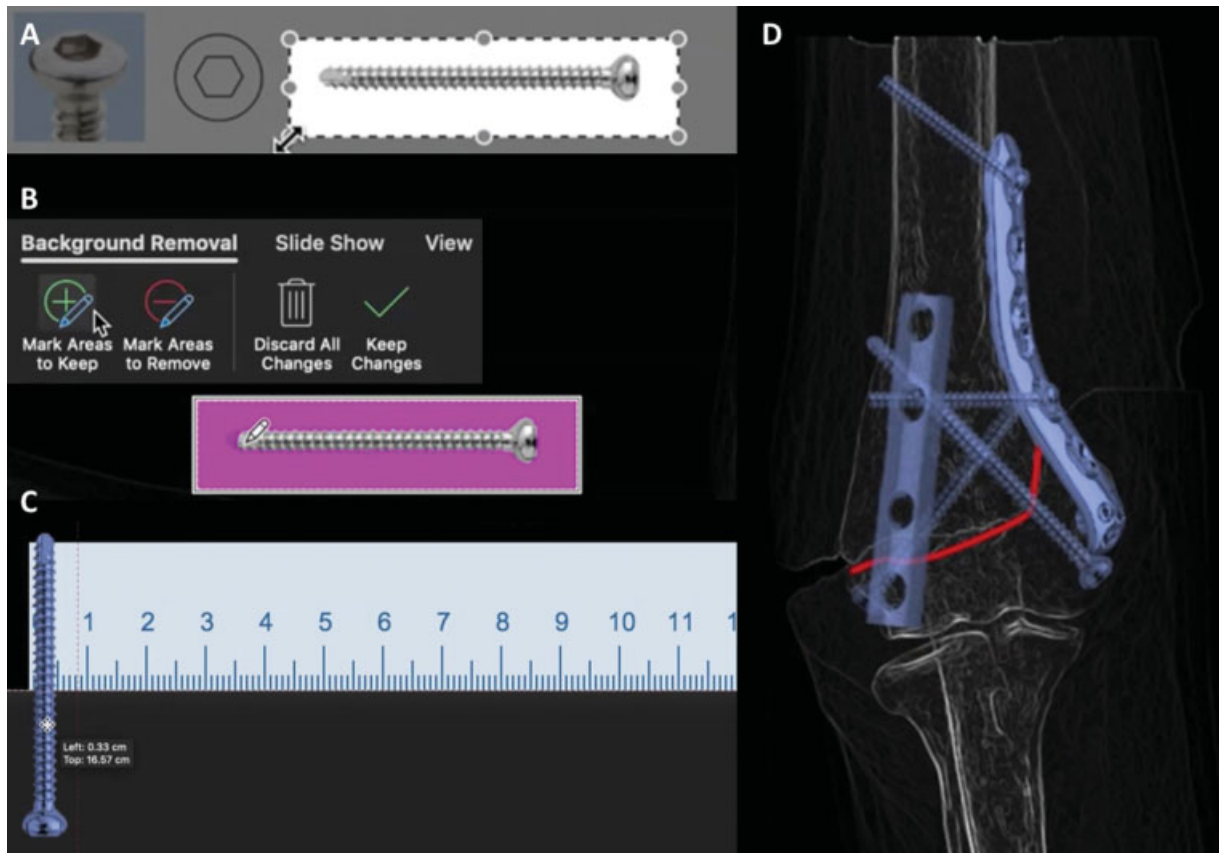


Fig. 5 Fixation stage of a 3.5-mm cortical screw in the preoperative planning with a presentation software. A screenshot from the surgical technique manual is cropped (A) and pasted on a slide to have its background removed (B). The color of the image is changed to blue and placed over a ruler to scale its diameter (C). The one-third tubular plate and the screws are shown over the reconstruction after applying the Transparency tool (D).

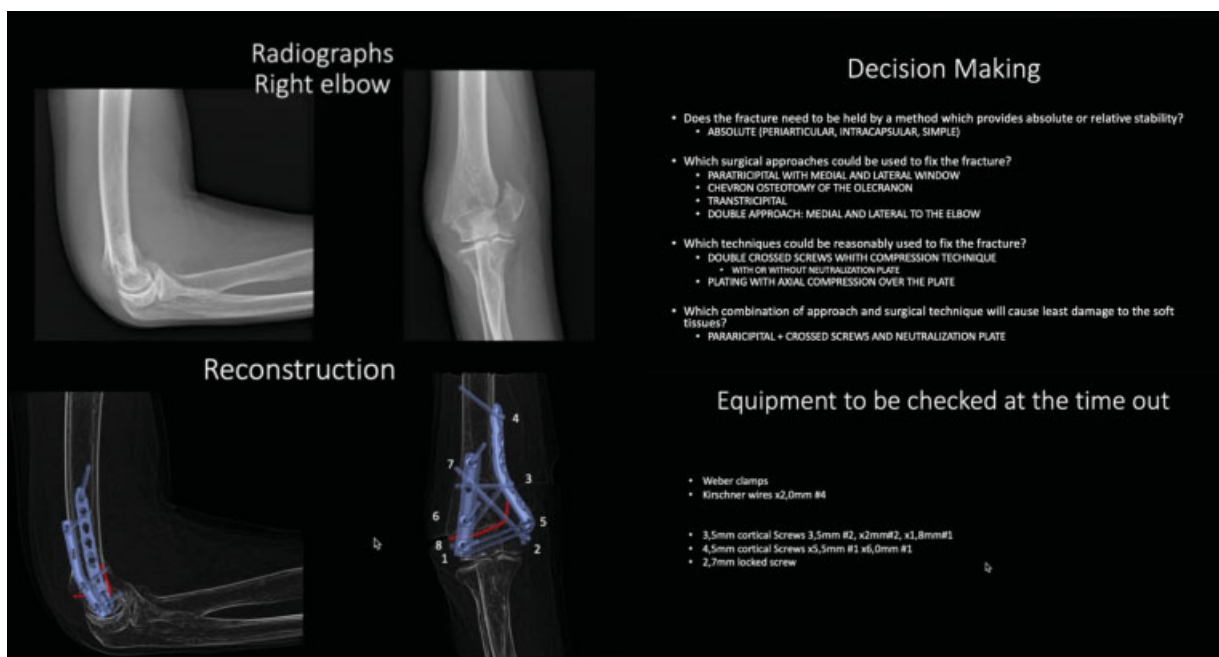


Fig. 6 Key slides from the final result of the PPPS.

The final product of the PPPS is a presentation containing the preoperative status, the desired postoperative reduction and reconstruction of the fracture, the fixation strategies, and a rehabilitation plan (► Fig. 6).

Discussion

Because the OPP was initially designed to be done on paper, it requires physical materials, such as radiographs, implant templates, tracing paper, and colored pens. These are cheap, and, in theory, are available throughout the world. However, most hospitals currently use PACS to store radiological imaging, so acetate radiographs are rarely available. In practice therefore, the OPP requires the surgeon to print the radiographs, which affects the accuracy of the PP. Printed templates are also often unavailable. All four authors of the present study had trouble finding these in different countries. The OPP also requires artistic skills and can be quite time consuming, especially when the surgeon needs to create many hand-drawn copies.

The PS is widely available in most hospitals and surgeons' own devices, being familiar to most orthopedic surgeons. The PPPS can be performed on nearly any device with a PS. The presentations can be kept online, making them easy to access and share. This is a significant advantage over the OPP. Furthermore, there is no image degradation when the surgeon experiments with the digital radiological images in the PS. The "duplicate slide" tool also eliminates the need to make many hand-drawn copies. We are aware, however, that the process of copying, pasting and cropping images can be quite repetitive. Nevertheless, we have found two important reasons for its use. Firstly, especially true when CT scans are available, the exercise of selecting the best cuts and capturing them enables ample image visualization, providing the surgeon with a good mental three-dimensional image of the fracture. Secondly, the process becomes "automatic" after a few attempts at the PPPS, and much faster as a result. In our experience, it takes 5 to 15 minutes to prepare a presentation, depending on the case. Most operating theaters now have a computer in which the PPPS can be displayed before the case starts. Staff can access and browse both the theater layout and equipment list, which saves time and improves team communication.

Specialized software (TraumaCad [Brainlab AG, Munich, Germany], PeekMed [PeekMed, Braga, Portugal] etc.) has also been developed for the PP. These are wonderful and accurate tools, but they are not as easily accessible and widely used as a simple PPPS. Based on the authors' experience, they are largely unavailable in Central and South America, Asia, Africa, and southern Europe. They also require in-hospital PACS integration and specialized hardware to function properly.

In our opinion, the main advantage of the PPPS is the educational opportunity it provides. It enables the surgeon to include pictures or videos of the patient's clinical assessment (such as, wounds, unusual physical examination findings etc.). Its format makes discussion with the colleagues easier. In addition, the PPPS goes beyond the PP. Once the case has ended, intraoperative fluoroscopy can also be added to the PPPS. The surgeon can identify pitfalls *a posteriori* by reviewing the case.

Old plans can also be useful when planning new cases with a similar injury. Finally, it is helpful for the follow-up of the patient in the clinic and for monitoring purposes (such as the status of the soft tissues). All of these features make the PPPS particularly useful for teaching and self-guided learning.

Reviewing the literature,^{1-3,7} we have found that there is a significant gap between the OPP and three-dimensional PP (3D-PP), which has established a new paradigm in PP, by enabling the surgeon to touch the fracture fragments, apply reduction techniques in advance, and preoperatively measure and fit implants. Although the 3D-PP is rapidly evolving,⁸ its availability and practical application are still restricted. It requires advanced imaging techniques (CT, MRI), so its applicability to diaphyseal fractures or simple articular fractures is limited. The environmental costs of producing a significant amount of thermoplastic fibers, the material used by 3D printers, should also be kept in mind. On the other hand, the PPPS can be used for every fracture with simple imaging, and could complement both PP using specialized software and 3D-PP.

Conclusion

To conclude, the PPPS enhances and updates known methods of PP. It is an inexpensive, straightforward, and widely accessible technique, providing the surgeon with a comprehensive summary case in a digital presentation, with an incalculable educational and documental value.

Disclosures

Alejandro Ordas-Bayon, David Cabrera, Karl Logan and Rodrigo Pesántez certify that they have no financial conflict of interests (such as consultancies, stock ownership, equity interest, patent/licensing arrangements etc.) in connection with the present article.

Conflict of Interests

The authors have no conflict of interests to declare.

References

- 1 Ruedi PT, Buckley ER, Moran GC. AO Principles of Fracture Management. Philadelphia: Thieme; 2007
- 2 Tornetta IP 3rd, Ricci WM, Ostrum RF, McQueen M. Rockwood and Green's Fractures in Adults. Philadelphia: Wolters Kluwer; 2019
- 3 Browner B, Jupiter J, Krettek C, Anderson P. Skeletal Trauma: Basic Science, Management and Reconstruction. Philadelphia: Elsevier; 2019
- 4 Graves ML. The value of preoperative planning. J Orthop Trauma 2013;27(10, Suppl 1):S30-S34
- 5 Hak DJ, Rose J, Stahel PF. Preoperative planning in orthopedic trauma: benefits and contemporary uses. Orthopedics 2010;33(08):581-584
- 6 Mast J, Ganz R, Jacob R. Planning and reduction technique in fracture surgery. Berlin: Springer-Verlag; 1989
- 7 Cabrera D, Bermúdez J. Planeamiento quirúrgico en fracturas de la mano y muñeca. In: Pinilla E, Naquira LF. Fracturas Del Radio Distal, Evaluación y Tratamiento. Bogotá: Asociación Colombiana de Cirugía; 2018
- 8 Chana-Rodríguez F, Mañanes RP, Rojo-Manaute J, Gil P, Martínez-Gómez JM, Vaquero-Martín J. 3D surgical printing and pre contoured plates for acetabular fractures. Injury 2016;47(11):2507-2511