

# Facial Transplantation: Complications, Outcomes, and Long-Term Management Strategies

Tom Shokri, MD<sup>1</sup> Robert Saadi, MD<sup>2</sup> Weitao Wang, MD<sup>1</sup> Likith Reddy, DDS, MD<sup>3</sup>  
Yadranko Ducic, MD, FRCS(C), FACS<sup>1</sup>

<sup>1</sup>Otolaryngology and Facial Plastic Surgery Associates, Fort Worth, Texas

<sup>2</sup>Department of Otolaryngology – Head & Neck Surgery, Penn State Health, Hershey, Pennsylvania

<sup>3</sup>Department of Oral and Maxillofacial Surgery, Texas A&M College of Dentistry, Dallas, Texas

Address for correspondence Yadranko Ducic, MD, FRCS(C), FACS, Otolaryngology and Facial Plastic Surgery Associates, 923 Pennsylvania Avenue, Suite 100, Fort Worth, TX 76104 (e-mail: yducic@sbcglobal.net).

Semin Plast Surg 2020;34:245–253.

## Abstract

Within the past two decades, vascularized facial composite allotransplantation has evolved into a viable option in the reconstructive surgeons' armamentarium for patients with extensive facial disfigurements. As it has expanded the frontiers of microsurgical reconstructive techniques, facial transplantation has come to garner widespread interest within both the medical community and the general public. The procedure has established itself as an amalgamation of the forefronts of reconstructive microsurgery, immunology, and transplantation science. Therein too lies its complexity as multifaceted scientific developments are met with ethical and social issues. Both patients and physicians are faced with the everlasting challenges of immunosuppression regimens and their inherent complications, long-term aesthetic and functional considerations, the role of revision procedures, and the inevitable psychosocial implications. This article reflects on the medical and surgical advancements in facial transplantation surgery and highlights anticipated future challenges. It aims to encourage discussion regarding anticipated barriers to current practice and suggest future directions as we transition into the next phase of facial allograft transplantation.

## Keywords

- ▶ facial transplantation
- ▶ composite tissue allotransplantation
- ▶ microvascular surgery
- ▶ immunosuppression
- ▶ ethics

Vascularized facial composite allotransplantation was initially described in the literature in 2002.<sup>1</sup> The procedure was first performed successfully in 2005, and early cases were met with considerable debate within the scientific community, general public, and media regarding the potential risks and benefits of the procedure.<sup>1–7</sup> Currently, there is a paucity of long-term data due to the rapid growth of the field, inherent delays in publication of results, compliance with patient privacy, and a potential reluctance to report suboptimal outcomes. To address this deficit, the International Registry on Hand and Composite Tissue Allotransplantation was formed to catalog data involving vascularized composite allotransplantation procedures, with the most recent published update in 2017. However, there

continues to be a lag in reporting up-to-date, evidence-based parameters, and, as such, long-term outcomes in facial transplantation are still lacking. The heterogeneity of the patient population and facial defects adds further complexity in delineating treatment guidelines. Furthermore, there is currently no centralized governing body monitoring facial transplantation programs. This resultant deficiency in statistical outcomes has impeded the reconstructive transplant community from consolidating data and subsequently developing standardized long-term management protocols. The purpose of this article is to review the primary literature regarding anticipated complications and long-term management within this continually evolving and transformative surgical field.

Issue Theme Complications and Secondary Management and Repair in Head, Neck and Plastic Surgery; Guest Editor: Yadranko Ducic, MD, FRCS(C), FACS

Copyright © 2020 by Thieme Medical Publishers, Inc., 333 Seventh Avenue, 18th Floor, New York, NY 10001, USA  
Tel: +1(212) 760-0888.

DOI <https://doi.org/10.1055/s-0040-1721760>  
ISSN 1535-2188.

## Functional Outcomes

In general, outcomes have been relatively favorable with regard to facial movement and function following facial transplantation in nearly all patients. This has been demonstrated in both observed and patient-reported measures of mastication, oral competence, smell, and facial expression.<sup>8-15</sup> Siemionow et al reported recovery of intelligible speech within 1 month of their first four patients.<sup>16</sup> Immediate improvement in deglutition, respiratory function, and sense of smell has been reported in an additional case series as well.<sup>17</sup> Notably, despite suboptimal facial nerve coaptation, recovery of speech articulation and deglutition to near pre-morbid conditions have been reported at 2 years following intervention.<sup>18</sup> Pomahac et al confirmed functional speech recovery at 3-year follow-up both clinically and with sequential electromyography of lip musculature. Although based on a single patient experience, their study suggests that axonal regeneration begins early following transplantation and correlates with the patient's functional improvement.<sup>19</sup> The utilization of interpositional nerve grafts, however, results in delayed restoration of function with delays occurring up to 1 year.<sup>9</sup> Preliminary studies suggest that the rate of sensory and motor recovery may be contingent on a patient's immunosuppressive regimen.<sup>16-18</sup> Currently, no formalized rehabilitation protocol has been established to facilitate functional recovery of allograft tissue. Speech therapy, facial mimetic exercises, and sensory reeducation have been described as early as 48 hours following surgery. Proponents of aggressive rehabilitation protocols postulate a role of cortical neuroplasticity in the integration of transplanted musculature into the recipient's motor cortex. Further studies are needed to develop standardized metrics for the objective documentation of functional outcomes in facial transplantation to allow for interstudy assessment and data aggregation. Defining outcomes is of paramount importance to refine medical regimens and surgical techniques. With this in mind, assimilation of transplanted functional tissue may be further subdivided into motor and sensory neurologic outcomes.

## Motor

Restoration of motor function is paramount in the overall success in facial transplantation. The capacity toward this function is contingent on facial nerve coaptation and has generally shown a trend toward delayed recovery in contrast to that of sensory reinnervation.<sup>6,7,9,10,16,17</sup> Motor recovery is reported within 6 to 8 months following surgery, with continual improvement for up to years.<sup>5</sup> Restoration of motor function is thought to be dependent on facial nerve coaptation, and the technique for performing coaptation has been the subject of considerable debate. While the majority of centers report performing intraoperative neuroorrhaphy, they report varying methodology. Proximal facial trunk coaptation has been advocated as a pragmatic approach for reducing overall operative time and achieving near-total return of facial movement.<sup>9</sup> However, initial studies have reported facial synkinesis, which may be attributable to this technique. These data have prompted other centers to attempt distal neuro-

orrhaphy, beyond the anterior border of the parotid gland. By decreasing distance to the facial mimetic musculature, it is thought that there may be an associated risk reduction for aberrant reinnervation and synkinesis.<sup>6,20</sup> Additionally, reinnervation of allograft facial muscles utilizing nerve grafts has also been described.<sup>9,18,21</sup>

There is significant difficulty in objective comparisons of outcomes due to a lack of standardization across studies. Following nerve coaptation, lip occlusion and articulation has been reported at 6 months,<sup>6</sup> with return of complete mouth closure and oral competence by 8 months.<sup>7</sup> Early motor recovery has been reported as early as 3 months with complete lip occlusion by 6 months and continued improvement following 1 year.<sup>6-10</sup> Cases in which neuroorrhaphy was not performed have resulted in poor motor function, with a lack of gradual improvement typically seen with coaptation techniques. Tongue transplantation without concomitant hypoglossal nerve coaptation, to preserve the patient's baseline tongue function, has shown recovery of food bolus formation, swallow, and speech production at 3 months.<sup>22</sup> In this context, end-to-side coaptation of the nerve may play a role in further accelerating motor recovery within the donor tissues. Further standardized, aggregate, multi-institutional studies are needed to elucidate the optimal technique for the management of motor nerves with respect to functional outcomes. These studies should additionally explore the role of both physical and occupational therapy in augmenting functional recovery.

## Sensory

Restoration of pre-morbid facial sensation was not previously thought to be feasible following initial face transplantation.<sup>11</sup> However, expectations have since become realigned with clinical experience. Over the following decade, the rapid restoration of facial sensory feedback was consistently observed in patients undergoing transplantation.<sup>11,17</sup> Mechanical and thermal sensations have been documented as early as 3 months postoperatively, with near-complete sensory restoration at 8 months.<sup>7</sup> Optimal recovery has been previously defined as a resolution of thermal sensory function, discriminatory capacity of light touch, two-point touch, and detection of noxious painful stimuli.<sup>6,7,10,11,16</sup>

Technical aspects, with respect to repair of sensory nerves, differ markedly across institutions. Reconstitution of sensory function has been documented independent of technique. Pomahac et al advocated for neuroorrhaphy of all major sensory nerves after one recipient experienced facial anesthesia 4 months following repair. Notably, this patient experienced persistent anesthesia on the side that did not undergo neuroorrhaphy, whereas the contralateral side, which had successfully undergone nerve repair, experienced sensory recovery.<sup>10</sup> Dorafshar et al and Dubernard et al have reported end-to-end mental and infraorbital neuroorrhaphy resulting in thermal sensation recovery at 2 weeks with detection of thermal and proprioceptive stimuli 14 weeks postoperatively.<sup>6,23</sup> Alternatively, simple placement of bilateral donor mental nerves in close proximity to recipient mental foramina without neuroorrhaphy has resulted in a resolution of sensory function by

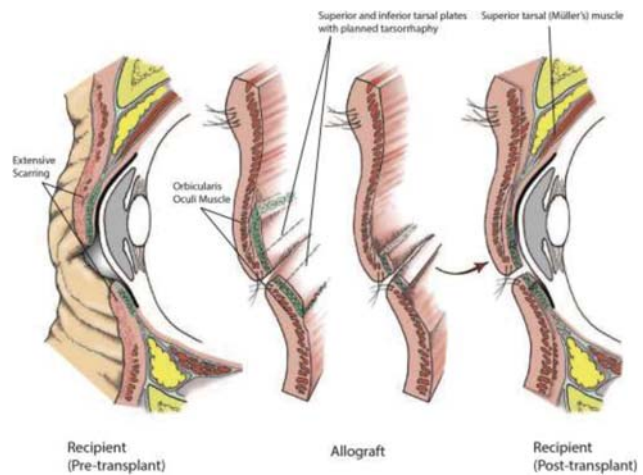
3 months.<sup>7</sup> Sensory restoration has been similarly documented without repair of the trigeminal nerve by 6 months. Therefore, sensory recovery may be obtained irrespective of neurotaphy in contradistinction to the previously discussed data on motor nerve repair.

Several mechanisms have been proposed for sensory restoration without operative nerve repair. Human facial anatomy is distinct in that there is a high density of sensory nerves within this region. The facial region has more than 17,000 sensory corpuscles. This is likely to be a contributory factor in optimal sensory results as the majority of these neural components are likely retained within the maxillofacial region.<sup>24-27</sup> There are additional implications with respect to immunosuppression regimen, particularly with tacrolimus, and sensory function. Data from extremity transplantation literature suggest a dose-dependent relationship between tacrolimus and axonal regeneration rates.<sup>28</sup> Tacrolimus has been shown to reduce neural recovery times and regeneration by 50% and results in a corresponding increase of myelinated axons by 40%. Furthermore, tacrolimus has been shown to increase axonal density and myelin thickness.<sup>29-32</sup> This may represent a potential benefit in chronic immunosuppression therapy despite this agent's associated neurotoxicity.

### Ocular Considerations

Unique consideration should be given to periocular management in face transplant recipients. Injuries to structures including the globe, eyelids, orbit, and ocular adnexa increase susceptibility within this patient population to potential lid deformity, corneal pathology, conjunctival fibrosis, and resultant visual impairment.<sup>22,33</sup> It is therefore imperative that facial transplant surgeons address periorbital form and function. Additionally, transplant teams must be cognizant of potential complications and include ophthalmology in multidisciplinary postoperative care planning. More than 40 patients have thus far undergone face transplantation, of whom approximately 54% have received allograft periorbital components.<sup>22,33-36</sup> However, the majority of these studies tend to underreport ocular outcomes, and a comprehensive consideration of periocular and ocular considerations is lacking. Only 64% of studies to date have reported ocular outcomes.<sup>20-24,37-40</sup> Proper positioning of the eyelid and periorbital is of utmost importance with respect to functional considerations such as tear production. Corneal complications such as exposure keratopathy can result secondary to undiagnosed ectropion or lagophthalmos. Aycart et al evaluated secondary revision following facial transplantation and described tarsorrhaphy as the primary treatment in patients with evidence of exposure keratopathy, with one patient undergoing bilateral V-Y medial canthus advancement secondary to malpositioning of the medial canthi.<sup>40</sup>

Complex periorbital defects pose significant challenges to the reconstructive surgeon, particularly in patients with intact visual acuity (→ Fig. 1). Optimization of outcomes is contingent on meticulous eyelid-globe apposition, appropriate canthal positioning, and functional lacrimal apparatus. Vascularized composite allotransplantation of facial



**Fig. 1** Left: recipient eyelid tissue prior to face transplantation. Middle: eyelid in procured facial allograft with subsequent tarsorrhaphy of the superior and inferior tarsal plates. Right: allograft following inset to recipient. (Reproduced with permission of Grigos et al.<sup>42</sup>)

tissue represents an important tool when autologous reconstructive options have been exhausted. However, the extent of revision procedures addressing horizontal lid laxity, ectropion, dermatochalasis, ptosis, and brow and forehead positioning, with their associated functional and aesthetic implications, suggests that periorbital management is unexplored during initial intervention.<sup>39,40</sup> Greenfield et al report successful management of periorbital injuries in two face transplant recipients. They advocate for the following reconstructive tenets that are critical in the management of the periocular region: preservation of recipient medial canthal attachments, avoidance of high lateral canthal fixation, preservation of tissue redundancy within the donor allograft eyelid, and preservation of zygomatic and buccal facial nerve branches with prioritization of reestablishment of periorbital sensory function when possible.<sup>41</sup> Periocular management in facial transplantation remains a nascent field of study with high rates of periorbital revision following transplantation. Oculoplastic surgeons and ophthalmologists are therefore critical components of the facial transplant multidisciplinary team and continued, outcomes-based research is necessary to optimize techniques in management of the eye and surrounding tissue during transplantation.<sup>36-40</sup>

### Osseous Considerations and Dental Occlusion

Although the first facial transplant contained only soft tissue, reconstruction of the underlying osseous framework in addition to soft tissue augmentation was quickly found to be a critical component in facial transplantation. Appropriate mandibular occlusion in particular is critical in the restoration of both form and function. To perform truly recipient-specific reconstruction, subsequent procedures have included varying degrees of the maxilla, mandible, orbital floor/rim, and zygoma.<sup>9</sup> In fact, of more than 45 facial transplantations performed to date, 25 have been reported to contain bone. Of these cases, 19 included maxilla, 16

mandible, 9 zygoma, and 5 with orbital components. Of those patients with osseous reconstruction, all exhibited at least one dental/occlusal complication: temporomandibular joint ankylosis (9/25; 36%), carious odontogenic disease and dental extraction (32%), palatal fistula (28%), Angle II malocclusion (24%), Angle III (12%), open bite (20%), maxillary malrotation (8%), skeletal nonunion (8%), and infected hardware (4%). Of the patients, 28% required revision surgeries involving Le Fort I, III, or mandibular osteotomies.<sup>18,41-43</sup>

Reconstitution of cephalometric relationships between the donor craniomaxillofacial skeleton and the recipient's skull base has emerged as an evolving field of active research.<sup>44</sup> With the increased utilization of virtual surgical planning (VSP) techniques, transplantation with confirmation of accurate cephalometric proportions and functional occlusion has become increasingly feasible.<sup>21,45</sup> The incorporation of this technology into surgical planning has greatly improved postoperative outcomes and likely decreased the necessity for revision surgery, although data exploring this are not readily available. However, despite more predictable cephalometric planning, certain limitations continue to exist including limited capacity to account for functional movement secondary to masticatory muscles or the tongue. Despite these limitations, the appropriate inclusion of vascularized bone in composite reconstructions is of utmost importance in reestablishing maxillofacial contour and reconstituting the facial suspensory ligaments to mitigate potential soft tissue ptosis.<sup>46</sup>

As mentioned, dental occlusion is particularly dependent on appropriate bony implantation. Of face transplants that have included maxilla or mandibular components, only eight have thus far incorporated the entirety of the maxilla and mandible. When these structures are not transplanted in their entirety, hybrid occlusion (consisting of structures from recipient and donor) must be created with anatomical precision to promote functionality.<sup>13,47-49</sup> Hybrid occlusion is associated with considerable functional limitation and can only partially refabricate the functional characteristics of mastication or speech. Dental contouring has been attempted with only minor improvement in this regard.<sup>50,51</sup> Concomitant transplantation of both tooth-bearing maxillary and mandibular segments has therefore been advocated, if feasible, despite added complexity and procedural duration. Regardless of advances in bimaxillary transplantation and VSP, preorbital occlusion has been difficult to obtain in transplantation surgery. These long-term limitations have been attributed to spatial relations between the mandibular condyle and fossa during general anesthesia as opposed to functional considerations during conscious mobilization of the mandible with masticatory activity. Evolving technological refinements in computer-assisted design, virtual modeling, intraoperative navigation, and prefabricated cutting guides may soon address these shortcomings. Orthognathic and dental complications remain common, although underreported, following facial allotransplantation. The role of early orthodontic interventions or skeletal revisions continues to be unclear, and future prospective studies are needed to help elucidate measures in preventing suboptimal occlusion.<sup>52</sup>

## Immunological Considerations

Immunosuppressive regimens have been reappropriated from solid organ transplantation protocols. Induction of immunosuppression consists of antithymocyte globulin, a T cell depleting agent.<sup>53</sup> Additional induction agents include as humanized interleukin-2 receptor antibody,<sup>18,54</sup> alemtuzumab,<sup>21</sup> and rituximab.<sup>46</sup> Posttransplantation maintenance regimens typically consist of triple therapy in the form of tacrolimus, mycophenolic acid, and prednisone taper.<sup>12,53,55</sup> Despite general uniformity in maintenance protocols, variability exists in dosing and scheduling.

Thus far, all transplant recipients have experienced an acute rejection episode within the first year following surgery. The majority of these episodes are successfully treated with pulse dose corticosteroids, with or without increased dosage of maintenance immunomodulators.<sup>22</sup> Complications due to long-term immunosuppression have been well documented and include metabolic complications, renal toxicity, opportunistic infections, and increased rates of malignancy.<sup>56</sup> Efforts have therefore been made to minimize maintenance therapies such as dual therapy with tacrolimus and corticosteroids<sup>9</sup> or mycophenolic acid.<sup>22,46,57,58</sup> Immunomodulation regimens employing tacrolimus monotherapy and donor bone marrow transplantation have shown promise within the extremity transplantation literature but have yet to be investigated.<sup>59</sup> To mitigate the risk of renal toxicity and resultant end-stage renal disease, alternative immunosuppressive nonnephrotoxic T-cell inhibitors, such as sirolimus or belatacept, have been incorporated.<sup>60,61</sup> Several reports also document the development of posttransplantation diabetes, hypertension, and hyperlipidemia secondary to maintenance immunosuppression. However, these side effects have generally been managed successfully with medication and preventive measures.<sup>57</sup>

Infectious complications due to chronic immunosuppression are unfortunately common. To date, published data document infections in at least 15 recipients (15/45 [33%]), with 6 undergoing recurrent infections.<sup>62</sup> Of those infected, three (20%) were with HSV (herpes simplex virus), five (33%) with CMV (cytomegalovirus), four (27%) with pneumonia (two pseudomonas, two polymicrobial), two with candida, one with staph aureus, one with aspergilloma, one with molluscum contagiosum, and one with polymicrobial bacteremia.<sup>62</sup> With this in mind, adequate antibiotic and antiviral prophylaxis is recommended in all patients planned to undergo allotransplantation followed by consultation regularly by transplant infectious disease specialists.

Malignancy-related death has also been reported in transplant recipients. Due to chronic immunosuppression, a prior history of malignancy is considered a relative contraindication to facial transplantation. Active malignancy is an absolute contraindication. However, length of postmalignancy remission prior to consideration for transplantation is as of yet undetermined. This is not unexpected as one can assume that the risk of de novo malignancy in solid organ transplantation may be applied to facial recipients as well. Maintenance immunosuppression may be deescalated following the

diagnosis of malignancy in a recipient. However, the necessary addition of chemotherapeutic agents further compromises the recipient's immune system, resulting in further oncological spread and likely infection.

While chronically immunosuppressed transplant patients are particularly susceptible to lymphoma and cutaneous malignancies, posttransplant lymphoproliferative disorders occur in 1 to 16% of solid organ transplant patients with likely corollary findings in vascularized composite facial allotransplantation.<sup>63–65</sup> As long-term data in facial transplantation continue to accumulate, malignancy potential, treatment resistance, and remission rates will aid in determining whether tumor biology is similar to that seen in solid organ transplants. These findings will undoubtedly have implications for patient selection.

### Cutaneous Manifestations of Chronic Rejection and Volume Loss

Due in part to the rarity with which these procedures are performed, long-term outcomes with respect to chronic rejection are rarely reported within the literature. Further complicating matters, a distinct definition of chronic rejection has not been delineated in facial allotransplantation. In solid organ transplantation, chronic rejection is thought to be secondary to allograft vasculopathy.<sup>66–69</sup> Parallels have been drawn to this within the facial transplantation literature. However, recent studies indicate an alternative mechanism toward chronic rejection in this patient population. Krezdorn et al performed surveillance skin biopsy of seven patients who received face transplants during an 8-year interval. They noted histopathological findings consistent with chronic rejection including epidermal thinning, foci of lymphocyte-mediated cytotoxicity, vascular ectasia, and sclerosis without evidence of intimal hyperplasia or vessel narrowing.<sup>69</sup> These changes manifested clinically as premature cutaneous aging (► Fig. 2). These clinicopathological changes were similar to those found in autoimmune cutaneous disorders. Further research may identify new preventive therapies for chronic immune-mediated changes and early identification of potential chronic rejection and transplant failure.

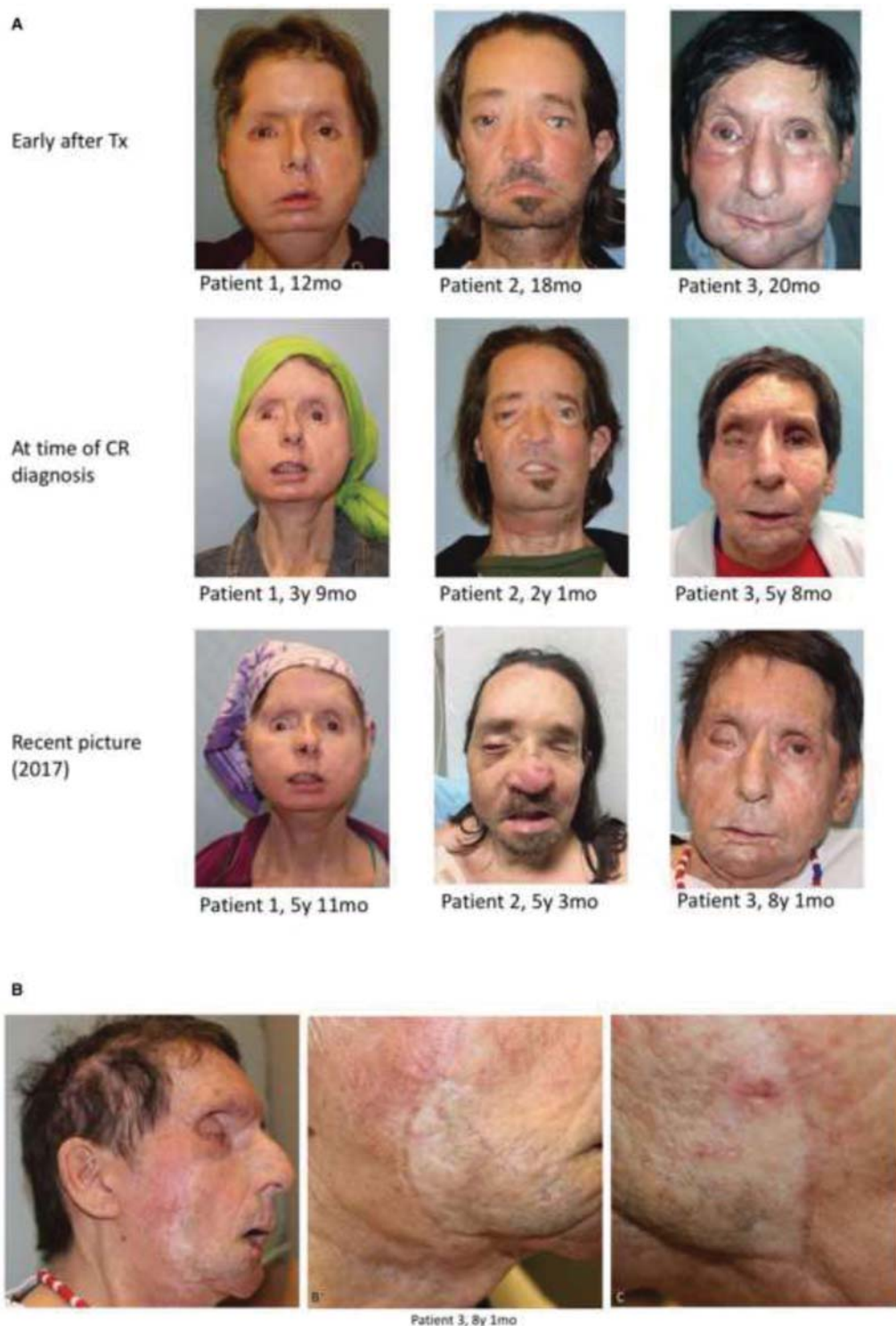Volumetric changes have been noted to resemble accelerated aging in facial transplantation patients as well. Kueckelhaus et al reviewed morphologic changes secondary to volume loss in three such patients over 40 months. Data obtained from computed tomography (CT) at standardized time intervals, and soft tissue biopsies of muscle and fat were analyzed as well. Their data indicated that all patients lost on average 30% soft tissue volume between 6 to 36 months. Bone and “nonfat soft tissue” volumes were shown to decrease more rapidly than fat. Concurrent muscle biopsies confirmed significant muscle atrophy.<sup>67</sup> These findings were unique in that they deferred from the normal aging process due to disproportionate volumetric decrease attributable to connective tissue loss, bone, and muscular atrophy. More robust studies are needed to determine whether these findings are uniform finding in facial transplantation and to delineate measures that may mitigate substantial volumetric changes.

### Ethical Implications

Previously, ethical issues surrounding facial transplantation largely mirrored those of solid tissue transplant regarding mainly informed consent.<sup>68</sup> The procedure remains experimental, and appreciable risks of opportunistic infections, posttransplant lymphoproliferative disease, graft versus host disease, host rejection of graft, and mortality have always raised the question of risk versus benefit.<sup>69–71</sup> However, as the number of facial transplants performed has increased, so has publicity on the subject, raising more nuanced ethical considerations.<sup>71</sup>

Categorizing ethical concerns with traditional ethical principles can aid in conceptualizing the complex subject matter.<sup>70</sup> In addition to the process of informed consent, patient autonomy may be undercut by the relatively high risk of coercion for a procedure with the promise of financial rewards and self-promotion to both the institution/surgical team and the patient.<sup>68,70</sup> Beneficence and nonmaleficence in this case extend beyond the possible risks of the surgery and benefits of functional and cosmetic outcomes but include the psychological implications of accepting a new face and the extended risk to confidentiality and anonymity with media requests and coverage.<sup>70</sup> Furthermore, graft loss in this scenario may place the patient at a significantly worse outcome than preoperatively due to the need to remove native tissue for placement of the vascularized composite allograft.<sup>69,72</sup> Preservation of dignity and value extend both to the patient, who will endure effects regarding self-esteem and peer relationships, and to the donor's family, who will require preparation for seeing media-reported postoperative images and will need to make open-versus closed-casket funeral considerations. Finally, distribution of this service must maintain equitable access in deliverance of a significantly limited resource to those with the best odds of graft acceptance and overall survival, as the number of patients worldwide with significant facial disfigurement far exceeds the availability of resources to perform this high-cost procedure.<sup>70,71</sup>

Given the limited supply, there are further social and cultural considerations regarding the appropriateness of age, ethnicity, or sex mismatch between the donor and recipient. The preprocedural morbidity of facial disfigurement generally outweighs the quality of the match from the donor to the host, but it can be difficult to sufficiently prepare a patient for this possibility.<sup>73</sup> It is particularly easy for a patient with significant facial deformity to form unrealistic expectations regarding a full facial transplant.<sup>69</sup> Approaching the topic too soon in the treatment of the patient may prevent patients from consideration of other reasonable alternatives. Conversely, exposure of patients to many more procedures prior to facial transplantation may compromise the ability to perform this procedure or the ability to perform a rescue procedure in the event of graft failure. Further controversy surrounds the option of performing the procedure on a patient in childhood given the uniquely vulnerable state of a child to the psychological and social ramifications.<sup>74,75</sup> A survey of ethicists ( $n = 401$ ) demonstrated that a majority (84%) agreed that facial transplantation on an adult without



**Fig. 2** (A) Progression of face vascularized composite allografts for up to an 8-year interval showing changes associated with chronic rejection. (B) White patches on allograft with permanent telangiectasias in one of the face vascularized composite allograft recipients: physical manifestations of chronic rejection. (Reproduced with permission of Krezdorn et al.<sup>69</sup>)

medical contraindications was permissible. A majority of respondents also found facial transplant on a child or blind patient to be permissible (roughly 60%); however, somewhat less respondents were supportive of age, sex, and ethnicity mismatches. Sex mismatch (45%) and significant age mismatch (12% for 45-year mismatch) were the least supported.<sup>76</sup>

### Psychosocial Factors

Psychiatric and social considerations are integral both preoperatively and following surgery. Patients with severe facial disfigurement have a high likelihood of having some degree of psychiatric disturbance and tend to exhibit social avoidance and isolation.<sup>77,78</sup> As such, these patients should be vetted for

conditions including generalized anxiety, depression, post-traumatic stress disorder, and even chronic opioid dependence following numerous attempts at prior reconstruction.<sup>71,72</sup> Multidisciplinary assessment including a psychiatrist and social worker should be performed in any patient seeking candidacy for facial transplantation to understand any and all baseline mental illnesses present. Psychiatric conditions may significantly interfere with the necessary long-term follow-up and immunosuppression with which patients will be required to be actively involved.<sup>78,79</sup>

Psychosocial state at both the time of injury (including the cause of injury) and the time of screening is particularly important for patients with a previous suicide attempt to demonstrate their eligibility.<sup>80</sup> Active severe psychiatric disturbances including psychosis, untreated depression, dementia, traumatic brain injury, substance abuse, and suicide attempt within 1 year should serve as contraindications to the procedure.<sup>70</sup> Screening with a psychological grading scale such as the Stanford Integrated Psychosocial Assessment for Transplantation Instrument (SIPAT) has been shown to have prognostic value regarding outcomes.<sup>81</sup>

It is important to demonstrate improved postoperative quality of life and psychosocial benefits given that facial transplantation is not a life-saving procedure. Overall, benefits in quality of life have been noted across studies.<sup>82,83</sup> Modest improvements in self-esteem and mental health related quality of life have been found even in patients with relatively high perceived health status preoperatively. However, there does appear to be a consistent decline in quality of life up to 3 months postoperatively, which may represent a particularly challenging timeframe for patients.<sup>84–86</sup>

## Conclusion

Facial transplantation represents possibly the ultimate adherence to one of the earliest dictums in reconstructive surgery, put forth by Sir Harold Gillies: “losses must be replaced in kind—bone for bone, cartilage for cartilage, and skin for skin.”<sup>87</sup> Although still in its infancy, this procedure has been shown to improve both functional and aesthetic outcomes in patients with large composite defects that cannot be addressed sufficiently with autologous reconstructive methods. Stringent standardized outcomes measures, multi-institutional collaboration, and multidisciplinary efforts are needed to establish facial allotransplantation as a first-line reconstructive option. As new milestones are met, new challenges will inevitably arise, and outcome-driven data are needed to optimize technique and long-term management.

### Disclosures

The authors have no disclosures.

### Conflict of Interest

None declared.

## References

- Hettiaratchy S, Butler PE. Face transplantation—fantasy or the future? *Lancet* 2002;360(9326):5–6
- Morris PJ, Bradley JA, Doyal L, et al. Facial transplantation: a working party report from the Royal College of Surgeons of England. *Transplantation* 2004;77(03):330–338
- Siemionow M, Ozmen S, Demir Y. Prospects for facial allograft transplantation in humans. *Plast Reconstr Surg* 2004;113(05):1421–1428
- Wiggins OP, Barker JH, Martinez S, et al. On the ethics of facial transplantation research. *Am J Bioeth* 2004;4(03):1–12
- Shanmugarajah K, Hettiaratchy S, Butler PE. Facial transplantation. *Curr Opin Otolaryngol Head Neck Surg* 2012;20(04):291–297
- Dubernard JM, Lengelé B, Morelon E, et al. Outcomes 18 months after the first human partial face transplantation. *N Engl J Med* 2007;357(24):2451–2460
- Lantieri L, Meningaud JP, Grimbert P, et al. Repair of the lower and middle parts of the face by composite tissue allotransplantation in a patient with massive plexiform neurofibroma: a 1-year follow-up study. *Lancet* 2008;372(9639):639–645
- Siemionow M, Ozturk C. An update on facial transplantation cases performed between 2005 and 2010. *Plast Reconstr Surg* 2011;128(06):707e–720e
- Siemionow MZ, Papay F, Djohan R, et al. First U.S. near-total human face transplantation: a paradigm shift for massive complex injuries. *Plast Reconstr Surg* 2010;125(01):111–122
- Pomahac B, Pribaz J, Eriksson E, et al. Three patients with full facial transplantation. *N Engl J Med* 2012;366(08):715–722
- Shanmugarajah K, Hettiaratchy S, Clarke A, Butler PE. Clinical outcomes of facial transplantation: a review. *Int J Surg* 2011;9(08):600–607
- Siemionow M, Ozturk C. Face transplantation: outcomes, concerns, controversies, and future directions. *J Craniofac Surg* 2012;23(01):254–259
- Sosin M, Ceradini DJ, Levine JP, et al. Total face, eyelids, ears, scalp, and skeletal subunit transplant: a reconstructive solution for the full face and total scalp burn. *Plast Reconstr Surg* 2016;138(01):205–219
- Tasiogiorgos S, Kollar B, Krezdorn N, Bueno EM, Tullius SG, Pomahac B. Face transplantation—current status and future developments. *Transpl Int* 2018;31(07):677–688
- Fischer S, Kueckelhaus M, Pauzenberger R, Bueno EM, Pomahac B. Functional outcomes of face transplantation. *Am J Transplant* 2015;15(01):220–233
- Siemionow M. The decade of face transplant outcomes. *J Mater Sci Mater Med* 2017;28(05):64
- Giatsidis G, Sinha I, Pomahac B. Reflections on a decade of face transplantation. *Ann Surg* 2017;265(04):841–846
- Lantieri L, Hivelin M, Audard V, et al. Feasibility, reproducibility, risks and benefits of face transplantation: a prospective study of outcomes. *Am J Transplant* 2011;11(02):367–378
- Pomahac B, Pribaz J, Eriksson E, et al. Restoration of facial form and function after severe disfigurement from burn injury by a composite facial allograft. *Am J Transplant* 2011;11(02):386–393
- Guo S, Han Y, Zhang X, et al. Human facial allotransplantation: a 2-year follow-up study. *Lancet* 2008;372(9639):631–638
- Barret JP, Gavalda J, Bueno J, et al. Full face transplant: the first case report. *Ann Surg* 2011;254(02):252–256
- Pomahac B, Pribaz JJ, Bueno EM, et al. Novel surgical technique for full face transplantation. *Plast Reconstr Surg* 2012;130(03):549–555
- Dorafshar AH, Bojovic B, Christy MR, et al. Total face, double jaw, and tongue transplantation: an evolutionary concept. *Plast Reconstr Surg* 2013;131(02):241–251
- Khalifian S, Brazio PS, Mohan R, et al. Facial transplantation: the first 9 years. *Lancet* 2014;384(9960):2153–2163
- Devauchelle B, Badet L, Lengelé B, et al. First human face allograft: early report. *Lancet* 2006;368(9531):203–209
- Nordin M, Hagbarth KE. Mechanoreceptive units in the human infra-orbital nerve. *Acta Physiol Scand* 1989;135(02):149–161

- 27 Hwang K, Hwang JH, Cho HJ, Kim DJ, Chung IH. Horizontal branch of the supraorbital nerve and temporal branch of the facial nerve. *J Craniofac Surg* 2005;16(04):647–649, discussion 650
- 28 Shankland WE II. The trigeminal nerve. Part III: the maxillary division. *Cranio* 2001;19(02):78–83
- 29 Siemionow M, Gharb BB, Rampazzo A. The face as a sensory organ. *Plast Reconstr Surg* 2011;127(02):652–662
- 30 Canan S, Asim OM, Okan B, Ozek C, Alper M. Anatomic variations of the infraorbital foramen. *Ann Plast Surg* 1999;43(06):613–617
- 31 Aziz SR, Marchena JM, Puran A. Anatomic characteristics of the infraorbital foramen: a cadaver study. *J Oral Maxillofac Surg* 2000;58(09):992–996
- 32 Hu KS, Kwak HH, Song WC, et al. Branching patterns of the infraorbital nerve and topography within the infraorbital space. *J Craniofac Surg* 2006;17(06):1111–1115
- 33 Hwang K, Nam YS, Choi HG, Han SH, Hwang SH. Cutaneous innervation of lower eyelid. *J Craniofac Surg* 2008;19(06):1675–1677
- 34 Singhal D, Pribaz JJ, Pomahac B. The Brigham and Women's Hospital face transplant program: a look back. *Plast Reconstr Surg* 2012;129(01):81e–88e
- 35 Rifkin WJ, David JA, Plana NM, et al. Achievements and challenges in facial transplantation. *Ann Surg* 2018;268(02):260–270
- 36 Kirkey S. Canada's First Face Transplant. Accessed July 8, 2020 at: <https://nationalpost.com/feature/canadas-first-face-transplant>
- 37 Gordon CR, Siemionow M, Papay F, et al. The world's experience with facial transplantation: what have we learned thus far? *Ann Plast Surg* 2009;63(05):572–578
- 38 Sosin M, Munding GS, Dorafshar AH, et al. Eyelid transplantation: lessons from a total face transplant and the importance of blink. *Plast Reconstr Surg* 2015;135(01):167e–175e
- 39 Ozkan O, Ozkan O, Ubur M, Hadimioglu N, Cengiz M, Afsar I. Face allotransplantation for various types of facial disfigurements: a series of five cases. *Microsurgery* 2018;38(08):834–843
- 40 Aycart MA, Alhefzi M, Kueckelhaus M, et al. A retrospective analysis of secondary revisions after face transplantation: assessment of outcomes, safety, and feasibility. *Plast Reconstr Surg* 2016;138(04):690e–701e
- 41 Greenfield JA, Kantar RS, Rifkin WJ, et al. Ocular considerations in face transplantation: report of 2 cases and review of the literature. *Ophthal Plast Reconstr Surg* 2019;35(03):218–226
- 42 Grigos MI, LeBlanc É, Rifkin WJ, et al. Total eyelid transplantation in a face transplant: analysis of postoperative periorbital function. *J Surg Res* 2020;245:420–425
- 43 Sosin M, Rodriguez ED. The face transplantation update: 2016. *Plast Reconstr Surg* 2016;137(06):1841–1850
- 44 Woman Receives Total Face Transplant at Cleveland Clinic. Available at: <https://health.clevelandclinic.org/woman-receives-total-face-transplant-at-cleveland-clinic/>. Accessed July 9, 2020
- 45 Lassus P, Lindford A, Vuola J, et al. The Helsinki face transplantation: surgical aspects and 1-year outcome. *J Plast Reconstr Aesthet Surg* 2018;71(02):132–139
- 46 Caterson EJ, Diaz-Siso JR, Shetye P, et al. Craniofacial principles in face transplantation. *J Craniofac Surg* 2012;23(05):1234–1238
- 47 Dorafshar AH, Brazio PS, Munding GS, Mohan R, Brown EN, Rodriguez ED. Found in space: computer-assisted orthognathic alignment of a total face allograft in six degrees of freedom. *J Oral Maxillofac Surg* 2014;72(09):1788–1800
- 48 Gordon CR, Susarla SM, Peacock ZS, Kaban LB, Yaremchuk MJ. Le Fort-based maxillofacial transplantation: current state of the art and a refined technique using orthognathic applications. *J Craniofac Surg* 2012;23(01):81–87
- 49 Gordon CR, Susarla SM, Peacock ZS, et al. Osteocutaneous maxillofacial allotransplantation: lessons learned from a novel cadaver study applying orthognathic principles and practice. *Plast Reconstr Surg* 2011;128(05):465e–479e
- 50 Blondeel P. Facial transplantation—the Gent, Belgium clinical experience. Presented at the State of the Art: Facial Reconstruction & Transplantation, Baltimore, MD, May 17–19, 2013
- 51 Jacobs JMS, Dec W, Levine JP, et al. Best face forward: virtual modeling and custom device fabrication to optimize craniofacial vascularized composite allotransplantation. *Plast Reconstr Surg* 2013;131(01):64–70
- 52 Wall A, Bueno E, Pomahac B, Treister N. Intraoral features and considerations in face transplantation. *Oral Dis* 2016;22(02):93–103
- 53 Ramly EP, Kantar RS, Diaz-Siso JR, Alfonso AR, Shetye PR, Rodriguez ED. Outcomes after tooth-bearing maxillomandibular facial transplantation: insights and lessons learned. *J Oral Maxillofac Surg* 2019;77(10):2085–2103
- 54 Brown EN, Dorafshar AH, Bojovic B, et al. Total face, double jaw, and tongue transplant simulation: a cadaveric study using computer-assisted techniques. *Plast Reconstr Surg* 2012;130(04):815–823
- 55 Fischer S, Lian CG, Kueckelhaus M, et al. Acute rejection in vascularized composite allotransplantation. *Curr Opin Organ Transplant* 2014;19(06):531–544
- 56 Cavadas PC, Ibáñez J, Thione A. Surgical aspects of a lower face, mandible, and tongue allotransplantation. *J Reconstr Microsurg* 2012;28(01):43–47
- 57 Madani H, Hettiaratchy S, Clarke A, Butler PEM. Immunosuppression in an emerging field of plastic reconstructive surgery: composite tissue allotransplantation. *J Plast Reconstr Aesthet Surg* 2008;61(03):245–249
- 58 Diaz-Siso JR, Bueno EM, Sisk GC, Marty FM, Pomahac B, Tullius SG. Vascularized composite tissue allotransplantation—state of the art. *Clin Transplant* 2013;27(03):330–337
- 59 Lantieri L, Grimbert P, Ortonne N, et al. Face transplant: long-term follow-up and results of a prospective open study. *Lancet* 2016;388(10052):1398–1407
- 60 Diaz-Siso JR, Fischer S, Sisk GC, et al. Initial experience of dual maintenance immunosuppression with steroid withdrawal in vascular composite tissue allotransplantation. *Am J Transplant* 2015;15(05):1421–1431
- 61 Schneeberger S, Gorantla VS, Brandacher G, et al. Upper-extremity transplantation using a cell-based protocol to minimize immunosuppression. *Ann Surg* 2013;257(02):345–351
- 62 Petruzzo P, Testelin S, Kanitakis J, et al. First human face transplantation: 5 years outcomes. *Transplantation* 2012;93(02):236–240
- 63 Krezdorn N, Murakami N, Pomahac B, Riella LV. Immunological characteristics of a patient with belatacept-resistant acute rejection after face transplantation. *Am J Transplant* 2016;16(11):3305–3307
- 64 Theodorakopoulos E, Meghji S, Pafitanis G, et al. A review of the world's published face transplant cases: ethical perspectives. *Scars Burns Heal* 2017;3:1–10
- 65 Dharnidharka VR, Lamb KE, Gregg JA, Meier-Kriesche HU. Associations between EBV serostatus and organ transplant type in PTLD risk: an analysis of the SRTR National Registry Data in the United States. *Am J Transplant* 2012;12(04):976–983
- 66 Hussein K, Rath B, Ludewig B, Kreipe H, Jonigk D. Clinico-pathological characteristics of different types of immunodeficiency-associated smooth muscle tumours. *Eur J Cancer* 2014;50(14):2417–2424
- 67 Kueckelhaus M, Turk M, Kumamaru KK, et al. Transformation of face transplants: volumetric and morphologic graft changes resemble aging after facial allotransplantation. *Am J Transplant* 2016;16(03):968–978
- 68 Grulich AE, Vajdic CM. The epidemiology of cancers in human immunodeficiency virus infection and after organ transplantation. *Semin Oncol* 2015;42(02):247–257
- 69 Krezdorn N, Lian CG, Wells M, et al. Chronic rejection of human face allografts. *Am J Transplant* 2019;19(04):1168–1177
- 70 Renshaw A, Clarke A, Diver AJ, Ashcroft RE, Butler PE. Informed consent for facial transplantation. *Transpl Int* 2006;19(11):861–867
- 71 Brown CS, Gander B, Cunningham M, et al. Ethical considerations in face transplantation. *Int J Surg* 2007;5(05):353–364



- 72 Coffman KL, Siemionow MZ. Ethics of facial transplantation revisited. *Curr Opin Organ Transplant* 2014;19(02):181–187
- 73 Liu X, Langsdon S, Holloway W, et al. The ethics of facial allotransplantation: a systematic review. *Plast Reconstr Surg Glob Open* 2019;7(10):e2425
- 74 Kiwanuka H, Bueno EM, Diaz-Siso JR, Sisk GC, Lehmann LS, Pomahac B. Evolution of ethical debate on face transplantation. *Plast Reconstr Surg* 2013;132(06):1558–1568
- 75 Paradis C, Siemionow M, Papay F, et al. Ethical considerations in the first American face transplant. *Plast Reconstr Surg* 2010;126(03):896–901
- 76 Marchac A, Kuschner T, Paris J, Picard A, Vazquez MP, Lantieri L. Ethical issues in pediatric face transplantation: should we perform face transplantation in children? *Plast Reconstr Surg* 2016;138(02):449–454
- 77 Flynn J, Shaul RZ, Hanson MD, Borschel GH, Zuker R. Pediatric facial transplantation: ethical considerations. *Plast Surg (Oakv)* 2014;22(02):67–69
- 78 Suchyta MA, Sharp R, Amer H, Bradley E, Mardini S. Ethicists' opinions regarding the permissibility of face transplant. *Plast Reconstr Surg* 2019;144(01):212–224
- 79 Hull AM, Lowe T, Devlin M, Finlay P, Koppel D, Stewart AM. Psychological consequences of maxillofacial trauma: a preliminary study. *Br J Oral Maxillofac Surg* 2003;41(05):317–322
- 80 Furr LA, Wiggins O, Cunningham M, et al. Psychosocial implications of disfigurement and the future of human face transplantation. *Plast Reconstr Surg* 2007;120(02):559–565
- 81 Coffman KL. Psychiatric evaluation of the face transplant candidate. *Curr Opin Organ Transplant* 2015;20(02):222–228
- 82 Kiwanuka H, Aycart MA, Gitlin DF, et al. The role of face transplantation in the self-inflicted gunshot wound. *J Plast Reconstr Aesthet Surg* 2016;69(12):1636–1647
- 83 Maldonado JR, Sher Y, Lolak S, et al. The Stanford Integrated Psychosocial Assessment for Transplantation: a prospective study of medical and psychosocial outcomes. *Psychosom Med* 2015;77(09):1018–1030
- 84 Aycart MA, Kiwanuka H, Krezdorn N, et al. Quality of life after face transplantation: outcomes, assessment tools, and future directions. *Plast Reconstr Surg* 2017;139(01):194–203
- 85 Cogliandro A, Barone M, Salzillo R, Persichetti P. Quality of life after face transplantation: outcomes, assessment tools, and future directions. *Plast Reconstr Surg* 2017;140(05):757e
- 86 Oser ML, Nizzi MC, Zinser JL, et al. Quality of life and psychosocial functioning 2 years following facial transplantation. *Psychosomatics* 2018;59(06):591–600
- 87 FitzGibbon GM. The commandments of Gillies. *Br J Plast Surg* 1968;21(03):226–239