



Microsurgical Resection of Glioblastoma in a Patient Infected with Covid-19: A Case Report

Ressecção microcirúrgica de glioblastoma em um paciente infectado com COVID-19: Relato de caso

Lívio Pereira de Macêdo¹ Kauê Franke¹ Auricélio Batista Cezar-Junior^{1,2} Igor Vilela Faquini^{1,2} Eduardo Vieira de Carvalho Júnior¹ Nivaldo S. Almeida¹ Hildo Rocha Cirne Azevedo-Filho³

¹ Department of Neurosurgery, Hospital da Restauração, Recife, PE, Brazil

² Department of Neurosurgery, Instituto de Medicina Integral Professor Fernando Figueira (IMIP), Recife, PE, Brazil

³ Chairman of Department of Neurosurgery, Hospital da Restauração, Recife, PE, Brazil

Address for correspondence Lívio Pereira de Macêdo, MD, Rua João Fernandes Vieira, 544, Boa Vista, Recife, PE, 50050-200, Brazil (e-mail: livio21@gmail.com).

Arq Bras Neurocir 2021;40(3):e284–e287.

Abstract

The COVID-19 pandemic has affected a large number of patients in all countries, overwhelming healthcare systems worldwide. In this scenario, surgical procedures became restricted, causing unacceptable delays in the treatment of certain pathologies, such as glioblastoma. Regarding this tumor with high morbidity and mortality, early surgical treatment is essential to increase the survival and quality of life of these patients. Association between COVID-19 and neurosurgical procedures is quite scarce in the literature, with a few reported cases. In the present study, we present a rare case of a patient undergoing surgical resection of glioblastoma with COVID-19.

Keywords

- ▶ neurosurgery
- ▶ COVID-19
- ▶ SARS-CoV-2
- ▶ glioblastoma

Resumo

A pandemia de COVID-19 afetou um grande número de pacientes em todos os países, sobrecarregando os sistemas de saúde em todo o mundo. Nesse cenário, os procedimentos cirúrgicos tornaram-se restritos, causando atrasos inaceitáveis no tratamento de algumas patologias, como o glioblastoma. Em relação a esse tumor com alta morbimortalidade, o tratamento cirúrgico precoce é fundamental para aumentar a sobrevida e a qualidade de vida desses pacientes. A associação entre COVID-19 e procedimentos neurocirúrgicos é bastante escassa na literatura, com poucos casos relatados. No presente estudo, apresentamos um caso raro de paciente com COVID-19 submetido à ressecção cirúrgica de glioblastoma.

Palavras-chave

- ▶ neurocirurgia
- ▶ COVID-19
- ▶ SARS-CoV-2
- ▶ glioblastoma

Introduction

Officially declared as a global pandemic by the World Health Organization (WHO) on 11 March 2020, the Coronavirus

Disease 2019 (COVID-19) outbreak has evolved at an unprecedented rate. It presents as a severe acute respiratory syndrome (severe acute respiratory syndrome coronavirus 2 [SARS-CoV-2]), which was first reported in the city of

received

June 22, 2020

accepted

August 24, 2020

published online

November 26, 2020

DOI <https://doi.org/>

10.1055/s-0040-1718998.

ISSN 0103-5355.

© 2020. Sociedade Brasileira de Neurocirurgia. All rights reserved.

This is an open access article published by Thieme under the terms of the Creative Commons Attribution-NonDerivative-NonCommercial-License, permitting copying and reproduction so long as the original work is given appropriate credit. Contents may not be used for commercial purposes, or adapted, remixed, transformed or built upon. (<https://creativecommons.org/licenses/by-nc-nd/4.0/>)

Thieme Revinter Publicações Ltda., Rua do Matoso 170, Rio de Janeiro, RJ, CEP 20270-135, Brazil

Wuhan, China, in December 2019. Despite efforts to contain this virus, it quickly turned into a pandemic with an exponentially increasing number of patients being diagnosed. Therefore, COVID-19 has overwhelmed healthcare systems worldwide.¹⁻⁹ However, operative procedures have become restricted in hospitals due to that infection. Therefore, this may lead to unacceptable delays in the treatment of patients with certain types of pathologies with high morbidity and mortality such as glioblastoma (GBM).

Glioblastoma is the most aggressive type of brain tumor. The median survival time after diagnosis is only 12 to 15 months, with < 3 to 7% of patients surviving for > 5 years. It is well-established that early surgical treatment, associated with adjuvant treatment, is essential to increase survival and quality of life in these patients. In this scenario, management protocols recommend early surgical treatment for newly diagnosed or recurrent high-grade gliomas.^{9,10} Association between COVID-19 and neurosurgical procedures is quite scarce in the literature, with a few reported cases. In the present study, we present a rare case of a patient undergoing surgical resection of GBM with COVID-19, in the Hospital da Restauração, Recife, state of Pernambuco, Brazil.

Case Report

A 70-year-old male patient, with no comorbidities, was admitted to the neurosurgical emergency at Hospital da

Restauração, on April 2020. He presented with headache, left sided hemiparesis and gait disturbances, for 3 days. There was no previous history of respiratory symptoms. A cranial computed tomography (CT) scan showed a right heterogeneous parietal lesion, with mass effect, irregular hypodense center and enhancement of its margins. A cerebral magnetic resonance imaging (MRI) revealed a heterogeneous lesion in the right parietal convexity, with extension to the ipsilateral ventricular atrium, irregular-enhancing margins and a central necrotic core, suggestive of high-grade glioma (HGG) (► Fig. 1). On physical examination, he was alert, oriented, with an incomplete and asymmetric left hemiparesis (grades III and IV on the lower and upper limbs, respectively).

Preoperative laboratory tests and cardiologic evaluation were normal, including the SARS-CoV2 real-time polymerase chain reaction (RT-PCR), which was negative. The surgical procedure was performed within 72 hours. Personal protective equipment (PPE) was appropriately used by the surgical team, following the recommendations established for COVID-19 suspected or confirmed surgical patients.^{1,2,5,11,12} Gross Total Resection (GTR) was performed. At the end of the procedure, mechanical ventilation could not be removed due to the patient's low oxygen saturation, despite the high fraction of oxygen offered (FiO₂). The postoperative cranial CT scan showed GTR of the tumor (► Fig. 2). A chest CT scan exhibited multilobed ground-glass opacities, compatible with SARS-CoV2 infection (► Fig. 3). The patient was moved to the

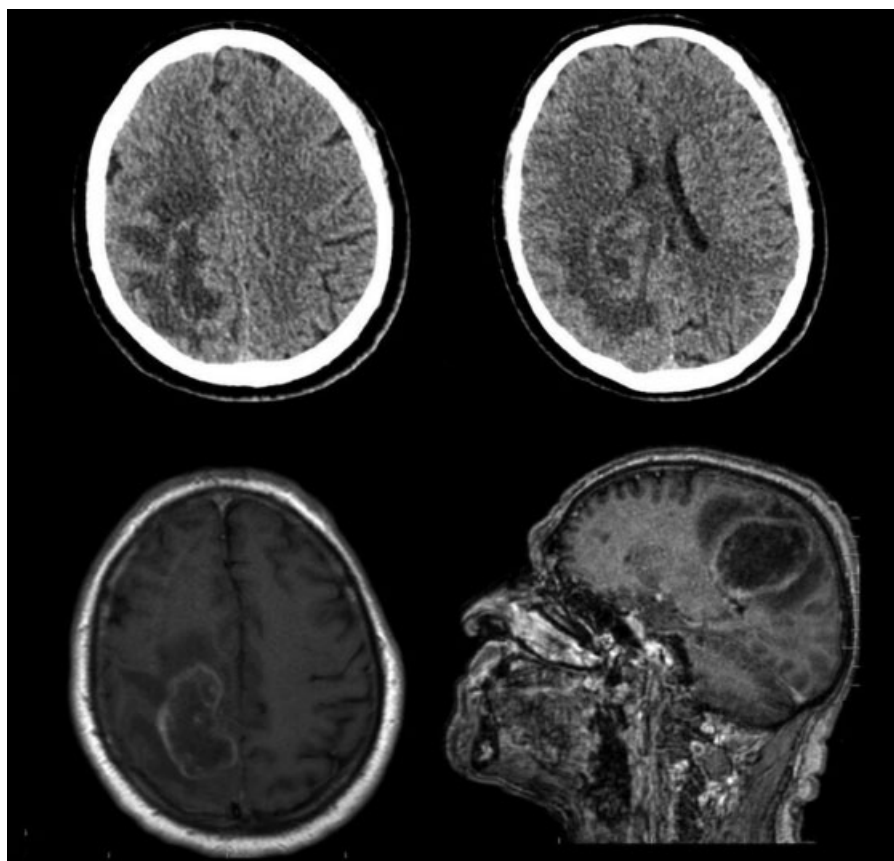


Fig. 1 Axial cranial computed tomography scan (upper) and axial brain magnetic resonance imaging (lower) with paramagnet contrast showing a heterogeneous lesion in the right parietal convexity, with extension to the ipsilateral ventricular atrium, irregular-enhancing margins and a central necrotic core.

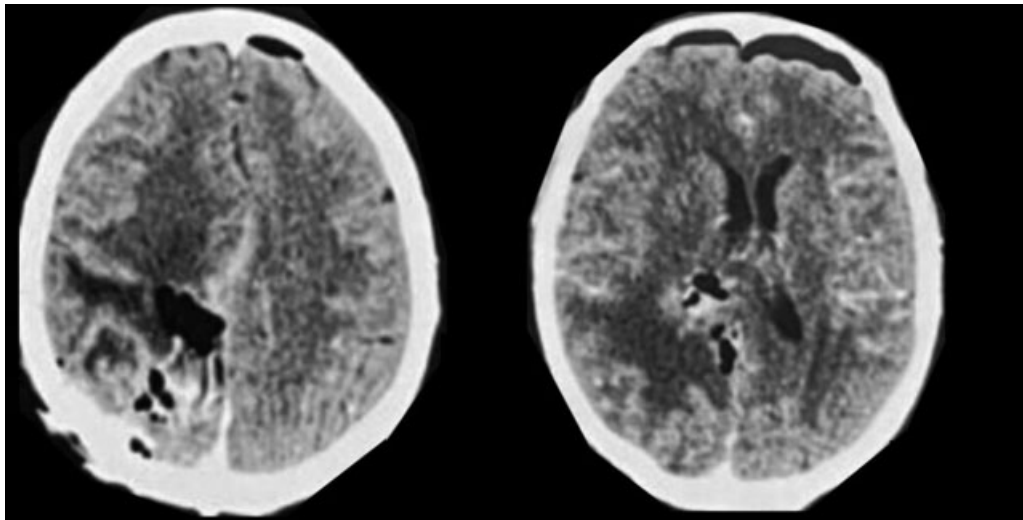


Fig. 2 Postoperative axial cranial computed tomography scan showing gross total resection of the tumor.

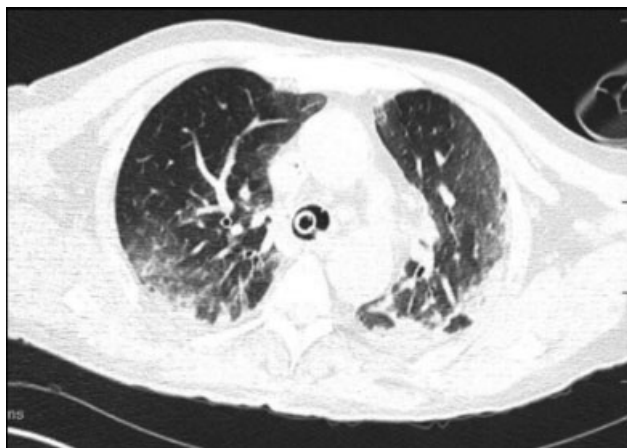

Fig. 3 Postoperative axial chest computed tomography scan exhibiting multilobed ground-glass opacities, suggestive of SARS-CoV2 infection.

intensive care unit (ICU), and another nasopharyngeal swab RT-PCR test was performed postoperatively, which was positive for SARS-CoV2 infection. During the hospitalization, respiratory symptoms were treated with ceftriaxone, azithromycin, oseltamir and hydroxychloroquine. After 12 days of mechanical ventilation, and 15 days of ICU, the patient was allocated to the infirmary. He showed improvement of his previous neurological deficits (showing left hemiparesis grade IV +). He was discharged after 19 days of hospitalization, with resolution of the respiratory condition and improvement of the functional status (modified Rankin Scale [mRS] of 3). The histological analysis diagnosed GBM (WHO grade IV), and the patient was referred to the clinical oncology department for planning adjuvant therapy.

Discussion

Recommendations and guidelines for the best neurosurgical practices in the COVID-19 era are still ongoing.¹¹ The case described in the present study was a suspected HGG in a patient infected with SARS-CoV-2. Due to the presence of neurological

deficits (left hemiparesis) and radiologic evidence of malignancy, associated with the fact that the patient had no respiratory symptoms and negative RT-PCR on admission, we opted for early surgical treatment, following precautions recommended by the WHO. As described by Zoia et al.¹³ in Lombardy (Italy), screening protocols were performed to support or contraindicate neurosurgical procedures. Thus, patients requiring immediate surgical treatment were classified as Class A ++; as Class +, those requiring treatment within a maximum of 7–10 days; and as Class A, those requiring surgery within a month. Patients with intracranial tumors with mass effect or with progressive neurological deficits, as reported in the present study, should be treated within a maximum of 7–10 days (Class A +). Moreover, according to the Centers for Medicare and Medicaid Services (CMS), all non-essential surgical procedures should be postponed and only urgent procedures must be performed. However, neurological surgeries should not be delayed if they are essential in reducing mortality and in preserving neurological function. The same recommendation is applied to patients with intracranial hypertension and risk of death.¹⁴

It is known that patients diagnosed with COVID-19 who underwent surgical procedures had worse outcomes and a higher mortality rate, requiring a longer ICU stay and hospitalization, compared to uninfected patients.^{2,15} On this account, for COVID-19 patients, the in-hospital mortality rate is, regrettably, high, at 28% overall; however, it is much greater, at > 50%, among those requiring mechanical ventilation.¹ Endorsing the higher mortality rate in neurosurgical patients, Ozoner et al.² reported their recent data from the University of Brescia (Italy). According to this study, the mortality related to chronic subdural hematoma surgical drainage was 80% in COVID-19 (+) patients. This rate was reported as 3.7% in the control group treated before the pandemic. The case described in our study showed a longer hospital stay and consequent delay in starting adjuvant treatment, which may cause a negative impact on the outcome of a patient with HGG. However, the patient reported that he recovered well. Although the mechanism of SARS-CoV-2 cerebral invasion is not fully understood, COVID-19 appears to demonstrate neuroinvasive potential. Viral encephalitis,

hemorrhagic necrosis involving mesial brain structures such as the mesial temporal lobes and thalami have been reported to date and may affect neurosurgical results.¹⁶ Moreover, according to a recent meta-analysis including nearly 1,800 COVID-19 patients, lower platelet count was associated with severe COVID-19. Thus, thrombocytopenia can lead to postoperative rebleeding that results in a poor outcome.¹⁵ Similarly, in SARS-CoV-2 infected and asymptomatic patients, surgical intervention could impair the immune system, leading to progression of the respiratory disease and to a worse outcome.^{17,18}

Since the infection is asymptomatic in some cases, the authors of the present study believe screening for COVID-19 is essential in all patients before surgery. In addition, it contributes to healthcare professional safety. A higher mortality risk is well-demonstrated in COVID-19 patients who were submitted to surgical procedures.² Therefore, asymptomatic surgical candidates are screened for SARS-CoV2 RT-PCR on hospital admission. However, the case reported in the present study showed a preoperative negative test. According to Kucirka et al.,¹⁹ the false-negative rate for SARS-CoV-2 RT-PCR testing is highly variable, highest within the first 5 days after exposure (up to 67%), and lowest on day 8 after exposure (21%). Therefore, it is questionable which is the best screening test on preoperative asymptomatic patients. Thus, there is still no standard protocol to guide the screening tests of neurosurgical patients.

In the literature, there are few cases reported of neurosurgery in patients diagnosed with COVID-19.^{2,20} As shown by Wen et al.,⁶ microsurgery for a ruptured cerebral aneurysm clipping was performed in a patient with suspected SARS-Cov-2 infection. In this case, RT-PCR testing was negative, despite the possibility of being a false negative, which impacts to reduce registered cases. Therefore, we reported in our study a rare confirmed case of patient infected with SARS-CoV-2 undergoing neurosurgical operation. Despite prolonged hospitalization, a good outcome was obtained, with a mRS of 3 on discharge.

Conclusion

The SARS-CoV-2 pandemic has caused changes in the routines of healthcare systems worldwide. Many surgeries have been postponed, so there are few reported cases of neurosurgery performed in patients diagnosed with COVID-19. The possibility of false negative SARS-CoV2 RT-PCR screening test might contribute to the reduced registered cases. Although these patients have worse results and a high mortality rate, the reported patient managed to recover well. Therefore, the present study showed a rare case of a patient with COVID-19 undergoing neurosurgical procedure. Although the management of these patients is still uncertain, the value of surgical treatment must be balanced with risks and benefits.

Patient Consent

The patient and relatives have consented to the submission of the present case report to the journal.

Conflict of Interests

The authors have no conflict of interests to declare.

References

- 1 Tsermoulas G, Zisakis A, Flint G, Belli A. Challenges to Neurosurgery during the COVID-19 pandemic. *World Neurosurg* 2020
- 2 Ozoner B, Gungor A, Hasanov T, Toktas ZO, Kilic T. Neurosurgery Practice During Coronavirus Disease. 2019 (COVID-19) Pandemic. *World Neurosurg*. 2020 May;
- 3 Flemming S, Hankir M, Ernestus RI, et al. Surgery in times of COVID-19-recommendations for hospital and patient management. *Langenbecks Arch Surg* 2020;405(03):359–364
- 4 Moriguchi T, Harii N, Goto J, et al. A first case of meningitis/encephalitis associated with SARS-Coronavirus-2. Vol. 94, *International journal of infectious diseases : IJID : official publication of the International Society for Infectious Diseases*. 2020:55–8
- 5 Grelat M, Pommier B, Portet S, et al. Covid-19 patients and surgery: Guidelines and checklist proposal. *World Neurosurg* 2020
- 6 Wen J, Qi X, Lyon KA, Liang B, Wang X, Feng D, et al. Lessons from China When Performing Neurosurgical Procedures During the Coronavirus Disease 2019 (COVID-19) Pandemic. *World Neurosurg* 2020
- 7 Ng Kee Kwong KC, Mehta PR, Shukla G, Mehta AR. COVID-19, SARS and MERS: A neurological perspective. *J Clin Neurosci* 2020;77:13–16
- 8 Paybast S, Emami A, Koosha M, Baghalha F. Novel coronavirus disease (COVID-19) and central nervous system complications: What neurologist need to know. *Acta Neurol Taiwan* 2020;29(01):24–31
- 9 Ramakrishna R, Zadeh G, Sheehan JP, Aghi MK. Inpatient and outpatient case prioritization for patients with neuro-oncologic disease amid the COVID-19 pandemic: general guidance for neuro-oncology practitioners from the AANS/CNS Tumor Section and Society for Neuro-Oncology. *J Neurooncol* 2020;147(03):525–529
- 10 Bernhardt D, Wick W, Weiss SE, et al. Neuro-oncology Management During the COVID-19 Pandemic With a Focus on WHO Grade III and IV Gliomas. *Neuro-oncol* 2020;noaa113
- 11 Germanò A, Raffa G, Angileri FF, Cardali SM, Tomasello F. Coronavirus Disease 2019 (COVID-19) and Neurosurgery: Literature and Neurosurgical Societies Recommendations Update. *World Neurosurg* 2020;139:e812–e817
- 12 Liu Z, Zhang Y, Wang X, et al. Recommendations for Surgery During the Novel Coronavirus (COVID-19) Epidemic. *Indian J Surg* 2020:1–5
- 13 Zoia C, Bongetta D, Veiceschi P, et al. Neurosurgery during the COVID-19 pandemic: update from Lombardy, northern Italy. *Acta Neurochir (Wien)* 2020;162(06):1221–1222
- 14 D'Amico RS, Baum G, Serulle Y, et al. A Roadmap to Reopening a Neurosurgical Practice in the Age of COVID-19. *World Neurosurg* 2020;139:289–293
- 15 Lippi G, Plebani M, Henry BM. Thrombocytopenia is associated with severe coronavirus disease 2019 (COVID-19) infections: A meta-analysis. *Clin Chim Acta* 2020;506:145–148
- 16 Wilson MP, Jack AS. Coronavirus disease 2019 (COVID-19) in neurology and neurosurgery: A scoping review of the early literature. *Clin Neurol Neurosurg* 2020;193:105866
- 17 O'Dwyer MJ, Owen HC, Torrance HDT. The perioperative immune response. *Curr Opin Crit Care* 2015;21(04):336–342
- 18 Torrance HDT, Pearse RM, O'Dwyer MJ. Does major surgery induce immune suppression and increase the risk of postoperative infection? *Curr Opin Anaesthesiol* 2016;29(03):376–383
- 19 Kucirka LM, Lauer SA, Laeyendecker O, Boon D, Lessler J. Variation in False-Negative Rate of Reverse Transcriptase Polymerase Chain Reaction-Based SARS-CoV-2 Tests by Time Since Exposure. *Ann Intern Med* 2020;173(04):262–267
- 20 Carrabba G, Tariciotti L, Guez S, Calderini E, Locatelli M. Neurosurgery in an infant with COVID-19. *Lancet* 2020;395(10234):e76