




## SPECIAL ARTICLE COVID-19

# Percutaneous Tracheostomy in COVID-19 Critically Ill Patients: Experience from 30 Consecutive Procedures

Pietro Bertini<sup>1</sup>  Francesco Forfori<sup>2</sup> Luca Bruschini<sup>3</sup> Francesco Corradi<sup>2</sup> Alessandro Ribechini<sup>4</sup>  
Etrusca Brogi<sup>2</sup> Fabio Guarracino<sup>1</sup>

<sup>1</sup>Cardiothoracic and Vascular Anesthesia and Intensive Care, Department of Anesthesia and Critical Care Medicine, Azienda Ospedaliero Universitaria Pisana, Pisa, Italy

<sup>2</sup>Department of Anesthesia and Critical Care Medicine, Department of Surgical, Medical and Molecular Pathology and Critical Care Medicine, Università di Pisa, Pisa, Italy

<sup>3</sup>ENT Audiology and Phoniatic Unit, Department of Surgical, Medical, Molecular Pathology and Emergency Medicine, Università di Pisa, Pisa, Italy

<sup>4</sup>Thoracic Endoscopy Unit, Cardiothoracic and vascular Department, Azienda Ospedaliero Universitaria Pisana, Pisa, Italy

Address for correspondence Pietro Bertini, MD, Department of Anaesthesia and Critical Care Medicine, Azienda Ospedaliero Universitaria Pisana, Via Paradisa, 2, Pisa, 56124, Italy (e-mail: [pietro.bertini@gmail.com](mailto:pietro.bertini@gmail.com)).

Int Arch Otorhinolaryngol 2021;25(1):e135–e140.

## Abstract

**Introduction** Percutaneous tracheostomy (PT) in the intensive care unit (ICU) is a well-established practice that shows a reduced risk of wound infection compared with surgical tracheostomy, thus facilitating mechanical ventilation, nursing procedures, reduction in sedation and early mobilization.

**Objective** This is an observational case-control study that compares the results of PT in ICU patients with coronavirus disease 2019 (COVID-19) prospectively enrolled to a similar group of subjects, retrospectively recruited, without COVID-19.

**Methods** Ninety-eight consecutive COVID-19 patients admitted to the ICU at Pisa Azienda Ospedaliero Universitaria Pisana between March 11th and May 20<sup>th</sup>, 2020 were prospectively studied. Thirty of them underwent PT using different techniques. Another 30 non-COVID-19 ICU patients were used as a control-group. The main outcome was to evaluate the safety and feasibility of PT in COVID-19 patients. We measured the rate of complications.

**Results** Percutaneous tracheostomy was performed with different techniques in 30 of the 98 COVID-19 ICU patients admitted to the ICU. Tracheostomy was performed on day 10 (mean  $10 \pm 3.3$ ) from the time of intubation. Major tracheal complications occurred in 5 patients during the procedure. In the control group of 30 ICU patients, no differences were found with regards to the timing of the tracheostomy, whereas a statistically significant difference was observed regarding complications with only one tracheal ring rupture reported.

**Conclusion** Percutaneous tracheostomy in COVID-19 patients showed a higher rate of complications compared with controls even though the same precautions and the same expertise were applied. Larger studies are needed to understand whether the coronavirus disease itself carries an increased risk of tracheal damage.

## Keywords

- ▶ ARDS
- ▶ COVID-19
- ▶ tracheostomy
- ▶ percutaneous
- ▶ surgical

received  
July 18, 2020  
accepted  
August 8, 2020

DOI <https://doi.org/10.1055/s-0040-1718528>.  
ISSN 1809-9777.

© 2021. Fundação Otorrinolaringologia. All rights reserved.  
This is an open access article published by Thieme under the terms of the Creative Commons Attribution-NonDerivative-NonCommercial-License, permitting copying and reproduction so long as the original work is given appropriate credit. Contents may not be used for commercial purposes, or adapted, remixed, transformed or built upon. (<https://creativecommons.org/licenses/by-nc-nd/4.0/>)  
Thieme Revinter Publicações Ltda., Rua do Matoso 170, Rio de Janeiro, RJ, CEP 20270-135, Brazil

## Introduction

In late February 2020, Italy was stricken by the coronavirus disease 2019 (COVID-19) pandemic. The outbreak first started in the Northern part of Italy and then spread south, causing disruption in social services and increasing the burden on hospitals and intensive care units (ICUs).<sup>1</sup>

From the preliminary experience in Northern Italy and China, it emerged that the majority of the COVID-19 positive critically ill patients experienced a rapid progression of pneumonia to acute respiratory distress syndrome (ARDS), which can lead to respiratory insufficiency and death.<sup>1-6</sup>

Tracheostomy is usually advisable in critically ill patients requiring prolonged mechanical ventilation (MV) to facilitate the weaning process. It has many beneficial effects, such as improving pulmonary and chest mechanics, the reduction of laryngeal or tracheal nociceptive stimuli, and injury due to protracted endotracheal intubation, and the improvement of patient comfort leading to less need of sedation. It also facilitates oral hygiene, nutrition and improves communication with personnel and relatives. However, it may be associated with complications related to the surgical technique.<sup>7-9</sup>

Percutaneous tracheostomy (PT) is nowadays one of the most common procedures in the ICU. It allows the intensivist to perform it at the bedside by placing a tracheostomy cannula after piercing the anterior tracheal wall using blunt dilatation of soft tissues by passing dilators over a guidewire according to the Seldinger technique.<sup>10</sup> As such, PT is a less invasive procedure that carries fewer procedural risks if performed by experts under direct bronchoscopy.

The benefits of performing early tracheostomy in the ICU are unclear from the available data. However, tracheostomy must be customized to the subject's clinical condition, recovery expectation, risk of continuous endotracheal intubation, and ventilatory machine support.<sup>10</sup>

Specific COVID-19 reports, case series, and recommendations about tracheostomy have been published but have not specifically targeted percutaneous approaches,<sup>11-14</sup> except for one recent publication.<sup>15</sup>

As an aerosol generating procedure (AGP), PT increases potential viral exposure to the personnel, thus requiring them to have adequate personal protective equipment (PPE).<sup>16,17</sup> Reducing the risk of nosocomial outbreak amplification through the transmission of COVID-19 to other patients and health caregivers is of critical importance.<sup>4</sup> For this reason, at the Azienda Ospedaliero Universitaria Pisana, ambient positive air pressure was converted to negative in the COVID-19 critical care area to allow safer AGPs, such as non-invasive ventilation (NIV), intubation and extubation, bronchoscopy, and tracheostomy.

In the present paper, we report the analysis of percutaneous tracheostomy in patients with COVID-19 at the Azienda Ospedaliero Universitaria Pisana.

The aim of our study was to evaluate clinical, logistic (negative pressure environment, PPE) and management differences between tracheostomy performed on patients with ARDS due to COVID-19 and patients with ARDS from other causes.

## Material and Methods

After local ethics committee approval (protocol nr. 17124, April 9<sup>th</sup>, 2020), a prospective (COVID-19 group) and retrospective (control group) study was performed at our ICU.

From March 11<sup>th</sup> to May 20<sup>th</sup>, 98 consecutive patients suffering from acute and severe respiratory failure were admitted to the COVID-19 dedicated ICU at the Azienda Ospedaliero Universitaria Pisana.

Patients needing tracheostomy were recruited as the COVID-19 group, and a retrospective matched group of patients were also included for comparison.

The exclusion criteria were: age < 18; preexisting tracheal pathology; tracheostomy in the past; tracheal or neck infection; known coagulopathy; altered neck anatomy, such as thyroid mass or swelling; unstable cervical spine; morbid obesity; elevated positive end expiratory pressure (PEEP) ventilation, and consent refusal.

The indication and timing of the tracheostomy were based on the duration of the MV, the need for prone ventilation, the anticipation of prolonged MV, and frequency of weaning failures.

The patient had to meet the following criteria: positive end expiratory pressure (PEEP) < 10 cm H<sub>2</sub>O; fraction of inspired oxygen (FiO<sub>2</sub>) < 0.7 L/min, and hemodynamic stability (avoidance or low dose of vasopressor agents, no serious cardiac arrhythmia).

### Statistical Analysis

All the data were analyzed using SPSS software version 24.0 for MacOSX (IBM Corp., Armonk, NY, USA). The baseline characteristics of patients were presented as number and percentage for dichotomous variables and mean ± standard deviation (SD) for continuous variables.

All the data were tested for normality using the Shapiro-Wilk analysis.

Analysis of variance (ANOVA) was evaluated using the one-way ANOVA procedure, with a *p*-value 0.05 chosen for the level of significance. The Chi-squared test was used to find correlation between categorical data.

Unless otherwise stated, the data are presented as mean ± SD.

Statistical studies were two-tailed and a *p*-value 0.05 was considered significant.

## Results

The sample consisted of 78% male patients with a mean age of 64 ± 13 years in the COVID-19 group, and of 74% male patients with a mean age of 67 ± 15 years in the control group (*p* NS).

The mean total time of MV in days was 18 ± 10 in the COVID-19 group, and 11 ± 12 in the control group (*p* < 0.05), with a mean sedation time in days of 15 ± 12 in the COVID-19 group, and of 9 ± 4 in the control group (*p* < 0.05). The mean ICU stay was 24.5 ± 8.2 in the COVID-19 group, and 23.4 ± 7.3 in the control group (*p* non-significant [NS]) (► **Table 1**).

**Table 1** Feature summary in patients with COVID-19 and non-COVID-19 infection

	COVID-19 Group	Non-COVID-19 Group	p
Sex (Male) %	78	74	NS
Age (years)	64 ± 13	67 ± 15	NS
Admission PaO <sub>2</sub> /FiO <sub>2</sub>	160	170	NS
Ciaglia	15	20	
Griggs	13	10	
Fantoni	2	0	
MV duration (days)	18 ± 10	11 ± 12	< 0.05
Sedation time (days)	15 ± 12	9 ± 4	< 0.05
Mean ICU stay (days)	24.5 ± 8.2	18.4 ± 7.3	< 0.05

Abbreviations: ICU, intensive care unit; MV, mechanical ventilation.

Orotracheal intubation was required in 57 of the COVID-19 patients, who did not require PT, at some point during their stay.

In the COVID-19 group, a tracheostomy was performed in 32 patients: PT was performed in 30 patients, a surgical tracheostomy in the remaining 2.

Of the 32 tracheostomized subjects, 26 patients were already invasively ventilated upon arrival from the emergency department or transported intubated from spoke hospitals.

Tracheostomy was performed on day 10 ± 3.3 from time of intubation in the COVID-19 group.

According to on-duty intensivist’s practice and experience, PT was performed in 13 patients with the Griggs Portex (Smiths Medical Inc. Minneapolis, MN, USA) technique, in 15 using the Ciaglia Blue-Rhino (Cook Medical Inc. Bloomington, IN, USA) procedure, and in 2 patients with the Fantoni trans-laryngeal technique.<sup>18</sup>

In one patient scheduled to undergo a Griggs procedure, a surgical tracheostomy was performed as a lesion of the posterior tracheal wall was detected upon endoscopically evaluating the tracheal lumen prior to initiating the PT. The lesion had probably occurred during tracheal intubation in the prehospital setting. In another case the surgical approach was preferred due to the unfavorable anatomy of the patient’s neck.

According to our protocol, a baseline endoscopic evaluation was performed in all cases to assess the tracheal anatomy and the feasibility of the tracheostomy procedure, and in all cases PT procedure was performed under bronchoscopy using a disposable Ambu aScope 4 Broncho Regular disposable bronchoscope (Ambu s.r.l., Milan, Italy) or standard airways video endoscope connected to an external monitor screen.

At the time of PT, one patient in the Ciaglia group was on veno-venous extracorporeal membrane oxygenation (VV

ECMO) due to the severity of the respiratory insufficiency. This allowed ventilation to be stopped to substantially reduce the risk of aerosol generation.

All procedures were conducted by expert intensivists wearing the appropriate PPE, in particular filtering facepiece class 3 (ffp3) respirator, face protecting shield, and eye protection (►Fig. 1).

The following complications were found after the PT: in 4 patients, a tracheal injury was observed consisting of a longitudinal mucosal laceration of the posterior wall. Such lesions occurred in two cases with the Griggs procedure and in two subjects with the Ciaglia technique. In one of the tracheal injuries following the Ciaglia Blue-Rhino percutaneous procedure, which was distally located only 1.5 cm from the carina, we took advantage of the specific cannula included in the Fantoni kit (Covidien-DAR, Segrate, Milan, Italia), which has a very short distal cuff. The complications were suspected based on pneumomediastinum or pneumothorax detected on chest X-ray or computed tomography (CT) scan after the procedures, and, in all cases, a tracheoscopy confirmed the tracheal wounds. All tracheal injuries were not treated surgically, but a conservative treatment and endoscopic follow-up was preferred: all of them healed completely within 2 weeks.

One large tracheoesophageal fistula (►Supplemental Video 1) was experienced during PT using the Griggs technique that required immediate surgery for esophageal and tracheal wall repair. This patient, who underwent PT on day 17, is still in our ICU on VV-ECMO, now on day 58 (►Fig. 2).

**Supplemental Video 1**

Large tracheoesophageal fistula in a patient with COVID-19, endoscopic vision.



We also observed two lesions to the pyriform sinuses due to placement of nasal-gastric tubes (NGT).

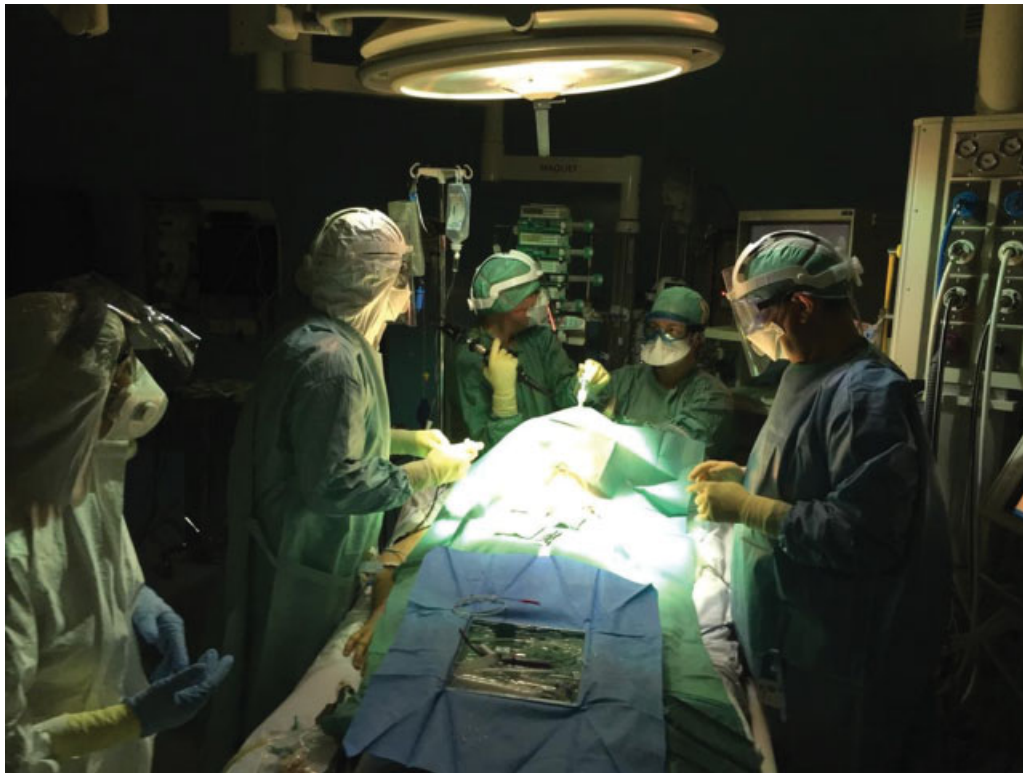In the control group of 30 sex- and age-matched ICU patients undergoing mechanical ventilation for ARDS, PT was performed with the Ciaglia technique in 20 patients and the Griggs in 10 using bronchoscopy guidance in all cases. Only one minor complication was reported, which consisted of a tracheal ring rupture during the cannula introduction.

None of the members of the team who performed the PT in the COVID-19 group turned out to be positive for Sars-CoV-2 screening, according to the hospital protocols.

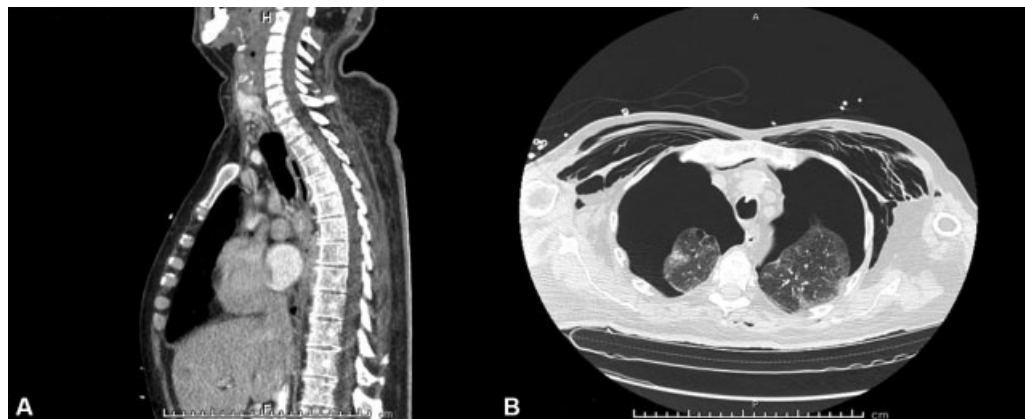**Discussion**

Although a well-established practice in the critically ill, there is no evidence so far that the percutaneous approach was superior to the surgical one in the setting of the COVID-19 pandemic.

Percutaneous tracheostomy involves extensive airway manipulation, such as bronchoscopy and serial dilatation



**Fig.1** Tracheostomy procedure performed in a COVID-19 patient on veno-venous extracorporeal membrane oxygenation, personnel wearing full PPE.



**Fig.2** Computed tomography scan showing large tracheoesophageal fistula (A) and bilateral pneumothorax (B).

of the trachea during the maneuver leading to a theoretical risk of aerosolization and favoring the surgical approach during the SARS pandemic.<sup>19,20</sup> On the other hand, percutaneous approaches have evolved over time as well as devices to perform bronchoscopy, such as remote monitors and closed circuits to seal the airway and prevent air diffusion and desaturation during the procedure.<sup>21</sup> Furthermore, PT can be performed as a bedside procedure, thus avoiding moving the critically ill patient to the operation room. Moreover, PT has also been demonstrated to be safer in terms of bleeding complications compared with the surgical procedure<sup>22</sup>: a recent report about PT in COVID-19 patients discloses increased hemorrhagic complications.<sup>15</sup> We did

not observe such an increased bleeding risk, but this might depend on different anticoagulation regimens related to local protocols. Nonetheless, managing bleeding complications seems to be crucial in COVID-19 patients who seem to benefit from anticoagulation administration.<sup>23</sup>

As far as we know from early reports concerning the present COVID-19 pandemic, invasive ventilation has to be expected to be longer rather than shorter in ICU patients and tracheostomy in the ICU must be performed according to the proper timing.<sup>24</sup> As of today, there is no identified time-point when diseased patients either improve, remain stable, or progress toward death due to pulmonary complications. In the SARS-1 epidemic, the mean time from onset to death was

23.7 days,<sup>25</sup> suggesting the low potential benefit of tracheostomy prior to this time. Patients who show no clinical or radiological remission within 10 days may be more likely to require ongoing ventilation and have a more severe course of disease, including death.<sup>4</sup> There is no anticipated timing for viral clearance, and critically ill patients may have significantly longer positive testing, lasting at least 2 to 3 weeks.<sup>2</sup>

As previously reported, early tracheostomy within 10 days has shown beneficial effects in terms of early liberation from mechanical ventilation and heavy sedation.<sup>26</sup>

In our experience, PT was feasible and safe for the medical team and the majority of our patients. A brief survey among the intensivists who performed the PT in our patients revealed the difficulty related to wearing full PPE as the most challenging condition in this setting. In particular, the double gloves were reported as limiting the sensitivity to guidewire manipulation and handling the dilators. Such qualitative evaluation highlights once more the need for the most experienced operators to be involved in performing PT in COVID-19 subjects. Surprisingly, no bleeding complications were observed despite the altered coagulation profile these patients may show<sup>27</sup> and the continued low molecular weight heparin regimen. Periods of ventilation interruption during the procedure were minimal and the risk of aerosol generation were reduced by using seals between the catheter mount piece and the bronchoscope used to guide the percutaneous procedure. In the patient under VV-ECMO support, we could completely stop mechanical ventilation throughout the PT procedure.<sup>28</sup>

Other COVID-19 airway complications have been reported, and they seem to be related to laryngitis and consequent edema of the upper airways.<sup>29</sup>

The 5 major complications we reported seem to suggest an apparent frailty observed in COVID-19 patients and related to perfusion impairment, as suggested elsewhere.<sup>30</sup> Though not yet reported, also the two lesions from the NG tube seem to suggest an abnormal reactivity in the upper airway tissues in such patients.

As it remains unclear why we detected more anatomical complications if compared with the control group, and even compared with the COVID-19 series recently reported,<sup>15</sup> further investigation in larger series is needed to address this observation in our patients. Published data from autopsies<sup>31</sup> in COVID-19 patients so far tend to concentrate on the lung pathology and do not provide insight into the upper airway characteristics in this specific disease.

## Lesson Learned and Where to Go from Here

Based on this experience from the first wave of the pandemic, we plan to have a multidisciplinary tracheostomy team (otolaryngologists, intensivists, airway endoscopists) in case of a new pandemic peak. This team will be composed of the most experienced operators who should carry out all the procedures. In the light of zero contamination among our staff members, we also confirm the logistics of negative pressure rooms as the preferred setting.

## Conclusion

Our experience with patients admitted to the ICU for SARS-CoV2 infection showed that the need for tracheostomy in such patients does not show specific peculiarities. Tracheostomy had no significant impact neither in the duration of MV, nor in the overall duration of ICU stay. However, COVID-19 patients showed a surprisingly higher rate of PT-related complications compared with non-COVID-19 ICU patients. Whether such side effects depend on specific disease characteristics affecting the upper airway tissues or on logistic differences is still unknown, and deserves further studies. Despite being a high-risk AGP, tracheostomy itself did not increase the ICU personnel infection rate thanks to the recommended protective measures.

### Conflict of Interests

The authors have no conflict of interests to declare.

## References

- Grasselli G, Zangrillo A, Zanella A, et al. Baseline Characteristics and Outcomes of 1591 Patients Infected With SARS-CoV-2 Admitted to ICUs of the Lombardy Region, Italy. *JAMA* 2020;06
- Chen J, Qi T, Liu L, et al. Clinical progression of patients with COVID-19 in Shanghai, China. *J Infect* 2020;80(05):e1–e6
- Guan W-J, Ni Z-Y, Hu Y, Liang W-H, Ou C-Q, He J-X, et al. Clinical Characteristics of Coronavirus Disease 2019 in China. *N Engl J Med*. 2020 30;382(18):1708–1720
- Murthy S, Gomersall CD, Fowler RA. Care for Critically Ill Patients With COVID-19. *JAMA* 2020
- Wu C, Chen X, Cai Y, Xia J, Zhou X, Xu S, et al. Risk Factors Associated With Acute Respiratory Distress Syndrome and Death in Patients With Coronavirus Disease 2019 Pneumonia in Wuhan, China. *JAMA Intern Med* 2020 Mar 13
- Yang X, Yu Y, Xu J, et al. Clinical course and outcomes of critically ill patients with SARS-CoV-2 pneumonia in Wuhan, China: a single-centered, retrospective, observational study. *Lancet Respir Med* 2020;8(05):475–481
- de Kleijn BJ, Wedman J, Zijlstra JG, Dijkers FG, van der Laan BFAM. Short- and long-term complications of surgical and percutaneous dilatation tracheotomies: a large single-centre retrospective cohort study. *Eur Arch Otorhinolaryngol* 2019; 276(06):1823–1828
- Gupta S, Dixit S, Choudhry D, et al. Tracheostomy in Adult Intensive Care Unit: An ISCCM Expert Panel Practice Recommendations. *Indian J Crit Care Med* 2020;24(Suppl 1):S31–S42
- Modalsli L, Liknes K, Flaatten H. Outcomes after percutaneous dilatation tracheostomy: Patients view 6 years after the procedure. *Acta Anaesthesiol Scand* 2020;64(06):798–802
- Mehta Y, Mehta C. Percutaneous tracheostomy. *Ann Card Anaesth* 2017;20(01):121
- McGrath BA, Ashby N, Birchall M, et al. Multidisciplinary guidance for safe tracheostomy care during the COVID-19 pandemic: the NHS National Patient Safety Improvement Programme (NatPat-SIP). *Anaesthesia* 2020
- McGrath BA, Brenner MJ, Warrillow SJ, et al. Tracheostomy in the COVID-19 era: global and multidisciplinary guidance. *Lancet Respir Med* 2020;8(07):717–725
- Piccin O, Albertini R, Caliceti U, et al. Early experience in tracheostomy and tracheostomy tube management in Covid-19 patients. *Am J Otolaryngol* 2020;41(04):102535
- Turri-Zanoni M, Battaglia P, Czaczkes C, Pelosi P, Castelnovo P, Cabrini L. Elective Tracheostomy During Mechanical Ventilation in Patients Affected by COVID-19: Preliminary Case Series From

- Lombardy, Italy. *Otolaryngol Head Neck Surg* 2020;163(01):135–137
- 15 Angel L, Kon ZN, Chang SH, et al. Novel Percutaneous Tracheostomy for Critically Ill Patients With COVID-19. *Ann Thorac Surg* 2020; S0003-4975(20)30603-2
  - 16 Kwan A, Fok WG, Law KI, Lam SH. Tracheostomy in a patient with severe acute respiratory syndrome. *Br J Anaesth* 2004;92(02):280–282
  - 17 Wei WI, Tuen HH, Ng RWM, Lam LK. Safe tracheostomy for patients with severe acute respiratory syndrome. *Laryngoscope* 2003;113(10):1777–1779
  - 18 Divisi D, Altamura G, Di Tommaso S, et al. Fantoni translaryngeal tracheostomy versus ciaglia blue rhino percutaneous tracheostomy: a retrospective comparison. *Surg Today* 2009;39(05):387–392
  - 19 Chee VWT, Khoo ML-C, Lee SF, Lai YC, Chin NM. Infection control measures for operative procedures in severe acute respiratory syndrome-related patients. *Anesthesiology* 2004;100(06):1394–1398
  - 20 Tien HC, Chughtai T, Joglekar A, Cooper AB, Brennenman F. Elective and emergency surgery in patients with severe acute respiratory syndrome (SARS). *Can J Surg* 2005;48(01):71–74
  - 21 Tay JK, Khoo ML-C, Loh WS. Surgical Considerations for Tracheostomy During the COVID-19 Pandemic: Lessons Learned From the Severe Acute Respiratory Syndrome Outbreak. *JAMA Otolaryngol Head Neck Surg* 2020
  - 22 Suzuki Y, Suzuki T, Yamamoto Y, et al. Evaluation of the Safety of Percutaneous Dilational Tracheostomy Compared with Surgical Tracheostomy in the Intensive Care Unit. *Crit Care Res Pract* 2019; 2019:2054846
  - 23 Tang N, Bai H, Chen X, Gong J, Li D, Sun Z. Anticoagulant treatment is associated with decreased mortality in severe coronavirus disease 2019 patients with coagulopathy. *J Thromb Haemost* 2020;18(05):1094–1099
  - 24 Wang D, Hu B, Hu C, Zhu F, Liu X, Zhang J, et al. Clinical Characteristics of 138 Hospitalized Patients With 2019 Novel Coronavirus-Infected Pneumonia in Wuhan, China. *JAMA*. 2020 Feb 7
  - 25 Leung TF, Wong GWK, Hon KLE, Fok TF. Severe acute respiratory syndrome (SARS) in children: epidemiology, presentation and management. *Paediatr Respir Rev* 2003;4(04):334–339
  - 26 Khammas AH, Dawood MR. Timing of Tracheostomy in Intensive Care Unit Patients. *Int Arch Otorhinolaryngol* 2018;22(04):437–442
  - 27 Giannis D, Ziogas IA, Gianni P. Coagulation disorders in coronavirus infected patients: COVID-19, SARS-CoV-1, MERS-CoV and lessons from the past. *J Clin Virol* 2020;127:104362
  - 28 Salna M, Tipograf Y, Liou P, et al. Tracheostomy Is Safe During Extracorporeal Membrane Oxygenation Support. *ASAIO J* 2020;66(06):652–656
  - 29 McGrath BA, Wallace S, Goswamy J. Laryngeal oedema associated with COVID-19 complicating airway management. *Anaesthesia* 2020;75(07):972
  - 30 Lodigiani C, Iapichino G, Carenzo L, et al; . Humanitas COVID-19 Task Force. Venous and arterial thromboembolic complications in COVID-19 patients admitted to an academic hospital in Milan, Italy. *Thromb Res* 2020;191:9–14
  - 31 Menter T, Haslbauer JD, Nienhold R, et al. Postmortem examination of COVID-19 patients reveals diffuse alveolar damage with severe capillary congestion and variegated findings in lungs and other organs suggesting vascular dysfunction. *Histopathology* 2020