Article published online: 2022-03-31

Case Series for Gamma Knife Surgery for Arteriovenous Malformation Associated Intracranial Aneurysms

Jungwook Baek[1] Mooseong Kim[1] Seyoung Pyo[1] Youngjin Heo[2] Seong Ho Kim[3] Cheol Ahn[4] Jeongeun Kim[5]

[1]Department of Neurological Surgery, Inje University Busan Paik Hospital, Busan, South Korea
[2]Department of Diagnostic Radiology, Inje University Busan Paik Hospital, Busan, South Korea
[3]Department of Neurological Surgery, DaeKoo, Korea
[4]Department of Neurological Surgery, ChoonHae Hospital, Busan, Korea
[5]Boston University College of Arts and Sciences: Biology, Boston, Massachusetts, United States

Address for correspondence Jungwook Baek, MD, Department of Neurological Surgery, Inje University, Busan Paik Hospital, Bokji road 75, Jinkoo, Busan 47392, Korea, (e-mail: ibisjuh@hanmail.net).

Indian J Neurosurg 2022;11:265–268

Abstract

Objective The incidence of aneurysms coexisting with arteriovenous malformations (AVMs) ranges between 2.7% and 16.7%. The anatomical relationship between AVM and aneurysm is critical in deciding the best management.

Methods Between October 1994 and August 2017, gamma knife surgery (GKS) was performed in six patients with AVMs and associated aneurysms. The patients consisted of four men and two women with a mean age of 37.8 years (range, 18–57 years). The mean follow-up was 34.2 months (range, 13–84 months). The mean maximal dose was 35.9 Gy and the mean margin dose to AVM was 18 Gy. Coil embolization was performed in one of the aneurysms prior to GKS. In our study, GKS was performed in six AVM-associated aneurysms. Of the six aneurysms, four were intranidal and two were pedicular. The mean volume of AVMs was 3.6 cm^3 (range, 1.6–6.5 cm^3).

Results The locations of aneurysms are as follows: four on posterior cerebral artery (PCA), one on posterior inferior cerebellar artery (PICA), and one on middle cerebral artery (MCA). Sublocation sites were MCA M3 above, PCA P3 above, and PICA distal. There were no GKS-related complications. Complete obliteration of AVM and aneurysm was documented in all four patients with intranidal aneurysm-associated AVMs. Both the aneurysm and AVM were completely obliterated in the two patients with proximal pedicular aneurysms.

Conclusion GKS is a possible treatment for AVM with associated intranidal or pedicular aneurysms located above P3 or M3, etc., in which there is less turbulent flow and jet flow.

Keywords
- aneurysm
- arteriovenous malformation
- gamma knife

DOI https://doi.org/10.1055/s-0040-1718239
ISSN 2277-954X.

Introduction

The occurrence of aneurysms in arteriovenous malformations (AVMs) patients ranges from 2.7% to 16.7%[1,2]. The proper treatment of AVMs and aneurysms is crucial as AVM-associated aneurysms has a higher propensity of hemorrhage. The size of AVM and the presence of aneurysms are positively correlated.

The topological relationship between the AVM and the aneurysm is critical in deciding the best management. Perata et al[3] associated feeding pedicle aneurysm with parenchymal hemorrhage and AVM in brain and claimed that anatomical relationship between the AVM and the aneurysm is critical in deciding the best management. In our study, we assessed angiographic results and clinical outcomes of patients, with AVM-combined aneurysms, who were treated with gamma knife surgery (GKS).

Methods

From October 1994 to December 2017, we treated 542 patients for AVMs with GKS. Ten of 542 patients (1.97%) had AVM-associated aneurysms. Six of 542 patients (1.1%) were treated with GKS for associated aneurysms.

The mean follow-up was 34.2 months (range, 7–83 months). There were two women and four men with a mean age of 37.8 years (range, 18–55 years). A summary of the outcome result is provided in ►**Table 1**.

All radiosurgical procedures were performed using the Leksell Gamma Knife B unit or Perfexion (Elekta Instruments AB, Stockholm, Sweden). Dose planning was based on a combination of findings from stereotactic biplanar angiography and MR imaging (Gyroscan: Philips Medical Systems, Best, The Netherlands). Dose planning was performed using the KULA system (Elekta Instrument AB) and July 1997 and GammaPlan was used thereafter. The mean maximal dose was 36 Gy and the mean margin dose to AVM was 18 Gy. Of the six aneurysms, four were intranidal and two were pedicular. Radiosurgery target was nidus plus aneurysm. The mean volume of the AVM was 2.9 cm^3 (range 1.6–6.5 cm^3). All aneurysms were small aneurysms. The follow-up review of patients, which was performed, consisted of clinical examinations and MR imaging studies. When MRI findings revealed no residual vascular abnormality, cerebral angiography was performed.

Result

Female to male ratio of the patients was 2:4. The mean age of the patients with combined aneurysm was 32.7 years (range, 18–55 years). The locations of the aneurysms were the following: four on posterior cerebral artery (PCA), one on middle cerebral artery MCA, and one on posterior inferior cerebellar artery (PICA). There were four intranidal aneurysms (three PCA intranidal aneurysms and one MCA intranidal aneurysm) and two proximal pedicular aneurysms.

Before GKS, four patients were treated with embolization for the associated proximal pedicular aneurysms: two MCA aneurysms, one PICA aneurysm, and one anterior cerebral artery (ACA) aneurysm. The mean maximal dose was 35.9 Gy and the mean margin dose to AVM was 18 Gy. The mean volume of the AVM was 3.6 cm^3 (range, 1.6–6.5 cm^3). The mean follow-up was 34.2 months (range, 13–84 months).

►**Table 1** presents the clinical data from the patients with AVM-associated aneurysm. We classified the results of the treatments into the following four categories: complete obliteration, subtotal obliteration (≥ 70% obliteration), partial obliteration, and no change. All of the six patients had complete obliteration of AVM and the aneurysm. A 27-year-old woman patient presented with a sudden onset of headache and vomiting. A CT scan of the brain demonstrated spontaneous intraventricular hemorrhage. Angiography revealed an PCA pseudoaneurysm and AVM. Embolization failed to achieve obliteration, and GKS was performed on aneurysm and AVM with maximal dose of 36 Gy and margin dose of 18 Gy to the AVM and the aneurysm. Follow–up angiography performed 13 months later demonstrated complete obliteration of AVM and pedicular aneurysm (►**Fig. 1**). There were no GKS-related complications.

Discussion

The frequency of aneurysms associated with AVMs ranges from 2.7% to 16.7% in AVM patients.[1,2] It is important to determine the treatment options based on the anatomical locations of the AVM and aneurysm. Controversy exists regarding the etiology of both distal flow-related and intranidal aneurysms.[4-7] There are three main theories that explain their etiology: 1) aneurysms are caused by hemodynamic stresses, due to the presence of AVMs; 2) congenital disorders

Table 1 Summary of the characteristics in patients with concomitant aneurysms and AVMs.

Case No.	Age (years), sex	Aneurysm location	Follow-up (months)	Outcome
1	22, M	PCA, intranidal aneurysm	36	Complete obliteration
2	18, M	Right MCA, intranidal aneurysm	36	Complete obliteration
3	55, F	Left PICA, 3 pedicular aneurysm	25	Complete obliteration
4	55, M	PCA, P2-3 junction aneurysm: coil P3-4 intranidal aneurysm	23	Complete obliteration
5	19, M	Right PCA (P3) intranidal aneurysm	72	Complete obliteration
6	27, F	Left PCA: pseudoaneurysm: coil; fail	13	Complete obliteration

Abbreviations: MCA, middle cerebral artery; PICA, posterior inferior cerebellar artery; PCA, posterior cerebral artery.

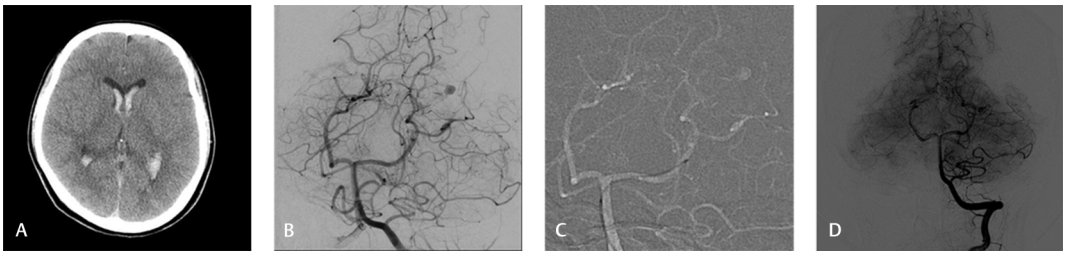

Fig. 1 (**A**) Neuroimages obtained in a 28-year-old woman. (**B**) Angiography demonstrates left posterior cerebral artery (PCA) pedicular pseudoaneurysm and an arteriovenous malformation (AVM). (**C**) Embolization failed to achieve obliteration, and GKS was performed on aneurysm and an AVM. (**D**) Thirteen months postoperatively, angiography revealed complete obliteration of the AVM and aneurysm

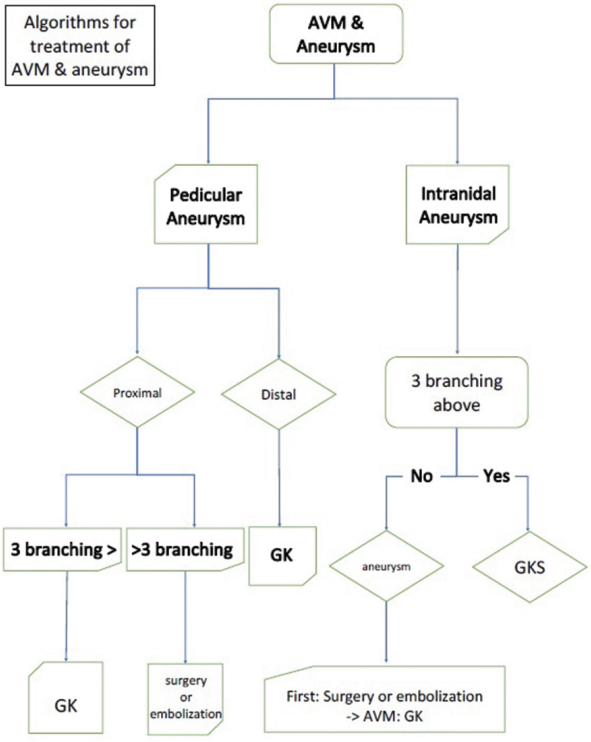

Fig. 2 Treatment algorithm for patients with AVM and associated aneurysm.

of vascular disorders; 3) purely coincidental.[8] There are two flows in aneurysms. One is jet flow which works in the basilar bifurcation or MCA bifurcation site. The other is turbulent flow that is inside the aneurysms.

Perata et al[3] classified the aneurysms in the following manner: (1) dysplastic or remote, unrelated to inflow vessels; (2) proximal, arising at the circle of Willis origin of a vessel supplying the AVM; (3) pedicular, arising from the midcourse of a feeding pedicle; 4) intranidal within the AVM nidus itself.

Lasjaunias et al[9] described three types of arterial aneurysms associated with AVMs: (1) distal or intralesional aneurysms; (2) proximal aneurysms on vessels directly supplying the AVM; (3) remote or dysplastic aneurysms unrelated to inflow vessels.

Cunha et al[10] distinguished the following four categories: **I**: proximal on ipsilateral major artery feeding the AVM; **IA:** proximal on major artery related but contralateral to the AVM; **II:** distal on superficial artery feeding the AVM; **III:** proximal or distal on deep artery feeding the AVM; **IV:** on artery unrelated to the AVM.

Redekop et al[6] categorized the aneurysm associated with an AVM in the following manner: intranidal and flow-related, proximal, distal, and unrelated to the AVM supply. Redekop policy involves treating the symptomatic lesion first.

In our study, GKS was performed in six AVM-associated aneurysms. The aneurysms location were as follows: one on the MCA, four on the PCA, and one on the PICA.

In patients with AVM-associated aneurysms, treatment of the hemorrhage site should be performed first. GKS is a possible method of choice for the treatment of an AVM with an associated intranidal or pedicular aneurysms above P3 above or M3 above site, etc. That site is less turbulent flow and jet flow area. Most of the distal pedicular aneurysms disappear after AVM obliteration and only nidus is enough in most of the cases, but proximal pedicular aneurysms do not disappear after AVM obliteration, so we should treat combined proximal pedicular aneurysms (►**Fig. 2**).

Conclusions

Our research demonstrates that to determine the ideal treatment of AVM-associated aneurysms, the identification of the location of aneurysm is crucial. In patients with AVM-associated aneurysms, treatment of the hemorrhage site should be performed first. GKS is a possible method of choice to treat AVM with an associated intranidal or pedicular aneurysms located above P3, M3, etc.

Conflict of Interest
None declared.

References

1 Brown RD Jr, Wiebers DO, Forbes GS. Unruptured intracranial aneurysms and arteriovenous malformations: frequency of intracranial hemorrhage and relationship of lesions. J Neurosurg 1990;73(6):859–863
2 Cockroft KM, Thompson RC, Steinberg GK. Aneurysms and arteriovenous malformations. Neurosurg Clin N Am 1998;9(3):565–576
3 Perata HJ, Tomsick TA, Tew JM Jr. Feeding artery pedicle aneurysms: association with parenchymal hemorrhage and arteriovenous malformation in the brain. J Neurosurg 1994;80(4):631–634

4 Marks MP, Lane B, Steinberg GK, Chang PJ. Hemorrhage in intracerebral arteriovenous malformations: angiographic determinants. Radiology 1990;176(3):807–813
5 Marks MP, Lane B, Steinberg GK, Snipes GJ. Intranidal aneurysms in cerebral arteriovenous malformations: evaluation and endovascular treatment. Radiology 1992;183(2):355–360
6 Redekop G, TerBrugge K, Montanera W, Willinsky R. Arterial aneurysms associated with cerebral arteriovenous malformations: classification, incidence, and risk of hemorrhage. J Neurosurg 1998;89(4):539–546
7 Wiebers DO, Whisnant JP, Sundt TMJr, O'Fallon WM. The significance of unruptured intracranial saccular aneurysms. J Neurosurg 1987;66(1):23–29
8 Boyd-Wilson JS. The association of cerebral angiomas with intracranial aneurysms. J Neurol Neurosurg Psychiatry 1959;22(3):218–223
9 Lasjaunias P, Piske R, Terbrugge K, Willinsky R. Cerebral arteriovenous malformations (C. AVM) and associated arterial aneurysms (AA). Analysis of 101 C. AVM cases, with 37 AA in 23 patients. Acta Neurochir (Wien) 1988;91(1-2):29–36
10 Cunha e Sa MJ, Stein BM, Solomon RA, McCormick PC. The treatment of associated intracranial aneurysms and arteriovenous malformations. J Neurosurg 1992;77(6):853–859

