

Direct Oral Anticoagulants in Antithrombin Deficiency: Initial Experience in a Single Center

B. Soerajja Bhoelan¹ René Mulder² Michaël V. Lukens² Karina Meijer¹

¹Department of Haematology, University Medical Centre Groningen, University of Groningen, Groningen, The Netherlands

²Department of Laboratory Medicine, University Medical Centre Groningen, University of Groningen, Groningen, The Netherlands

Address for correspondence B. Soerajja Bhoelan, MD, University Medical Centre Groningen, P.O. Box 30.001, 9700 RB Groningen, The Netherlands (e-mail: b.s.bhoelan@umcg.nl).

Thromb Haemost 2021;121:242–245.

Recently, a paper on the treatment of venous thromboembolism (VTE) in patients with hereditary antithrombin (AT) deficiency was published.¹ One of the issues the authors address is the use of direct oral anticoagulants (DOACs) and the duration of anticoagulation therapy in this specific patient population. Currently, clinical evidence on the use of DOACs in these patients is lacking. Here, we would like to share our experience with a direct factor Xa inhibitor in the treatment of VTE in our patients with hereditary AT deficiency.

Currently, 67 patients with hereditary AT deficiency are followed in our center. Thirty-five patients experienced at least one VTE. Twenty-two patients experienced one VTE and 13 patients suffered from recurrent VTE. None of the VTEs occurred during anticoagulation therapy. All patients were treated with vitamin K antagonist (VKA) initially for their first or recurrent VTE. Twenty-nine out of 35 patients continued with long-term anticoagulation therapy with VKA. In one of these 29 patients, long-term anticoagulation therapy was discontinued because of severe bleeding complications. Of the remaining 6 out of 35 who were primarily treated without long-term therapy, anticoagulation therapy was discontinued after a first provoked VTE in 5 patients and after two provoked VTEs in 1 patient.

Of 28 patients still on long-term anticoagulation therapy with VKA, 10 patients switched to a direct factor Xa inhibitor (rivaroxaban 20 mg once daily) contributing to 17.3 person years of follow-up (mean 1.7 years, range 0.04–5.4 years) (►Table 1). Seven out of 10 patients were included in previous family studies.² Reasons for switch to rivaroxaban were unstable VKA therapy and medication convenience. None of the patients experienced recurrent venous thrombotic disease (95% confidence interval [CI] 0–45%) and no major bleeds did occur during treatment with rivaroxaban. In two patients rivaroxaban was discontinued and VKA restarted, because of intermittent hematuria in one patient and acute femoral artery occlusion due to peripheral arterial disease in the other patient.

Few other studies have reported on the efficacy of VTE treatment in hereditary AT deficiency. Recently, a meta-analysis was published by Elsebaie et al in which patients with hereditary thrombophilia included in large DOAC trials for the initial VTE treatment in the first 6 months were analyzed separately.³ Combined, 15 patients with AT deficiency were included in the EINSTEIN-VTE, EINSTEIN-PE, and Hokusai VTE trials.^{4–6} None of these patients experienced recurrent VTE.³ In another study, five patients with AT deficiency were described in both the initial and long-term treatment setting, three of whom used a direct factor Xa inhibitor in full dose (i.e., rivaroxaban 20 mg once daily and apixaban 5 mg twice daily), one in reduced dose (i.e., apixaban 2.5 mg twice daily), and one using a direct factor IIa inhibitor (dabigatran 110 mg twice daily) in reduced dose.⁷ Follow-up time was not specified for patients with AT deficiency specifically. Also, none of these patients experienced recurrent VTE. As in this report, a limited number of patients with AT deficiency were available. In ►Fig. 1, the estimates are pooled showing rather favorable efficacy of DOACs in this specific patient category.

AT deficiency is associated with an increased risk of recurrent VTE. In family studies, the annual incidence of recurrent VTE is estimated to be around 10% without long-term anticoagulation therapy^{2,8,9} with the incidence accumulating up to 50% during 10 years of follow-up.¹⁰ With long-term anticoagulation therapy the recurrence risk in AT-deficient patients is effectively decreased to 1.5 to 4.0% per year.^{2,8,11,12} Based on this, we treat AT deficiency patients with long-term anticoagulation therapy after a first VTE event, in the absence of an increased bleeding risk. Data stratified by the presence of a provoking factor is thus far not available for the population of AT deficiency patients, specifically because of the small numbers included in studies concerning these patients. However, estimates from a study pooling AT, protein S, and protein C deficiency patients reported an annual incidence of recurrence of 6.6% (95% CI 4.8–8.9%) for provoked events versus 9.7% (95% CI 6.8–13.4%)

received

June 30, 2020

accepted

July 10, 2020

published online

August 30, 2020

© 2020, Thieme. All rights reserved.

Georg Thieme Verlag KG,

Rüdigerstraße 14,

70469 Stuttgart, Germany

DOI <https://doi.org/>

10.1055/s-0040-1715647.

ISSN 0340-6245.

Table 1 Patient characteristics

No.	Sex	Body weight (kg)	Age (y)	AT antigen ^a (%)	AT activity ^a (%)	Type	Indication long-term OAC	Provoking factor first VTE	Provoking factor recurrent VTE	Positive family history	Nucleotide change (cNomen) ^b	Predicted protein change (pNomen) ^b	FU (y)
1	M	103	39	99	68	II	First VTE	None	NA	First degree	c.749C > T	p.Thr250Ile	0.6
2	F	74	65	73	58	I	Recurrent VTE	Surgery	None	First degree	c.(1029_1034)delGGA	Could not be assigned	0.2
3	M	93	81	47	46	I	First VTE	None	NA	First degree	c.857A > C	p.Gln286Pro	2.2
4	M	91	48	58	54	I	First VTE	None	NA	First degree	c.857A > C	p.Gln286Pro	3.0
5	F	61	57	58	54	I	Recurrent VTE	Pregnancy	Pregnancy ^d	Second degree	c.857A > C	p.Gln286Pro	2.5
6	M	85	53	NA	NA	I	Recurrent VTE	None	None	First degree	c.979dup	p.Val327Glyfs*16	1.5
7	M	105	68	NA	74	NA	First VTE	None	NA	First degree	NA	NA	0.04
8	F	89	38	65	44	I	First VTE	None	NA	First degree	c.(1029_1034)delGGA	Could not be assigned	1.0
9	F	81	37	48	69	I	First VTE	Estrogens	NA	First degree	No mutations found in SERPINC1 gene or promoter region	NA	5.4
10	F	57	62	44	NA	I	Recurrent VTE ^c	Unknown	Unknown	First degree	c.857A > C	p.Gln286Pro	0.7

Abbreviations: AT, antithrombin; FU, follow-up; OAC, oral anticoagulation therapy; VTE, venous thromboembolism.

^aReference value 80–120%.

^bAs described by Mulder et al. *British Journal of Haematology* 2017.¹⁵

^cAt least one VTE in left leg, arguable whether second VTE in same leg was an evident recurrence.

^dUnknown whether patient used of thromboprophylaxis during pregnancy.

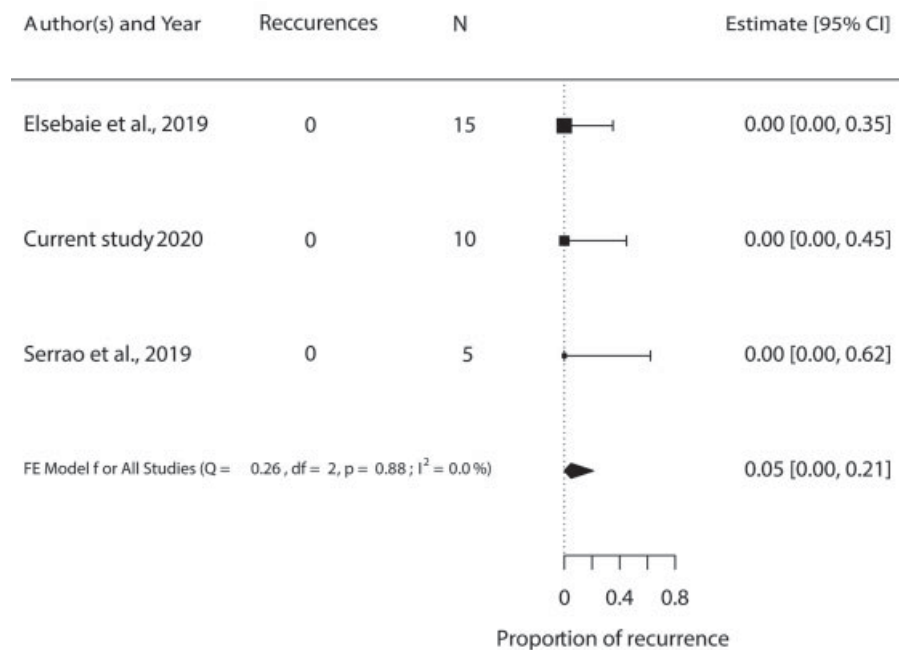


Fig. 1 Forest plot displaying proportion of venous thromboembolism (VTE) recurrence in patients with antithrombin (AT) deficiency treated with a direct oral anticoagulant (DOAC).

for unprovoked events, which could justify long-term anticoagulation therapy irrespective of the presence of a provoking factor.⁹

When considering long-term secondary prophylaxis with a direct factor Xa inhibitor, the next question is—Which dose should be applied? Secondary prophylaxis can either consist of treatment with a full-dose factor Xa inhibitor or reduced-dose factor Xa inhibitor in certain clinical scenarios. The EINSTEIN-CHOICE and AMPLIFY-EXT have shown that the reduced doses of apixaban and rivaroxaban (2.5 mg twice daily and 10 mg once daily, respectively) are effective in the secondary prevention of VTE in patients with a first episode of an unprovoked VTE.^{13,14} However, the EINSTEIN-CHOICE and AMPLIFY-EXT trials included patients in whom clinical equipoise existed regarding the choice of long-term anticoagulation therapy. Based on the data discussed before, sufficient equipoise is not present in this specific population and these patients with a hereditary AT deficiency would probably not have been included in these trials. Therefore, we believe that clinicians should refrain from routinely prescribing DOACs in a reduced dose in patients with AT deficiency, as data are currently lacking in this specific population.

In conclusion, our preliminary observation does not seem to suggest direct factor Xa inhibitors being less effective in patients with an AT deficiency. Given the data available on the high recurrence risk of VTE in this patient population, long-term anticoagulation therapy seems to be justified. However, data on the efficacy of direct factor Xa inhibitors in a reduced dose in AT deficient patients is currently lacking. Therefore, while experience accumulates, we continue using full-dose direct factor Xa inhibitors for secondary prophylaxis in these patients.

Authors' Contributions

K.M. conceptualized the paper. B.S.B. drafted and wrote the manuscript. R.M. and M.V.L. contributed to the laboratory and genetics data. K.M., R.M., and M.V.L. revised the manuscript.

Conflict of Interest

B.S.B. has nothing to disclose. R.M. has nothing to disclose. M. V.L. has nothing to disclose. K.M. reports grants, speaker fees, and travel support from Bayer, grants and speaker fees from Sanquin, grants from Pfizer, speaker fees from Boehringer Ingelheim, speaker fees from BMS, speaker fees from Aspen, consulting fees from Uniqure, outside the submitted work.

References

- Pabinger I, Thaler J. How I treat patients with hereditary antithrombin deficiency. *Blood* 2019;134(26):2346–2353
- Croles FN, Mulder R, Mulder AB, Lukens MV, Meijer K. β -Antithrombin, subtype of antithrombin deficiency and the risk of venous thromboembolism in hereditary antithrombin deficiency: a family cohort study. *Thromb Res* 2018;168(June):47–52
- Elsebaie MAT, van Es N, Langston A, Büller HR, Gaddh M. Direct oral anticoagulants in patients with venous thromboembolism and thrombophilia: a systematic review and meta-analysis. *J Thromb Haemost* 2019;17(04):645–656
- Bauersachs R, Berkowitz SD, Brenner B, et al; EINSTEIN Investigators. Oral rivaroxaban for symptomatic venous thromboembolism. *N Engl J Med* 2010;363(26):2499–2510
- Büller HR, Prins MH, Lensin AW, et al; EINSTEIN-PE Investigators. Oral rivaroxaban for the treatment of symptomatic pulmonary embolism. *N Engl J Med* 2012;366(14):1287–1297
- Büller HR, Décousus H, Grosso MA, et al; Hokusai-VTE Investigators. Edoxaban versus warfarin for the treatment of

- symptomatic venous thromboembolism. *N Engl J Med* 2013;369(15):1406–1415
- 7 Serrao A, Lucani B, Mansour D, et al. Direct oral anticoagulants in patients affected by major congenital thrombophilia. *Mediterr J Hematol Infect Dis* 2019;11(01):e2019044
 - 8 Vossen CY, Walker ID, Svensson P, et al. Recurrence rate after a first venous thrombosis in patients with familial thrombophilia. *Arterioscler Thromb Vasc Biol* 2005;25(09):1992–1997
 - 9 Brouwer JLP, Lijfering WM, Ten Kate MK, Kluijn-Nelemans HC, Veeger NJGM, van der Meer J. High long-term absolute risk of recurrent venous thromboembolism in patients with hereditary deficiencies of protein S, protein C or antithrombin. *Thromb Haemost* 2009;101(01):93–99
 - 10 De Stefano V, Simioni P, Rossi E, et al. The risk of recurrent venous thromboembolism in patients with inherited deficiency of natural anticoagulants antithrombin, protein C and protein S. *Haematologica* 2006;91(05):695–698
 - 11 Di Minno MND, Dentali F, Lupoli R, Ageno W. Mild antithrombin deficiency and risk of recurrent venous thromboembolism: a prospective cohort study. *Circulation* 2014;129(04):497–503
 - 12 Croles FN, Borjas-Howard J, Nasserinejad K, Leebeek FWG, Meijer K. Risk of venous thrombosis in antithrombin deficiency: a systematic review and Bayesian meta-analysis. *Semin Thromb Hemost* 2018;44(04):315–326
 - 13 Agnelli G, Buller HR, Cohen A, et al; AMPLIFY-EXT Investigators. Apixaban for extended treatment of venous thromboembolism. *N Engl J Med* 2013;368(08):699–708
 - 14 Weitz JI, Lensing AWA, Prins MH, et al; EINSTEIN CHOICE Investigators. Rivaroxaban or aspirin for extended treatment of venous thromboembolism. *N Engl J Med* 2017;376(13):1211–1222
 - 15 Mulder R, Croles FN, Mulder AB, Huntington JA, Meijer K, Lukens MV. SERPINC1 gene mutations in antithrombin deficiency. *Br J Haematol* 2017;178(02):279–285