

Coronavirus Disease 2019 in a Premature Infant: Vertical Transmission and Antibody Response or Lack Thereof

Pedro Rivera-Hernandez, MD^{1,*} Jayasree Nair, MD^{1,*} Shamim Islam, MD¹ Lauren Davidson, DO²
Arthur Chang, MD¹ Valerie Elberson, MD¹

¹Department of Pediatrics, Jacobs School of Medicine and Biomedical Sciences, University at Buffalo, Buffalo, New York

²Buffalo Neonatology Associates, Sisters of Charity Hospital, Buffalo, New York

Address for correspondence Jayasree Nair, MD, UBMD Pediatrics, 1001 Main Street, Conventus 5th Floor, Buffalo, NY 14203 (e-mail: jnair@upa.chob.edu).

Am J Perinatol Rep 2020;10:e224–e227.

Abstract

Keywords

- ▶ severe acute respiratory syndrome coronavirus 2 in preterm
- ▶ vertical transmission
- ▶ coronavirus disease 2019
- ▶ antibody response

With the global spread of severe acute respiratory syndrome coronavirus 2 (SARS-CoV-2) infection, several reports highlight its effects on pregnant women. Based on scant available data, vertical transmission is considered unlikely. We present here a preterm neonate born to a critically ill mother with SARS-CoV-2 with early evidence of infection with a positive reverse transcription polymerase chain reaction on day 1. Lack of parental contact prior to testing and strict adherence to recommended airborne precautions perinatally suggest vertical transmission of infection. Critical maternal illness and medications may have contributed to the need for extensive resuscitation at birth and highlight the importance of close fetal monitoring. Infant lacked immunoglobulin G antibody response by 3 weeks, presumably secondary to mild clinical course and prematurity. Effects of SARS-CoV-2 in preterm infants, their antibody response and potential for asymptomatic carriage remain uncertain.

Limited data exist on severe acute respiratory syndrome coronavirus 2 (SARS-CoV-2) during pregnancy, outcomes of infected pregnant patients and vertical or perinatal transmission of infection.¹ However, the potential for preterm birth and other adverse pregnancy outcomes is recognized.² It is unclear if risk factors for severe coronavirus disease 2019 (COVID-19), the infection caused by SARS-CoV-2, such as diabetes, obesity and hypertension,³ exacerbated illness in pregnant women, increasing the risk of adverse pregnancy outcomes. We report the perinatal course of a preterm neonate with SARS-CoV-2 infection.

Case Presentation

A male infant was born at 33 weeks of gestational age to a 38-year-old female with SARS-CoV-2 infection who presented to the hospital with a 3-day history of dyspnea and

malaise. Maternal medical history included obesity, poorly controlled type 2 diabetes, asthma, and hypertension. Laboratory results are represented in ▶Table 1 and RT-PCR on a nasopharyngeal swab was positive for SARS-CoV-2 at admission. She was admitted to the ICU and started on hydroxychloroquine, ceftriaxone, azithromycin, heparin for DVT prophylaxis, and methylprednisolone. The next day her condition worsened, she developed diabetic ketoacidosis (DKA), necessitating an insulin infusion. Progressive hypoxic respiratory failure led to intubation and mechanical ventilation. Over the course of the next 2 days, her DKA resolved, she received a convalescent plasma transfusion, and completed a course of betamethasone for fetal lung maturity. Remdesivir was added to her medication regimen on her day 4 of admission. Shortly after, her membranes ruptured and the bedside fetal monitoring showed fetal distress and tachycardia. The mother was transferred to the operating room for a cesarean section, while on mechanical ventilatory support requiring 50% oxygen.

* Authors contributed equally to this study.

received
May 31, 2020
accepted
June 1, 2020

DOI <https://doi.org/10.1055/s-0040-1715176>
ISSN 2157-6998.

Copyright © 2020 by Thieme Medical Publishers, Inc., 333 Seventh Avenue, New York, NY 10001, USA.
Tel: +1(212) 760-0888.

License terms



Table 1 Maternal laboratory test results

Maternal			
Variable	Results Day of admission	Results Day of delivery	Reference range
Hemoglobin (g/dL)	12.0	9.3	12.0–16.0
White-cell count (per mm ³)	11.4	18.3	4.0–11.0
Platelet count (per mm ³)	154	247	145–450
Prothrombin time (s)	11.6	10.6	9.3–13.5
INR	1.0	0.9	0.9–1.2
aPTT (s)	36.2		25.9–40.5
Sodium (mmol/L)	137	140	136–145
Potassium (mmol/L)	4.1	4.9	3.6–5.1
Chloride (mmol/L)	109	105	98–107
CO ₂ (mmol/L)	16	25	21–31
BUN (mg/dL)	9	13	7–25
Creatinine (mg/dL)	0.67	0.55	0.6–1.10
Glucose (mg/dL)	192	239	74–100
SARS-CoV-2, RT-PCR	Positive on day of admission 1		Negative
SARS-CoV-2, IgG	Positive on day of admission 5		≤ 1.4

Abbreviations: aPTT, activated partial thromboplastin time; BUN, blood urea nitrogen; IgG, immunoglobulin G; INR, international normalized ratio; RT-PCR, reverse transcription polymerase chain reaction; SARS-CoV-2, severe acute respiratory syndrome coronavirus 2.

The infant required cardiopulmonary resuscitation at birth with endotracheal intubation, chest compressions, and a single dose of endotracheal epinephrine; Apgar's scores were 0, 1, and 5 at 1, 5, and 10 minutes, respectively. Airborne precautions were maintained throughout perinatal care and delivery. There was no postdelivery contact with mother or father; also, paternal SARS-CoV-2 testing was negative. Infant was transferred to the neonatal intensive care unit, following neonatal care guidelines.⁴

The appropriate for gestational age (birthweight = 2,380 g) infant had poor tone and decreased activity on admission, likely due to maternal sedation and general anesthesia, which subsequently improved over the next few hours. Infant was on conventional pressure control ventilation with stable vital signs: temperature of 98.2°F (36.8°C), heart rate of 130 bpm, blood pressure of 66/44 (51) mm Hg, and oxygen saturation of 95 on 50% oxygen. The infant's cord blood gas showed perinatal metabolic acidosis (pH 7.03 and base deficit of –3.6). He had an abnormal coagulation profile without any bleeding manifestations (► **Table 2**), which normalized after a fresh frozen plasma transfusion. Chest radiography had mild ground glass appearance and increased pulmonary vascularity bilaterally (► **Fig. 1A**), consistent with respiratory distress syndrome which was treated with surfactant administration.

Table 2 Infant laboratory test results

Infant	Results on admission	Results 24 hours	Reference range
Blood gas pH/pCO ₂ (mmHg)/pO ₂ (mmHg)/base	7.18/70/52/–3.6		
White-cell count (per mm ³)	11.3	13.5	4.0–11.0
Hemoglobin (g/dL)	16.9	15.5	12.0–16.0
Hematocrit, %	52.5	45.8	36–47
Platelet count (per mm ³)	153	70	145–450
Neutrophils, %	38	74	(50–75)
Bands, %	7	0	(0–3)
Lymphocytes, %	33	16	(20–40)
Monocytes, %	12	10	(2–10)
Eosinophils, %	6	0	(0–8)
Basophils, %	1	0	(0–2)
Prothrombin time (s)	65.8	18.9	9.3–13.5
INR	5.6	1.6	0.9–1.2
aPTT (s)	103.9	48.7	25.9–40.5
Sodium (mmol/L)	141	139	136–145
Potassium (mmol/L)	3.7	4.1	3.6–5.1
Chloride (mmol/L)	104	102	98–107
CO ₂ (mmol/L)	24	22	21–31
BUN (mg/dL)	18	15	7–25
Creatinine (mg/dL)	1.00	0.87	0.6–1.10
Calcium (mg/dL)	8.0	6.1	8.6–10.3
Glucose (mg/dL)	98	59	74–100
SARS-CoV-2, RT PCR	24 hours: positive 72 hours: negative 96 hours: negative		Negative
SARS-CoV-2, IgG	< 1.4 index Negative at 7, 13, and 21 days		≤ 1.4

Abbreviations: aPTT, activated partial thromboplastin time; BUN, blood urea nitrogen; IgG, immunoglobulin G; INR, international normalized ratio; RT-PCR, reverse transcription polymerase chain reaction; SARS-CoV-2, severe acute respiratory syndrome coronavirus 2.

Case Progression and Outcome

During the next 12 to 20 hours, the infant remained stable on conventional ventilation with relatively low settings. On day 2, an abnormal bowel gas pattern evoked suspicion for malrotation (► **Fig. 1B**). Infant was transferred to the regional perinatal center where upper gastrointestinal contrast and water-soluble contrast enema studies were normal. A large bladder was noted on abdominal ultrasound with bilateral hydronephrosis, suggestive of obstructive uropathy. The infant was extubated at 24 hours to noninvasive ventilation and was in room air by 60 hours after birth. Nasopharyngeal swab for SARS-CoV-2 by RT-PCR was positive at 24 hours and

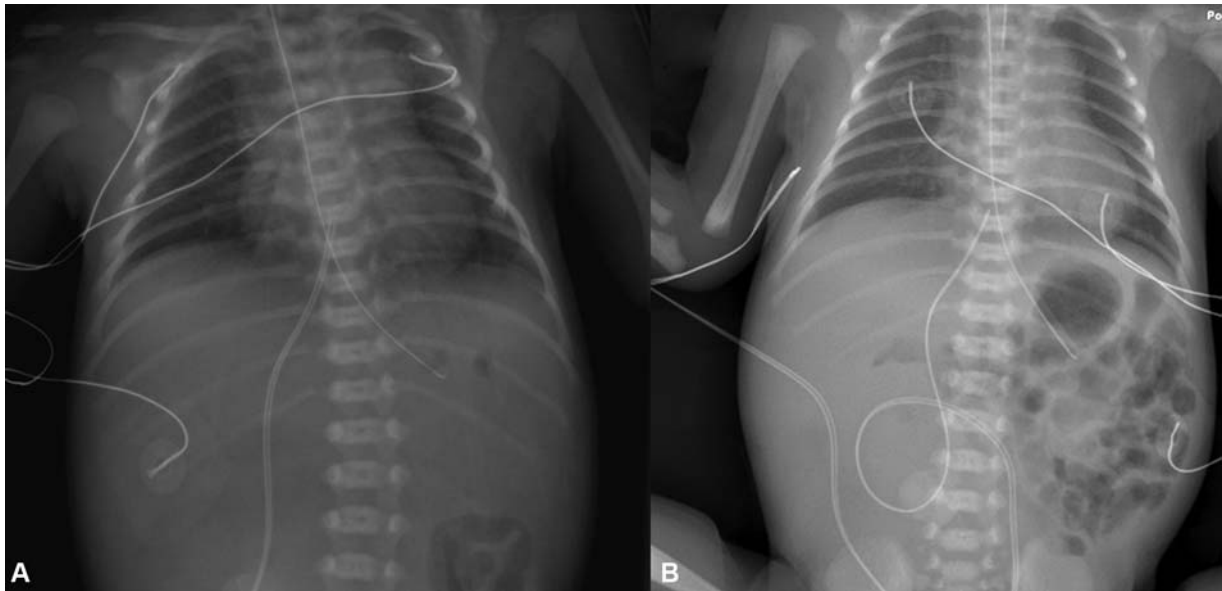


Fig. 1 Radiographs of infant. (A) Chest radiograph at presentation. (B) Chest and abdomen on day 2 with abnormal bowel gas pattern.

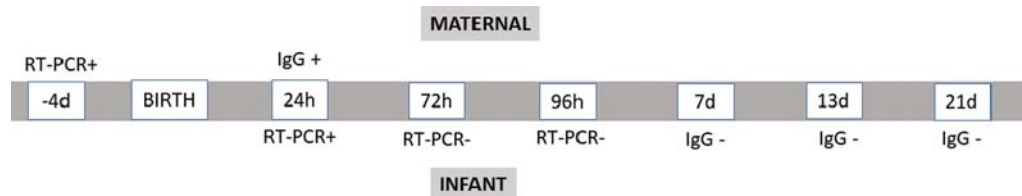


Fig. 2 Timeline of maternal and infant corona virus testing.

negative at 72 and 96 hours. Immunoglobulin G (IgG) testing was negative at 7, 13, and 21 days (→ **Fig. 2**). Currently, the infant is 25 days old and remains stable on full enteral feeds. Breast milk was available only on day 15 due to maternal illness and clinical condition, with the infant receiving formula feeds prior to that. Further urological investigations including a voiding cystourethrogram were normal, and spontaneous resolution of hydronephrosis was noted on follow-up ultrasound at 15 days.

Discussion

Initial reports indicated vertical transmission of COVID-19 was unlikely; however, recent publications highlight possible intrauterine infection.^{5,6} In our case, positive RT-PCR at 24 hours of life suggested prenatal infection, as the patient had no direct contact with his critically ill mother or any known COVID-infected person postbirth. Evidence of virus by PCR on the first day has been demonstrated only in one prior published report, a preterm infant from Peru.⁶ There are several similarities with our report, with both being preterm infants born to mothers with diabetes and class II obesity, categorized as risk factors for severe COVID-19 in adults.³ Whether severity of maternal illness and comorbidities contributed to presumed transmission of this infection to the infant remains unclear. A recent preprint report has also demonstrated SARS-CoV-2 localized to syncytiotropho-

blast cells at the maternal–fetal interface of the placenta,⁷ supporting possibility of vertical transmission. Neonatal data, however, is lacking in this case due to a previable pregnancy that underwent termination.

All the infants reported thus far in the literature that were perinatally exposed, or possibly had vertical transmission, had mild disease and good outcomes. Several theories, including altered immune responses, are proposed for this relatively benign picture in neonates.⁸ While this infant did have respiratory symptoms necessitating intubation and mechanical ventilation, this could be a result of respiratory distress syndrome and is unlikely to be a COVID-19 pneumonia. Depression at birth and altered coagulation profile could be a reflection of maternal medical condition and medications. However, the fetal heart decelerations, low Apgar's score, and perinatal metabolic acidosis are also suggestive of possible hypoxic ischemic insult suggesting close monitoring of pregnant women with severe SARS-CoV-2 infection is required to optimize neonatal outcomes.

The timeline of antibody response in neonates remains unclear. Dong et al published a case report of a term infant who tested negative by RT-PCR but had presence of IgG and IgM.⁵ Zeng et al⁷ also made a similar observation noting IgM positivity in a newborn full-term infant. Both articles suggest evidence of vertical transmission as IgM is not transferred via the placenta and would presumptively be produced by the infant, which would require exposure to the virus prior to

delivery. However, they did not sample maternal tissue and could not demonstrate virological presence with RT-PCR nasopharyngeal swabs. Preterm infants have a maturing immune system which may further alter their response to a perinatal infection. We speculate that our infant's mild infection and prematurity may be associated with a lack of IgG development by 21 days. The only other premature infant reported with SARS-CoV-2 infection also lacked an IgG response.⁶ IgM tests were not performed due to technical concerns with IgM assays⁹ and a lack of validated tests available at our center.

False positive RT-PCR results are unlikely; however, the possibility of the neonate's PCR sample being contaminated by maternal body fluids cannot be completely ruled out. The lack of placental tissue and maternal amniotic fluid testing are limitations to this report. Nevertheless, this case of SARS-CoV-2 in a preterm neonate emphasizes the need for further characterization of the clinical features, timeline of clearance, antibody response, and potential for asymptomatic carriage of SARS-CoV-2 in this vulnerable population. Data from large groups such as national perinatal COVID registries should help answer some of these questions.

Authors' Contributions

P.R.H., J.N., and V.E. conceptualized and designed the report, drafted the initial manuscript, and reviewed and revised the manuscript. L.D., A.C. and S.I. collected data, participated in care of infant, and reviewed and revised the manuscript. All authors approved the final manuscript as submitted and agree to be accountable for all aspects of the work.

Funding

None.

Conflict of Interest

None declared.

References

- Mimouni F, Lakshminrusimha S, Pearlman SA, Raju T, Gallagher PG, Mendlovic J. Perinatal aspects on the covid-19 pandemic: a practical resource for perinatal-neonatal specialists. *J Perinatol* 2020;40(05):820–826
- Rasmussen SA, Smulian JC, Lednický JA, Wen TS, Jamieson DJ. Coronavirus disease 2019 (COVID-19) and pregnancy: what obstetricians need to know. *Am J Obstet Gynecol* 2020;222(05):415–426
- Li B, Yang J, Zhao F, et al. Prevalence and impact of cardiovascular metabolic diseases on COVID-19 in China. *Clin Res Cardiol* 2020; 109(05):531–538
- Puopolo K, Hudak M, Kimberlin D, et al. Management of infants born to mothers with COVID-19. Available at: <https://www.the-hospitalist.org/hospitalist/article/221157/pediatrics/management-infants-born-mothers-covid-19>. Accessed April 22, 2020
- Dong L, Tian J, He S, et al. Possible vertical transmission of SARS-CoV-2 from an infected mother to her newborn. *JAMA* 2020
- Alzamora MC, Paredes T, Caceres D, Webb CM, Valdez LM, La Rosa M. Severe COVID-19 during pregnancy and possible vertical transmission. *Am J Perinatol* 2020
- Hosier H, Farhadian S, Morotti R, et al. SARS-CoV-2 infection of the placenta. Available at: <https://www.medrxiv.org/content/10.1101/2020.04.30.20083907v3>. Accessed May 12, 2020
- Rawat M, Chandrasekharan P, Hicar MD, Lakshminrusimha S. COVID-19 in newborns and infants-low risk of severe disease: silver lining or dark cloud? *Am J Perinatol* 2020
- Kimberlin DW, Stagno S. Can SARS-CoV-2 infection be acquired in utero?: more definitive evidence is needed *JAMA* 2020