



Iatrogenic Acute Type A Aortic Dissection following Elective Cardiopulmonary Bypass

Pierre Huette, MD¹ Christophe Beyls, MD¹ Mathieu Guilbart, MD¹ Guillaume Haye, MD¹
Jérémy Vial, MD³ Gilles Touati, MD² Yazine Mahjoub, MD, PhD¹ Osama Abou-Arab, MD, PhD¹

¹Department of Anesthesia and Critical Care, Cardiac Thoracic Vascular and Respiratory Intensive Care Unit, Amiens University Medical Center, 1 rue du Professeur Christian Cabrol, Amiens, France

²Cardiac surgery Department, Amiens University Medical center, 1 rue du Professeur Christian Cabrol, Amiens, France

³Radiologic Department, Amiens University Medical Center, 1 rue du Professeur Christian Cabrol, Amiens, France

Address for correspondence Pierre Huette, MD, Department of Anesthesia and Critical Care, Cardiac Thoracic Vascular and Respiratory Intensive Care Unit, Amiens Hospital University, 1 rue du Professeur Christian Cabrol, Amiens, 80054, France (e-mail: huette.pierre@chu-amiens.fr).

AORTA 2020;8:155–158.

Abstract

Keywords

- ▶ cardiopulmonary bypass
- ▶ iatrogenic acute aortic dissection
- ▶ lower limb ischemia

We report a 62-year-old woman who was scheduled for an elective Tirone David valve sparing aortic root replacement under cardiopulmonary bypass. Within the next few hours, the patient developed bilateral acute ischemia of both lower limbs. A thoracic and abdominopelvic computed tomography scan showed acute Type A aortic dissection with a perforation at the brachiocephalic arterial trunk and a complete malperfusion of the inferior mesenteric and iliac arteries.

Iatrogenic acute Type A aortic dissection (AAAD) following cardiopulmonary bypass may occur intraoperatively (with recognition during the primary cardiac surgery), within the first 2 weeks, classified as early postoperative AAAD or late (>30 days after primary heart surgery).¹

We report the case of a 62-year-old woman without previous medical history. After discovery of an aortic murmur, echocardiography demonstrated 3+ aortic insufficiency and an aneurysm of the ascending aorta. Computed tomography (CT) scan revealed an ascending aortic diameter of 70 mm.

The patient underwent an elective David valve sparing aortic root replacement.

Within the next few hours, the patient developed bilateral acute ischemia of both lower limbs and asymmetric blood pressure in the upper limbs. Transthoracic and transesophageal echocardiography revealed a flap in the distal ascending aorta, the aortic arch, and the descending thoracic aorta, suggestive of acute aortic dissection. A thoracic and abdominopelvic CT scan with three-dimensional volume rendering

was performed. It showed an acute Type A aortic dissection with fenestration at the brachiocephalic arterial trunk and complete malperfusion of the inferior mesenteric and iliac arteries (▶ **Figs. 1–3**).


Despite maximal management with revascularization of the lower extremities by axillofemoral bypass, total colectomy, and stenting of the abdominal aorta, evolution was unfavorable with multiorgan failure leading to the death of the patient 72 hours later. Iatrogenic AAAD is a rare complication that must be recognized early to deliver the appropriate therapy. Intraoperative diagnosis may be difficult.^{2,3} Regarding the aortic repair, our chosen strategy was a rescue therapy via revascularization of the lower limbs, without direct aortic repair because of the high surgical risk associated with emergency aortic surgery. Shea and Polanco conducted a retrospective study and reported a standardized approach management of AAAD with aortic repair.⁴ Thus, in our case, aortic arch repair could have been performed once aortic dissection was recognized.^{5,6}

received
June 20, 2019
accepted after revision
June 11, 2020

DOI <https://doi.org/10.1055/s-0040-1715124>.
ISSN 2325-4637.

Copyright © 2020 by Thieme Medical Publishers, Inc., 333 Seventh Avenue, New York, NY 10001, USA.
Tel: +1(212) 760-0888.

License terms



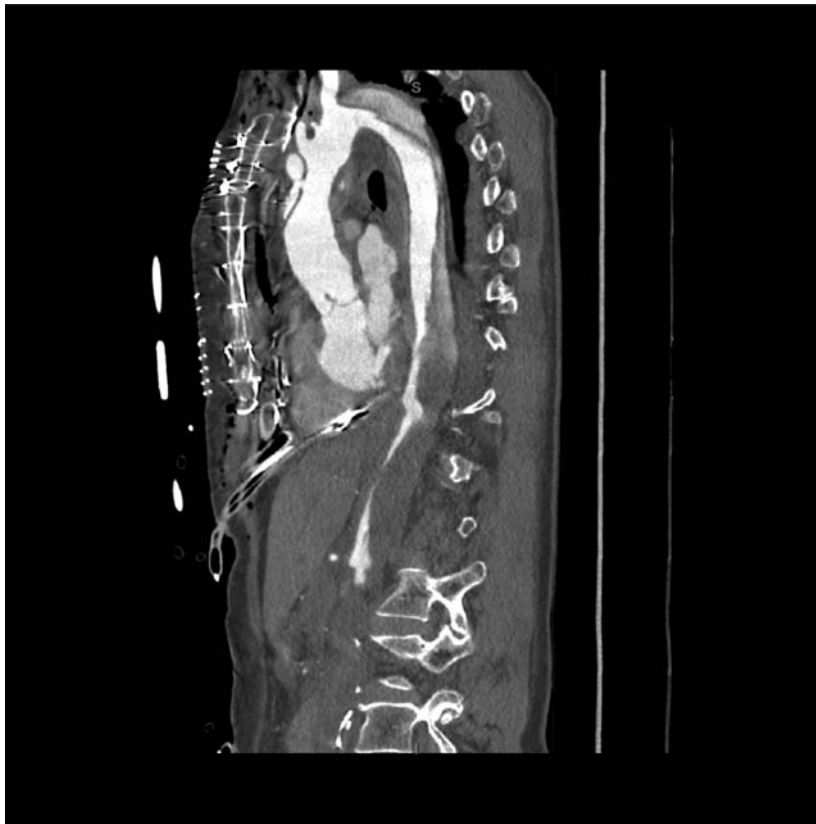


Fig. 1 Angio-computed tomography scan on sagittal view showing an acute Type A aortic dissection with complete malperfusion of inferior mesenteric and iliac arteries.

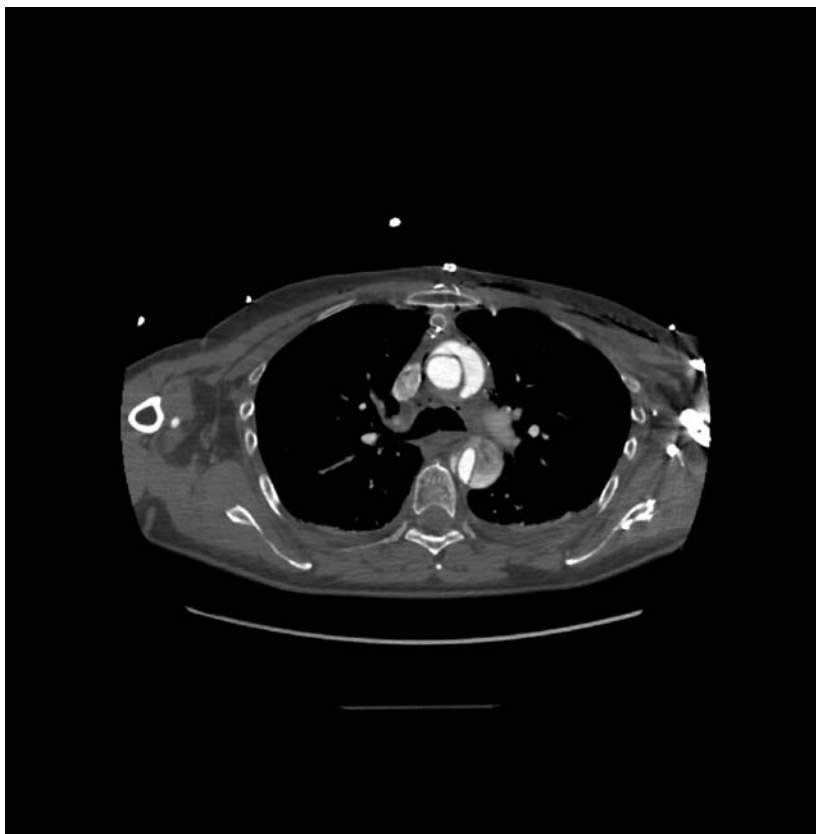

Fig. 2 Angio-computed tomography scan on axial view showing an acute Type A aortic dissection with compression of the true lumen.

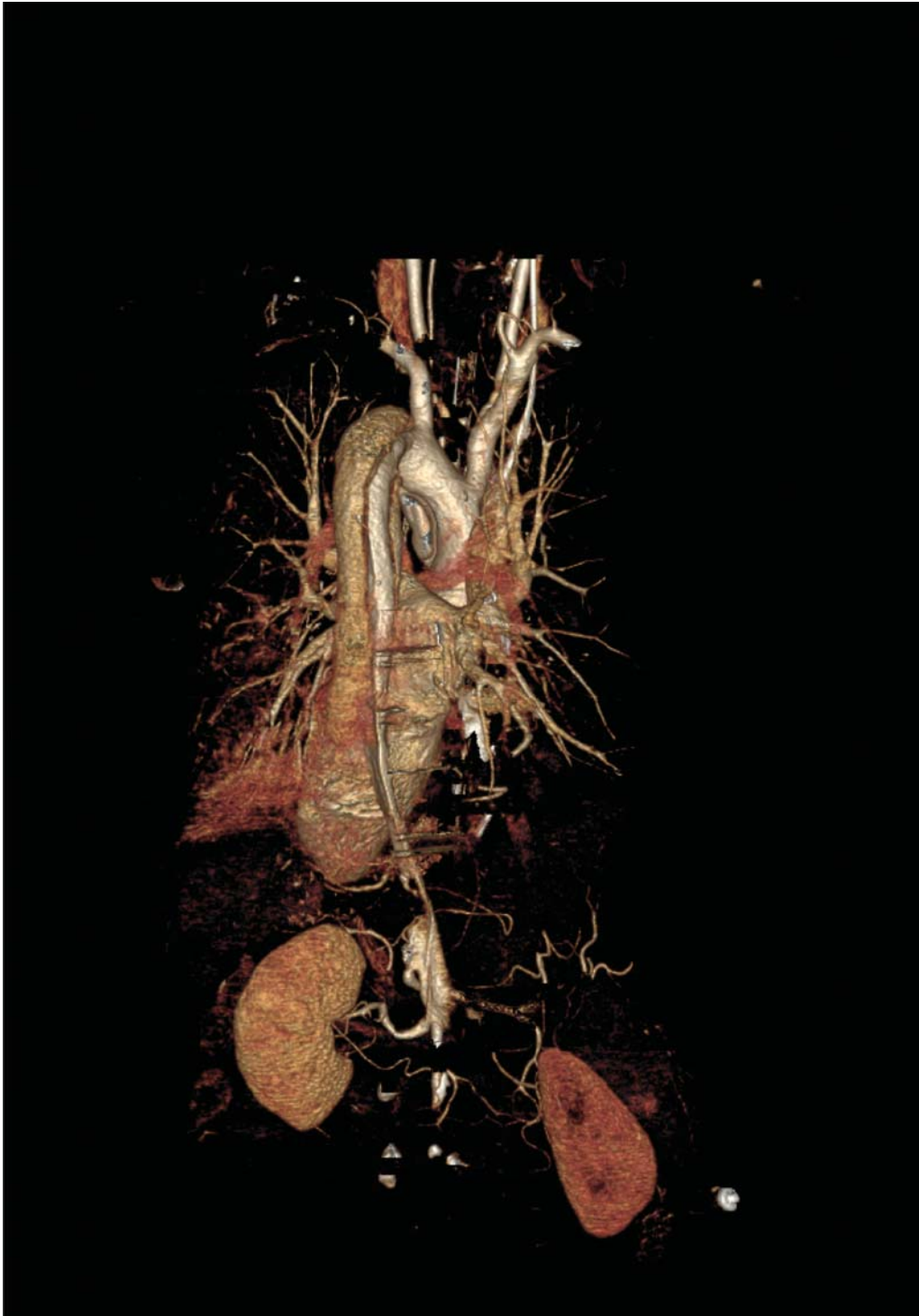

Fig. 3 Three-dimensional volume rendering showing acute Type A aortic dissection.

Funding

None.

Conflict of Interest

The authors declare no conflict of interest related to this article.

Acknowledgments

None.

References

- 1 Rylski B, Hoffmann I, Beyersdorf F, et al. Iatrogenic acute aortic dissection type A: insight from the German Registry for Acute Aortic Dissection Type A (GERAADA). *Eur J Cardiothorac Surg* 2013;44(02):353–359, discussion 359
- 2 Narayan P, Angelini GD, Bryan AJ. Iatrogenic intraoperative type A aortic dissection following cardiac surgery. *Asian Cardiovasc Thorac Ann* 2015;23(01):31–35

- 3 Still RJ, Hilgenberg AD, Akins CW, Daggett WM, Buckley MJ. Intraoperative aortic dissection. *Ann Thorac Surg* 1992;53(03):374–379, discussion 380
- 4 Shea NJ, Polanco AR, D'Angelo A, Bethancourt CN, Sanchez J, George J et al. Improving Outcomes of Iatrogenic Type A Aortic Dissection during Cardiac Surgery. *Aorta (Stamford)* 2019;7(04):115–120
- 5 Januzzi JL, Sabatine MS, Eagle KA, et al; International Registry of Aortic Dissection Investigators. Iatrogenic aortic dissection. *Am J Cardiol* 2002;89(05):623–626
- 6 Li J, Guan X, Gong M, Wang X, Zhang H. Iatrogenic acute aortic dissection induced by off-pump coronary artery bypass grafting: A case report and review of the literature. *Medicine (Baltimore)* 2017;96(51):e9206

Editor's Comments

The authors did an excellent initial aortic root operation before this extensive arch, thoracic, and abdominal aortic dissection developed. Another treatment alternative would have been a fenestration, done retroperitoneally at an infra-renal level. Our extensive experience with fenestration has found that this procedure is extremely effective at restoring flow to all branch vessels, both above and below the level of the fenestration. Especially with the excellent self-retaining retractors available in this era, the retroperitoneal approach for fenestration is quick, easy, and well tolerated.^{1–3}

References

- 1 Elefteriades JA, Hammond GL, Gusberg RJ, Kopf GS, Baldwin JC. Fenestration revisited. A safe and effective procedure for descending aortic dissection. *Arch Surg*. 1990;125(06):786–790.
- 2 Morales DL, Quin JA, Braxton JH, Hammond GL, Gusberg RJ, Elefteriades JA. Experimental confirmation of effectiveness of fenestration in acute aortic dissection. *Ann Thorac Surg*. 1998;66(05):1679–1683.
- 3 Elefteriades JA and Ziganshin BA. *Practical Tips in Aortic Surgery*. Springer. 2020 [In press]