

Radiographic Recognition of Tarsal Malformation in 8- to 9-Week-Old Bernese Mountain Dogs

Massimo Petazzoni¹  Francesca Briotti² Carlo M. Mortellaro² Randy J. Boudrieau³ 

¹ Clinica Veterinaria Milano Sud, Peschiera Borromeo, Milan, Italy

² Medicina Veterinaria, Università degli Studi di Milano, Milan, Italy

³ Cummings School of Veterinary Medicine, Tufts University, North Grafton, Massachusetts, United States

Address for correspondence Randy J. Boudrieau, DVM, Department of Clinical Sciences, Cummings School of Veterinary Medicine, Tufts University, 200 Westboro Road, North Grafton, MA 01536, United States (e-mail: randy.boudrieau@tufts.edu).

Vet Comp Orthop Traumatol 2020;33:451–456.

Abstract

Introduction Tarsal malformation is a skeletal malformation of unknown aetiology associated with a variety of morphologic changes to the tarsal and metatarsal bones of the dog.

Objective The aim of this study was to determine if early diagnosis and prevalence of tarsal malformation could be obtained at approximately 8 to 9 weeks of age in multiple litters of Bernese Mountain dogs.

Methods A prospective study of 51 Bernese Mountain dog puppies were evaluated from 12 litters in northern Italy. Dorsoplantar radiographic views of the tarsus were obtained at 60 ± 5 days of age. Tarsal malformation was defined as an abnormal extension of the central tarsal bone on its medial side, or the presence of ectopic bone located medially to the central tarsal bone, talus and second metatarsal bones (proximomedial, distomedial and metatarsal ossification sites respectively).

Results All puppies were found to be clinically normal. Thirty-nine of the 51 puppies showed ossification sites medial to the tarsus as defined. A metatarsal ossification was present in all dogs with either a proximo- or distomedial ossification site. No central tarsal bone extensions were observed. The remainder of the tarsometatarsal joints were normal.

Clinical Significance Tarsal malformation can be identified in the 8- to 9-week-old Bernese Mountain dog. The clinical significance of tarsal malformation remains to be determined, either as an incidental finding or a precursor to the development of other clinically relevant and related issues in the tarsus.

Keywords

- ▶ tarsal malformation
- ▶ Bernese Mountain dog
- ▶ central tarsal bone
- ▶ ectopic bone
- ▶ radiographic evaluation

Introduction

Tarsal malformation is a skeletal malformation of unknown aetiology involving the tarsal and metatarsal bones of dogs.^{1–4} Tarsal malformation has been diagnosed in medium, large and giant breed dogs including the Bernese Mountain dog, Rottweiler, Saint Bernard, Pyrenean Mountain dog, Great Dane, Australian Shepherd dog, Briard and Spinone Italiano.^{1–4} Some authors suggest that tarsal malformation might be a congenital skeletal deformity.^{1,3,4} In newborn

puppies, tarsal deformities are characterized by anomalies of the shape and number of bones in the distal row of the tarsus.¹ The tarsal malformation deformity has been associated with hindlimb dew claws (extra digit) and various anomalies of the tarsal bones, such as extra ossification sites associated with the central tarsal bone, or varying degrees of fusion of the distal row of tarsal bones.^{1,2} In adults, a large curved bone seems to be an extension of the central tarsal bone on the medial side of the proximal row of tarsal

received

September 17, 2019

accepted after revision

May 16, 2020

published online

August 10, 2020

© 2020 Georg Thieme Verlag KG
Stuttgart · New York

DOI <https://doi.org/>

10.1055/s-0040-1714416.

ISSN 0932-0814.

bones.¹⁻³In the Pyrenean Mountain dog, it is often associated with the presence of a well-developed first digit.¹ A vestigial first metatarsal bone was described in a Saint Bernard in the medial aspect of the tarsal bones.⁴ Tarsal malformation is generally bilateral and often thought to be of no clinical significance.^{3,4} Some cases, however, present with mild lameness, or simply a tarsus that is grossly abnormal in size and/or shape.¹ Tarsal malformation has also been associated with metatarsal rotation, a condition characterized by a lateral torsion of the hind paw such that the dorsal surface of the paw is turned laterally to varying degrees.² It is unknown whether tarsal malformation leads to the development of metatarsal rotation in some dogs; nevertheless, all dogs reported with metatarsal rotation have tarsal malformation.^{2,5-9}The dorsoplantar radiographic view is the most useful for detecting the various abnormalities consistent with descriptions of tarsal malformation.^{2,5,6}

The purpose of the present study was to determine if a diagnosis of tarsal malformation was possible at ~60 days of age in multiple litters of Bernese Mountain dogs in northern Italy, and to determine the prevalence of tarsal malformation in this population.

Materials and Methods

Dogs were considered to be affected by tarsal malformation if a malformation of the central tarsal bone and/or metatarsal bone(s) was present at 60 ± 5 days based upon a dorsoplantar radiographic projection of the tarsus.

Inclusion Criteria

Twelve unrelated litters of Bernese Mountain dogs were included in this study. These dogs were all located in northern Italy within 20 km of the two clinics (Clinica Veterinaria Nord Milano; and Ambulatorio Veterinario Associato Di Dott.ssa Billa E Dott.ssa Maconi, where the clinical and radiographic examinations were performed^a) and included all breeders of this breed in this locale. All breeders agreed to the study and provided their informed consent to participate. Inclusion in the study, and the time interval selected, was based upon the puppies age and associated logistics agreed upon by the breeders. These included timing of the radiographs of all dogs in their litters only after initiating vaccinations at 6 to 8 weeks of age as the maternal antibody protection declined at this time, thus supplementing their natural resistance to disease as acquired immunity began to develop. Furthermore, all dogs were not weaned until 55 days, and the puppies were not permitted to be separated from the bitch until after weaning. Lastly, radiographs were to be obtained only with manual restraint (no sedation or anaesthesia) just prior to being adopted by their new owners. Based upon these parameters, radiographic examinations were to be performed at 60 ± 5 days of age. This time window was selected for uniformity amongst all dogs.

^a M.P. was a consultant to both of these clinics at the time of the study.

Clinical Examination

All puppies underwent a clinical examination; group behaviour/interaction/observation was used to assess for any evidence of lameness, followed by an orthopaedic examination of the limbs, with the focus on the hock joints and paws.

Radiographic Evaluation

Bilateral dorsoplantar radiographic projections of the hock were obtained. All puppies were physically restrained (without sedation) in a sitting position (► Fig. 1). A malformation of the central tarsal bone was defined as a large curved bone that appeared to be an extension of this bone on its medial side, or the presence of separate ectopic bone located medially to the central tarsal bone, talus and second metatarsal bones (► Fig. 2). Appearance of ectopic bone formation was defined as an extra ossification site. For each tarsus, malformation of the central tarsal bone and the number and location of ossification sites medial to the central tarsal bone, talus and 2nd metatarsal bones were recorded; furthermore, any supernumerary digits or abnormalities of the metatarsal bones were noted. For the purposes of this study, these findings were consistent with our definition of affected versus non-affected dogs (► Fig. 2).



Fig. 1 Cartoon drawing demonstrating manual restraint and positioning to perform the dorsoplantar radiographic view of the tarsus in these dogs. (Artist: Flaminio Addis; copyright Francesca Briotti, 2003) Source: Modified and reprinted with permission from Petazzoni M. Metatarsal rotation in the dog – Early diagnosis. Proceedings of the 2009 American College of Veterinary Surgeons Veterinary Symposium; October 8–10, 2009; Washington DC; pp 327–329.

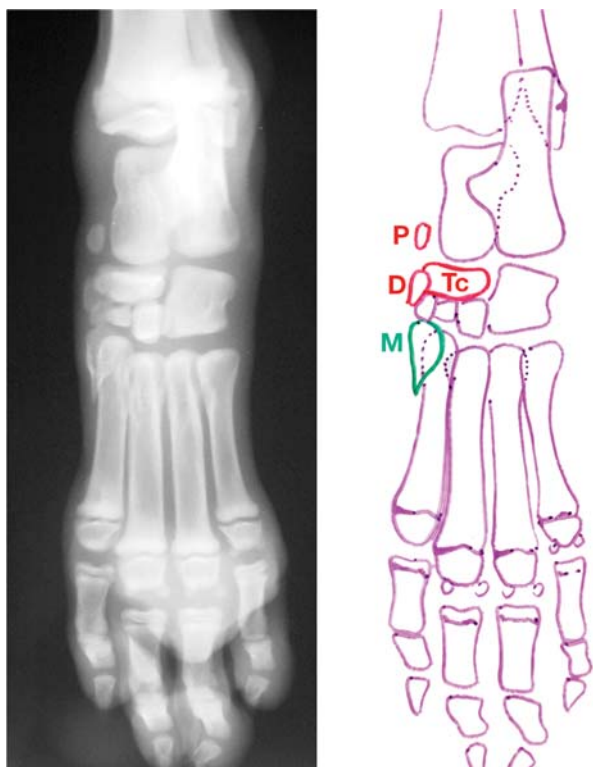


Fig. 2 (Left) Dorsoplantar radiographic view and (Right) corresponding line drawing of the tarsal joint. Central tarsal bone (Tc), proximomedial ossification and distomedial ossification sites are outlined in red (P and D respectively); metatarsal ossification site is outlined in green (M; refer to ►Table 1).

Source: Modified and reprinted with permission from Petazzoni M. Metatarsal rotation in the dog – Early diagnosis. Proceedings of the 2009 American College of Veterinary Surgeons Veterinary Symposium; October 8–10, 2009; Washington DC; pp 327–329.

Results

Fifty-one Bernese mountain dog puppies between 56 and 65 days of age were examined (mean 60.3; median 60; standard deviation 2.2 days). None of these litters were related, as attested to by the breeders after a review of their pedigrees. Twenty-four of 51 puppies were male, and 27/51 were female. All puppies were found to be clinically normal. No lameness was observed in any dog. There were no gross abnormalities noted at the level of the tarsometatarsal joints.

Radiographic findings included ossification site in the proximomedial aspect of the tarsal joint adjacent to the central tarsal bone; ossification site in the distomedial aspect of the tarsal joint adjacent to the central tarsal bone; ossification site in the medial aspect of the metatarsal bones (►Fig. 2). None of the puppies displayed an 'extension' of the central tarsal bone.¹

Thirty-nine of 51 puppies showed ossification sites medial to the central tarsal bone, talus and metatarsal bones. Twelve of 51 puppies were considered normal: 18/24 male puppies and 21/27 female puppies were affected. Thirty-four of 51 dogs were bilaterally affected, with 5/51 dogs affected unilaterally: the right and left tarsi were affected in three and two dogs respectively; Twenty-eight out of 34 bilaterally affected pup-

pies were symmetric (same ossification sites right and left), while 6/34 were asymmetric. All the puppies presenting unilateral or bilateral, proximal or distal or both ossification sites medial to the central tarsal bone also presented an ossification site medial to the metatarsal bones (►Table 1).

Discussion

We have demonstrated that tarsal malformation can be diagnosed at a very young age—identified in three quarters of the dogs in this study at 8 to 9 weeks of age. All radiographic changes found were similar to those previously described in adult dogs in the various reports.^{1–9} Interestingly, we observed ectopic bone formation(s), assumed to be a separate site of ossification adjacent to the central tarsal bone based upon our definition; on the other hand, we did not observe any 'extension' of the central tarsal bone that has been reported in a variety of breeds in older dogs.^{1–9}

As these puppies were not re-evaluated at a later time, we cannot rule out that the unaffected dogs did not also develop tarsal malformation in the future; thus, a higher prevalence cannot be excluded in adulthood; however, it is unlikely that new ossification sites would appear later in life, as all bones of the tarsus are present by 40 days.^{10–14} Our study demonstrated that there was a very high prevalence of tarsal malformation in the Bernese Mountain dog puppies that we examined. Furthermore, at the time of examination, none of the puppies with tarsal malformation demonstrated any clinical issues with the hind limbs.

A review of the normal embryological development of the bones in the tarsus is beyond the scope of this discussion; however, suffice it to state that both the calcaneus and talus are radiographically present at birth in all breeds described, and although there is some breed variation, all other ossification sites are radiographically present by 21 to 40 days of age.^{10–14} As such, the timing of the radiographs of our study coincides with all centres of ossification being present/visible, thus allowing us to note the appearance of any ectopic areas present, which are not described in the literature of normal dogs. As a point of reference for comparison, we include radiographs of both a normal Bernese Mountain dog and German Shepherd dog at 60 days of age (►Fig. 3). We surmise that the new bone formation observed medial to the central tarsal bone likely fuses with this bone to give the characteristic 'banana-shaped' appearance (the 'extension') observed in the adult dog. Because of these findings, we suggest that dogs should be re-evaluated radiographically during growth to identify any possible modification/fusion at this level. We cannot, however, make any broad generalizations, as we were not able to follow these dogs as they were dispersed to their new homes; the owners (which at the time of examination were yet to be identified) were not part of the study protocol. As such, future evaluation of these dogs was not possible and thus not part of our study.

These findings are supportive of the comments made in the scant literature that tarsal malformation appears to be an incidental finding.^{1,3,4} However, since none of these puppies were re-evaluated at a later age, we cannot rule out that

Table 1 Signalment with summary radiographic findings of the tarsi in 8-week-old Bernese Mountain dog puppies

Litter number	Puppy number	Sex	Age (days)	Right ossification sites	Left ossification sites
1	1	Male	60	D, M	D, M
1	2	Male	60	D, M	–
1	3	Female	60	D, M	D, M
1	4	Male	60	D, M	P, D, M
1	5	Female	60	D, M	D, M
1	6	Male	60	P, D, M	P, D, M
1	7	Female	60	P, D, M	P, D, M
2	8	Female	60	D, M	D, M
2	9	Female	60	–	–
2	10	Male	60	–	–
2	11	Female	60	D, M	D, M
3	12	Male	60	D, M	–
3	13	Male	60	P, D, M	P, D, M
3	14	Female	60	D, M	D, M
4	15	Male	60	P, M	P, D, M
4	16	Female	60	P, D, M	P, M
5	17	Male	60	–	–
5	18	Male	60	P, M	P, M
5	19	Female	60	–	–
5	20	Male	60	–	P, M
5	21	Male	60	–	–
6	22	Male	65	P, D, M	P, D, M
6	23	Female	65	P, D, M	P, D, M
6	24	Female	65	P, D, M	P, M
7	25	Male	59	D, M	D, M
7	26	Female	59	D, M	D, M
8	27	Male	60	–	–
8	28	Female	60	P, D, M	P, D, M
8	29	Female	60	D, M	D, M
8	30	Female	60	D, M	D, M
8	31	Female	60	D, M	P, D, M
9	32	Female	56	–	–
9	33	Female	56	D, M	–
9	34	Female	56	–	–
9	35	Female	56	–	–
9	36	Male	56	–	–
10	37	Male	64	D, M	D, M
10	38	Male	64	D, M	D, M
10	39	Male	64	–	D, M
10	40	Male	64	D, M	D, M
10	41	Male	64	D, M	D, M
10	42	Female	64	D, M	D, M
11	43	Female	60	D, M	D, M
11	44	Female	60	D, M	D, M
11	45	Female	60	–	–

Table 1 (Continued)

Litter number	Puppy number	Sex	Age (days)	Right ossification sites	Left ossification sites
11	46	Female	60	D, M	D, M
11	47	Male	60	–	–
12	48	Male	60	D, M	P, D, M
12	49	Female	60	D, M	D, M
12	50	Female	60	D, M	D, M
12	51	Male	60	D, M	D, M

Abbreviations: D, distomedial ossification site; M, metatarsal ossification site; P, proximomedial ossification site.

Note: See ► **Fig. 2** for radiographic location of these ossification sites.

these findings remained incidental or resulted in some other developmental abnormalities, perhaps due to abnormal development within the tarsus as a result of these areas of new bone formation. For example, metatarsal rotation is considered to be a developmental condition and has been reported to occur in this same subset of dogs.² Interestingly, in all dogs reported in the literature with metatarsal rotation, all had radiographic descriptions of tarsal malformation.^{1,2,4–9} As already noted, the possible development of metatarsal rotation later in life in this group of dogs was not evaluated, as it was beyond the scope of this study; however, a reasonable argument can be made that a probable hereditary predisposition of tarsal malformation plays a role in the later development of metatarsal rotation in some dogs. The relationship between tarsal malformation and metatarsal rotation needs further investigation.

In one of the litters (dog 9, ► **Table 1**), four of five puppies were evaluated as normal. This finding and the prevalence of tarsal malformation in this breed (and the others reported in the literature) indicate that there may likely be a hereditary aetiology. We were unable to determine if there was a history in these breeding pairs (re: previous litters) for either tarsal malformation or metatarsal rotation, as this was beyond the scope of this study. We did not evaluate any of the adult breeding dogs for the evidence of tarsal malformation or metatarsal rotation; however, none were noted by the owners, and all of the adult breeding dogs were considered to be clinically normal. The latter, nevertheless, does not rule out either possibility, although dogs with a significant metatarsal rotation would be easily identified by their conformation and those more severely affected to also exhibit varying degrees of lameness (and we assume would not be considered good breeding stock).

The single dorsoplantar radiographic projection was obtained based upon our definition of tarsal malformation, as these ossifications could only be readily identified on the dorsoplantar radiographic view, and thus the mediolateral view was not used.^{2–4} In addition, obtaining a single view facilitated/speeded the process and minimized the stress of handling in these young dogs.

Multiplanar re-construction and three-dimensional construction based on computed tomography scans of the tarsus

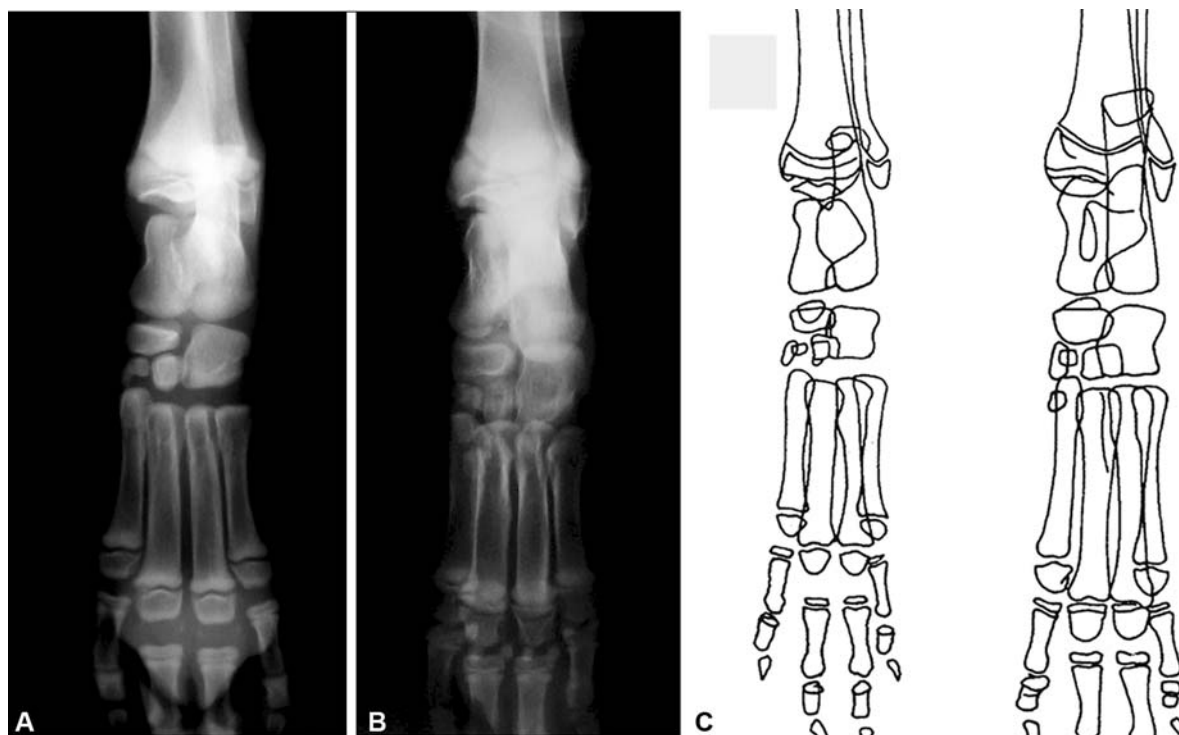


Fig. 3 Dorsoplantar radiographic views of the left tarsal joint in (A) 60-day old Bernese Mountain dog and (B) 60-day old German Shepherd dog. Notice the absence of the proximomedial, distomedial and metatarsal ossification sites (compare with **Fig. 2**). Also, notice that despite these puppies being the same age, that they are at slightly different stages of ossification, with the German Shepherd dog further along in this process. Despite these differences between breeds, all ossification sites are present and visible at this age. (C) Line drawings of canine joint morphology at 57 and 72 days (left and right respectively)

Source: Line drawings modified with permission from Thrall DF, Robertson ID. *Atlas of Normal Radiographic Anatomy and Anatomic Variants in the Dog and Cat*. 2nd ed. St. Louis: Elsevier; 2016.

might have allowed the shape of the central tarsal bone and any ossification sites to be assessed more effectively than by radiography. In addition, a magnetic resonance imaging might have provided more information about the precise anatomical location and tissue origin of the mineralization. However, both of these techniques would have required sedation or general anaesthesia but were not part of the inclusion criteria as permitted by the breeders.

As previously noted, concurrent metatarsal rotation and tarsal malformation have been reported in the literature.^{2,5-7,9} The paucity of reports appears to indicate that metatarsal rotation is not a common entity, even in the breeds reported.⁵⁻⁷ Surgical correction has been suggested only for dogs affected by severe metatarsal rotation, where the dogs exhibited an abnormal gait and/or were lame.⁵⁻⁷ The Bernese Mountain dog appears to be over-represented in these reports of surgical corrections, as this breed accounts for one-half of the 10 dogs treated for metatarsal rotation, with only the Saint Bernard accounting for more than a single case.⁵⁻⁷ These are, however, only isolated case reports and may underestimate the overall frequency of the problem, and therefore, may indicate that the Bernese Mountain dog may be predisposed to metatarsal rotation, which may be a result of the tarsal malformation.

Limitations to this study include the small sample group from a limited locale—this despite the lack of connection between all of the breeding pairs. The lack of information from a detailed breeding history, including the lack of objective details on conformation of these reportedly normal dogs

used for breeding, was problematic. In addition, without radiographic evidence to document tarsal malformation, or other possibly related issues in the breeding stock, all anecdotal assessments could be questioned. As such, it cannot be determined if the high prevalence observed is a reflection of an overall issue in the breed, or this particular subset of dogs as a result of a pre-existence of the problem. Despite the finding of a high prevalence of tarsal malformation in these dogs, it remains of unknown significance, as we cannot make any determinations of its clinical importance, for example, whether it contributes to another developmental issue. Consequently, the association between tarsal malformation and metatarsal rotation remains speculative.

Conclusion

We have demonstrated that tarsal malformation can be diagnosed in Bernese Mountain dog puppies by approximately 8 to 9 weeks of age. Despite the early identification of these changes, and their potential use for screening dogs at an early age, the clinical significance remains to be determined. Although the prevalence of tarsal malformation in this population was high, the consistent relationship with the ossification sites adjacent to the central tarsal bone and second metatarsal bone should be explored. Based upon the high prevalence of Bernese Mountain dogs with tarsal malformation, it appears that these are likely to be incidental findings, but this assumption needs to be documented. An association of tarsal

malformation with more severe deformities that requires treatment (e.g. metatarsal rotation) is proposed but requires further investigation.

Authors' Contributions

M.P. and C.M.M. contributed to conception of study, study design, acquisition of data and data analysis and interpretation. F.B. and R.J.B. contributed to acquisition of data and data analysis and interpretation. All authors drafted, revised and approved the submitted manuscript.

Funding

None.

Conflict of Interest

None declared.

Acknowledgements

Special thanks and gratitude to Simona Lissoni, Agostina Lonati, Cristina Sonzogni and Cristina Merisio of S.I.B.B. (Società Italiana Bovero del Bernese [Italian Society of Bernese Mountain dogs]) for giving us the opportunity to perform this study on tarsal malformation. We additionally thank Prof. Flaminio Addis for the cartoon drawing of

► Fig. 1.

References

- Vaughan LC. Disorders of the tarsus in the dog. II. *Br Vet J* 1987;143(06):498–505
- Bennett DB. Joints and joint diseases. In: Whittick W, ed. *Canine Orthopaedics*. Philadelphia: Lea & Febiger; 1990:804–805
- Dyce J. Congenital malformations. In: Houlton JEF, ed. *Manual of Small Animal Arthrology*. Shurdington: BSAVA; 1994:305
- Johnson KA, Watson ADJ. Skeletal diseases. In: Ettinger SJ, Feldman EC, eds. *Textbook of Veterinary Internal Medicine*. 6th ed. Philadelphia: Saunders; 2001:1894–1895
- Nelligan MR, Wheeler JL, Lewis DD, Thompson MS. Bilateral correction of metatarsal rotation in a dog using circular external skeletal fixation. *Aust Vet J* 2007;85(08):332–336
- Petazzoni M, Piras A, Jaeger GH, Marioni C. Correction of rotational deformity of the pes with external skeletal fixation in four dogs. *Vet Surg* 2009;38(04):506–514
- Boudrieau RJ, Kowaleski MP, Petazzoni M. Correction of rotational deformity of the pes with plate fixation in 5 dogs. *Scientific Presentation Abstracts*. 2011 ACVS Veterinary Symposium. Chicago, Illinois; November 3–5, 2011. *Vet Surg* 2011;40:E22
- Robins GM. Sesamoid disease and metatarsal rotation. *Aust Vet Pract* 1986;16(04):200
- Di Giancamillo M, Lombardo R, Mortellaro CM, Leonardi L. Malformazioni tarsiche associate a extrarotazione del piede nel cane: Segnalazione di due casi clinici {Tarsal malformations associated with outward rotation of the foot: Two case reports}. *Arch Vet Ital* 1994;45:271–278
- Zoetis T, Tassinari MS, Bagi C, Walthall K, Hurtt ME. Species comparison of postnatal bone growth and development. *Birth Defects Res B. Dev Reprod Toxicol* 2003;68(02):86–110
- Hare WC. The ages at which the centers of ossification appear roentgenographically in the limb bones of the dog. *Am J Vet Res* 1961;22:825–835
- Chapman WL Jr. Appearance of ossification centers and epiphysal closures as determined by radiographic techniques. *J Am Vet Med Assoc* 1965;147(02):138–141
- Bressou C, Pomriaskinsky-Kobozieff NA, Kobozieff N. Radiological study of skeletal ossification in the foot of the dog from birth to adult age.[French] Etude radiologique de l'ossification du squelette du pied du chien aux divers stade de son evolution, de la naissance à l'age adulte. *Rec Med Vet Ec Alfort* 1957;133:449–464
- Thrall DF, Robertson ID. Basic imaging principles and physeal closure time. In: *Atlas of Normal Radiographic Anatomy and Anatomic Variants in the Dog and Cat*. 2nd ed. St. Louis: Elsevier; 2016:1–19