



# Posttraumatic Arachnoid Cyst in the Thoracic Spine with Medullary Compression: Case Report

## *Cisto aracnóide após trauma na coluna torácica com compressão medular: Relato de caso*

Igor de Barcellos Zanon<sup>1</sup>  Michel Kanas<sup>2</sup>  Marcos Augusto Stávale Joaquim<sup>2</sup>   
 Délio Eulálio Martins<sup>2</sup>  Marcelo Wajchenberg<sup>2</sup>  Nelson Astur<sup>1,2</sup> 

<sup>1</sup>Spine Group, Orthopedics and Traumatology Department “Pavilhão Fernandinho Simonsen”, Santa Casa de Misericórdia de São Paulo, São Paulo, SP, Brazil

<sup>2</sup>Orthopedics and Traumatology Department, Hospital Israelita Albert Einstein, São Paulo, São Paulo, SP, Brazil

Address for correspondence Igor de Barcellos Zanon, MD, Departamento de Ortopedia e Traumatologia, 2° andar, Sala do Grupo de Afeções da Coluna Vertebral, Rua Dr. Cesário Motta Júnior, 112, Vila Buarque, São Paulo, SP, Brazil (e-mail: igorzanon@gmail.com).

Rev Bras Ortop 2021;56(1):114–117.

### Abstract

Arachnoid cysts are rare; they can occur at all levels of the dural sac, and can have a congenital, traumatic, iatrogenic or inflammatory origin. In the present article, we report a patient presenting a compressive thoracic myelopathy due to an unusual intradural arachnoid cyst with posttraumatic manifestation and its resolution, in addition to a literature review on the subject. These cysts mainly occur at the thoracic spine, followed by the lumbar, lumbosacral and thoracolumbar spines. Traumatic cysts are caused by an injury to the inner dural layer. These lesions produce neurological deficits through a mass effect on the spinal cord. Concomitant compressive myelopathy is even rarer. In case of myelopathy, cyst resection or drainage is the treatment of choice, and it must be performed immediately. Although rare, arachnoid cysts can be a complication of spine fractures; as such, orthopedists and neurosurgeons, who commonly see these injuries, must be prepared for this unusual situation.

### Keywords

- ▶ arachnoid cysts
- ▶ spinal cord injuries
- ▶ spinal cord compression

### Resumo

Cistos aracnóides são raros, podem ocorrer em todos os níveis do saco dural, e sua origem pode ser congênita, traumática, iatrogênica ou inflamatória. Neste artigo, relatamos o caso de uma paciente com mielopatia torácica compressiva decorrente de um cisto aracnoide intradural incomum, de manifestação pós-traumática, assim como sua resolução, além de realizar revisão da literatura sobre o tema. A principal localização é na coluna torácica, seguida das colunas lombar, lombossacra e toracolumbar. O cisto com origem traumática é causado por lesão da camada interna da

received  
September 29, 2019  
accepted  
May 5, 2020  
published online  
September 30, 2020

DOI <https://doi.org/10.1055/s-0040-1714225>.  
ISSN 0102-3616.

© 2020. Sociedade Brasileira de Ortopedia e Traumatologia. All rights reserved.

This is an open access article published by Thieme under the terms of the Creative Commons Attribution-NonDerivative-NonCommercial-License, permitting copying and reproduction so long as the original work is given appropriate credit. Contents may not be used for commercial purposes, or adapted, remixed, transformed or built upon. (<https://creativecommons.org/licenses/by-nc-nd/4.0/>)

Thieme Revinter Publicações Ltda., Rua do Matoso 170, Rio de Janeiro, RJ, CEP 20270-135, Brazil

**Palavras-chave**

- ▶ cistos aracnóides
- ▶ traumatismos da medula espinhal
- ▶ compressão da medula espinhal

dura-máter. Essas lesões produzem déficit neurológico por meio de efeito de massa sobre a medula espinhal. A existência de mielopatia compressiva associada é mais rara ainda. A ressecção ou drenagem dos cistos na vigência de mielopatia deve ser imediata, sendo o tratamento de escolha. Apesar de raros, podem ser uma complicação de fraturas da coluna vertebral que são muito comuns na prática de ortopedistas e neurocirurgiões, que devem estar preparados para essa situação incomum.

**Introduction**

Arachnoid cysts are rare; these injuries can occur at all levels of the dural sac, and can have congenital, traumatic, iatrogenic or inflammatory origin.<sup>1,2</sup> Cysts are believed to form due to herniation of the arachnoid membrane through a dura-mater defect. Traumatic cysts are even rarer, and are caused by penetrating trauma, spinal fractures associated with dural lesions by bone fragments, and intraoperative iatrogenic dural injuries.<sup>3</sup> The most common sites for the cyst ostium are the entry point of the dorsal root into the dural sac and the dural midline.<sup>1</sup> The clinical presentation ranges from asymptomatic cases to pain, weakness, paresthesia and paralysis due to neural compression. The imaging evaluation includes computed tomography (CT), myelography and magnetic resonance imaging (MRI). The surgical intervention, when required, consists of primary closure of the dural defect through a posterior approach, accompanied by laminectomy and/or costotransversectomy.<sup>1</sup>

Although rare, arachnoid cysts can be a complication of spinal fractures, which are commonly seen by orthopedists and neurosurgeons; as such, all physicians must be aware of these lesions.

In the present article, we report a case of a patient presenting compressive thoracic myelopathy due to an unusual intradural arachnoid cyst with posttraumatic manifestation, its resolution, and a literature review on the subject.

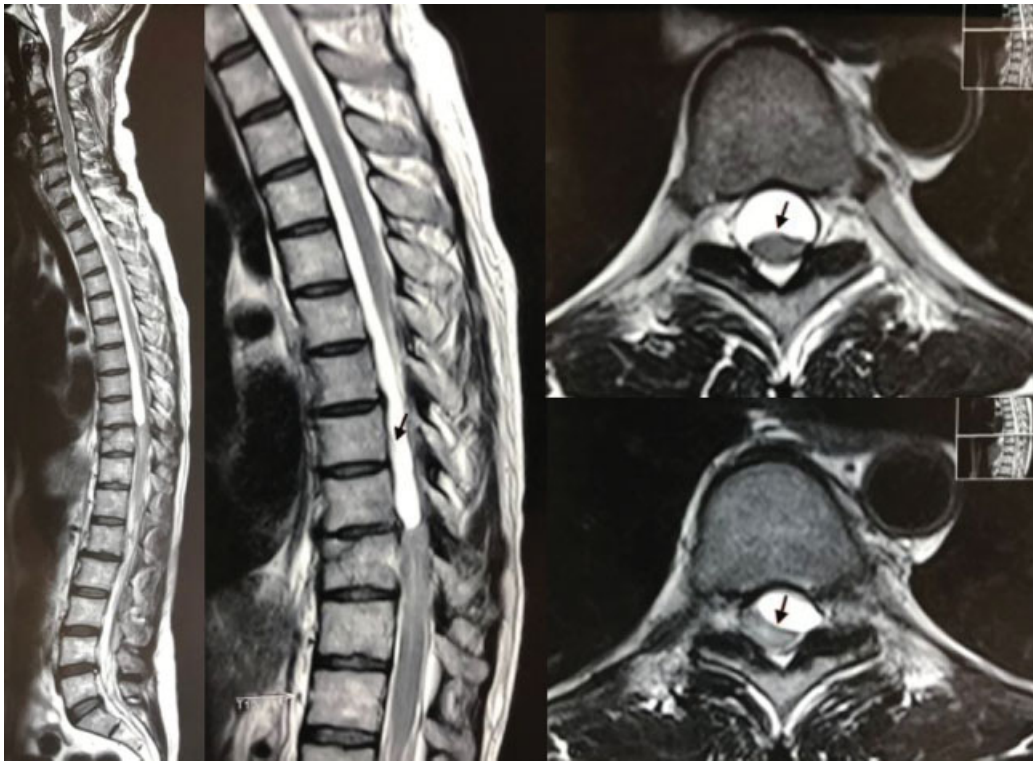
**Case Report**

A 46-year-old female patient had been in a car accident in the previous 7 months, and suffered a compressive fracture of the tenth thoracic vertebra, type B (A1) according to the Arbeitsgemeinschaft für Osteosynthesefragen (Working Community for Osteosynthesis Issues, AO) group classification.<sup>4</sup> Back then, emergency care was performed at another hospital, with conservative treatment of the fracture using a thoracolumbar orthosis. After three months, the patient was walking with increasing difficulty and developed severe spastic paraparesis and an inability to walk in the last month. When the patient came to our outpatient service, she had grade-III motor strength in the left lower limb and hypoaesthesia distal to the L1 dermatome. In addition, she presented exacerbation of the deep-tendon reflexes, a positive Babinski sign, and inexhaustible clonus. The results of the routine laboratory tests were within normal range. Thoracic spine radiographs showed no acute osteoarticular changes or fracture sequelae. The MRI showed: an old fracture of the

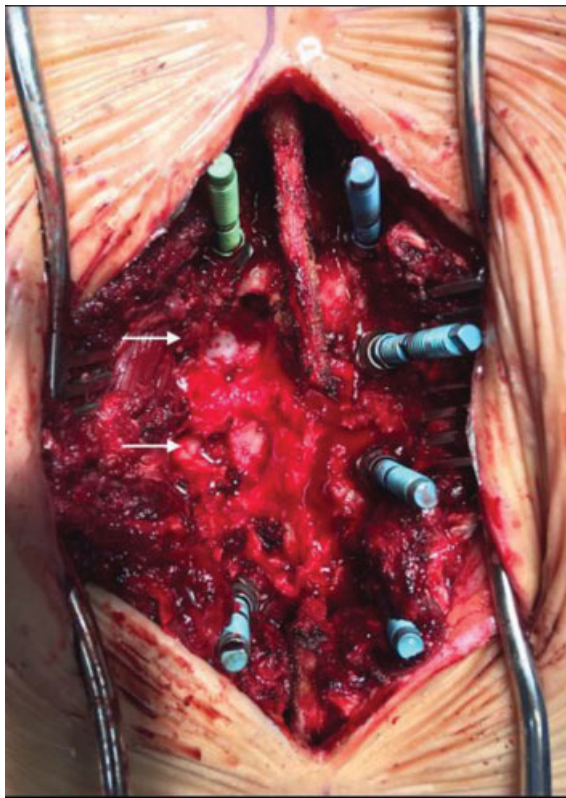
T10 vertebral body sparing the anatomy; widening of the space between the T9 and T10 spinous processes, suggesting chronic ligament rupture; alteration of the spinal cord signal at the T9, T10 and T11 levels, consistent with myelomalacia; and posterior adhesion of the spinal cord at the T7-T9 level and anterior adhesion at the T9-T12 level, associated with adhesive arachnoiditis and a ventral arachnoid cyst at the vertebral canal in these levels, posteriorly dislocating the cord (▶ **Figure 1**). In the same week, the patient underwent a surgical decompressive treatment through a posterior approach, accompanied by laminectomy and left costotransversectomy in T9 and T10 for the anterior approach to the vertebral canal. An anterolateral durotomy was then performed with a direct approach to the arachnoid cyst for drainage and repair with 5-0 nylon suture, followed by stabilization and arthrodesis with pedicle screws and pins from T8 to T11 (▶ **Figures 2, 3 and 4**). No orthosis was required, and rehabilitation began on the first postoperative day. The neurological deficit gradually improved in about a week, with recovery of the strength of the lower limbs and sensitivity. Six months later, there was residual ataxia, but the patient walked with no assistance or orthosis. There were no complications related to the surgical site. The follow-up tests showed adequate position and alignment of the fused segment, as well as bone healing (▶ **Figure 5**).

**Discussion**

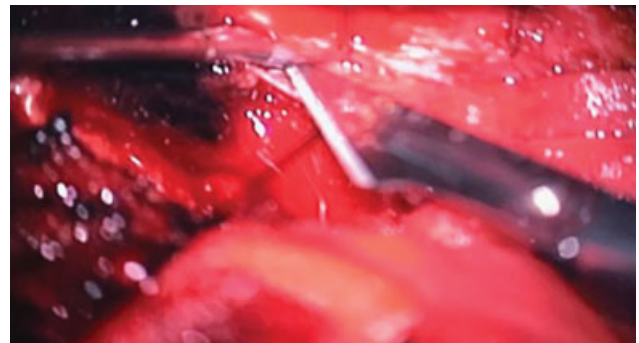
While arachnoid cysts are rare, concomitant compressive myelopathy is even rarer.<sup>2,5,6</sup> The frequent use of MRI scans increased the reports of these injuries.<sup>6</sup> Most cases have an idiopathic origin and are asymptomatic.<sup>5</sup> Among the potential causes, posttraumatic injuries, as presented here, are rare. Their prevalence is not yet available in the literature, probably due to the fact that asymptomatic cases are not interesting enough to be published, and only cases with concomitant myelopathy are reported.<sup>7</sup> Most arachnoid cysts are located in the thoracic spine, followed by the lumbar, lumbosacral and thoracolumbar spines.<sup>8</sup> Posttraumatic cysts are caused by a defect in the inner dural layer.<sup>5</sup> Ventral cysts can cause weakness and myelopathy, while dorsal cysts present with neuropathic pain and paresthesia.<sup>7</sup> The symptomatology differs because ventral lesions can compress the territory of the anterior spinal artery, leading to weakness or myelopathy, while dorsal lesions locally compress the spinal tracts, resulting in radiculopathy and pain.<sup>9</sup> Failure in treating the cause of the cyst can lead to recurrences, whose frequency is still unknown.<sup>3</sup> Myelography and CT scans reveal compression of



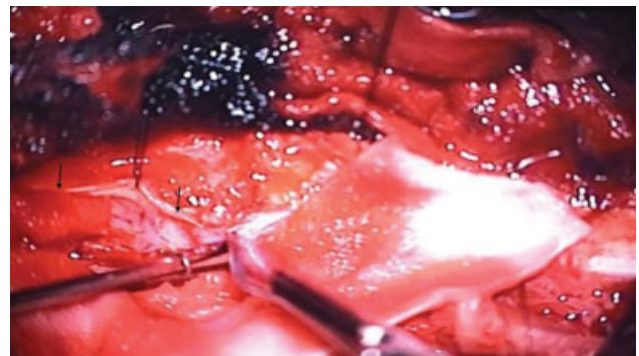
**Fig. 1** Sagittal T2-weighted magnetic resonance imaging showing an old fracture at the T10 vertebral body; space widening between the T9-T10 spinous processes, suggesting chronic ligament rupture; alteration of the spinal-cord signal at the T9, T10 and T11 levels, consistent with myelomalacia; posterior adhesion of the spinal cord at the T7-T9 level, and anterior adhesion at the T9-T12 level, associated with adhesive arachnoiditis and an arachnoid cyst at these levels. The white arrows show the boundaries of the cyst and posterior spinal adherence.



**Fig. 2** Laminectomy and costotransversectomy (white arrows) after the insertion of the pedicle screws at the T8 and T11 levels to approach the arachnoid cyst and perform the subsequent stabilization.

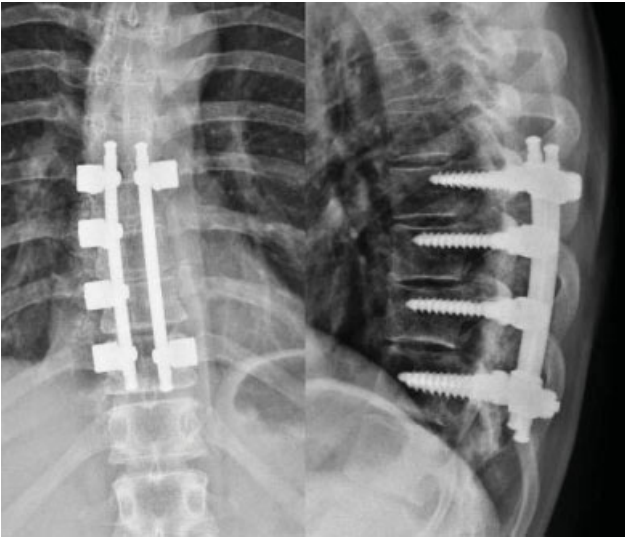


**Fig. 3** Microscope image showing durotomy and cyst drainage at the T9 and T10 levels.



**Fig. 4** Repair of arachnoid cyst using primary, 5-0 non-absorbable nylon suture. The arrows highlight the edge of the durotomy to approach the cyst.





**Fig. 5** Posterolateral and lateral radiographs of the thoracic spine at the end of the procedure, showing adequate position and alignment of the pedicle screws.

the structures adjacent to the cyst and the site of communication between the lesion and the dural sac. The MRI shows a mass effect on the adjacent structures, revealing a hypersignal on the cerebrospinal fluid in T2-weighted images.<sup>1</sup> Radical cyst removal is the treatment of choice; if not feasible due to technical limitations, the cyst must be drained.<sup>4,6–10</sup> Hemilaminectomy sparing the posterior-ligament complex was performed in most cases reported in the literature; it is sufficient to approach the cyst, avoiding complications such as deformity and instability, as well as the need for additional stabilization. In this case, laminectomy was associated with a two-level costotransversectomy due to the ventral location of the cyst and the need to approach it without dislocating the spinal cord. Non-absorbable wires can be used, and, in cases of major failures, complemented by covering with fat tissue, fascia, dural substitute or fibrin sealant.<sup>1,2,5</sup> In most published

reports, the patients evolved with total improvement in the neurological deficit and the myelopathy after surgery.<sup>1,3,7,9</sup> Since this is a rare condition, with few publications and a low level of evidence, the reproducibility in the clinical practice and the discussion regarding treatment options are limited.

Arachnoid cysts are rare lesions that can produce neurological deficit through a mass effect on the spinal cord. In case of myelopathy, the treatment of choice is cyst resection or drainage, which must be performed immediately.

#### Conflict of Interests

The authors have no conflict of interests to declare.

#### References

- 1 Yanni DS, Mammis A, Thaker NG, Goldstein IM. Traumatic fracture of thin pedicles secondary to extradural meningeal cyst. *J Surg Tech Case Rep* 2011;3(01):40–43
- 2 Shibata T, Nakamura H, Yamano Y. Intradural arachnoid cyst associated with thoracic spinal compression fracture: 7-year follow up after surgery. *Spinal Cord* 2001;39(11):599–601
- 3 Hernández-León O, Pérez-Nogueira FR, Corrales N. [Postraumatic epidural arachnoid spinal cyst: case report]. *Neurocirugía (Astur)* 2011;22(03):267–270
- 4 Vaccaro AR, Oner C, Kepler CK, et al. AOSpine Spinal Cord Injury & Trauma Knowledge Forum. AOSpine thoracolumbar spine injury classification system: fracture description, neurological status, and key modifiers. *Spine* 2013;38(23):2028–2037
- 5 Chen HJ, Chen L. Traumatic interdural arachnoid cyst in the upper cervical spine. Case report. *J Neurosurg* 1996;85(02):351–353
- 6 Alvisi C, Cerisoli M, Giulioni M, Guerra L. Long-term results of surgically treated congenital intradural spinal arachnoid cysts. *J Neurosurg* 1987;67(03):333–335
- 7 Levin TL, Zimmerman RD, Lieberman H. Intradural spinal arachnoid cyst. Case report. *Clin Imaging* 1990;14(03):245–247
- 8 Kong WK, Cho KT, Hong SK. Spinal extradural arachnoid cyst: a case report. *Korean J Spine* 2013;10(01):32–34
- 9 Wang MY, Levi AD, Green BA. Intradural spinal arachnoid cysts in adults. *Surg Neurol* 2003;60(01):49–55, discussion 55–56
- 10 Kendall BE, Valentine AR, Keis B. Spinal arachnoid cysts: clinical and radiological correlation with prognosis. *Neuroradiology* 1982;22(05):225–234