

Brainstem Bleed after Chronic Subdural Hematoma Drainage

Lamkordor Tyngkan¹ Nayil Malik¹

¹Department of Neurosurgery, Sheri-Kashmir- Institute of Medical Sciences, Srinagar, Jammu and Kashmir, India

Address for correspondence Dr. Nayil Malik, MS, MCh, Department of Neurosurgery, Sheri-Kashmir- Institute of Medical Sciences, Srinagar 190011, India (e-mail: nayilkhursh@gmail.com).

Indian J Neurotrauma:2021;18:66–68

Abstract

Keywords

- ▶ chronic subdural hematoma
- ▶ head injury
- ▶ burr hole evacuation
- ▶ postoperative complications
- ▶ brainstem bleed

Chronic subdural hematoma (CSDH) is one of the most frequent benign neurosurgical pathologies. Burr hole drainage is known to be safe, with low-morbidity and low-mortality rates. However, postoperative complications have been reported. We report the case of a 40-year-old lady who suffered a fatal brain stem hemorrhage after burr hole drainage for unilateral chronic SDH. Rapid decompression or sudden increase in cerebral blood flow were the probable factors for her brainstem bleed. Therefore, a slow rate of evacuation of CSDHs and maintenance of a correct blood pressure perioperatively are recommended to prevent serious complications.

Introduction

Chronic subdural hematoma (CSDH) is a frequently encountered neurosurgical condition, especially in the elderly, with an incidence of 50 out of 100,000 and mortality of 0.5 to 4%.^{1,2} Burr hole drainage is the surgical modality of choice for the evacuation of CSDH. This technique is safe and easy to perform.³ However, postoperative complications, including cerebral edema, hematoma recurrence, subdural empyema, tension pneumocephalus, and intracranial hemorrhage at other sites, have been reported with variable frequencies.^{4,5} Brainstem bleeding secondary to this surgery is extremely rare, as so far only seven cases have been reported in the literature.⁶⁻¹²

Case Description

A 40-year-old lady with no known comorbidities presented to us with progressive worsening of her sensorium for a duration of 1 day. She had accidentally hit her head with a wall approximately 2 weeks prior to her presentation. On neurological examination, she had a Glasgow coma scale (GCS) score of 9 with left anisocoria. CT scan head (▶ **Fig. 1**) showed a left 1.2 cm thick frontoparietal subdural hematoma (SDH) with mass effect and midline shift of 1 cm. She underwent burr hole drainage of

the hematoma with a subdural drain. She improved to a GCS score of 15 over a couple of hours and her anisocoria also settled. Two hours after the procedure, she developed a sudden drop in GCS from 15 to 4, with pupils bilaterally dilated and fixed. Check CT was done immediately, and it demonstrated evacuation of the SDH with specks of pneumocephalus and brainstem hemorrhage (▶ **Fig. 2**). The patient was intubated and ventilated; however, she remained comatose and died after 2 days.

Discussion

CSDH is a frequently encountered neurosurgical condition, especially in the elderly with a mortality rate of 0.5 to 4%. The highest incidence is in the fifth and sixth decades. CSDH is most commonly seen in men than women and the higher numbers in males is attributed to the males being more active than females. Headache is the most common presenting complaint.¹⁻⁵

CSDHs are usually characterized by a history of head trauma, which may even go unnoticed.^{1,2} Some cases are secondary to defective coagulation, alcohol abuse, post-lumbar puncture, etc. CSDH should be suspected in a patient who presents with an unusually persistent headache after spinal anesthesia or lumbar puncture. Anticoagulant and

published online
September 29, 2020

DOI <https://doi.org/10.1055/s-0040-1714177>
ISSN 0973-0508.

©2020. Neurotrauma Society of India.

This is an open access article published by Thieme under the terms of the Creative Commons Attribution-NonDerivative-NonCommercial-License, permitting copying and reproduction so long as the original work is given appropriate credit. Contents may not be used for commercial purposes, or adapted, remixed, transformed or built upon. (<https://creativecommons.org/licenses/by-nc-nd/4.0/>).
Thieme Medical and Scientific Publishers Pvt. Ltd. A-12, 2nd Floor, Sector 2, Noida-201301 UP, India

antiplatelet drugs have a significant association with an increased risk of CSDH.^{3,6,7}

The principal mechanism causing postoperative intracerebral hemorrhage is thought to be a sudden increase in cerebral blood flow combined with defective vascular autoregulation. But, the pathophysiology of brainstem hemorrhage following intracranial hematoma decompression is still not clear, since brain stem hemorrhage is often the cause of sudden death, so hemodynamic changes are difficult to

study. It is suggested that the brainstem hemorrhage is likely due to damaged vessels caused by increased intracranial pressure (ICP),^{8,10,13,14} Rapid alleviation of increased ICP, under conditions of elevated blood pressure, could disrupt the small injured vessels, invariably resulting in brainstem hemorrhage. Because of the mass effect caused by CSDH, the blood vessels near the brainstem get stretched and distorted. The sudden decompression tears the blood vessels surrounding the brainstem, precipitating hemorrhage.¹⁵

Physiological aging of the cerebral vascular tree is associated with poor tolerance of sudden variations in cerebral blood flow. In the elderly, the increased fragility of the small blood vessels might not be able to sustain the rapid changes in the brainstem blood flow during decompression of the SDH. Other factors responsible for brainstem hemorrhage, such as vascular malformations, bleeding tendency, and perioperative hypertension, are also some incriminating factors.¹³⁻¹⁶

To the best of our knowledge, so far only seven cases (► **Table 1**)⁶⁻¹² of brainstem hemorrhage, as a complication of surgery for CSDH, have been reported. Out of seven patients,

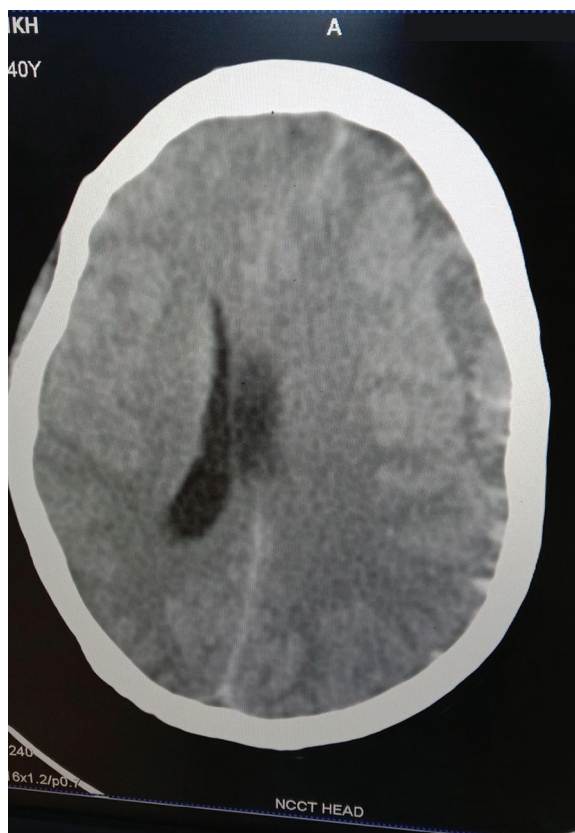


Fig. 1 Preop CT showing left frontoparietal chronic SDH. SDH, subdural hematoma.

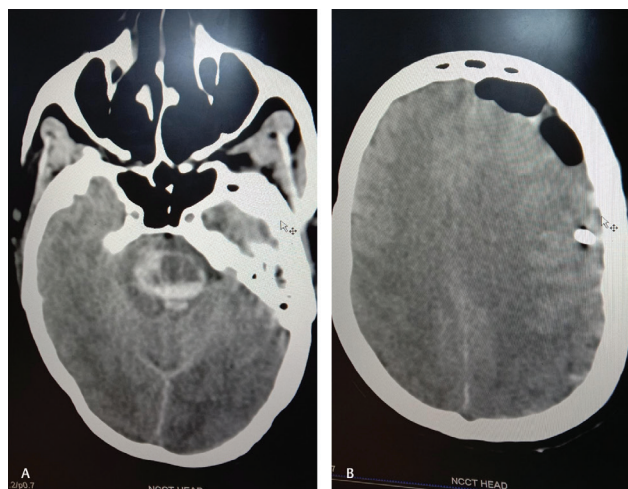

Fig. 2 Postop CT showing brainstem hemorrhage (A) and pneumocephalus with subdural drain tip in situ (B).

Table 1 Published case reports of brainstem hemorrhage postevacuation of chronic SDH

Case	Reference	Year	Age/Gender	Laterality	Treatment	Diagnosis	Outcome
1	McKissock & Bloom ⁶	1960	ND	Unilateral	Burr hole drainage	Autopsy	Died
2	Robinson ⁷	1984	59/M	Bilateral	Burr hole drainage	Autopsy	Died
3	Park et al ⁸	2009	76/M	Bilateral	Burr hole drainage	CT and MRI brain	Improved but had gait disturbance
4	Alcala-Cerra et al ⁹	2011	77/M	Bilateral	Minicraniotomy on each side	CT brain	Died
5	Rojas-Medina & Goel ¹⁰	2014	58/M	Bilateral	Burr hole drainage	CT brain	Died
6	Pratibandla et al ¹¹	2017	48/M	Bilateral	Craniotomy on left side and burr hole on right side	MRI brain	Died
7	Gader ¹²	2018	70/M	Unilateral	Burr hole drainage	CT brain	Died
8	Present case	2020	40/F	Unilateral	Burr hole drainage	CT brain	Died

Abbreviations: CT, computed tomography; MRI, magnetic resonance imaging; ND, not described; SDH, subdural hematoma.

only one patient survived. Brainstem hematoma was diagnosed in the surviving patient, as he presented with gait disturbance. We also lost our patient. In our case, the most likely explanation could be rapid decompression with tearing of perforators to the brainstem. Conclusion

Brainstem hematoma following CSDH evacuation is a very rare complication. Elderly age with a history of chronic hypertension are considered risk factors. Slow decompression and maintenance of a normal blood pressure perioperatively may prevent the occurrence of these complications.

Conflict of Interest

None declared.

References

- Nayil K, Ramzan A, Sajad A, et al. Subdural hematomas: an analysis of 1181 Kashmiri patients. *World Neurosurg* 2012;77(1):103–110
- Nayil K, Altaf R, Shoaib Y, Wani A, Laharwal M, Zahoor A. Chronic subdural hematomas: single or double burr hole—results of a randomized study. *Turk Neurosurg* 2014;24(2):246–248
- Kotwica Z, Brzeziński J. Chronic subdural haematoma treated by burr holes and closed system drainage: personal experience in 131 patients. *Br J Neurosurg* 1991;5(5):461–465
- Sambasivan M. An overview of chronic subdural hematoma: experience with 2300 cases. *Surg Neurol* 1997;47(5):418–422
- Weigel R, Schmiedek P, Krauss JK. Outcome of contemporary surgery for chronic subdural haematoma: evidence based review. *J Neurol Neurosurg Psychiatry* 2003;74(7):937–943
- McKissock W, Bloom W. Subdural haematoma. A review of 389 cases. *Lancet* 1960;1:1365–1369
- Robinson RG. Chronic subdural hematoma: surgical management in 133 patients. *J Neurosurg* 1984;61(2):263–268
- Park K-J, Kang S-H, Lee H-K, Chung Y-G. Brain stem hemorrhage following burr hole drainage for chronic subdural hematoma. *Neurol Med Chir (Tokyo)* 2009;49(5):94–97
- Alcalá-Cerra G, Gutiérrez-Paternina JJ, Niño-Hernández LM, Polo-Torres C, Romero-Ramírez H, Sabogal-Barrios R. [Intracerebral hemorrhages following drainage of chronic subdural hematomas]. *Rev Med Inst Mex Seguro Soc* 2011;49(5):547–550
- Rojas-Medina LM, Goel A. Brainstem hemorrhage secondary to evacuation of chronic subdural hematoma. *Neurol India* 2014;62(4):435–437
- Patibandla MR, Thotakura AK, Shukla D, Purohit AK, Addagada GC, Nukavarapu M. Postoperative hematoma involving brainstem, peduncles, cerebellum, deep subcortical white matter, cerebral hemispheres following chronic subdural hematoma evacuation. *Asian J Neurosurg* 2017;12(2):259–262
- Gader G, Rkhami M, Salem MB, Badri M, Bahri K, Zammel I. A rare complications of chronic subdural hematoma evacuation: brainstem hemorrhage: a case report. *Romanian Neurosurgery*. 2018;32:57
- Klintworth GK. The pathogenesis of secondary brainstem hemorrhages as studied in an experimental model. *Am J Pathol* 1965;47(4):525–536
- Marupaka SK, Sood B. Atypical Duret haemorrhages seen on computed tomography. *Emerg Med Australas* 2008;20(2):180–182
- Kim JK, Kim SW, Kim SH. Intracerebral hemorrhage following evacuation of a chronic subdural hematoma. *J Korean Neurosurg Soc* 2013;53(2):108–111
- Sousa J, Golash A, Vaz J, Chaudhary H. Spontaneous intracerebral haemorrhage following evacuation of chronic subdural hematomas. *J Clin Neurosci* 2004;11(7):794–796