







Assessment of Preoperative Endometrial Histopathological Sampling as a Predictor of Final Surgical Pathology in Endometrial Cancer

Avaliação do diagnóstico histopatológico endometrial pré-operatório como preditor do diagnóstico patológico final em câncer de endométrio

Mario Augusto Silveira Bueno Piotto¹  Gustavo Rubino de Azevedo Focchi¹ 
Renato Moretti Marques¹  Andressa Melina Severino Teixeira¹  Wagner José Gonçalves¹ 
Sergio Mancini Nicolau¹ 

¹Department of Gynecology, Escola Paulista de Medicina, Universidade Federal de São Paulo, São Paulo, SP, Brazil

Address for correspondence Mario Augusto Silveira Bueno Piotto, PhD, Rua Napoleão de Barros, 608, Vila Clementino, São Paulo, SP, 04024-002, Brazil (e-mail: mario.piotto@gmail.com).

Rev Bras Ginecol Obstet 2020;42(10):642–648.

Abstract

Objective To evaluate the agreement between the histopathological diagnoses of preoperative endometrial samples and surgical specimens and correlate the agreement between the diagnoses with the impact on surgical management and the survival of patients with endometrial adenocarcinomas.

Methods Sixty-two patients treated for endometrial cancer at a university hospital from 2002 to 2011 were retrospectively evaluated. The histopathological findings of preoperative endometrial samples and of surgical specimens were analyzed. The patients were subjected to hysterectomy as well as adjuvant treatment, if necessary, and clinical follow-up, according to the institutional protocol. Lesions were classified as endometrioid tumor (type 1) grades 1, 2, or 3 or non-endometrioid carcinoma (type 2).

Results The agreement between the histopathological diagnoses based on preoperative endometrial samples and surgical specimens was fair (Kappa: 0.40; $p < 0.001$). However, the agreement was very significant for tumor type and grade, in which a higher concordance occurred at a higher grade. The percentage of patients with lymph nodes affected was 19.2%. Although most patients presenting with disease remission or cure were in the early stages (90.5%), there were no significant differences between those patients who had a misdiagnosis (11/16; 68.8%) and those who had a correct diagnosis (25/33; 75.8%) based on preoperative endometrial sampling ($p = 0.605$).

Conclusion Our findings corroborate the literature and confirm the under staging of preoperative endometrial samples based on histopathological assessment, especially for lower grade endometrial tumors. We suggest that the preoperative diagnosis should be complemented with other methods to better plan the surgical management strategy.

Keywords

- ▶ cancer of the endometrium
- ▶ histopathological diagnosis
- ▶ diagnostic method
- ▶ endometrial cancer surgery

received
July 18, 2019
accepted
May 7, 2020

DOI <https://doi.org/10.1055/s-0040-1713802>.
ISSN 0100-7203.

Copyright © 2020 by Thieme Revinter Publicações Ltda, Rio de Janeiro, Brazil

License terms



Resumo

Objetivo Avaliar a concordância entre os diagnósticos histopatológicos de amostras endometriais pré-operatórias e cirúrgicas de pacientes com adenocarcinomas endometriais e avaliar o impacto da concordância entre os diagnósticos no planejamento cirúrgico e sobrevida das pacientes.

Métodos Dados de 62 pacientes com câncer de endométrio operadas entre 2002 a 2011 em um hospital universitário foram avaliadas retrospectivamente. As pacientes foram submetidas à histerectomia e tratamento adjuvante, se necessário, e acompanhadas clinicamente de acordo com o protocolo institucional. Foram avaliados os resultados das análises histopatológicas das amostras endometriais pré-operatórias e cirúrgicas. As lesões foram classificadas como tumor endometriode (tipo 1) graus 1, 2 ou 3 ou carcinoma não endometriode (tipo 2).

Resultados De modo geral, houve uma concordância baixa entre os diagnósticos histopatológicos das amostras endometriais pré-operatórias e cirúrgicas (Kappa: 0,40; $p < 0,001$). Entretanto, uma alta concordância entre os diagnósticos foi observada nos tumores de graus mais elevados. Comprometimento de linfonodos ocorreu em 19,2% das pacientes e a maioria das que apresentaram remissão ou cura foram diagnosticadas nos estágios iniciais da doença (90,5%). Não houve diferença significativa na taxa de remissão ou cura entre as pacientes que tiveram concordância (25/33; 75,8%) ou divergência (11/16; 68,8%) entre os resultados histopatológicos pré-operatórios e cirúrgicos ($p = 0,605$).

Conclusão Nossos achados corroboram a literatura e confirmam o sub-estadiamento de amostras endometriais pré-operatórias com base na avaliação histopatológica, especialmente para tumores endometriais de baixo grau. Outros métodos complementares são necessários para um diagnóstico pré-operatório mais preciso a fim de melhorar o planejamento cirúrgico.

Descritores

- ▶ câncer do endométrio
- ▶ diagnóstico histopatológico
- ▶ método diagnóstico
- ▶ cirurgia de câncer endometrial

Introduction

Endometrial cancer is the second most common gynecological malignancy and the fourth most common malignancy in women. It represents 7% of cancers in women and the 6th most common cause of death by cancer in women. The estimates show ~ 60 thousand new cases and 12,000 deaths during the year 2016 in the United States.¹ In Brazil, almost 7,000 new cases were estimated for 2018.² The survival rate after 5 years of follow-up is 90% when the tumor is diagnosed in the early stage, but the survival is only 30% if detected later.³ Abnormal vaginal bleeding is the initial symptom, and diagnosis is usually made in the early stages of the disease (e.g., in 75% of patients).⁴

Tumor grading, defined by the International Federation of Gynecology and Obstetrics (FIGO) in 1988 and revised in 2009, is based on histopathological analysis of surgical specimens. The samples obtained during hysterectomy and bilateral adnexectomy with pelvic and para-aortic lymph node dissections are necessary, and the involvement of tumor grading from intraoperative specimens is a key point.⁵ However, the initial diagnosis is established by the histopathological analysis of endometrial biopsies.⁶ The histological subtype and the grade of endometrial cancer are key factors related to the probability of disease spread and recurrence.⁷⁻¹⁰

Total hysterectomy remains the standard treatment for the management of endometrial cancer.¹¹ However, the

benefit of systematic lymphadenectomy for women with early stage endometrial cancer is a matter of debate, and is basically defined according to the preoperative histopathological grade.¹²⁻¹⁴ Thus, the accuracy of preoperative histopathological analysis of endometrial biopsies is imperative because it directly affects the surgical management.^{15,16}

Studies published since the 1980s have demonstrated discordance between the histopathological analysis of preoperative endometrial samples and surgical specimens. Moreover, the discordance rates vary according to grades and other factors, such as the method of sample collection.¹⁶⁻²⁴ Thus, the study of preoperative endometrial sampling as a predictor of surgical specimen grading and its value on surgical decisions and patient prognosis is still debated.

The present study aimed to evaluate the agreement between the histopathological diagnoses of preoperative endometrial samples and surgical specimens and to correlate it with the impact on surgical management and survival of patients with endometrial adenocarcinomas from our university hospital.

Methods

The present study was performed at the Gynecologic Oncology discipline of the Gynecology Department of the Universidade Federal de São Paulo (UNIFESP), São Paulo,

Brazil. The study was approved by the Ethics Committee of the UNIFESP (CAAE: 02003912.5.0000.5505). The study presents a mixed design of cross-sectional and retrospective cohort, as it was developed into two steps. A cross-sectional study was performed to evaluate the association of pre and postoperative specimens' diagnosis of endometrial cancer. Then, a retrospective cohort strategy was also applied to explore the impact of agreement or not of the histopathological classifications, determined from the preoperative endometrial samples and surgical specimens, on patients survival.

Patients

Consecutive patients treated for endometrial cancer from 2002 to 2011 at the Gynecology Department of the Universidade Federal de São Paulo (UNIFESP) had their data reviewed from a prospectively maintained patient database. A total of 122 patients referred to our service with a previous endometrial cancer diagnosis were elected for this study. The inclusion criteria were women presenting endometrial cancer with a preoperative histopathological evaluation. For the patients referred from other institutions, our protocol was to review the biopsy specimens, and then, 57 patients whose preoperative biopsies specimens were not available for review were excluded from the study. Three women who did not had the postoperative data available in the datasheet were excluded as well. The final data analysis included 62 women with complete data about pre and postoperative histological evaluation. The preoperative endometrial sampling was performed by hysteroscopy with biopsy or curettage and histopathological analysis. The preoperative histopathological analysis or reviews were performed by an experienced pathology team from our institution that also performed the histopathological analysis of surgical specimens as per the department protocol. Patients were subjected to hysterectomy with bilateral salpingo-oophorectomy, associated or not with lymphadenectomy, and adjuvant treatment if necessary.

The clinical follow-up of patients was performed according to the institutional protocol.

According to the World Health Organization and the Royal College of Pathologists' definitions for tumor cell type, the lesions were classified as endometrioid adenocarcinoma (type 1) or non-endometrioid adenocarcinoma (type 2, mostly serous and clear cells). Endometrioid adenocarcinomas were sub classified as grades 1, 2, or 3 according to the FIGO) with a higher grade corresponding to less-differentiated lesions. Preoperative cancer samples could also be classified as atypical hyperplasia.

Data Analysis

Cases were grouped by preoperative and surgical histopathological diagnoses, and the correlation between them was assessed. Lymph node involvement and number of lymph nodes involved were registered for each group as features related to a higher risk of disease recurrence. Survival and clinical prognosis were also registered for each patient. Continuous variables were described as the mean and standard deviation and categorical variables as frequency and percentage. The McNemar and Chi-square tests were used to compare proportions of histopathological diagnoses between the preoperative samples and surgical specimens. The Kappa correlation evaluated the agreement between the preoperative and surgical specimens. Overall survival was estimated using Kaplan-Meier curves and log-rank test. For that, the time of statistical analysis was performed using SPSS for Windows version 21.0 (IBM Corp., Armonk, NY, USA), and *p*-values < 0.05 were considered statistically significant.

Results

We identified 62 cases that met our inclusion criteria. Most patients had preoperative endometrial sampling by hysteroscopy (60.0%), 18 were obtained by curettage and biopsy (32.7%) and 4 (7.3%) had missing endometrial sampling methods. ▶ **Table 1** summarizes the findings of the

Table 1 Histopathological review of the cases grouped by preoperative endometrial samples and surgical specimens

Preoperative endometrial samples	Surgical specimens					Total n(%)
	Atypical hyperplasia N (%)	Endometrioid adenocarcinoma grade 1 N (%)	Endometrioid adenocarcinoma grade 2 N (%)	Endometrioid adenocarcinoma grade 3 N (%)	Non-endometrioid adenocarcinoma N (%)	
Atypical hyperplasia	0 (0)	10 (55.6)	5 (27.8)	1 (5.6)	2(11.1)	18 (100)
Endometrioid adenocarcinoma grade 1	0 (0)	16 (64.0)	7 (28.0)	0 (0.0)	2 (8.0)	25 (100)
Endometrioid adenocarcinoma grade 2	0 (0)	2 (25.0)	4 (50.0)	1 (12.5)	1 (12.5)	8 (100)
Endometrioid adenocarcinoma grade 3	0 (0)	0 (0)	0 (0)	0 (0)	0 (0)	0 (100)
Non-endometrioid adenocarcinoma	0 (0)	1 (9.1)	0 (0)	1 (9.1)	9 (81.8)	11 (100)

Chi-square - *p* < 0.001.

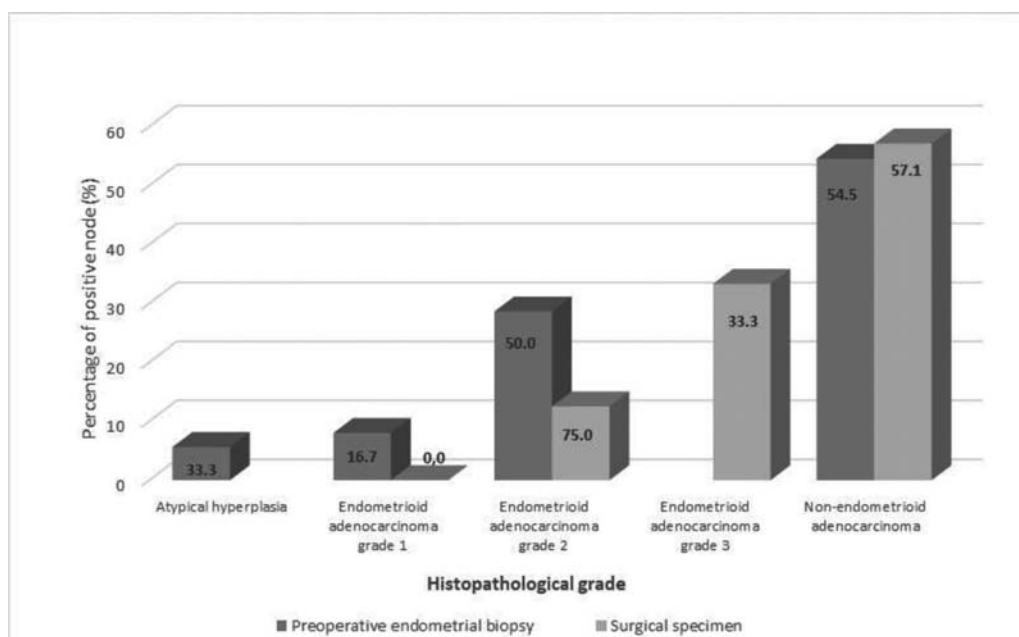


Fig. 1 Percentage of patients with positive nodes according to histopathological grade of the preoperative endometrial samples and surgical specimens.

histopathological review of the preoperative endometrial samples and surgical specimens. The general agreement between the preoperative endometrial samples and surgical specimens was 46.8% (Kappa: 0.279, $p < 0.001$). However, we noted that the agreement varied significantly by tumor type and grade, so that a reasonable concordance occurred at endometrioid adenocarcinoma grade 1 (64.0%) and grade 2 (50.0%) and non-endometrioid adenocarcinoma (81.8%). It is interesting to note that there were 18 patients diagnosed with atypical hyperplasia in the preoperative sample and none confirmed in the surgical sample. Moreover, no women were diagnosed with endometrioid adenocarcinoma grade 3 in the preoperative samples, and we observed 3 in the surgical specimens. Those data demonstrate that higher discordances occur in the extremes of classifications.

During the hysterectomy, the lymph nodes were excised in 61 patients and were affected in 10 patients (19.2%). ► **Fig. 1** describes the percentage of patients with positive lymph nodes according to the histopathological grades of the preoperative endometrial samples and surgical specimens.

We obtained the follow-up data of 49 patients for a period that varied from 1 to 121 months (median: 41; Q25:9; Q75: 66 months/mean \pm SD: 45.6 \pm 31.9 months). Of those, 20 were considered cured (32.7%), 20 had disease remission (40.8%), 2 had active disease or suffered disease recurrence (4.8%), and 11 died (22.4%). The percentage of patients with disease remission or cure according to the histopathological grade of the surgical specimens are described in ► **Table 2**.

We also evaluated the rates of disease remission or cure among the 49 patients with follow-up data, according to agreement or not with the histopathological classifications

Table 2 Percentage of patients with disease remission or cure according to the histopathological grade of the surgical specimens

Histopathological grade of the surgical specimens	Disease remission or cure n(%)
Endometrioid adenocarcinoma grade 1	19/21 (90.5)
Endometrioid adenocarcinoma grade 2	13/15 (86.7)
Endometrioid adenocarcinoma grade 3	2/2 (100.0)
Non-endometrioid adenocarcinomas	2/11 (18.2)
Total number of patients	36/49 (73.5)

$P < 0.001$.

determined from the preoperative endometrial samples and surgical specimens. The percentage of patients with disease remission or cure was similar between those who had a correct diagnosis (15/22, 68.2%) on preoperative endometrial sampling and those with a misdiagnosis (21/27, 77.8%; $p = 0.450$). Then, ► **Fig. 2** shows the Kaplan-Meier curve for survival function in subgroups of women with correct diagnosis or misdiagnosis on preoperative endometrial sampling. This shows that the estimated mean of survival time was similar between patients with correct diagnosis in the preoperative samples (85.6%) and those with misdiagnosis (93.7%, $p = 0.487$). Those data showed that even though misdiagnosis in preoperative samples is frequent (53.2% of cases), it does not affect the survival rates of patients.

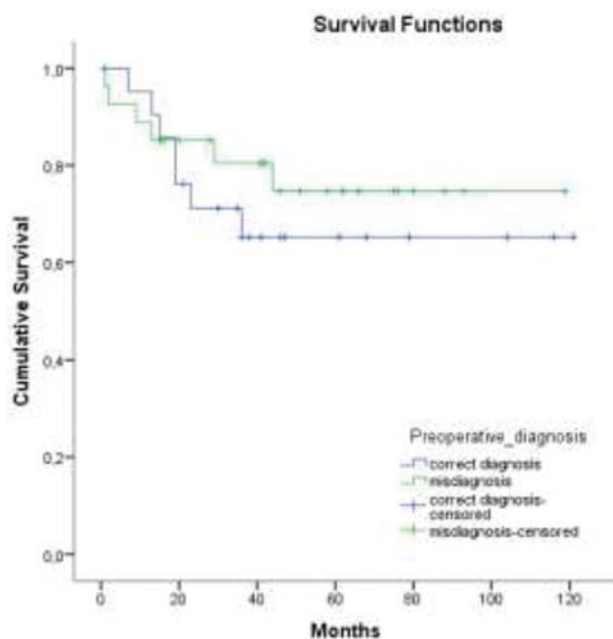


Fig. 2 Kaplan-Meier plots showing the cumulative survival function in subgroups of women with correct diagnosis or misdiagnosis on preoperative endometrial sampling.

Discussion

Pathological information of preoperative sampling is often used to stratify endometrial cancer based on low and high risk for lymphatic dissemination and prognosis, which guides decision-making for surgical planning. Thus, the accuracy of the preoperative histopathological assessment is imperative. Our findings showed that the agreement between the histopathological diagnoses based on the preoperative endometrial samples and those based on the surgical specimens is fair, and the vast majority of samples that were misdiagnosed had a lower grade classification based on preoperative endometrial sampling. Our findings corroborate those of other studies that also showed fair agreement between the histopathology assessment of preoperative and surgical specimens in endometrial cancer,^{20,25,26} suggesting that the preoperative histological grade is not a good predictor of definitive diagnosis. Our findings and those outcomes suggest that patient treatment planning can be underestimated and may impair the patient's prognosis.

On the other hand, the samples classified as non-endometrioid adenocarcinoma had higher agreement between the diagnoses based on the preoperative endometrial samples and the surgical specimens. Hence, at least for the patients with the worst prognosis, a higher accuracy of histopathology for the preoperative endometrial sample gives us the correct information for the decision-making on surgical planning for most cases.

Despite some authors^{9,27} and FIGO¹¹ recommending that the surgical treatment of endometrial cancer include hysterectomy plus lymph node dissection of the pelvis and para-aortic areas for all histological grades and types of endome-

trial cancer, there are other authors^{12,13,28,29} who did not find benefits of lymph node dissection for patients with early disease. In our study, most patients underwent lymph node dissection, and we found ~20% of cases with lymph node involvement, which represents a higher percentage than that in other studies.^{9,30,31} However, those with early disease presented a lower incidence of lymph node involvement, and higher grade tumors had a higher incidence of lymph node involvement, corroborating the literature findings.²⁸

It is well established that patient prognosis and survival are directly associated with tumor staging and lymph node involvement. We considered those patients without disease recurrence after 60 months of follow-up to be cured, and those patients without disease recurrence before completing 60 months of follow-up to have disease remission. We found a significantly lower disease remission/cure for patients presenting with non-endometrioid adenocarcinoma, similar to the literature findings.^{32,33} A limitation of our data are the small number of patients presenting endometrioid adenocarcinoma grade 3, who had 100% of remission/cure, which is not consistent with this tumor type. Additionally, the understaging of endometrial cancer did not affect the survival rates, probably due to the higher grades and, consequently, a worse prognosis patients, in whom there was a greater agreement between the histopathological assessments of the preoperative and surgical specimens. Another pitfall is that the follow-up until 60 months was missed for most patients and the survival analysis can be compromised, although Kaplan-Meier plots do not show any difference between subgroups.

The retrospective design of our study is also a limitation. Additionally, although all surgeries were performed in the same hospital, the surgeons were not the same, and there was no clear rule to perform lymph node dissection in early-stage tumors, which can be considered a bias.

Faced with our results and literature findings demonstrating the understaging of endometrial cancer on preoperative endometrial samples, other parameters can be considered for surgical planning. Magnetic resonance imaging to evaluate myometrial invasion,³⁴ tumor volume,³⁵ and intraoperative staging estimation by the analysis of cryopreserved specimens³⁶ can also contribute to surgical planning.

Conclusion

In summary, our findings corroborate the literature results and confirm the understaging of preoperative endometrial samples by histopathological assessment, especially for lower grade endometrial tumors. Therefore, we suggest that the preoperative diagnosis should be complemented with other methods to better plan the surgical management strategy.

Contributions

Mario Augusto Silveira Bueno Piotto contributed to study design, execution, manuscript drafting, critically revising and discussing of the article and final approval of the version to be published. Gustavo Rubino de Azevedo Focchi contributed to study execution, sample analysis,

revising and final approval of the version to be published. Renato Moretti Marques contributed to data collection and final approval of the version to be published. Addressa Melina Severino Teixeira contributed to data collection and final approval of the version to be published. Wagner José Gonçalves contributed to critically revising and discussing of the article and final approval of the version to be published. Sergio Mancini Nicolau contributed to study design, execution, manuscript drafting, critically revising and discussing of the article and final approval of the version to be published.

Conflict of Interests

The authors have no conflict of interests to declare.

Acknowledgments

The authors gratefully acknowledge all members of the Gynecology Oncology discipline of the Gynecology Department of the Universidade Federal de São Paulo, São Paulo, SP, Brazil for their invaluable support with patients and procedures.

References

- Siegel RL, Miller KD, Jemal A. Cancer statistics, 2019. *CA Cancer J Clin.* 2019;69(01):7–34. Doi: 10.3322/caac.21551
- Ministério da Saúde. Instituto Nacional de Câncer [Internet]. Estatísticas de câncer. 2019 [cited 2019 Feb 20]. Available from: <https://www.inca.gov.br/numeros-de-cancer>
- Watari H, Mitamura T, Moriwaki M, Hosaka M, Ohba Y, Sudo S, et al. Survival and failure pattern of patients with endometrial cancer after extensive surgery including systematic pelvic and para-aortic lymphadenectomy followed by adjuvant chemotherapy. *Int J Gynecol Cancer.* 2009;19(09):1585–1590. Doi: 10.1111/IGC.0b013e31818a833c
- Münstedt K, Grant P, Woencckhaus J, Roth G, Tinneberg HR. Cancer of the endometrium: current aspects of diagnostics and treatment. *World J Surg Oncol.* 2004;2:24. Doi: 10.1186/1477-7819-2-24
- Zaino RJ. FIGO staging of endometrial adenocarcinoma: a critical review and proposal. *Int J Gynecol Pathol.* 2009;28(01):1–9. Doi: 10.1097/PGP.0b013e3181846c6d
- Leitao MM Jr, Kehoe S, Barakat RR, Alektiar K, Gattoc LP, Rabbitt C, et al. Comparison of D&C and office endometrial biopsy accuracy in patients with FIGO grade 1 endometrial adenocarcinoma. *Gynecol Oncol.* 2009;113(01):105–108. Doi: 10.1016/j.ygyno.2008.12.017
- Morrow CP, Bundy BN, Kurman RJ, Creasman WT, Heller P, Homesley HD, Graham JE. Relationship between surgical-pathological risk factors and outcome in clinical stage I and II carcinoma of the endometrium: a Gynecologic Oncology Group study. *Gynecol Oncol.* 1991;40(01):55–65. Doi: 10.1016/0090-8258(91)90086-k
- Mariani A, Webb MJ, Keeney GL, Aletti G, Podratz KC. Endometrial cancer: predictors of peritoneal failure. *Gynecol Oncol.* 2003;89(02):236–242. Doi: 10.1016/s0090-8258(03)00052-0
- Cragun JM, Havrilesky LJ, Calingaert B, Synan I, Secord AA, Soper JT, et al. Retrospective analysis of selective lymphadenectomy in apparent early-stage endometrial cancer. *J Clin Oncol.* 2005;23(16):3668–3675. Doi: 10.1200/JCO.2005.04.144
- Chi DS, Barakat RR, Palayekar MJ, Levine DA, Sonoda Y, Alektiar K, et al. The incidence of pelvic lymph node metastasis by FIGO staging for patients with adequately surgically staged endometrial adenocarcinoma of endometrioid histology. *Int J Gynecol Cancer.* 2008;18(02):269–273. Doi: 10.1111/j.1525-1438.2007.00996.x
- Benedet JL, Bender H, Jones H III, Ngan HY, Pecorelli S; FIGO Committee on Gynecologic Oncology. FIGO staging classifications and clinical practice guidelines in the management of gynecologic cancers. *Int J Gynaecol Obstet.* 2000;70(02):209–262. Doi: 10.1016/S0020-7292(00)90001-8
- Kitchener H, Swart AM, Qian Q, Parmar MK; ASTEC study group. Efficacy of systematic pelvic lymphadenectomy in endometrial cancer (MRC ASTEC trial): a randomised study. *Lancet.* 2009;373(9658):125–136. Doi: 10.1016/S0140-6736(08)61766-3
- Benedetti Panici P, Basile S, Maneschi F, Lissoni AA, Signorelli M, Scambia G, et al. Systematic pelvic lymphadenectomy vs. no lymphadenectomy in early-stage endometrial carcinoma: randomized clinical trial. *J Natl Cancer Inst.* 2008;100(23):1707–1716. Doi: 10.1093/jnci/djn397
- Uccella S, Podratz KC, Aletti GD, Mariani A. Re: Systematic pelvic lymphadenectomy vs no lymphadenectomy in early-stage endometrial carcinoma: randomized clinical trial. *J Natl Cancer Inst.* 2009;101(12):897–898, author reply 898–899. Doi: 10.1093/jnci/djp124
- Cooke EW, Pappas L, Gaffney DK. Does the revised International Federation of Gynecology and Obstetrics staging system for endometrial cancer lead to increased discrimination in patient outcomes? *Cancer.* 2011;117(18):4231–4237. Doi: 10.1002/cncr.26030
- Oakley G, Nahhas WA. Endometrial adenocarcinoma: therapeutic impact of preoperative histopathologic examination of endometrial tissue. *Eur J Gynaecol Oncol.* 1989;10(04):255–260
- Petersen RW, Quinlivan JA, Casper GR, Nicklin JL. Endometrial adenocarcinoma—presenting pathology is a poor guide to surgical management. *Aust N Z J Obstet Gynaecol.* 2000;40(02):191–194. Doi: 10.1111/j.1479-828x.2000.tb01145.x
- Soothill PW, Alcock CJ, MacKenzie IZ. Discrepancy between curettage and hysterectomy histology in patients with stage 1 uterine malignancy. *Br J Obstet Gynaecol.* 1989;96(04):478–481. Doi: 10.1111/j.1471-0528.1989.tb02427.x
- Jones HW III. The importance of grading in endometrial cancer. *Gynecol Oncol.* 1999;74(01):1–2. Doi: 10.1006/gy.1999.5508
- Batista TP, Cavalcanti CL, Tejo AA, Bezerra AL. Accuracy of preoperative endometrial sampling diagnosis for predicting the final pathology grading in uterine endometrioid carcinoma. *Eur J Surg Oncol.* 2016;42(09):1367–1371. Doi: 10.1016/j.ejso.2016.03.009
- Leitao MM Jr, Kehoe S, Barakat RR, Alektiar K, Gattoc LP, Rabbitt C, et al. Accuracy of preoperative endometrial sampling diagnosis of FIGO grade 1 endometrial adenocarcinoma. *Gynecol Oncol.* 2008;111(02):244–248. Doi: 10.1016/j.ygyno.2008.07.033
- Phelippeau J, Canlorbe G, Bendifallah S, Naoura I, Lefevre M, Ballester M, Daraï E. Preoperative diagnosis of tumor grade and type in endometrial cancer by pipelle sampling and hysteroscopy: Results of a French study. *Surg Oncol.* 2016;25(04):370–377. Doi: 10.1016/j.suronc.2016.08.004
- Garcia TS, Appel M, Rivero R, Kliemann L, Wender MC. Agreement between preoperative endometrial sampling and surgical specimen findings in endometrial carcinoma. *Int J Gynecol Cancer.* 2017;27(03):473–478. Doi: 10.1097/JG.0000000000000922
- Bezerra AL, Batista TP, Martins MR, Carneiro VC. Surgical treatment of clinically early-stage endometrial carcinoma without systematic lymphadenectomy. *Rev Assoc Med Bras (1992).* 2014;60(06):571–576. Doi: 10.1590/1806-9282.60.06.017
- Visser NCM, Reijnen C, Massuger LFAG, Nagtegaal ID, Bulten J, Pijnenborg JMA. Accuracy of endometrial sampling in endometrial carcinoma: a systematic review and meta-analysis. *Obstet Gynecol.* 2017;130(04):803–813. Doi: 10.1097/AOG.0000000000002261
- Wang X, Zhang H, Di W, Li W. Clinical factors affecting the diagnostic accuracy of assessing dilation and curettage vs frozen section specimens for histologic grade and depth of myometrial invasion in endometrial carcinoma. *Am J Obstet Gynecol.* 2009;201(02):194.e1–194.e10. Doi: 10.1016/j.ajog.2009.05.003
- Kilgore LC, Partridge EE, Alvarez RD, Austin JM, Shingleton HM, Noojin F 3rd, Conner W. Adenocarcinoma of the endometrium: survival comparisons of patients with and without pelvic node sampling. *Gynecol Oncol.* 1995;56(01):29–33

- 28 Frost JA, Webster KE, Bryant A, Morrison J. Lymphadenectomy for the management of endometrial cancer. *Cochrane Database Syst Rev.* 2017;10:CD007585. Doi: 10.1002/14651858.CD007585.pub4
- 29 May K, Bryant A, Dickinson HO, Kehoe S, Morrison J. Lymphadenectomy for the management of endometrial cancer. *Cochrane Database Syst Rev.* 2010;(01):CD007585. Doi: 10.1002/14651858.CD007585.pub2
- 30 Chan JK, Cheung MK, Huh WK, Osann K, Husain A, Teng NN, Kapp DS. Therapeutic role of lymph node resection in endometrioid corpus cancer: a study of 12,333 patients. *Cancer.* 2006;107(08):1823–1830. Doi: 10.1002/cncr.22185
- 31 Lutman CV, Havrilesky LJ, Cragun JM, Secord AA, Calingaert B, Berchuck A, et al. Pelvic lymph node count is an important prognostic variable for FIGO stage I and II endometrial carcinoma with high-risk histology. *Gynecol Oncol.* 2006;102(01):92–97. Doi: 10.1016/j.ygyno.2005.11.032
- 32 van Hanegem N, Prins MM, Bongers MY, Opmeer BC, Sahota DS, Mol BWJ, Timmermans A. The accuracy of endometrial sampling in women with postmenopausal bleeding: a systematic review and meta-analysis. *Eur J Obstet Gynecol Reprod Biol.* 2016; 197:147–155. Doi: 10.1016/j.ejogrb.2015.12.008
- 33 Kapucuoglu N, Bulbul D, Tulunay G, Temel MA. Reproducibility of grading systems for endometrial endometrioid carcinoma and their relation with pathologic prognostic parameters. *Int J Gynecol Cancer.* 2008;18(04):790–796. Doi: 10.1111/j.1525-1438.2007.01067.x
- 34 Lee JY, Kim YH, Lee JM, Kim K, Kang S, Lim MC, et al. Role of pre-operative magnetic resonance imaging and histological assessment in identifying patients with a low risk of endometrial cancer: a Korean Gynecologic Oncology Group ancillary study. *Oncotarget.* 2017;8 (62):106009–106016. Doi: 10.18632/oncotarget.22520
- 35 Todo Y, Watari H, Okamoto K, Hareyama H, Minobe S, Kato H, Sakuragi N, et al. Tumor volume successively reflects the state of disease progression in endometrial cancer. *Gynecol Oncol.* 2013; 129(03):472–477. Doi: 10.1016/j.ygyno.2013.02.034
- 36 Larson DM, Connor GP, Broste SK, Krawisz BR, Johnson KK. Prognostic significance of gross myometrial invasion with endometrial cancer. *Obstet Gynecol.* 1996;88(03):394–398. Doi: 10.1016/0029-7844(96)00161-5