

Correlation between Age and Surgical Approach for Thoracic and Lumbar Hemivertebra

Alexandrina Nikova¹,^{ORCID} Varvara Chatzipaulou¹ Belkis Malkots¹ Reichan Molla Mustafa¹
Christina Valsamidou¹ Theodosia Biribilis¹

¹Department of Neurosurgery, Democritus University of Thrace Medical School, Alexandroupolis, Greece

Address for correspondence Alexandrina Nikova, MD, Department of Neurosurgery, Democritus University of Thrace Medical School, Dragana, 68100 Alexandroupolis, Greece (e-mail: nikovaalex@gmail.com).

Indian J Neurosurg:2020;9:115–121

Abstract

Objective Hemivertebra (HV) is a congenital defect of the formation of the spinal vertebra, which can result in scoliosis or kyphosis along with the related symptomatology of spine deformity. More often than not, it is linked to other abnormalities and requires attention. Its management is surgical and it is of great importance for the physician to choose the right approach at the right time, due to its deteriorative prognosis.

Methods Due to the interest of the subject, the authors investigated the world literature between 1990 and 2018 and found 45 articles, reporting thoracic, thoracolumbar, and lumbar HV in children and its postsurgical outcome, aiming to show whether the approaches are equal in terms of the final outcome.

Results The chosen surgical method depends much on the level of the pathology. Despite this fact, after analyzing the included data, we found that the surgical techniques are unequal with regard to the purpose of achieving improvement. Age, caudal and cranial curves, segmental kyphosis, and scoliosis are factors playing a major role in this.

Conclusion If not treated, HV leads to deterioration and dysfunction. The most optimal result, however, is achieved only when the surgical approach is applied according to age and rest of the accompanying factors, which should be considered in future management planning.

Keywords

- ▶ hemivertebra
- ▶ quality of life
- ▶ spine surgery

Introduction

Embryologic period is essential for the correct growth of tissues and organs. During this period, many errors and abnormalities can occur which will accompany the human during its life. Such a congenital condition is hemivertebra (HV), where only half of the vertebral body is developed. Other expressions for hemivertebra are “congenital scoliosis,” “unilateral aplasia of the vertebral body,” and “complete unilateral failure of formation of the vertebral body.”¹

Its first mention in medicine was not long ago by Winter et al² and their classification system on congenital scoliosis (CS). Current statistics evaluate the incidence of the hemivertebra to be around 0.5 to 1/1000 births.^{3,4}

Usually, around the sixth week of gestation, independent centers of chondrification are developing the vertebrae.⁵ A few weeks later, these centers merge to provide ossification centers for the development of the notochord remnant. Lack of these centers lead to the development of lateral hemivertebra, while the posterior hemivertebra is caused by a lack of ossification.^{6,7} Currently, according to the disk space between the bony structures, there are four known types of hemivertebra.⁸

The HV acts as a triangular-shaped construction within the spine, causing contralateral divergence of the spine.⁹ More often than not, HV is associated with other deformities, disorders, and imbalances.

Many reports describe this abnormality and conclude that surgery is a vital procedure for the therapy of the HV.

Available approaches for HV include anterior and posterior techniques with or without fusion.⁸

Hemivertebra is a condition that piqued our interest to a high degree, because of its symptomatology and capability of treatment with the proper technique. The most commonly used are anterior and posterior approaches; however, no other study reports whether there is a connection between the age, outcome, and technique, which represents the aim of this study.

Methods

For the study, all data published by MEDLINE (Cochrane, Wiley) and EMBASE on the subject of HV in the thoracic, lumbar, and sacral spine between 1990 and 2018 were collected to examine the role of the approach in the final result. The used MeSH terms for the search are as follows: “spine surgery,” “hemivertebra,” “congenital disorders,” “scoliosis.”

The inclusion criteria were the following: articles in English and German; type of articles—case report and clinical study; articles with sufficient information on the segment and approach, demographic data, as well as the postoperative outcome; and articles reporting the main curve postoperatively. Case reports are included because of the rare incidence of the condition and the fact that the outcome, either way, represents the average score.

On the other hand, from the review are excluded all articles: written in other than English and German language; letters to editor and comments; reviews; articles with insufficient information on the subject; studies on animals;

articles reporting cervical HV; articles reporting fetal or embryological HV; articles reporting infants (younger than 1 year) or older than 18 years; articles reporting more than one approach; articles with no demographic data (age and sex) or postoperative outcome (► Fig. 1).

After filtering the data, we divided the included reports into two main groups: group A—age under 9 years and group B—age equal or over 9 years. This age is considered as middle point or median value ($18/2 = 9$) and was chosen without any other additional settings. The included articles are further analyzed with *t*-test, linear regression analysis, and correlation matrix on statistical program, based on the used approach—posterior versus anterior + posterior.

Improvement in this analysis is based on the outcome. No complications and reoperations are evaluated as 100% improvement. Any complications and reinterventions are evaluated as 75% improvement, stable conditions as 50%, and any deterioration or worsening as 0%.

Other factors such as main curve, segmental kyphosis/scoliosis, and compensatory cranial/caudal curve are measured from the latest follow-ups.

The probability of bias of the current study is very small, if present, since the results and assumptions are based only on statistics. The latter are result of analysis of already published data, all of which lack reports on bias.

Results

In the study are included 45 articles with a total number of 971 patients (► Tables 1 and 2). Mean age of all the participants is 7.16 years with sufficient male dominance.

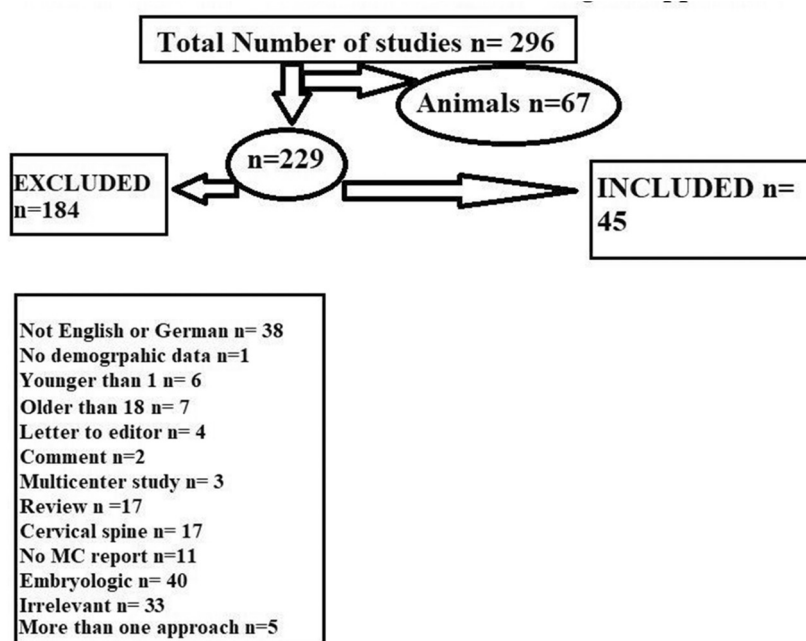


Fig. 1 Flow chart—Hemivertebra and surgical approach..

Table 1 List of studies reporting posterior approach

Study	Age	Number of patients	Improvement rate
Li et al ¹⁰	9.4	24	100
Hardequist et al ¹¹	4.2	10	100
Ruf et al ¹²	3.5	33	91.67
Ruf et al ¹³	3.5	28	83.93
Shono et al ¹⁴	5.7	12	97.92
Ruf et al ¹⁵	3.2	25	94
Ruf et al ¹⁶	5.8	20	92.5
Nakamura et al ¹⁷	10	5	100
Zhang et al ¹⁸	9.9	56	97.77
Li et al ¹⁹	17	12	100
Peng et al ²⁰	3.3	10	100
Erturer et al ²¹	9.2	9	100
Lyu et al ²²	13.2	17	94.18
Basu et al ²³	11.2	22	97.73
Guo et al ²⁴	5.4	39	96.79
Feng et al ²⁵	5.8	19	90.79
Chang et al ²⁶	11.3	45	91.11
Yang et al ²⁷	11.4	9	83.33
Guo et al ²⁸	9.8	116	96.77
Chang et al ²⁹	2	1	75
Chang et al ³⁰	6.6	20	96.25
Zhuang et al ³¹	10	14	98.21
Chu et al ³²	10.8	17	100
Zhu et al ³³	7	60	97.08
Crostelli et al ³⁴	5.5	15	96.67
Kose et al ³⁵	5	12	91.66
Crostelli et al ³⁶	7.5	30	99.17
Jeszenszky et al ³⁷	2	1	100
Huang et al ³⁸	11.9	15	86.67
Chen et al ³⁹	9.5	18	98.61
Wang et al ⁴⁰	6.5	37	100
Basu et al ⁴¹	9.2	20	96.25

T-test was performed on the four groups: posterior approach in younger than 9; posterior approach in older than 9; posterior + anterior in younger than 9; and posterior + anterior in older than 9. The results of the *t*-tests reveal that the techniques are unequal between the groups (► **Tables 3** and **4**).

Furthermore, in the group A for anterior + posterior approach, there is a negative correlation between main curve and improvement rate ($R^2 = 0,288$) (► **Table 5**). More detailed regression analysis reveals the correlation between age and compensatory caudal curve, compensatory cranial curve, segmental kyphosis and segmental scoliosis for the four groups (► **Table 6**). Based on the approach and the

Table 2 List of studies reporting posterior and anterior approach

Study	Age	Number of patients	Improvement rate
Bollini et al ⁴²	3.3	21	96.43
Garrido et al ⁴³	2.8	31	97.58
Klemme et al ⁴⁴	1,7	6	100
Hadequist et al ⁴⁵	3.1	18	98.61
Ginsburg et al ⁴⁶	10.5	96	100
Cheung et al ⁴⁷	3,4	7	91.67
Bradford et al ⁴⁸	4.14	34	92.86
Xu et al ⁴⁹	12,1	34	100
Holte et al ⁵⁰	12	37	89.19
Lazar et al ⁵¹	1.5	11	93.18
Winter et al ⁵²	12	1	100
Chang et al ⁵³	4	1	75
Wang et al ⁴⁰	5.4	18	100

Table 3 Paired t-test same approach different age

Paired samples T-Test			
	t	df	p-Value
Posterior	969.53	1	< 0.001 ^a
A + P	- 46.00	1	0.014 ^a

Abbreviation: A+P: anterior + posterior.

^aSignificant value.

Table 4 Paired t-test same age, different approach

Paired samples T-Test				
		t	df	p-Value
A + P under 9 y	Posterior under 9 y of age	3259.0	1	< 0.001 ^a
Posterior over 9 y	A+P over 9 y of age	124.8	1	0.005 ^a

Abbreviation, A + P: anterior + posterior approach.

^aSignificant value.

Table 5 Correlation between age, improvement rate, and main curve for group A

		Age	Improvement
Improvement	Pearson's r	- 0.170	—
	p-value	0.662	—
Main curve	Pearson's r	- 0.129	- 0.537
	p-value	0.741	0.136

age group, the correlations between the factors vary, but surely the age plays a very important role. The improvement, as lack of complications and reintervention, seems to be also connected to the latter (► **Table 7**). According to the analysis, every approach should be considered based

Table 6 Correlations between age, segmental kyphosis/scoliosis, and compensatory cranial/caudal curve

Approach	Age	Segmental kyphosis R ²	Segmental scoliosis R ²	Compensatory cranial curve R ²	Compensatory caudal curve R ²
Posterior only	Age < 9	0.2434	- 0.0538	- 0.2434	- 0.1667
	Age > 9	-0.0346	- 0.7562	0.3407	0.0882
Posterior + anterior	Age > 9	- 1	-	- 0.957	- 0.2844
	Age < 9	0.2601	-	-	1

Table 7 Correlations between improvement, segmental kyphosis/scoliosis, and compensatory cranial/caudal curve

Approach	Improvement	Segmental kyphosis R ²	Segmental scoliosis R ²	Compensatory cranial curve R ²	Compensatory caudal curve R ²
Posterior	< 9	0.2001	0.4834	0.1045	0.0116
	> 9	- 0.4219	0.3367	0.451	0.3128
Anterior+ posterior	< 9	1	-	0.9158	- 0.0035
	> 9	- 0.9955	-	-	-

on the age of the patients to achieve better results. A statement is based on the fact that in the anterior + posterior approach, there is a strong link between age/improvement and segmental kyphosis (follow-up results), while in the posterior only approach, there is a solid link between age/improvement and segmental scoliosis (follow-up results).

Although the approaches seem to be identical, they appear to be unequal with regard to improvement, and every technique according to the concrete age group has different correlations and values of the most optimal outcome. They are not the same and the surgery of HV should be personalized in the future.

Discussion

Scientifically proved, congenital abnormalities of the spine are formed in the embryonic period, either as formation or segmentation failure.⁵⁴ These abnormalities lead to the formation of congenital scoliosis and the most underlying factor is HV.⁵⁵ It has variable frequency from 1.33/10.000 (0.133/1000) to 10/10.000 (1/1000).^{1,6,56}

Generally speaking, HV headed to local instability, decreased longitudinal development, as well as enhanced convolution of the spine.^{2,57} The progression and its level could not be predicted.⁴⁰ However, for sure, there will be asymmetric growth, followed by secondary curvature and endorsed balance, requiring adequate therapy to prevent more severe deformity.¹³ The main controversy here is whether to choose posterior or posterior and anterior approach. Theoretically, posterior approach is a method that can fully resolve the problem, but it is more insisting and might cause some neurological problems. Due to this, some physicians chose to proceed with the posterior–anterior approach, even though it requires more operation time, hospital stay and, currently stated complications.^{16,58}

HV of the thoracic spine is more common than the HV of the cervical spine. Its symptomatology is mainly pain and myelopathy.⁵⁹ The surgical choices are in situ fusion, removal

of HV, and epiphysiodesis.⁴⁵ The main target of the therapy is to accomplish spine with right direction and fewer difficulties. Due to the sensitivity of the thoracic spine, it is a recommended procedure with less complication risks.⁴⁵ But also taken under consideration is the possibility of good outcome, when spinal growth is present.^{60,61} Regarding the technique, it could be a method with posterior only approach, posterior and anterior, or as Suzuki et al⁶² reports, correction with 4-staged surgical therapy. Finally, total elimination of the HV with cervical pedicle. Based on the fragment of the spine, the outcomes are promising. Regarding the thoracic and thoracolumbar spinal HV. Zhang et al¹⁸ reports improvement after only posterior approach with even lower rate of complication than expected. Better visualization, sense on the compression, and less invasiveness are reached with this approach. Qureshi et al⁶³ also reports 69% improvement of the kyphosis, 73% improvement of the sagittal, and 76% of the coronal shift after posterior approach for thoracic, lumbar, and thoracolumbar HV. In this relation, Mladenov et al⁶⁴ observed 59% improvement after posterior approach and 55% after combined method. It is believed that the posterior approach only for thoracic HV provides stabilization but not correction.⁶⁰ To achieve better correction, usually it takes the combined approach.

Lumbar spine is the second most common location to form HV. Its symptomatology seems to be very interesting. It consists of gait distortions, lordosis and bended hips with bowel, bladder abnormality, and back pain.⁵⁴ Lumbar stenosis and nerve extension might also be observed. If not treated, it is a condition that leads to functional loss.⁵⁴ Due to this, the operation has the aim of relaxing the nerves and providing stability.⁵⁴ There are three basic types: fusion, removal, and epiphysiodesis.^{40,65} Based on the approaches, there are two choices: posterior and anterior. In some cases, the surgery is performed with anterior approach at the beginning, while in others, initially posterior.⁴⁰ Posterior approach is better for children.⁶⁶ Anterior approach, on the other hand, is believed to

be suitable for thoracolumbar HV.⁶⁵ In many cases, it can be provided in one or two stages. The first stage consists of removal, while the second comprises fusion.⁶⁵ One stage surgery is recommended because of the shorter time of operation, while their combination is recommended for bigger resection.^{40,65,67} The operation of the lumbar HV leads to improvement of the symptomatology.⁵⁴ This is shown in the report of Bollini, who observed 59.9% enhancement for the total curve after surgical management of the lumbar HV after combined posterior-anterior approach.⁴² Bradford et al⁸ reports 68.1% improvement after HV removal with the same approach. A similar result on combined approach has Lazar et al⁵¹ with 70.2% enrichment. Regarding only the posterior approach, Shono et al¹⁴ reports 63.3% improvement and Nakamura et al¹⁷ 54.3% after one-stage surgery for lumbar HV. After investigation of the published data, it seems that the posterior approach is as safe as the combined for the thoracic and lumbar spine^{58,68} Finally, for the lumbar HV, Zhu et al³³ reports 87.3% improvement after posterior approach with fusion, which is encouraging results but this technique is very challenging and could lead to complications.

The outcome of the study presents a new insight in spine surgery for HV. After many years of reporting clinical outcomes, it has become clear that the techniques are unequal with respect to the improvement of the patients with thoracic and lumbar HV. According to the results of the study, the approaches are unequal for the both age groups, suggesting that age is a determining factor for the final results, and should be always considered before proceeding with the chosen technique. Since the pathology is rare, more detailed reports are needed.

In addition to this, if not treated, HV in children will worsen the condition and complicate the status itself and the surgery. It is a deteriorative pathology, leading to functional loss that requires treatment. So, in those cases and especially in dorsal HV, surgical intervention at an early stage is the highly recommended.^{12,18,15,55,58,63} As to the approach, it is clear that the patient determines the method. So, choosing the right technique aids in improvement.

Funding

None.

Conflict of Interest

None declared.

Acknowledgments

The authors would like to thank Michaela Mitova.

References

- Copel J, D'Alton ME, Gratacos E, et al. *Obstetric Imaging E-Book: Expert Radiology Series*. Elsevier; 2012 pp. 250–251
- Winter RB, Moe JH, Eilers VE. Congenital scoliosis a study of 234 patients treated and untreated Part I: natural history. *J Bone Joint Surg Am* 1968;50(1):1–15
- Weisz B, Achiron R, Schindler A, Eisenberg VH, Lipitz S, Zalel Y. Prenatal sonographic diagnosis of hemivertebra. *J Ultrasound Med* 2004;23(6):853–857
- Wynne-Davies R. Congenital vertebral anomalies: aetiology and relationship to spina bifida cystica. *J Med Genet* 1975;12(3):280–288
- Leung YL, Buxton N. Combined diastematomyelia and hemivertebra: a review of the management at a single centre. *J Bone Joint Surg Br* 2005;87(10):1380–1384
- Goldstein I, Makhoul IR, Weissman A, Drugan A. Hemivertebra: prenatal diagnosis, incidence and characteristics. *Fetal Diagn Ther* 2005;20(2):121–126
- Wax JR, Watson WJ, Miller RC, et al. Prenatal sonographic diagnosis of hemivertebrae: associations and outcomes. *J Ultrasound Med* 2008;27(7):1023–1027
- Burnei G, Gavrilu S, Vlad C, et al. Congenital scoliosis: an up-to-date. *J Med Life* 2015;8(3):388–397
- Varras M, Akrivis C. Prenatal diagnosis of fetal hemivertebra at 20 weeks' gestation with literature review. *Int J Gen Med* 2010;3:197–201
- Li X, Luo Z, Li X, Tao H, Du J, Wang Z. Hemivertebra resection for the treatment of congenital lumbar spinal scoliosis with lateral-posterior approach. *Spine* 2008;33(18):2001–2006
- Hedequist D, Emans J, Proctor M. Three rod technique facilitates hemivertebra wedge excision in young children through a posterior only approach. *Spine* 2009;34(6):E225–E229
- Ruf M, Jensen R, Jeszenszky D, Merk H, Harms J. Halbwirbel-Resektion bei kongenitaler Skoliose – Frühzeitige Korrektur im Kindesalter. *Z Orthop Ihre Grenzgeb* 2006;144(1):74–79
- Ruf M, Jensen R, Letko L, Harms J. Hemivertebra resection and osteotomies in congenital spine deformity. *Spine* 2009;34(17):1791–1799
- Shono Y, Abumi K, Kaneda K. One-stage posterior hemivertebra resection and correction using segmental posterior instrumentation. *Spine* 2001;26(7):752–757
- Ruf M, Harms J. Posterior hemivertebra resection with transpedicular instrumentation: early correction in children aged 1 to 6 years. *Spine* 2003;28(18):2132–2138
- Ruf M, Harms J. Hemivertebra resection by a posterior approach: innovative operative technique and first results. *Spine* 2002;27(10):1116–1123
- Nakamura H, Matsuda H, Konishi S, Yamano Y. Single-stage excision of hemivertebrae via the posterior approach alone for congenital spine deformity: follow-up period longer than ten years. *Spine* 2002;27(1):110–115
- Zhang J, Shengru W, Qiu G, Yu B, Yipeng W, Luk KD. The efficacy and complications of posterior hemivertebra resection. *Eur Spine J* 2011;20(10):1692–1702
- Li XF, Liu ZD, Hu GY, et al. Posterior unilateral pedicle subtraction osteotomy of hemivertebra for correction of the adolescent congenital spinal deformity. *Spine J* 2011;11(2):111–118
- Peng X, Chen L, Zou X. Hemivertebra resection and scoliosis correction by a unilateral posterior approach using single rod and pedicle screw instrumentation in children under 5 years of age. *J Pediatr Orthop B* 2011;20(6):397–403
- Erturker RE, Kilinc BE, Gokcen B, Erdogan S, Kara K, Ozturk C. The results of hemivertebra resection by the posterior approach in children with a mean follow-up of five years. *Adv Orthop* 2017;2017:4213413
- Lyu Q, Hu B, Zhou C, et al. The efficacy of posterior hemivertebra resection with lumbosacral fixation and fusion in the treatment of congenital scoliosis: A more than 2-year follow-up study. *Clin Neurol Neurosurg* 2018;164:154–159
- Basu S, Tikoo A, Malik FH, Ghosh JD, Jain M, Sarangi T. Single and multiple level one stage posterior hemivertebrectomy and short segment fixation: experience with 22 cases and comparison of single vs. multilevel procedures with minimum 2-year follow-up. *Asian Spine J* 2016;10(3):422–429

- 24 Guo J, Zhang J, Wang S, et al. Surgical outcomes and complications of posterior hemivertebra resection in children younger than 5 years old. *J Orthop Surg Res* 2016;11(1):48
- 25 Feng Y, Hai Y, Zhao S, Zang L. Hemivertebra resection with posterior unilateral intervertebral fusion and transpedicular fixation for congenital scoliosis: results with at least 3 years of follow-up. *Eur Spine J* 2016;25(10):3274–3281
- 26 Chang DG, Yang JH, Lee JH, et al. Congenital scoliosis treated with posterior vertebral column resection in patients younger than 18 years: longer than 10-year follow-up. *J Neurosurg Spine* 2016;25(2):225–233
- 27 Yang X, Song Y, Liu L, et al. Emerging S-shaped curves in congenital scoliosis after hemivertebra resection and short segmental fusion. *Spine J* 2016;16(10):1214–1220
- 28 Guo J, Zhang J, Wang S, et al. Risk factors for construct/implant related complications following primary posterior hemivertebra resection: study on 116 cases with more than 2 years' follow-up in one medical center. *BMC Musculoskelet Disord* 2016;17(1):380
- 29 Chang DG, Yang JH, Lee JH, et al. Revision surgery for curve progression after implant removal following posterior fusion only at a young age in the treatment of congenital scoliosis: a case report. *Medicine (Baltimore)* 2016;95(47):e5266
- 30 Chang DG, Suk SI, Kim JH, Ha KY, Na KH, Lee JH. Surgical outcomes by age at the time of surgery in the treatment of congenital scoliosis in children under age 10 years. *Spine J* 2015;15(8):1783–1795
- 31 Zhuang Q, Zhang J, Li S, Wang S, Guo J, Qiu G. One-stage posterior-only lumbosacral hemivertebra resection with short segmental fusion: a more than 2-year follow-up. *Eur Spine J* 2016;25(5):1567–1574
- 32 Chu G, Huang J, Zeng K, Guo Q, Zhang H. A modified surgical procedure for congenital kyphoscoliosis: selective partial hemivertebrectomy via posterior-only approach. *Childs Nerv Syst* 2015;31(6):923–929
- 33 Zhu X, Wei X, Chen J, et al. Posterior hemivertebra resection and monosegmental fusion in the treatment of congenital scoliosis. *Ann R Coll Surg Engl* 2014;96(1):41–44
- 34 Crostelli M, Mazza O, Mariani M. Posterior approach lumbar and thoracolumbar hemivertebra resection in congenital scoliosis in children under 10 years of age: results with 3 years mean follow up. *Eur Spine J* 2014;23(1):209–215
- 35 Kose KC, Inanmaz ME, Altinel L, et al. Convex short segment instrumentation and hemi-chevron osteotomies for Putti type 1 thoracic hemivertebrae: a simple treatment option for patients under 5 years old. *J Spinal Disord Tech* 2013;26(6):E240–E247
- 36 Crostelli M, Mazza O, Mariani M, Marscello D. Posterior approach hemivertebra resection in hemivertebra congenital scoliosis in 30 patients. Paper presented at: XXXVI Italian Spine Society National Congress Sala Maggiore: Fiera District, Bologna, Italy 16th–18th May, 2013
- 37 Jeszenszky D, Fekete TF, Kleinstueck FS, Haschtmann D, Bognár L. Fusionless posterior hemivertebra resection in a 2-year-old child with 16 years follow-up. *Eur Spine J* 2012;21(8):1471–1476
- 38 Huang Y, Feng G, Song Y, et al. Efficacy and safety of one-stage posterior hemivertebra resection for unbalanced multiple hemivertebrae: a more than 2-year follow-up. *Clin Neurol Neurosurg* 2017;160:130–136
- 39 Chen Z, Qiu Y, Zhu Z, et al. Posterior-only hemivertebra resection for congenital cervicothoracic scoliosis: correcting neck tilt and balancing the shoulders. *Spine* 2018;43(6):394–401
- 40 Wang S, Zhang J, Qiu G, et al. Posterior-only hemivertebra resection with anterior structural reconstruction with titanium mesh cage and short segmental fusion for the treatment of congenital scoliokyphosis: the indications and preliminary results. *Spine* 2017;42(22):1687–1692
- 41 Basu S, Tikoo A. Posterior hemivertebrectomy and short segment fixation-long term results. *Childs Nerv Syst* 2017;33(2):321–328
- 42 Bollini G, Docquier PL, Viehweger E, Launay F, Jouve JL. Lumbar hemivertebra resection. *J Bone Joint Surg Am* 2006;88(5):1043–1052
- 43 Garrido E, Tome-Bermejo F, Tucker SK, Noordeen HN, Morley TR. Short anterior instrumented fusion and posterior convex non-instrumented fusion of hemivertebra for congenital scoliosis in very young children. *Eur Spine J* 2008;17(11):1507–1514
- 44 Klemme WR, Polly DW Jr, Orchowski JR. Hemivertebra excision for congenital scoliosis in very young children. *J Pediatr Orthop* 2001;21(6):761–764
- 45 Hedequist DJ, Hall JE, Emans JB. Hemivertebra excision in children via simultaneous anterior and posterior exposures. *J Pediatr Orthop* 2005;25(1):60–63
- 46 Ginsburg G, Mulconrey DS, Browdy J. Transpedicular hemiepiphyodesis and posterior instrumentation as a treatment for congenital scoliosis. *J Pediatr Orthop* 2007;27(4):387–391
- 47 Cheung KM, Zhang JG, Lu DS, K Luk KD, Y Leong JC. Ten-year follow-up study of lower thoracic hemivertebrae treated by convex fusion and concave distraction. *Spine* 2002;27(7):748–753
- 48 Bradford DS, Boachie-Adjei O. One-stage anterior and posterior hemivertebra resection and arthrodesis for congenital scoliosis. *J Bone Joint Surg Am* 1990;72(4):536–540
- 49 Xu W, Yang S, Wu X, Claus C. Hemivertebra excision with short-segment spinal fusion through combined anterior and posterior approaches for congenital spinal deformities in children. *J Pediatr Orthop B* 2010;19(6):545–550
- 50 Holte DC, Winter RB, Lonstein JE, Denis F. Excision of hemivertebrae and wedge resection in the treatment of congenital scoliosis. *J Bone Joint Surg Am* 1995;77(2):159–171
- 51 Lazar RD, Hall JE. Simultaneous anterior and posterior hemivertebra excision. *Clin Orthop Relat Res* 1999;(364):76–84
- 52 Winter RB, Burger EL. L5 hemivertebra resection and T12–S1 fusion in a 14-year-old female with a 36-year follow-up. *Spine* 2012;37(7):E445–E450
- 53 Chang DG, Yang JH, Suk SI, et al. Fractional curve progression with maintenance of fusion mass in congenital scoliosis: an 18-year follow-up of a case report. *Medicine (Baltimore)* 2017;96(36):e7746
- 54 Williams F, McCall IW, O'Brien JP, Park WM. Severe kyphosis due to congenital dorsal hemivertebra. *Clin Radiol* 1982;33(4):445–452
- 55 McMaster MJ. Spinal growth and congenital deformity of the spine. *Spine* 2006;31(20):2284–2287
- 56 Forrester MB, Merz RD. Descriptive epidemiology of hemivertebrae, Hawaii, 1986–2002. *Congenit Anom (Kyoto)* 2006;46(4):172–176
- 57 Tsirikos AI, McMaster MJ. Goldenhar-associated conditions (hemifacial microsomia) and congenital deformities of the spine. *Spine* 2006;31(13):E400–E407
- 58 Aydinli U, Ozturk C, Temiz A, et al. Comparison of two techniques in hemivertebra resection: transpedicular eggshell osteotomy versus standard anterior–posterior approach. *Eur J Orthop Surg Traumatol* 2007;17:1–5
- 59 Polly DW Jr, Rosner MK, Monacci W, Moquin RR. Thoracic hemivertebra excision in adults via a posterior-only approach. Report of two cases. *Neurosurg Focus* 2003;14(2):e9
- 60 Deviren V, Berven S, Smith JA, Emami A, Hu SS, Bradford DS. Excision of hemivertebrae in the management of congenital scoliosis involving the thoracic and thoracolumbar spine. *J Bone Joint Surg Br* 2001;83(4):496–500
- 61 Thompson AG, Marks DS, Sayampanathan SRE, Piggott H. Long-term results of combined anterior and posterior convex

- epiphysiodesis for congenital scoliosis due to hemivertebrae. *Spine* 1995;20(12):1380–1385
- 62 Suzuki N, Iida T. Surgical treatment of cervico-thoracic and thoracic multi-level hemivertebra in young children. –two cases report. *Orthop Proc* 2008;90-B(SUPP III):481
- 63 Qureshi MA, Pasha IF, Khaliq AB, et al. Outcome of hemivertebra resection in congenital thoracolumbar kyphosis and scoliosis by posterior approach. *J Pak Med Assoc* 2015;65(11, Suppl 3):S142–S146
- 64 Mladenov K, Kunkel P, Stuecker R. Hemivertebra resection in children, results after single posterior approach and after combined anterior and posterior approach: a comparative study. *Eur Spine J* 2012;21(3):506–513
- 65 Khan A, Barrey C, Massourides H, Perrin G. Lumbar hemivertebra in an adult treated by transpedicular osteotomy. *World Neurosurg* 2012;77(3-4):592.e5–592.e9
- 66 Kesling KL, Lonstein JE, Denis F, et al. The crankshaft phenomenon after posterior spinal arthrodesis for congenital scoliosis: a review of 54 patients. *Spine* 2003;28(3):267–271
- 67 Suk SI, Chung ER, Lee SM, Lee JH, Kim SS, Kim JH. Posterior vertebral column resection in fixed lumbosacral deformity. *Spine* 2005;30(23):E703–E710
- 68 Obeid I, Bourghli A, Vital JM. Thoracic hemivertebra resection by posterior approach for congenital scoliosis. *Eur Spine J* 2013;22(3):678–680