


A Continuous Suture Anastomosis Outperforms a Simple Interrupted Suture Anastomosis in Esophageal Elongation

Christina Oetzmann von Sochaczewski¹  Evangelos Tagkalos² Andreas Lindner¹ Hauke Lang²
Axel Heimann³ Oliver J. Muensterer¹

¹ Department of Pediatric Surgery, Universitätsmedizin der Johannes-Gutenberg-Universität, Mainz, Germany

² Department of General, Visceral and Transplant Surgery, Universitätsmedizin der Johannes-Gutenberg-Universität, Mainz, Germany

³ Institute for Neurosurgical Pathophysiology, Universitätsmedizin der Johannes-Gutenberg-Universität, Mainz, Germany

Address for correspondence Christina Oetzmann von Sochaczewski, MD, Klinik und Poliklinik für Kinderchirurgie, Universitätsmedizin Mainz, Langenbeckstr. 1, D-55131 Mainz, Germany (e-mail: c.oetzmann@gmail.com).

Eur J Pediatr Surg 2021;31:177–181.

Abstract

Introduction Long-gap esophageal atresia represents a distinct entity among the esophageal atresia spectrum. In many patients, achieving a reasonable anastomosis depends on some millimeters of tissue. We aimed to determine what effect the suturing technique would have on esophageal ex vivo elongation as it may determine the strength of a primary anastomosis.

Materials and Methods In an analysis of porcine esophagi from animals for slaughter (100–120 days old with a weight of 100–120 kg), we determined esophageal length gain of simple continuous and simple interrupted suture anastomoses subjected to linear traction until linear breaking strength was reached. Statistical power of 80% was ensured based on an a priori power analysis using five specimens per group in a separate exploratory experiment.

Results The simple continuous suture anastomosis in 15 porcine esophagi (\bar{x} = 4.47 cm, 95% confidence interval: 4.08–4.74 cm) outperformed the simple interrupted suture anastomosis in another 15 esophagi (\bar{x} = 3.03 cm, 95% confidence interval: 2.59–3.43 cm) in length gain (Δ = 1.44 cm, 95% confidence interval: 0.87–2.01 cm, $p < 0.0001$).

Conclusion Simple continuous anastomoses achieved higher length gain compared with simple interrupted suture anastomoses. This effect warrants an experimental assessment in vivo to assess its potential merits for clinical applicability.

Keywords

- ▶ esophageal biomechanics
- ▶ surgical suturing
- ▶ esophageal surgery
- ▶ swine

Introduction

Long-gap forms of esophageal atresia represent a separate entity within the esophageal atresia disease spectrum and pose a variety of challenges in their management.¹ Foker described holding the ends of the esophagus under tension for several minutes to enabling a primary repair of long-gap esophageal atresia by the resulting elongation.² However, as he acknowledges, this maneuver results in anastomotic

tension.³ Tension on the other hand has been blamed to be a reproducible risk factor for anastomotic stricture^{4,5} as well as anastomotic leakage^{5–7} in esophageal anastomoses, among others.^{8,9} We have recently been able to prove experimentally that several minutes of constant traction results in more pronounced esophageal elongation than a similar steady increase of traction forces.¹⁰ In the same report, we also investigated the durability of different anastomotic techniques and found that the simple

received
November 30, 2019
accepted
March 22, 2020
published online
May 18, 2020

© 2020, Thieme. All rights reserved.
Georg Thieme Verlag KG,
Rüdigerstraße 14,
70469 Stuttgart, Germany

DOI <https://doi.org/10.1055/s-0040-1710025>.
ISSN 0939-7248.

continuous suture outperforms the simple interrupted suture in terms of anastomotic resilience.¹⁰ We conducted a secondary analysis of these data to investigate whether the more durable simple continuous anastomosis would also allow for more esophageal elongation than the simple interrupted suture anastomosis.

Materials and Methods

The data on the resistance to traction forces of several anastomotic techniques is available elsewhere.¹⁰ In this experiment, we measured the elongation of the specimens during application of traction forces until failure of the anastomoses for simple continuous and simple interrupted suture anastomoses. Our methodology has been described in detail before.^{10,11} In brief, esophagi of swine (*Sus scrofa domestica*, weighing 100–120 kg at an age of 100–120 days) were obtained from a local abattoir (Färber, Alzey, Germany), stored in a humid atmosphere, and processed to the end of the experiment within 5 hours of slaughtering as described previously for the investigation of biomechanical tissue properties.^{11–15} Esophagi were freed from its surrounding tissue, mounted in a motorized horizontal test stand (Sauter THM, Sauter, Balingen, Germany), and subjected to linear traction until visible disruption of the circumferential muscular layer occurred. This was objectified by traction forces that did not increase beyond this point. A video of the endpoint has been published before to make this abstract description more accessible for the reader by its visual depiction.¹⁰ All anastomoses were constructed by the same surgeon (C.O.) at 13 cm distal to the upper esophageal sphincter using USP 4–0 polydioxanone (Ethicon, Norderstedt, Germany) sutures. Initial length of all esophagi was around 26 cm as depicted elsewhere.¹⁰ Suture bite length was 8 mm to the cut surface, with a 5-mm lateral advancement (→ Fig. 1). This summed up to a relatively uniform number of 10 stitches per anastomosis.¹⁰ All endpoints were verified by a second researcher (A.L.).

We used an exploratory investigation of five specimens per group to conduct an a priori power analysis using G*Power¹⁶ (version 3.9.1.2) to achieve statistical power of 80% for a two-tailed *t*-test for independent groups with an α -level of 5%. The measurements for the simple continuous anastomoses were randomly drawn from the basis of 28 measurements in the original study¹⁰ using R's random number generating algorithm to achieve a balanced experimental design. We conducted all statistical analyses using R (version 3.4.3) with the stats4 package (version 3.4.3). A Gaussian distribution within our results was confirmed with the Shapiro–Wilk test and homoscedasticity was tested by Bartlett's test. Comparisons were conducted by using Student's *t*-test. We used the bias corrected, accelerated bootstrap procedure¹⁷ to calculate the 95% confidence interval of the group mean with 10,000 iterations as recommended elsewhere¹⁸ using the groupwise-Mean function from the rcompanion package (version 1.13.2).¹⁹

Results

The simple continuous suture anastomosis (\bar{x} = 4.47 cm, 95% confidence interval: 4.08–4.74 cm) outperformed the simple interrupted suture anastomosis (\bar{x} = 3.03 cm, 95% confidence interval: 2.59–3.43 cm) in length gain (Δ = 1.44 cm, 95% confidence interval: 0.87–2.01 cm, $p < 0.0001$) (→ Fig. 2).

Discussion

Pigs were the traditional model in experimental pediatric esophageal surgery,²⁰ but have largely been replaced by rodent models.²¹ Recently, swine experienced a revival as a favorite model for experimental esophageal surgery,^{22–30} because porcine closely mimics human anatomy.^{20–22} Moreover, tissue equivalence of porcine and human esophagi³¹ supports using swine as an experimental model, in particular because tissue equivalence is a feature unique to the esophagus, but not to other organs, for example, the colon.³²

There has been an ongoing debate on the right anastomotic technique in adult esophageal surgery. The most common techniques have narrowed to stapled versus continuous hand-sewn anastomoses,³³ but recently also included robotic-assisted anastomoses.³⁴ In pediatric esophageal surgery, robot-assisted esophageal surgery has only been conducted experimentally in swine.^{35,36} Concerning staplers, we have previously shown that their use is currently not advisable due to size discrepancy between staplers and patient's anatomy.³⁷ Moreover, the vast majority of operations for esophageal atresia are still conducted via the open approach,^{38,39} which also suggests the comparison of hand-sewn techniques would have the widest relevance for the practicing pediatric surgeon.

Interestingly, the continuous outperformed the simple interrupted suture anastomosis for esophageal elongation, most probably due to a different dispersal of traction forces within the tissue: Traction might propagate along the suture into the organ and because the continuous suture has a higher contact surface compared with the simple interrupted suture anastomosis, enabling larger amplitude of esophageal elongation. This might explain why simple interrupted suture anastomoses did not achieve anastomotic resiliencies similar to the native organ.^{10,40}

Our experiment has a statistical power sufficient enough to ensure that we were not investigating noise but a true effect based on the a priori power analysis. Given the equivalence of reaction of porcine and human esophageal tissue to traction, our results strongly encourage the transition into an experiment with live animals to further investigate the phenomenon before transition into everyday clinical practice. The implementation of Myers' decades old dictum “the best oesophagus is the patient's own oesophagus”⁴¹ might be achieved by esophageal elongation following several minutes of traction,² but it also requires securing the length gain by prevention of anastomotic leakages. They are linked to anastomotic tension,^{5–7} which could be modified by using continuous suturing that tolerates more anastomotic tension¹⁰ and thereby esophageal elongation before anastomotic failure.

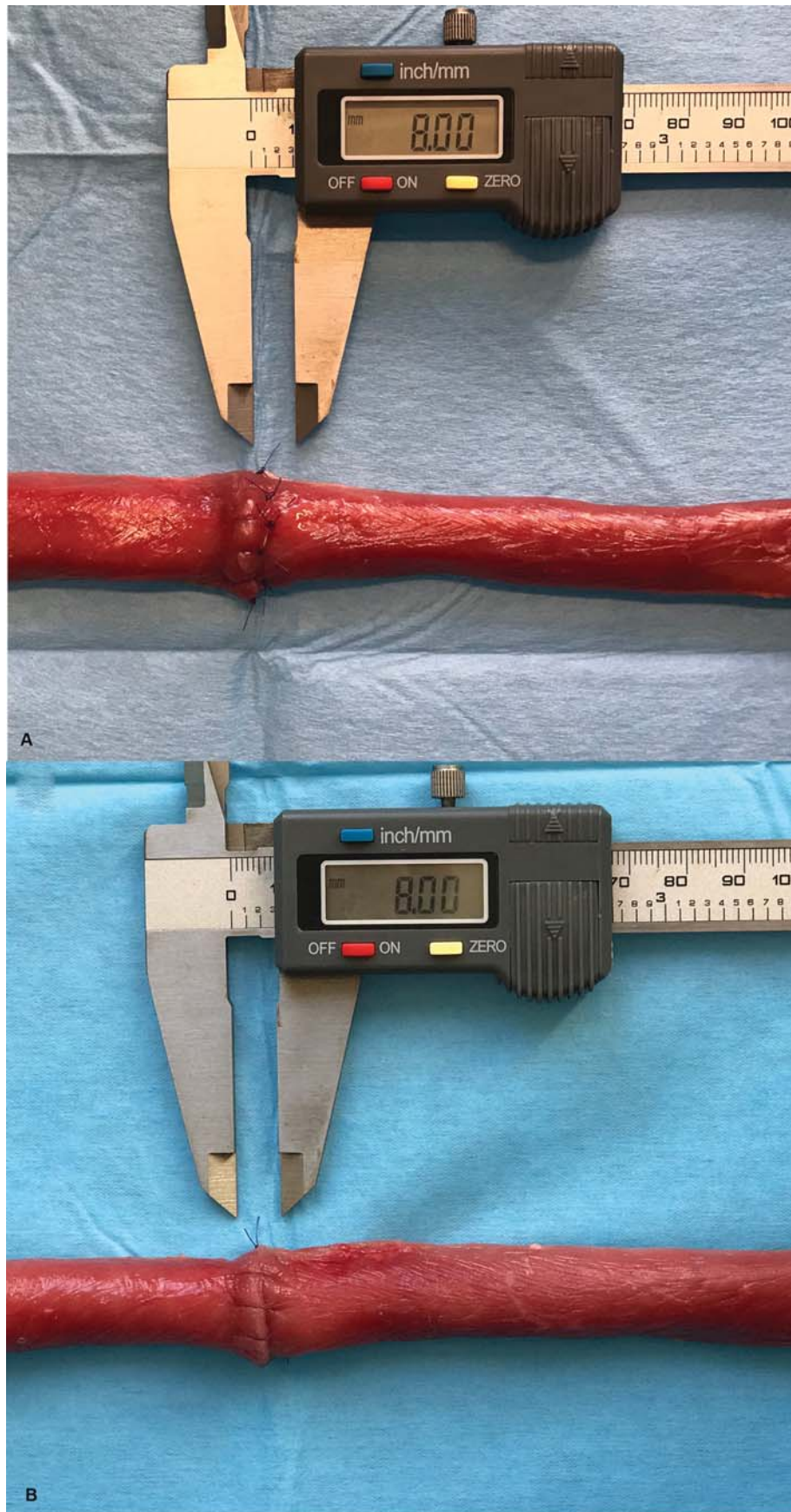


Fig. 1 Photographic documentation of the experimental procedures. (A) Simple interrupted suture anastomosis of 8 mm distance to cut surface and 5 mm lateral distance between the stitches. (B) Simple continuous anastomosis of 8 mm distance to the cut surface and 5 mm lateral distance between the stitches.

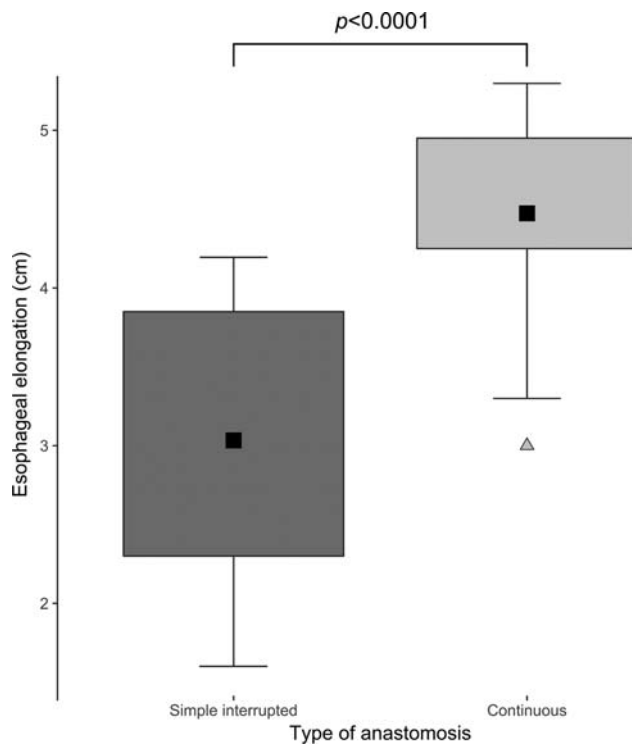


Fig. 2 Esophageal elongation of simple interrupted and continuous suture anastomoses. Simple interrupted suture anastomoses ($n = 15$). Data followed a normal distribution ($W = 0.933$, $p = 0.2991$). Continuous suture anastomoses ($n = 15$). Data had a normal distribution ($W = 0.906$, $p = 0.1163$). Homoscedasticity was present according to Bartlett's test ($K^2 = 0.942$, $p = 0.3317$). Tukey boxplot representing the interquartile range within the box with whiskers up to $1.5 \times$ the interquartile range. The black rectangle represents the mean and the triangle an outlier. Groups were compared with Student's t -test.

Conclusion

The simple continuous esophageal anastomosis outperforms the simple interrupted suture anastomosis in esophageal elongation and resistance to traction forces *ex vivo*. This result should be corroborated in an *in vivo* experiment to explore its suitability for clinical practice.

Conflict of Interest

None declared.

References

- Bairdain S, Zurakowski D, Vargas SO, et al. Long-gap esophageal atresia is a unique entity within the esophageal atresia defect spectrum. *Neonatology* 2017;111(02):140–144
- Foker JE, Linden BC, Boyle EM Jr, Marquardt C. Development of a true primary repair for the full spectrum of esophageal atresia. *Ann Surg* 1997;226(04):533–541
- Foker JE, Kendall TC, Catton K, Khan KM. A flexible approach to achieve a true primary repair for all infants with esophageal atresia. *Semin Pediatr Surg* 2005;14(01):8–15
- Michaud L, Guimber D, Sfeir R, et al. Sténose anastomotique après traitement chirurgical de l'atrésie de l'œsophage: fréquence, facteurs de risque et efficacité des dilatations œsophagiennes. *Arch Pediatr* 2001;8(03):268–274

- Schneider A, Blanc S, Bonnard A, et al. Results from the French National Esophageal Atresia register: one-year outcome. *Orphanet J Rare Dis* 2014;9(01):206
- Sillén U, Hagberg S, Rubenson A, Werkmäster K. Management of esophageal atresia: review of 16 years' experience. *J Pediatr Surg* 1988;23(09):805–809
- McKinnon LJ, Kosloske AM. Prediction and prevention of anastomotic complications of esophageal atresia and tracheoesophageal fistula. *J Pediatr Surg* 1990;25(07):778–781
- Urschel JD, Scott PG, Williams HTG. The effect of mechanical stress on soft and hard tissue repair; a review. *Br J Plast Surg* 1988;41(02):182–186
- Morse BC, Simpson JP, Jones YR, Johnson BL, Knott BM, Kotrady JA. Determination of independent predictive factors for anastomotic leak: analysis of 682 intestinal anastomoses. *Am J Surg* 2013;206(06):950–955
- Oetzmann von Sochaczewski C, Tagkalos E, Lindner A, et al. Esophageal biomechanics revisited: a tale of tenacity, anastomoses, and suture bite lengths in swine. *Ann Thorac Surg* 2019;107(06):1670–1677
- Oetzmann von Sochaczewski C, Tagkalos E, Lindner A, Lang H, Heimann A, Muensterer OJ. Technical aspects in esophageal lengthening: an investigation of traction procedures and suturing techniques in swine. *Eur J Pediatr Surg* 2019;29(05):481–484
- Behrend M, Kluge E, Schüttler W, Klempnauer J. Breaking strength of native and sutured trachea. An experimental study on sheep trachea. *Eur Surg Res* 2001;33(04):255–263
- Yang W, Fung TC, Chian KS, Chong CK. Directional, regional, and layer variations of mechanical properties of esophageal tissue and its interpretation using a structure-based constitutive model. *J Biomech Eng* 2006;128(03):409–418
- Carniel EL, Gramigna V, Fontanella CG, et al. Characterization of the anisotropic mechanical behaviour of colonic tissues: experimental activity and constitutive formulation. *Exp Physiol* 2014;99(05):759–771
- Carniel EL, Frigo A, Fontanella CG, et al. A biomechanical approach to the analysis of methods and procedures of bariatric surgery. *J Biomech* 2017;56:32–41
- Faul F, Erdfelder E, Lang A-G, Buchner A. G*Power 3: a flexible statistical power analysis program for the social, behavioral, and biomedical sciences. *Behav Res Methods* 2007;39(02):175–191
- Efron B. Better bootstrap confidence intervals. *J Am Stat Assoc* 1987;82(397):171–185
- Hesterberg TC. What teachers should know about the bootstrap: resampling in the undergraduate statistics curriculum. *Am Stat* 2015;69(04):371–386
- Mangiafico S. Rcompanion: Functions to Support Extension Education Program Evaluation; 2018. Available at: <https://CRAN.R-project.org/package=rcompanion>. Accessed September 5, 2018
- Livaditis A, Jönsson L. The piglet in experimental pediatric surgery. *Z Versuchstierkd* 1979;21(02):78–82
- Mortell A, Montedonico S, Puri P. Animal models in pediatric surgery. *Pediatr Surg Int* 2006;22(02):111–128
- Sullins VF, Traum PK, French SW, Wu BM, Dunn JCY, Lee SL. A novel method of esophageal lengthening in a large animal model of long gap esophageal atresia. *J Pediatr Surg* 2015;50(06):928–932
- Dibbern CB, Rose M, Ellebæk MB, Qvist N. The effect of intramural botulinum toxin injections on the elongation of the piglet oesophagus is time dependent. *Eur J Pediatr Surg* 2017;27(01):56–60
- Glenn IC, Bruns NE, Schomisch SJ, Ponsky TA. Creation of an esophageal atresia animal model using a bifurcated esophagus to maintain digestive tract continuity. *J Laparoendosc Adv Surg Tech A* 2017;27(10):1079–1084
- Bruns NE, Glenn IC, Craner DR, Schomisch SJ, Harrison MR, Ponsky TA. Magnetic compression anastomosis (magnamosis) in a porcine esophagus: proof of concept for potential application in esophageal atresia. *J Pediatr Surg* 2019;54(03):429–433

- 26 Oetzmann von Sochaczewski C, Heimann A, Linder A, Kempfski O, Muensterer OJ. Esophageal blood flow may not be directly influenced by anastomotic tension: an exploratory laser Doppler study in swine. *Eur J Pediatr Surg* 2019;29(06):516–520
- 27 Oetzmann von Sochaczewski C, Lindner A, Heimann A, et al. Beyond magnamosis: a method to test sutureless esophageal anastomotic devices in living swine by creating an esophageal bypass loop for natural oral nutrition. *J Laparoendosc Adv Surg Tech A* 2019;29(06):852–855
- 28 Muensterer OJ, Sterlin A, Oetzmann von Sochaczewski C, et al. An experimental study on magnetic esophageal compression anastomosis in piglets. *J Pediatr Surg* 2020;55(03):425–432
- 29 Jensen T, Wanczyk H, Sharma I, Mitchell A, Sayej WN, Finck C. Polyurethane scaffolds seeded with autologous cells can regenerate long esophageal gaps: an esophageal atresia treatment model. *J Pediatr Surg* 2019;54(09):1744–1754
- 30 Baumgart J, Deigendesch N, Lindner A, et al. Using multidimensional scaling in model choice for congenital oesophageal atresia: similarity analysis of human autopsy organ weights with those from a comparative assessment of Aachen Minipig and Pietrain piglets. *Lab Anim* 2020;54(06):576–587
- 31 Takada Y, Kent G, Filler RM. Circular myotomy and esophageal length and safe esophageal anastomosis: an experimental study. *J Pediatr Surg* 1981;16(03):343–348
- 32 Christensen MB, Oberg K, Wolchok JC. Tensile properties of the rectal and sigmoid colon: a comparative analysis of human and porcine tissue. *Springerplus* 2015;4(01):142
- 33 Yuan Y, Wang K-N, Chen L-Q. Esophageal anastomosis. *Dis Esophagus* 2015;28(02):127–137
- 34 Grimminger PP, van der Horst S, Ruurda JP, van Det M, Morel P, van Hillegersberg R. Surgical robotics for esophageal cancer. *Ann N Y Acad Sci* 2018;1434(01):21–26
- 35 Hollands CM, Dixey LN. Robotic-assisted esophagoesophagostomy. *J Pediatr Surg* 2002;37(07):983–985
- 36 Lorincz A, Langenburg SE, Knight CG, Gidell K, Rabah R, Klein MD. Robotically assisted esophago-esophagostomy in newborn pigs. *J Pediatr Surg* 2004;39(09):1386–1389
- 37 Holler A-S, Schwind M, Poplawska K, Muensterer OJ. Thoracoscopic tracheoesophageal N-fistula repair using a 5.8-mm miniature stapler for fistula division. *Eur J Pediatr Surg Rep* 2017;5(01):e55–e56
- 38 Zani A, Eaton S, Hoellwarth ME, et al. International survey on the management of esophageal atresia. *Eur J Pediatr Surg* 2014;24(01):3–8
- 39 Reusens H, Matthyssens L, Vercauteren C, van Renterghem K; Belgian Association of Paediatric Surgery (BELAPS). Multicentre survey on the current surgical management of oesophageal atresia in Belgium and Luxembourg. *J Pediatr Surg* 2017;52(02):239–246
- 40 Tagkalos E, Lindner A, Gruber G, et al. Using simple interrupted suture anastomoses may impair translatability of experimental rodent oesophageal surgery. *Acta Chir Belg* 2020;120(05):310–314
- 41 Myers NA. Oesophageal atresia: the epitome of modern surgery. *Ann R Coll Surg Engl* 1974;54(06):277–287