








# Spinal Cord Stimulation as a Treatment Option for Refractory Chemotherapy-Induced Peripheral Neuropathy: Case Report

## *Estimulação medular para tratamento da polineuropatia dolorosa induzida por quimioterapia: Relato de caso*

Arthur Lopes<sup>1,2</sup>  Kleber Duarte<sup>1,2,3</sup>  Catarina Lins<sup>1</sup> Gabriel Kubota<sup>1</sup>  Valquíria Silva<sup>2,3</sup>  
Ricardo Galhardoni<sup>2,4</sup>  Luciana Mendes Bahia Menezes<sup>1</sup> Irina Raicher<sup>1</sup>  Manoel J. Teixeira<sup>1,2,3</sup>   
Daniel C. Andrade<sup>1,2,3</sup> 

<sup>1</sup>Department of Neurology, Instituto do Câncer do Estado de São Paulo (Icesp), São Paulo, São Paulo, Brazil

<sup>2</sup>Neurosurgery Medical Laboratory (LIM-62), Universidade de São Paulo (USP), São Paulo, Brazil

<sup>3</sup>Pain Center, Department of Neurology, Universidade de São Paulo (USP), São Paulo, São Paulo, Brazil

<sup>4</sup>Department of Neurology, Faculdade de Medicina, Universidade Cidade de São Paulo (Unicid), São Paulo, São Paulo, Brazil

**Address for correspondence** Arthur José Maia Lopes, MD, Divisão de Clínica Neurocirúrgica do Hospital das Clínicas da FMUSP, Instituto Central, Av. Dr. Enéas de Carvalho Aguiar, 255, 5° andar, sala 5.084, Cerqueira César, São Paulo, 05403-900, Brazil  
(e-mail: arthurjlopes@gmail.com).

Arq Bras Neurocir 2020;39(3):228–231.

### Abstract

#### Keywords

- ▶ spinal cord stimulation
- ▶ chemotherapy-induced peripheral neuropathy
- ▶ colorectal cancer

Colorectal cancer is one of the most common oncological diseases. Chemotherapy is usually recommended as an adjuvant treatment for stage-II, -III, and -IV tumors. Approximately 10% of the patients develop neuropathic pain after chemotherapy, and they may remain refractory despite the administration of drugs that are commonly used to treat neuropathic pain. Spinal cord stimulation is a good treatment option for neuropathic pain of the lower limbs, and it should be trialed in patients with chemotherapy-induced peripheral neuropathy. We report the case of a patient with oxaliplatin-induced neuropathy and neuropathic pain refractory to oral medication who was successfully treated by spinal cord stimulation.

### Resumo

#### Palavras-chave

- ▶ estimulação medular espinhal
- ▶ neuropatia periférica induzida por quimioterapia
- ▶ câncer colorretal

O câncer colorretal é uma das neoplasias mais comuns na população em geral. A quimioterapia é habitualmente recomendada como tratamento adjuvante para tumores em estágios II, III e IV. Aproximadamente 10% dos pacientes irão desenvolver dor neuropática após a quimioterapia e eles podem se tornar refratários apesar da utilização de medicamentos para tratamento de dor neuropática. A estimulação medular espinhal é uma intervenção usualmente efetiva para alívio da dor neuropática em membros inferiores e deve ser testada em pacientes com neuropatia dolorosa induzida por quimioterapia. Nós descrevemos o caso de uma paciente portadora de neuropatia induzida por quimioterapia e dor neuropática refratária a medicações orais, a qual foi tratada de maneira bem-sucedida pela estimulação medular espinhal

received  
August 19, 2019  
accepted  
March 10, 2020

DOI <https://doi.org/10.1055/s-0040-1709985>.  
ISSN 0103-5355.

Copyright © 2020 by Thieme Revinter Publicações Ltda, Rio de Janeiro, Brazil

License terms



## Introduction

Colorectal cancer (CRC) will affect 6% of the Western population.<sup>1</sup> Similar to other cancers, chemotherapy-based treatments are the mainstay of CRC control. Neuropathy is a common chemotherapy complication, and ~70% of the patients present with some degree of neuropathic symptoms during treatment. Moreover, up to 10% of the patients develop long-term neuropathic pain after cancer, adding another layer of burden to the lives of cancer survivors.<sup>2</sup> Colorectal cancer is the third most common type of cancer. In Brazil, its incidence is estimated to be ~36,000 new cases per year. The overall survival rate is 65% at 5 years, and 58% at 10 years. Adjuvant chemotherapy is usually recommended for stages II, III, and IV, and oxaliplatin is a part of almost all of the chemotherapy regimens. If we consider that at least 10% of the patients receiving oxaliplatin will develop chronic neuropathy, then there will be ~3,300 new cases of chemotherapy-induced peripheral neuropathy (CIPN) associated with the oxaliplatin treatment in Brazil annually. In randomized controlled trials, very few drugs have shown efficacy in controlling chemotherapy-related neuropathic pain, and patients may remain refractory despite the administration of drugs commonly used to treat neuropathic pain, such as anticonvulsants (gabapentinoids), tricyclic antidepressants, serotonin-norepinephrine reuptake inhibitors (SNRIs), and opioids. After getting the approval of the institutional review board, we report the case of a patient with oxaliplatin-induced neuropathy and neuropathic pain refractory to oral medication who was successfully treated by spinal cord stimulation (SCS).

## Case Report

A 51-year-old woman diagnosed with CRC underwent right hemicolectomy and tumor resection (the pathological examination revealed an adenocarcinoma) and received a systemic fluorouracil, leucovorin and oxaliplatin (FLOX) regimen as adjuvant therapy. After the second cycle of chemotherapy, she developed grade-3 neuropathy, and the chemotherapy was discontinued. She then developed severe cold allodynia and painful dysesthesia of the hands and pharyngolaryngeal dysesthesia occasionally when drinking cold water. Her cancer was controlled; however, six months later, she developed severe burning and tingling pain in the lower limbs. Upon neurological examination, she had glove- and stocking-like distribution of cold and pain hypoesthesia associated with intense dynamic mechanical allodynia in both feet. Axonal sensory-predominant length-dependent polyneuropathy was confirmed by nerve conduction tests, and oxaliplatin-induced neuropathic pain was diagnosed. The patient received first-line (pregabalin, gabapentin, amitriptyline, venlafaxine, duloxetine), second-line (subcutaneous botulinum toxin injection, tramadol) and third-line (oxycodone and methadone) treatments at the maximal tolerated dosage with no significant clinical improvement. She was eventually discharged from regular oncological follow-up after being considered cured of her CRC, but the

refractory pain persisted. AnSCS trial was then proposed. The paddle was implanted at level T10–T12 (tripolar electrode – Specify, Medtronic, Minneapolis, MN, EUA. 5-6-5; PrimeAdvanceSureScan MRI neurostimulator – Medtronic, Dublin, Ireland) with a stimulation trial lasting seven days. During this trial period, she had significant improvement in her pain in both lower limbs – the 11-point numeric rating scale (NRS, in which 0 means no pain and 10 means the maximum tolerable pain) decreased ~50% (the presurgical NRS was 9, and the postoperative NRS was 4), and the pulse generator was then durably implanted.

After surgery, she was kept on continuous stimulation at a frequency of 40 Hz, a pulse width of 350 ms, and a voltage of 1 V (►Fig. 1), and the improvement was maintained with the pain well-controlled at the last outpatient follow-up at one year. At this visit, the neuropathic pain symptom inventory (NPSI) score was reduced from 55/100 (baseline) to 25/100, with a greater reduction in the superficial-spontaneous and evoked pain and dysesthesia subscores (►Table 1). The pain medications were progressively reduced (►Table 2).

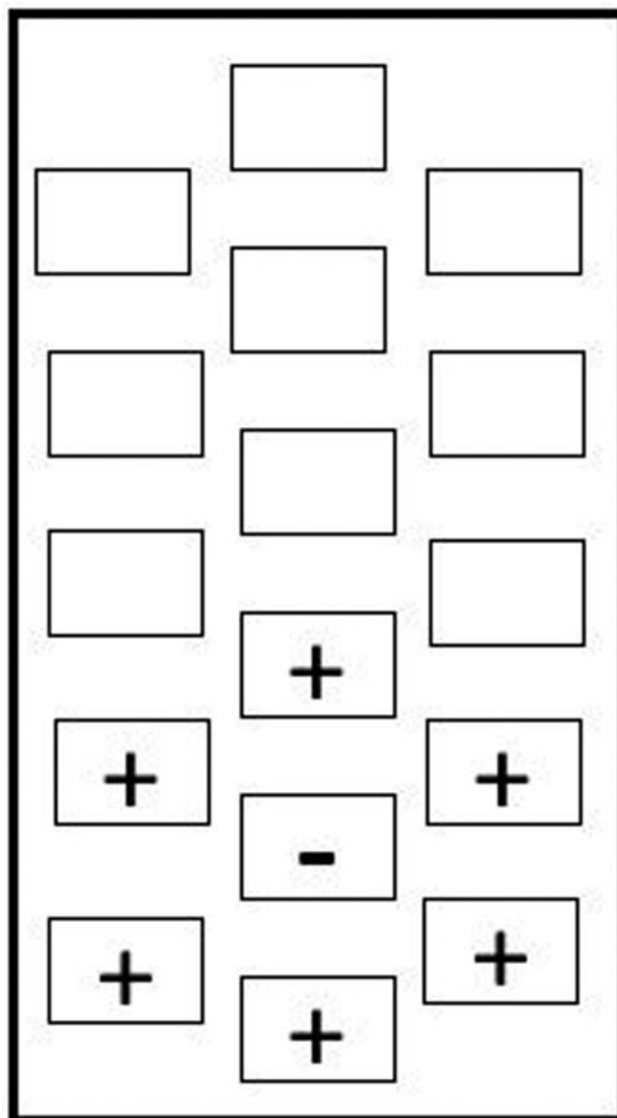


Fig. 1 5-6-5 electrode configuration.

**Table 1** Pre- and postoperative Neuropathic Pain Symptom Inventory subscores

Neuropathic Pain Symptom Inventory subscores	Preoperative	Postoperative
Superficial spontaneous pain	9/10	0/10
Deep spontaneous pain	17/20	16/20
Paroxysmal pain	1/20	1/20
Evoked pain	14/30	2/30
Paresthesia/dysesthesia	14/20	6/20

**Table 2** Medications taken by the patient before and after the implantation of spinal cord stimulation

Drug	Preoperative	Last follow-up
Pregabalin	600 mg	none
Venlafaxine	225 mg	150 mg
Lamotrigine	400 mg	400 mg
Methadone	40 mg	15 mg
Chlorpromazine	40 mg	24 mg

## Discussion

Neuropathic pain is a common finding in cancer patients, and it is present in up to 40% of the cases. There are many etiologies related to neuropathic pain, such as, nerve or plexus compression by the tumor, direct tumor invasion, central pain, paraneoplastic syndrome, radiation-induced neuritis, chemotherapy-induced neuropathy, and others.<sup>3</sup>

In oncological patients, CIPN is a common complication. Starabova and Vetter<sup>4</sup> reported six main types of chemotherapy drugs associated with an increased risk of neuropathy: taxanes (paclitaxel and docetaxel), vinca alkaloids (vincristine and vinblastine), platinum-based antineoplastics (oxaliplatin and cisplatin), epothilones, proteasome inhibitors, and immunomodulatory drugs (thalidomide). The main risk factors associated with the development of CIPN are older age, concomitant diabetes mellitus, previous neuropathy, smoking, and abnormal creatinine clearance.<sup>3-5</sup>

Depending on the severity of the neuropathy, the anti-neoplastic drugs may need to be reduced in dose, and, in some instances, discontinued. Some patients may improve after these alterations in treatment regimens, but, in some instances, they do not revert the neuropathy. Tricyclic antidepressants (amitriptyline, nortriptyline, imipramine), gabapentinoids (gabapentin and pregabalin), SNRIs (venlafaxine and duloxetine), anticonvulsants (lamotrigine and carbamazepine), and opioids (tramadol, methadone) are the main therapeutic options to treat neuropathic pain in general, and are frequently prescribed in CIPN. Even with the best medical treatment, many patients will not achieve adequate relief of pain and sensory symptoms. In this population, another treatment option for neuropathic pain treatment should be considered.<sup>4,6</sup> Some studies have reported good results after treatment with topical lidocaine and capsaicin patches. Botulinum toxin has also been described as an effective treatment for neuropathic pain in some patients.<sup>6,7</sup>

Spinal cord stimulation is the most commonly recommended surgical treatment for patients with neuropathic pain in the lower limbs that has failed to respond to optimal analgesic drug treatment and physical therapy. It is mainly indicated for failed back surgery syndrome and complex regional pain syndrome.<sup>8,9</sup> Most patients will experience more than 50% of pain relief at the long-term follow-up.<sup>8</sup> Spinal cord stimulation provokes changes in the integration of autonomic, sensory and motor information in the spinal cord, and it also triggers top-down inhibitory modulation of nociceptive inputs.<sup>9,10</sup> While SCS is frequently indicated for non-cancer-related neuropathic pain, long-term cancer survivors may suffer from neuropathic pain similar to that experienced by chronic diabetic or postherpetic neuralgia patients.

Spinal cord stimulation has already been described as a successful treatment for CIPN. Braun Filho and Braun<sup>11</sup> reported one case of SCS following vincristine therapy, which provided pain relief above 50% after percutaneous SCS. Cata et al,<sup>12</sup> in 2004, also reported two cases of SCS implantation following CIPN. The first patient had more than 90% of pain relief 4 months after surgery, and the second had more than 50% of pain relief at the 3-month follow-up. Abd-Elseyed et al<sup>13</sup> described a patient who underwent lead placement and had 95% of pain relief, which was maintained 2 years after treatment initiation (– **Table 3**). In all of the reports, the patients underwent the SCS trial before permanent implantation.<sup>11-13</sup> There were no reports of failed SCS trials, despite the potential bias related to negative results.

**Table 3** Previous reports of spinal cord stimulation after chemotherapy-induced peripheral neuropathy

	Chemotherapy regimen	Type of spinal cord stimulation	Follow-up	Pain relief
Abd-Elseyed et al <sup>13</sup>	Not described	Laminectomy	2 years	95%
Braun Filho and Braun <sup>11</sup>	Vincristine	Percutaneous	3 months	> 50%
Cata et al <sup>12</sup>	Not described	Laminectomy	4 months	> 90%
Cata et al <sup>12</sup>	Vincristine	Laminectomy	3 months	> 50%

## Conclusion

The present paper describes a long-term follow-up successful SCS for CIPN. The improvement was mainly observed in the evoked component of neuropathic pain. While this strategy warrants a cost-effectiveness assessment, the existing case-reports suggest that SCS could be a valid option to treat neuropathic patients refractory to the usual medical management. A clinical SCS trial in cancer survivors with CIPN refractory to medical treatment would help better support this approach and better appraise its potential limitations, which, for the time being, are perhaps underreported.

### Conflict of Interests

The authors have no conflict of interests to declare.

## References

- Hawk ET, Levin B. Colorectal cancer prevention. *J Clin Oncol* 2005; 23(02):378–391
- de Andrade DC, Jacobsen Teixeira M, Galhardoni R, et al; PreOx Workgroup. PreOx Workgroup. Pregabalin for the prevention of oxaliplatin-induced painful neuropathy: a randomized, double-blind trial. *Oncologist* 2017;22(10):1154–e105
- Hershman DL, Till C, Wright JD, et al. Comorbidities and Risk of Chemotherapy-Induced Peripheral Neuropathy Among Participants 65 Years or Older in Southwest Oncology Group Clinical Trials. *J Clin Oncol* 2016;34(25):3014–3022
- Starobova H, Vetter I. Pathophysiology of chemotherapy-induced peripheral neuropathy. *Front Mol Neurosci* 2017;10:174
- Seretny M, Currie GL, Sena ES, et al. Incidence, prevalence, and predictors of chemotherapy-induced peripheral neuropathy: A systematic review and meta-analysis. *Pain* 2014;155(12):2461–2470
- Finnerup NB, Attal N, Haroutounian S, et al. Pharmacotherapy for neuropathic pain in adults: a systematic review and meta-analysis. *Lancet Neurol* 2015;14(02):162–173
- Attal N, de Andrade DC, Adam F, et al. Safety and efficacy of repeated injections of botulinum toxin A in peripheral neuropathic pain (BOTNEP): a randomised, double-blind, placebo-controlled trial. *Lancet Neurol* 2016;15(06):555–565
- Taylor RS, Desai MJ, Rigoard P, Taylor RJ. Predictors of pain relief following spinal cord stimulation in chronic back and leg pain and failed back surgery syndrome: a systematic review and meta-regression analysis. *Pain Pract* 2014;14(06):489–505
- de Andrade DC, Bendib B, Hattou M, Keravel Y, Nguyen JP, Lefaucheur JP. Neurophysiological assessment of spinal cord stimulation in failed back surgery syndrome. *Pain* 2010;150(03):485–491
- Tazawa T, Kamiya Y, Kobayashi A, et al. Spinal cord stimulation modulates supraspinal centers of the descending antinociceptive system in rats with unilateral spinal nerve injury. *Mol Pain* 2015; 11:36
- Braun Filho JL, Braun LM. Estimulação medular espinhal para tratamento da polineuropatia dolorosa refratária induzida por quimioterapia. *Rev Bras Anesthesiol* 2007;57(05):533–538
- Cata JP, Cordella JV, Burton AW, Hassenbusch SJ, Weng HR, Dougherty PM. Spinal cord stimulation relieves chemotherapy-induced pain: a clinical case report. *J Pain Symptom Manage* 2004;27(01):72–78
- Abd-Elseyed A, Schiavoni N, Sachdeva H; Abd-Elseyed A. Efficacy of spinal cord stimulators in treating peripheral neuropathy: a case series. *J Clin Anesth* 2016;28:74–77