

Biomechanical Effects of Tibial Plateau Levelling Osteotomy on Joint Instability in Normal Canine Stifles: An *In Vitro* Study

Masakazu Shimada¹ Tetsuya Takagi² Nobuo Kanno¹ Satoshi Yamakawa² Hiromichi Fujie²
Tom Ichinohe^{1,3} Shuji Suzuki¹ Yasuji Harada¹ Yasushi Hara¹

¹Division of Veterinary Surgery, Department of Veterinary Science, Faculty of Veterinary Medicine, Nippon Veterinary and Life Science University, Musashino-shi, Tokyo, Japan

²The Biomechanics Laboratory, Faculty of System Design, Tokyo Metropolitan University, Asahigaoka, Hino-shi, Tokyo, Japan

³Veterinary Teaching Hospital, Azabu University, Sagami-hara-shi, Kanagawa, Japan

Address for correspondence Masakazu Shimada, DVM, Division of Veterinary Surgery, Department of Veterinary Science, Faculty of Veterinary Medicine, Nippon Veterinary and Life Science University, 1-7-1 Kyonan-cho, Musashino-shi, Tokyo 180-8602, Japan (e-mail: masakazu42710@gmail.com).

Vet Comp Orthop Traumatol 2020;33:301–307.

Abstract

Objective The aim of the study was to determine the changes in biomechanical characteristics following tibial plateau levelling osteotomy (TPLO) using simulated manual tests.

Study Design Twenty-one stifles from healthy Beagle dogs that had undergone TPLO or had not (control) were first tested in the intact form, and then the cranial cruciate ligament (CrCL) was transected in each to provide four test situations: control-intact, control-CrCL-transected, TPLO-intact and TPLO-CrCL-transected. The stifles were then analysed using a robotic joint biomechanical testing system. The craniocaudal drawer, axial rotation and proximal compression tests were applied.

Results The craniocaudal displacement during the drawer test was not significantly different between the control-intact and TPLO-intact. However, the displacement was significantly greater in the TPLO-CrCL-transected than in the control-intact. In the axial rotation test, the internal–external (IE) rotation was significantly greater in the TPLO-intact than in the control-intact. Similarly, the IE rotation was significantly greater in the TPLO-CrCL-transected than in the control-CrCL-transected. In the proximal compression test, craniocaudal displacement was not significantly different among the control-intact, TPLO-intact and TPLO-CrCL-transected.

Conclusion These findings suggest that TPLO influences the tension of the collateral ligaments and might generate laxity of the tibiofemoral joint. Instability after the osteotomy might be associated with the progression of osteoarthritis.

Keywords

- ▶ dog
- ▶ biomechanical effect
- ▶ six-degree-of-freedom robotic testing system
- ▶ cranial cruciate ligament
- ▶ tibial plateau levelling osteotomy

Introduction

Cranial cruciate ligament (CrCL) rupture is an orthopaedic disease that occurs with high frequency in dogs. Dynamic stabilizers, such as the quadriceps muscle and static stabil-

izers, such as the joint capsule, ligaments and meniscus, stabilize the stifle joint. The major ligaments that mediate stifle stabilization are the CrCL, caudal cruciate ligament, medial collateral ligament and lateral collateral ligament. The CrCL plays a vital role in maintaining stifle stability by

received

April 15, 2019

accepted after revision

February 24, 2020

published online

April 13, 2020

© 2020 Georg Thieme Verlag KG
Stuttgart · New York

DOI <https://doi.org/>

10.1055/s-0040-1709505.

ISSN 0932-0814.

preventing cranial tibial drawer movement, limiting joint hyperextension and preventing excessive internal tibial rotation, in combination with the caudal cruciate ligament.¹

The clinical efficacy of tibial plateau levelling osteotomy (TPLO) is widely recognized. Tibial plateau levelling osteotomy is a functional stabilization method that was first described by Slocum and Slocum.² This surgical method involves an osteotomy and rotation of the proximal tibia to correct the tibial plateau angle (TPA). The goal of TPLO is to neutralize cranial tibial thrust and prevent cranial displacement of the tibia in the stance phase.²

Tibial plateau levelling osteotomy is a useful treatment for CrCL rupture because it provides early functional restoration.³ However, TPLO cannot prevent the progression of osteoarthritis secondary to CrCL rupture.^{4,5} Osteoarthritis may develop due to chronic ligament degeneration, greater stifle instability following CrCL rupture and changes in biomechanical characteristics following the TPLO-induced changes in the anatomical conformation of the tibia. Previous studies have compared stifles that have undergone CrCL resection and TPLO with intact joints.^{6–8} However, in such studies, it is difficult to attribute changes in kinematics specifically to either CrCL resection or TPLO. Therefore, we aimed in the present study to determine not only the effect of CrCL resection, but also the changes induced by TPLO, by comparing the effects of the presence and absence of CrCL in control and TPLO-treated stifles. Many previous studies have shown changes in stability induced by axial loading or during the craniocaudal drawer test.^{6–9} However, the CrCL is also considered to play a role in the resistance of the joint to axial rotational force; therefore, we also aimed to assess the effects of TPLO and CrCL on this parameter.

We hypothesized that TPLO stabilizes the joint with respect to axial loading, but creates instability with respect to cranial drawer and axial rotation. Therefore, we aimed to determine the biomechanical effects of TPLO on stifle joint stability, by performing the craniocaudal drawer, axial rotation and proximal compression tests in control and TPLO-treated stifles, with and without an intact cranial cruciate ligament, using a robotic system.

Materials and Methods

Animals

The stifle joints used in this study were obtained from 21 healthy Beagle dogs that had been euthanatized for other reasons. The stifles were divided into two groups: those that did not undergo TPLO (control group) and those that did (TPLO group). The characteristics of each group are shown in ► **Table 1**. This study was approved by the Animal Experiment Committee and Bioethics Committee of our university (approval number: 28S-57).

Specimen Preparation

All soft tissues, except the collateral ligaments, the cruciate ligaments, menisci, joint capsule, patella and patellar ligament, were removed from the stifle joint, to create a bone-ligament model, based on the method of Kanno and colleagues.⁹ A

Table 1 Characteristics of the control and TPLO groups

Group	Control	TPLO
Number	<i>n</i> = 10	<i>n</i> = 11
Age (months)	21.4 ± 5.9	14.9 ± 3.1
Sex, M:F	9:1	6:5
Body weight (kg)	11.2 ± 1.3	11.2 ± 1.9

Abbreviations: F, female; M, male; TPLO, tibial plateau levelling osteotomy. Note: Data are presented as mean ± standard deviation.

mediolateral radiograph of each stifle was obtained, and the TPA was measured according to the method of Warzee and colleagues.⁶ A craniocaudal radiograph was also obtained to check for deformities, such as varus or valgus. In the TPLO group, surgery was performed according to the method of Slocum and Slocum.² We performed an osteotomy, rotated the proximal segment and applied temporary fixation using Kirschner wire. Radiographs were then obtained and the TPA was measured again. If the TPA was within the range of 6.5 ± 2.0 degrees, we performed fixation using a 2.4-mm TPLO locking compression plate (Johnson & Johnson; New Brunswick, New Jersey, United States). After processing, radiographs were again obtained and the postoperative TPA was measured. Next, the proximal femur and distal tibia were fixed using dental resin (GC OSTRON II; GC Corporation, Tokyo, Japan) and a cylindrical paper tube. To standardize between specimens, Kirschner wires were inserted in the bone axis of the femur and tibia. The resin was fixed at the centre of the tube so that the wires could be clamped by the robot. After fixing the bones with screws from all sides, so that the Kirschner wires were perpendicular to the centre of the tube, the resin was placed into the tube. At this time, the insertions of the medial and lateral collateral ligaments were marked with a surgical pen, because the coordinate system was determined on the basis of these marks. The specimens were then wrapped with gauze soaked in lactated Ringer's solution and cryopreserved at –20°C. They were thawed at 4°C the day before examination and testing by the robotic system.

Six-Degree-of-Freedom Robotic Testing System

A custom-made six-degree-of-freedom robotic testing system developed by Fujie and colleagues^{10–13} was used for the testing (► **Fig. 1**). This system enables the simulation of physiological stifle joint motion that is controlled with respect to either position or force, using a coordinate system (Grood and Sun-tay¹⁴) in vitro.¹² The coordinate system consists of three axes that are used to assess rotation and translation in six-degree-of-freedom. The motion can be defined in terms of three rotations (flexion–extension, internal–external [IE], varus–valgus) and three translations (medial–lateral, craniocaudal, proximal–distal) (► **Fig. 2**). In the robotic system, the flexion–extension axis is defined using the femur and the IE rotation axis is defined using the tibia based on bone landmarks and the manipulator position. The varus–valgus axis is defined by the line perpendicular to the flexion–extension and IE rotation axes. This new robotic system utilizes a real-time controller, which made it possible to speed up the control cycle in this study.¹⁰




Fig. 1 The testing system used in this study. This consisted of a 6-degree-of-freedom manipulator with a 6-degree-of-freedom universal force/moment sensor. The femur is on the left and the tibia is on the right. The suture coming out of the joint is placed as a mark when the cranial cruciate ligament is cut. The cable transmits the data from the sensor to the computer.

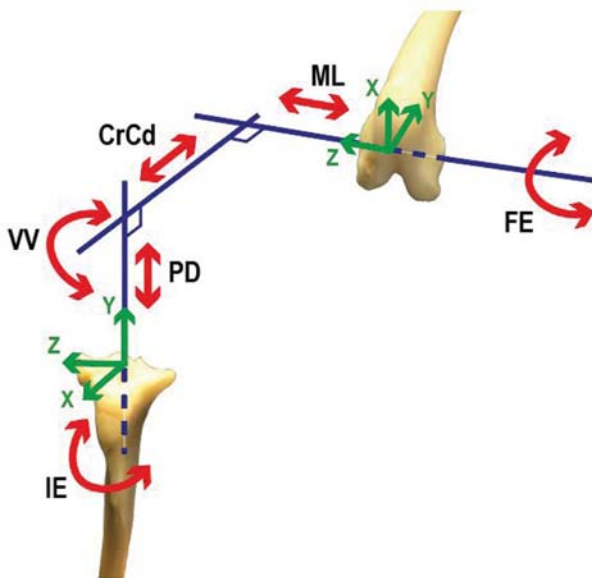


Fig. 2 The stifle coordinate system and stability control in each direction. This coordinate system consists of three rotational axes and their translations: flexion–extension (FE), internal–external (IE), varus–valgus (VV), medial–lateral (ML), cranial–caudal (CrCd) and proximal–distal (PD).

Testing Protocol

The stifle was extended as much as possible, with 0.5 Nm of extension torque, and the flexion–extension angle of the stifle, measured using a goniometer, was defined as the extension position. The mean extension of the control group was 153 degrees; therefore, 153 degrees was used as the extension value for the TPLO group. The craniocaudal drawer, axial rotation and proximal compression tests were performed at this degree of extension, and at 135 and 120 degrees, using the

robotic testing system. In the craniocaudal drawer test, as for the cranial drawer test,¹⁵ craniocaudal drawer loads of up to 30 N were applied to the stifles, while maintaining the joint angle and keeping the other four-degree-of-freedom forces/torques at 0. The six-degree-of-freedom displacement was then recorded and the range of motion during the craniocaudal displacement was calculated. In the axial rotation test, 1 Nm of IE torque was applied to the stifle joints, as in the craniocaudal drawer test, to measure the range of motion during IE rotation. In the proximal compression test, to mimic the method of clinical diagnosis (the positive cranial tibial thrust test),¹⁵ 30 N of proximal force was applied to the stifle joint, while maintaining all the rotation angles and keeping the medial–lateral and craniocaudal forces at 0; the six-degree-of-freedom displacement was then recorded. This test was used to assess craniocaudal displacement.

Test Situations

The stifles were allocated to TPLO and control groups, tested as intact stifles and then the CrCL were transected in half the joints (CrCL-transected) to provide four test situations: control-intact, control-CrCL-transected, TPLO-intact and TPLO-CrCL-transected.

Statistical Analysis

SPSS software version 26 (SPSS Inc., Chicago, Illinois, United States) was used for the statistical analysis. One-way analysis of variance was performed in each case, then to compare the changes between each tested joint angle, Tukey's honest significant difference test was used *post hoc*. Comparisons among the groups were made using the Tukey–Kramer test. Differences were considered to be significant when $p < 0.05$.

Results

The TPA in the control group was 32.0 ± 3.0 degrees. In the TPLO group, the preoperative TPA was 30.4 ± 2.6 degrees and the postoperative TPA was 6.4 ± 2.6 degrees. The displacement values for each test are shown in ►Tables 2 and 3.

Comparisons of Differences in the Tested Joint Angles

Craniocaudal Drawer Test

No significant differences in the tested angles were found in the control-intact and TPLO-intact groups, but in the control-CrCL-transected and TPLO-CrCL-transected groups the craniocaudal displacement was larger at both 135 and 120 degrees than at extension. Therefore, following CrCL transection, there was a tendency for the value to increase with flexion.

Axial Rotation Test

In the control-intact and TPLO-intact groups, significantly greater IE rotation was found at 135 and 120 degrees than at extension, and at 120 than at 135 degrees. In the control-CrCL-transected and TPLO-CrCL-transected groups, there was greater IE rotation at both 135 and 120 degrees than at extension. Therefore, in all these situations, there was a tendency for the value to increase with flexion.

Proximal Compression Test

In the control-intact and control-CrCL-transected groups, there was significantly greater craniocaudal displacement at

both 135 and 120 degrees than during extension. In TPLO-intact and TPLO-CrCL-transected groups, no significant differences in the tested angles were found. Therefore, following CrCL transection, there was a tendency for the value to increase with flexion.

Comparisons among the Joint Situations

Craniocaudal Drawer Test

At each angle, the craniocaudal drawer test result showed significantly greater craniocaudal displacement in TPLO-CrCL-transected stifles than in control-intact, control-CrCL-transected or TPLO-intact stifles. In addition, control-CrCL-transected stifles showed significantly greater craniocaudal displacement than control-intact stifles. However, no significant difference was found between control-intact and TPLO-intact stifles. Therefore, there was a tendency for the value to increase following CrCL transection.

Axial Rotation Test

In extension, there was significantly less IE rotation in control-intact than in control-CrCL-transected, TPLO-intact or TPLO-CrCL-transected stifles. In addition, there was significantly greater IE rotation in TPLO-CrCL-transected stifles than in control-CrCL-transected and TPLO-intact stifles. At 135 degrees, there was significantly less IE rotation in control-intact than in TPLO-intact or TPLO-CrCL-transected stifles. In addition, there was significantly greater IE rotation in TPLO-CrCL-transected stifles than in control-CrCL-transected stifles.

Table 2 Comparisons of differences in the outcome measures between the tested joint angles

	Craniocaudal displacement at craniocaudal drawer test (mm)		
	Extension	135°	120°
Control-intact	1.75 ± 0.48	1.95 ± 0.67	1.75 ± 0.77
Control-CrCL-transected	$4.33 \pm 2.09^{a,b}$	6.16 ± 2.91^a	6.93 ± 3.35^b
TPLO-intact	2.91 ± 0.72	2.85 ± 0.97	2.81 ± 0.87
TPLO-CrCL-transected	$10.37 \pm 3.58^{a,b}$	11.37 ± 3.63^a	12.17 ± 3.84^b
	Internal-external rotation at axial rotation test (°)		
	Extension	135 degrees	120 degrees
Control-intact	$44.75 \pm 7.56^{a,b}$	$65.65 \pm 9.10^{a,c}$	$74.45 \pm 7.84^{b,c}$
Control-CrCL-transected	$61.77 \pm 6.17^{a,b}$	75.22 ± 7.39^a	78.05 ± 9.13^b
TPLO-intact	$72.29 \pm 8.26^{a,b}$	$84.50 \pm 8.64^{a,c}$	$89.45 \pm 8.02^{b,c}$
TPLO-CrCL-transected	$86.27 \pm 8.24^{a,b}$	94.53 ± 10.52^a	97.17 ± 11.62^b
	Craniocaudal displacement at proximal compression test (mm)		
	Extension	135 degrees	120 degrees
Control-intact	$0.14 \pm 0.05^{a,b}$	0.32 ± 0.23^a	0.30 ± 0.14^b
Control-CrCL-transected	$1.40 \pm 1.04^{a,b}$	3.55 ± 1.84^a	3.80 ± 2.24^b
TPLO-intact	1.13 ± 0.10	0.12 ± 0.09	0.10 ± 0.07
TPLO-CrCL-transected	0.49 ± 0.70	1.00 ± 1.33	1.06 ± 1.27

Abbreviations: CrCL, cranial cruciate ligament; TPLO, tibial plateau levelling osteotomy.

Note: Data are presented as mean \pm standard deviation.

^a $p < 0.05$, extension vs. 135 degrees.

^b $p < 0.05$, extension vs. 120 degrees.

^c $p < 0.05$, 135 vs. 120 degrees.

Table 3 Comparisons of differences in the outcome measures among the stifle situations

	Craniocaudal displacement at craniocaudal drawer test (mm)			
	Control-intact	Control-CrCL-transected	TPLO-intact	TPLO-CrCL-transected
Extension	1.75 ± 0.48 ^{a,c}	4.33 ± 2.09 ^{a,e}	2.91 ± 0.72 ^f	10.37 ± 3.58 ^{c,e,f}
135°	1.95 ± 0.67 ^{a,c}	6.16 ± 2.91 ^{a,d,e}	2.85 ± 0.97 ^{d,f}	11.37 ± 3.63 ^{c,e,f}
120°	1.75 ± 0.77 ^{a,c}	6.93 ± 3.35 ^{a,d,e}	2.81 ± 0.87 ^{d,f}	12.17 ± 3.84 ^{c,e,f}
	Internal-external rotation at axial rotation test (°)			
	Control-intact	Control-CrCL-transected	TPLO-intact	TPLO-CrCL-transected
Extension	44.75 ± 7.56 ^{a,b,c}	61.77 ± 6.17 ^{a,d,e}	72.29 ± 8.26 ^{b,d,f}	86.27 ± 8.24 ^{c,e,f}
135°	65.65 ± 9.10 ^{b,c}	75.22 ± 7.39 ^e	84.50 ± 8.64 ^b	94.53 ± 10.52 ^{c,e}
120°	74.45 ± 7.84 ^{b,c}	78.05 ± 9.13 ^e	89.45 ± 8.02 ^b	97.17 ± 11.62 ^{e,e}
	Craniocaudal displacement at proximal compression test (mm)			
	Control-intact	Control-CrCL-transected	TPLO-intact	TPLO-CrCL-transected
Extension	0.14 ± 0.05 ^a	1.40 ± 1.04 ^{a,d,e}	1.13 ± 0.10 ^d	0.49 ± 0.70 ^e
135°	0.32 ± 0.23 ^a	3.55 ± 1.84 ^{a,d,e}	0.12 ± 0.09 ^d	1.00 ± 1.33 ^e
120°	0.30 ± 0.14 ^a	3.80 ± 2.24 ^{a,d,e}	0.10 ± 0.07 ^d	1.06 ± 1.27 ^e

Abbreviations: CrCL, cranial cruciate ligament; TPLO, tibial plateau levelling osteotomy.

Note: Data are presented as mean ± standard deviation.

^a*p* < 0.05, control-intact vs. control-CrCL-transected.

^b*p* < 0.05, control-intact vs. TPLO-intact.

^c*p* < 0.05, control-intact vs. TPLO-CrCL-transected.

^d*p* < 0.05, control-CrCL-transected vs. TPLO-intact.

^e*p* < 0.05, control-CrCL-transected vs. TPLO-CrCL-transected.

^f*p* < 0.05, TPLO-intact vs. TPLO-CrCL-transected.

However, there was no significant difference between control-CrCL-transected and TPLO-CrCL-transected stifles or between TPLO-intact and TPLO-CrCL-transected stifles. At 120 degrees, there was significantly less IE rotation in control-intact stifles than in TPLO-intact or TPLO-CrCL-transected stifles. However, there was no significant difference between control-CrCL-transected and TPLO-CrCL-transected stifles or between TPLO-intact and TPLO-CrCL-transected stifles. Therefore, there was a tendency for the value to increase following CrCL transection or with TPLO.

Proximal Compression Test

At each angle, there was significantly greater craniocaudal displacement in control-CrCL-transected than in control-intact, TPLO-intact or TPLO-CrCL-transected stifles during the proximal compression test. However, no significant differences were found between control-intact and TPLO-intact, control-intact and TPLO-CrCL-transected and TPLO-intact and TPLO-CrCL-transected stifles. Therefore, there was a tendency for the value to increase following CrCL transection in the control stifles and to decrease following TPLO.

Discussion

In this study, we found that TPLO provided stability during craniocaudal movement when a compressive force was applied to the tibiofemoral joint. However, in the absence of a compressive force, we found that TPLO promoted instability in the craniocaudal movement and IE rotation.

The craniocaudal drawer test confirmed that the CrCL prevents craniocaudal displacement, as previously shown.¹ Additionally, although no significant differences in craniocaudal displacement were found between the tested joint angles in control-intact stifles, the amount of displacement increased with flexion in control-CrCL-transected stifles. This may be because the collateral ligaments stretch during extension¹⁶ and stability in the craniocaudal direction may be minimally affected by relaxation of the collateral ligaments during flexion, because the main craniocaudal stabilizer is the CrCL. However, after CrCL transection, the craniocaudal stabilizing function of the CrCL is lost, and the collateral ligaments may compensate for some of its functions. Tibial plateau levelling osteotomy promotes greater instability during the craniocaudal drawer test in stifles lacking a CrCL. Thus, TPLO increases flexion at the femorotibial joint, which promotes conformational changes by effects on the collateral ligaments and stifle joint stability. One specific factor may be caudal movement of the insertion on the tibial side, due to rotation of part of the proximal tibia (→ Fig. 3). Therefore, TPLO is likely to increase the impact of the absence of a CrCL on joint function.

The axial rotation test in the control group showed that the CrCL limits IE rotation, so that rotational laxity was more limited during extension than during flexion in the normal stifles. The joint is stabilized against internal rotation by the CrCL and caudal cruciate ligament, and these ligaments stretch as the joint extends.¹ However, the collateral ligaments also play a role in limiting axial rotation and stretching

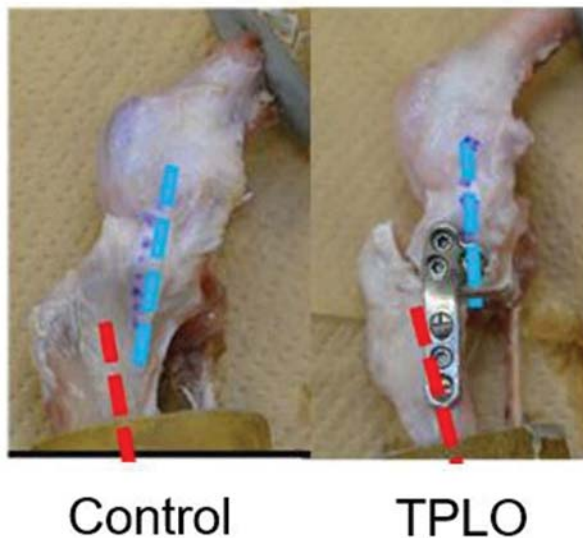


Fig. 3 Stifles in the control and tibial plateau levelling osteotomy groups. The red line represents the anatomical axis of the tibia and the blue line represents the path of the medial collateral ligament. The tibial plateau levelling osteotomy-treated stifle has a more caudal path than the Control stifle.

during extension.¹⁶ The stretching of each ligament stabilizes the joint against internal rotation in the extended position; however, in the flexed position these ligaments relax and their stabilizing effect is lower. This suggests that the degree of rotational instability depends on the angle of the stifle joint, and our findings suggest that TPLO promotes instability with respect to IE rotation. We think that this may be related to the effect of TPLO on each ligament, as discussed above, and that this instability may explain the sporadic occurrence of the pivot-shift phenomenon postoperatively in clinical cases.¹⁷

The results of the proximal compression test in the control group suggest that the CrCL prevents craniocaudal movement in response to a compressive force. When a vertical compressive force is generated at the tibiofemoral joint, as during weight bearing, cranial tibial thrust is generated, which displaces the tibia forward.¹⁸ Our findings are consistent with those of a previous study of CrCL function, which showed that the ligament prevents cranial displacement and excessive internal rotation of the tibia.¹ Grood and Suntay¹⁴ used a similar six-degree-of-freedom robotic testing system and reported instability in the normal canine stifle joint, identified using the craniocaudal drawer and proximal compression tests in the normal stifles of Beagles. Their finding was similar to ours in that the CrCL resisted craniocaudal displacement in the presence or absence of a compressive force at the tibiofemoral joint.¹⁴ We were able to reconfirm these functions of the CrCL using our robotic system. Furthermore, stifles from TPLO-treated dogs without a CrCL resisted cranial displacement of the tibia with a compressive force equal to that of normal stifle joints.

Tibial plateau levelling osteotomy promotes axial rotational and craniocaudal instability following CrCL transection, which may be due to the relative joint flexion created, which induces

collateral ligament laxity. However, normal stifles also have static and dynamic stabilizers, such as the quadriceps and hamstring muscles. The quadriceps muscle has a particularly potent influence on the stifle. During extension of the femorotibial joint, the patella creates a retropatellar force that pushes the distal femur caudally.¹⁹ Through this retropatellar force and cranial tibial thrust, the tibia is displaced cranially, especially in the stance phase.^{18,19} The present study and many *in vitro* studies, including that of Warzee and colleagues,⁶ have shown an increase in rotational instability in the absence of the CrCL; however, the dynamic stabilizers could not be completely reproduced in these studies.^{6,9} Tashman and colleagues²⁰ monitored the kinematics of the stifle joint in foxhounds for 2 years after CrCL excision. Two months after CrCL excision, the authors noted tibial subluxation in the stance phase and caudal reduction of the tibia in the swing phase.²⁰ They also found greater displacement in the craniocaudal direction (10 mm).²⁰ Two years after CrCL excision, the displacement had decreased to approximately 5 mm, which was considered to be the result of osteoarthritis progression and other changes.²⁰ However, no significant difference in the IE displacement was found during the 2-year observation period.²⁰ One factor associated with the differences between the results of *in vitro* and *in vivo* studies is considered to be the effect of rotational stabilization by the patella; the patella is stabilized mediolaterally by the femoral trochlea.²¹ Therefore, the influence of the rotational instability induced by CrCL rupture on the walking cycle is considered to be relatively small. However, craniocaudal instability is present during every shift from the swing phase to the stance phase, and the presence of craniocaudal instability in the absence of the CrCL may greatly influence the progression of osteoarthritis. Hulse and colleagues²² reported that the extent of the injury to the articular cartilage after TPLO depends on the degree of CrCL damage. They evaluated the articular cartilage by arthroscopy after TPLO and found that when CrCL function was preserved, the articular cartilage was normal or nearly normal and that degeneration of the CrCL was less, whereas when the CrCL function was not preserved, the damage to the articular cartilage was worse.²² This factor may also be affected by the instability induced by TPLO that has been shown in the present study.

This study had several limitations. First, the influence of dynamic stabilizers could not be reproduced. Furthermore, clinical CrCL rupture in the canine stifle manifests as a chronic condition termed 'cranial cruciate ligament disease', which may involve a partial tear or complete rupture.²³ Therefore, the severity of a CrCL injury depends on the amount of ligament degeneration. Cranial cruciate ligament degeneration, often associated with aging, can affect stifle instability.^{24,25} Therefore, the age difference between the control and TPLO groups might be responsible for the differences in stability. A previous report showed that such degeneration occurs by the age of 5 years in dogs weighing more than 15 kg.²⁵ Hence, we considered the risk small because the dogs used in this study were 15 kg or less and were all under two and a half years of age. Cranial cruciate ligament rupture is also associated with the development of

chronic periarticular fibrosis.²³ The degenerative changes observed in clinical cases, such as osteoarthritis and periarticular fibrosis, are a compensatory response and progress when the CrCL is damaged. These secondary joint changes have the potential to compensate for instability with respect to IE and cranio-caudal loads in stifles from TPLO-treated dogs. However, we could not imitate these compensatory mechanisms in the present study. Therefore, many clinical cases of ligament rupture caused by CrCL disease are expected to progress to stifle stabilization, which was not possible in the present study. Hence, this hypothesis must be tested in the future.

In conclusion, in the present study, TPLO provided effective cranio-caudal stabilization during vertical compression in stifle joints with a transected CrCL. However, it promoted instability under other test conditions following CrCL transection, which may be due to relative joint flexion inducing collateral ligament laxity. This instability might lead to more rapid progression of stifle osteoarthritis following TPLO. Therefore, TPLO should be performed while the CrCL is still partially functional to slow the progression of postoperative osteoarthritis.

Authors' Contributions

All authors contributed to conception of study, study design, acquisition of data and data analysis and interpretation. All authors also drafted, revised and approved the submitted manuscript.

Conflict of Interest

None declared.

Acknowledgements

We thank Dr Tatsuyuki Yoshida for assisting with the statistical analysis. We also thank Angela Morben, DVM, ELS, and Mark Cleasby, PhD, from Edanz Group (www.edanzediting.com/ac), for editing a draft of this manuscript.

References

- 1 Arnoczky SP, Marshall JL. The cruciate ligaments of the canine stifle: an anatomical and functional analysis. *Am J Vet Res* 1977; 38(11):1807–1814
- 2 Slocum B, Slocum TD. Tibial plateau leveling osteotomy for repair of cranial cruciate ligament rupture in the canine. *Vet Clin North Am Small Anim Pract* 1993;23(04):777–795
- 3 Krotscheck U, Nelson SA, Todhunter RJ, Stone M, Zhang Z. Long term functional outcome of tibial tuberosity advancement vs. tibial plateau leveling osteotomy and extracapsular repair in a heterogeneous population of dogs. *Vet Surg* 2016;45(02):261–268
- 4 Au KK, Gordon-Evans WJ, Dunning D, et al. Comparison of short- and long-term function and radiographic osteoarthritis in dogs after postoperative physical rehabilitation and tibial plateau leveling osteotomy or lateral fabellar suture stabilization. *Vet Surg* 2010;39(02):173–180
- 5 Rayward RM, Thomson DG, Davies JV, Innes JF, Whitelock RG. Progression of osteoarthritis following TPLO surgery: a prospective radiographic study of 40 dogs. *J Small Anim Pract* 2004;45(02):92–97
- 6 Warzee CC, Dejardin LM, Arnoczky SP, Perry RL. Effect of tibial plateau leveling on cranial and caudal tibial thrusts in canine cranial cruciate-deficient stifles: an in vitro experimental study. *Vet Surg* 2001;30(03):278–286
- 7 Kanno N, Amimoto H, Hara Y, et al. In vitro evaluation of the relationship between the semitendinosus muscle and cranial cruciate ligament in canine cadavers. *Am J Vet Res* 2012;73(05):672–680
- 8 Kim SE, Pozzi A, Banks SA, Conrad BP, Lewis DD. Effect of tibial plateau leveling osteotomy on femorotibial contact mechanics and stifle kinematics. *Vet Surg* 2009;38(01):23–32
- 9 Kanno N, Hara Y, Fukano S, et al. Tibial displacement with stifle joint flexion and cranial cruciate ligament transection in the dog. An ex vivo study using a robotic simulator. *Vet Comp Orthop Traumatol* 2014;27(04):277–284
- 10 Fujie H, Mabuchi K, Woo SL, Livesay GA, Arai S, Tsukamoto Y. The use of robotics technology to study human joint kinematics: a new methodology. *J Biomech Eng* 1993;115(03):211–217
- 11 Fujie H, Sekito T, Orita A. A novel robotic system for joint biomechanical tests: application to the human knee joint. *J Biomech Eng* 2004;126(01):54–61
- 12 Fujie H, Livesay GA, Fujita M, Woo SL. Forces and moments in six-DOF at the human knee joint: mathematical description for control. *J Biomech* 1996;29(12):1577–1585
- 13 Kimura K, Fujie H. Development of a novel robotic system for joint biomechanical tests using a real-time controller. *Jpn Soc Mech Eng* 2015;81(826):14–00684(in Japanese)
- 14 Grood ES, Suntay WJ. A joint coordinate system for the clinical description of three-dimensional motions: application to the knee. *J Biomech Eng* 1983;105(02):136–144
- 15 Muir P. Physical examination of lame dogs. *Compend Contin Educ Pract Vet* 1997;19:1149–1161
- 16 Vasseur PB, Arnoczky SP. Collateral ligaments of the canine stifle joint: anatomic and functional analysis. *Am J Vet Res* 1981;42(07):1133–1137
- 17 Knight RC, Thomson DG, Danielski A. Surgical management of pivot-shift phenomenon in a dog. *J Am Vet Med Assoc* 2017;250(06):676–680
- 18 Slocum B, Devine T. Cranial tibial thrust: a primary force in the canine stifle. *J Am Vet Med Assoc* 1983;183(04):456–459
- 19 Boudrieau RJ. Tibial plateau leveling osteotomy or tibial tuberosity advancement? *Vet Surg* 2009;38(01):1–22
- 20 Tashman S, Anderst W, Kolowich P, Havstad S, Arnoczky S. Kinematics of the ACL-deficient canine knee during gait: serial changes over two years. *J Orthop Res* 2004;22(05):931–941
- 21 Flandry F, Hommel G. Normal anatomy and biomechanics of the knee. *Sports Med Arthrosc Rev* 2011;19(02):82–92
- 22 Hulse D, Beale B, Kerwin S. Second look arthroscopic findings after tibial plateau leveling osteotomy. *Vet Surg* 2010;39(03):350–354
- 23 Hayashi K, Manley PA, Muir P. Cranial cruciate ligament pathophysiology in dogs with cruciate disease: a review. *J Am Anim Hosp Assoc* 2004;40(05):385–390
- 24 Döring AK, Junginger J, Hewicker-Trautwein M. Cruciate ligament degeneration and stifle joint synovitis in 56 dogs with intact cranial cruciate ligaments: correlation of histological findings and numbers and phenotypes of inflammatory cells with age, body weight and breed. *Vet Immunol Immunopathol* 2018;196:5–13
- 25 Vasseur PB, Pool RR, Arnoczky SP, Lau RE. Correlative biomechanical and histologic study of the cranial cruciate ligament in dogs. *Am J Vet Res* 1985;46(09):1842–1854