



Analysis of Speech and Functional Outcomes in Tongue Reconstruction after Hemiglossectomy

Chang Ryul Yi, MD, PhD^{1,2}  Woo Shik Jeong, MD³ Tae Suk Oh, MD, PhD³ Kyung S. Koh, MD, PhD³
Jong-Woo Choi, MD, PhD, MMM³ 

¹Department of Plastic and Reconstructive Surgery, Pusan National University, School of Medicine, Busan, Republic of Korea

²Biomedical Research Institute, Pusan National University Hospital, Busan, Republic of Korea

³Department of Plastic Surgery, Asan Medical Center, University of Ulsan College of Medicine, Seoul, Republic of Korea

Address for correspondence Jong-Woo Choi, MD, PhD, MMM, Department of Plastic Surgery, Asan Medical Center, University of Ulsan College of Medicine, 88, Olympic-ro 43-gil, Songpa-gu, Seoul 05505, Republic of Korea (e-mail: pschoi@amc.seoul.kr).

J Reconstr Microsurg 2020;36:507–513.

Abstract

Background Reconstruction in tongue cancer to restore the shape and function of the tongue without airway obstruction in the narrow oral cavity is challenging for reconstructive surgeons. Herein, the authors retrospectively analyzed flaps to reveal the factors that affect the functional outcome of tongue reconstruction.

Methods Herein, we retrospectively reviewed 30 patients (men, 16; women, 14; mean age, 50.3 years) who underwent the hemi-tongue reconstruction followed by speech therapy between 2009 and 2017. Data about postoperative chemotherapy and radiotherapy were collected. The dimensions (width and length) of the flaps were measured. Speech outcomes were assessed under the conditions of varying distances of the tongue tip from lower incisors when it was protruded, retracted, and elevated. Lateralization was evaluated based on the count of teeth reached by the tip of the tongue from the midline.

Results Preoperative chemotherapy and radiotherapy significantly influenced tongue retraction, tongue articulation, and intelligibility ($p = 0.006, 0.002, 0.048$, respectively). Postoperative chemotherapy did not statistically significantly influence any outcome measure. Contralateralization of the tongue was significantly decreased in the postoperative radiotherapy group ($p = 0.029$). The length of the flap showed highly negative correlation with articulation and intelligibility ($p = 0.009, p < 0.001$, respectively). The width of the flap was not correlated with the outcomes.

Conclusion We proved that unlike chemotherapy, postoperative radiotherapy influences the functional outcome of tongue reconstruction. The dimensions, particularly the length of the flap, were also important for restoring the reconstructed tongue function.

Keywords

- ▶ speech
- ▶ tongue
- ▶ reconstructive surgical procedures

Tongue cancer is one of the most common oral cavity cancers.¹ Herein, like in most cancers, our first aim of surgical treatment was to improve the survival rate. The extent of resection was planned as widely as possible to include the tumor and its microscopic spread.

However, the tongue is a functional structure with complicated components. It plays great roles in mastication, swallowing, and speech.^{1,2} Although it is a specialized sensory organ, most functions of the tongue are performed by the mobility of its series of complex arrangements of intrinsic and extrinsic

received
September 30, 2019
accepted
February 12, 2020
published online
April 14, 2020

Copyright © 2020 by Thieme Medical Publishers, Inc., 333 Seventh Avenue, New York, NY 10001, USA.
Tel: +1(212) 760-0888.

DOI <https://doi.org/10.1055/s-0040-1709493>.
ISSN 0743-684X.

musculature.¹ Particularly in speech production, the tongue plays an essential role as an air valve by constricting or making contact with other structures and modifying the shape and length of the vocal tract.² Significant changes in the function of the tongue result from its resection and reconstruction, altering the acoustic characteristics of speech.² Thus, the impairment of tongue function negatively influences the quality of life severely.³

Because of the increasing interest in head and neck cancer reconstruction, demands to reconstruct tongue functionally after minimal resection with acceptable survival rate have been increasing. Advances in microsurgical techniques have allowed reconstructive surgeons to prioritize not only the preservation of life but also better cosmetic and functional outcomes and quality of life for patients as an outcome of tongue reconstruction.⁴

Because of its complex structure and functions, reconstruction to restore the bulk, mobility, and sensibility of the tongue has been challenging for surgeons.³ In the narrow space of the oral cavity, reconstructive surgeons have to restore the shape and function of the tongue without airway obstruction. To reproduce the intact tongue anatomy, such as complex musculature, bulkiness, and sensory arrangements, diverse reconstructive attempts have been performed.¹ With the current advances in reconstructive surgery, new surgical options to restore the complex anatomy and function of the tongue are available.⁵

Functional speech outcomes of tongue reconstruction after the surgery have been evaluated subjectively and objectively in numerous studies.^{6–11} However, these studies often involve various extents of resection in a limited case series.

In this study, the authors retrospectively analyzed various factors of tumor and flaps to reveal the conditions that impact the functional outcome of tongue reconstruction.

Methods

A total of 30 patients who underwent hemi-tongue reconstruction followed by speech rehabilitation therapy at the Department of Plastic Surgery, Asan Medical Center, Seoul, were included in this study. Herein, 14 female and 16 male patients with a mean age of 50.3 years (range, 26–68 years) were enrolled. Only vascularized free-flap reconstruction was considered. Cases wherein reconstruction with a flap including innervated muscle or sensory nerve was performed were excluded.

Medical records were reviewed retrospectively for collecting information about patients.

Surgical Technique

Otolaryngologists performed resections of all tongue cancers, including neck dissections. Then, the authors began the reconstructive procedures. First, the defect size was estimated with a paper ruler. The volume of the tongue needed to reconstruct was inferred from the remaining part. The length from tip to base of the tongue along its curvature and the circumferential width were measured to design the flap. The defect size of the mouth floor and the surrounding tissues were taken into

account if needed. For a more accurate measurement, a rubber tourniquet designed as a flap was simulated into the defect. The flap was chosen based on the patient's body mass and the estimated volume of the defect required to be replaced.

Superior thyroidal vessels or facial vessels were identified for the recipient. After harvesting, the free flap was carefully positioned in the defect. One vein was anastomosed first, and then, anastomosis of the artery was performed. Another vein was anastomosed if necessary. The inset of the flap started from the deepest site, which was the most difficult to repair. The closure was then continued to the anterior aspect while ensuring that the flap had suitably restored the volume of defect. The inset was completed after trimming for final result.

Methods for Measurement

The flap was designed to be large enough to cover the measured defect size (►Fig. 1). The authors usually had 1 or 2 cm redundancy in flap design. The long axis of the flap aligning with the length of the tongue was measured as "length of flap." The short axis for circumferential width of the reconstructed tongue was measured as "width of flap." The resected tumor was measured as follows: "length" was defined as the shortest distance from the portion placed at the tip of the tongue to the most posterior portion. "Width" was the widest distance of tumor, perpendicular to the long axis in view from above. "Depth" of the tumor was measured as the longest length perpendicular to the long axis in lateral view.

Methods for Evaluation

There were three categories in the evaluation of speech outcomes in this study: range of tongue movement, articulation, and intelligibility. Speech outcomes of all patients were evaluated by a speech therapist.

Range of Tongue Movement

Distance from the middle point of the tip of lower incisors to the tip of the tongue was estimated as the range of movement of the tongue. The movement was measured in five directions: protrusion, retraction, elevation, ipsilateralization, and contralateralization to the affected side (►Fig. 2).

Articulation

Articulation was to digitize how precisely the patient could pronounce consonants. The evaluation was performed using the Urimal Test of Articulation and Phonation (U-TAP). The speech therapist showed pictures to the patients and the patients had to speak what they saw. If the patient could not recognize the name or said the wrong name, he or she was instructed to pronounce an imitative word. All evaluations were recorded with a video or audio recorder. The result was calculated in percentage of correct consonants (PCC).

$$PCC = (42 - \text{number of erroneously pronounced phonemes}) / 43 \times 100$$

Intelligibility

A measurement of how well a listener could comprehend the speech was defined as intelligibility. For evaluation, the patients recited a paragraph of "Autumn (Gaeul)," which

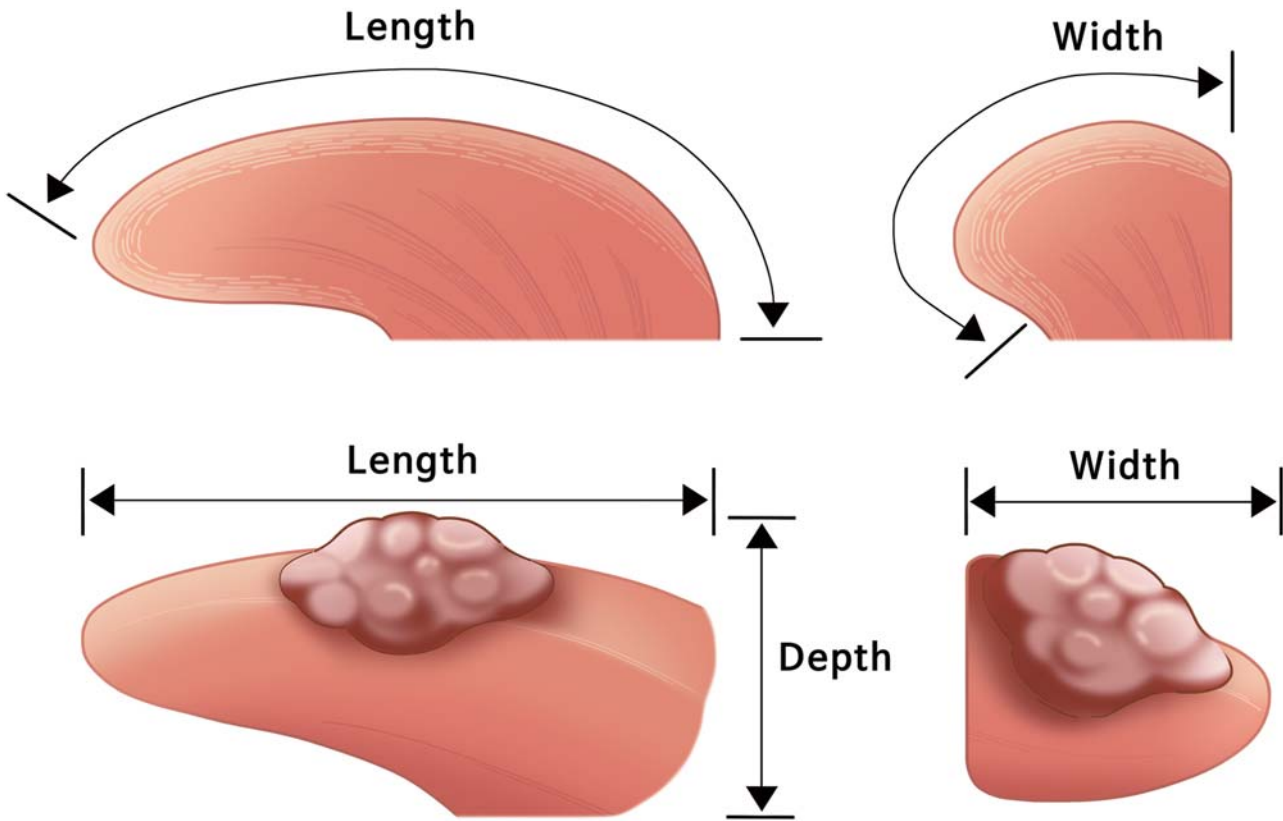


Fig. 1 Methods for measurement. The remnant hemi-tongue was utilized to infer the size of the defect. The distance from the tip to the base of the tongue was measured as the “length” of the defect. The circumferential width of the tongue was measured as the “width.” In measuring the resected tumor, the “length” was defined as shortest distance from the portion placed at the tip of the tongue to the most posterior portion. The “width” was the widest distance of the tumor which was perpendicular to the long axis in view from above. The “depth” of the tumor was measured as the longest length perpendicular to the long axis in lateral view.

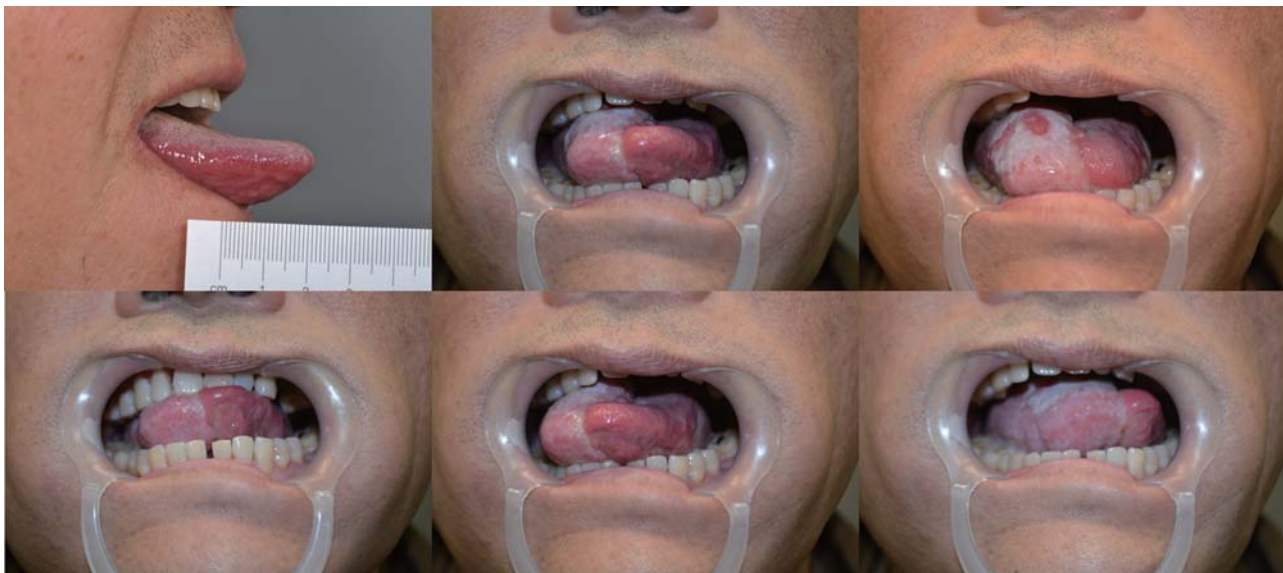


Fig. 2 Range of tongue movement. Distance from the middle point of the tip of lower incisors to the tip of the tongue was measured in five directions: protrusion, retraction, elevation, ipsilateralization, and contralateralization to the affected side.

was developed by HyangHee Kim in 1996 considering the frequency of appearance of Korean consonants and vowels including 369 syllables. The outcome was scored by the

speech therapist. The scoring was classified into five categories of impairment: mild, mild-to-moderate, moderate, moderate-to-severe, and severe impairment.

This document was downloaded for personal use only. Unauthorized distribution is strictly prohibited.

Table 1 Correlation between medical history and speech outcomes (*p*-value)

Outcome	Age	Gender	Smoking	Obesity	Hypertension	Diabetes
Protrusion	0.140	0.086	0.398	0.100	0.307	0.987
Retraction	0.644	1.000	0.473	0.468	0.904	0.763
Elevation	0.128	0.017 ^a	0.090	0.431	0.942	0.736
Ipsilateralization	0.152	0.866	0.884	0.592	0.239	0.879
Contralateralization	0.146	0.881	0.835	0.880	0.477	0.826
Articulation	0.305	0.325	0.401	0.331	0.652	0.603
Intelligibility	0.067	0.669	0.770	0.985	0.677	0.723

^aStatistically significant.

Statistical Analyses

Statistical analyses were performed using SPSS 24.0 (IBM SPSS Statistics, Chicago, IL). A *p*-value < 0.05 was considered significant.

Results

The speech outcomes seemed to have a negative relationship with the age of patients; however, the relationship was not statistically significant (►Table 1). On comparing the gender groups, men showed significantly better outcome in elevation (*p* = 0.017) (►Table 1). History of smoking also did not show a significant linear relationship with the speech outcomes (►Table 1).

Among underlying diseases, hypertension, obesity, and diabetes mellitus did not significantly affect the outcome of speech after tongue reconstruction (►Table 1).

In adjuvant therapy, preoperative chemotherapy and radiotherapy significantly influenced the outcome of tongue reconstruction, particularly retraction, articulation, and intelligibility (*p* = 0.006, 0.002, 0.048, respectively; ►Table 2). Postoperative chemotherapy did not significantly affect speech outcomes, whereas postoperative radiotherapy made a significant difference in the contralateralization outcome (*p* = 0.029; ►Table 2). The dose of preoperative radiotherapy was statistically, significantly, and negatively correlated with the speech outcomes— particularly retraction, articulation, and intelligibility (*p* = 0.006, 0.002, 0.048, respectively), unlike the dose of postoperative radiotherapy (►Table 2).

Herein, 26 of 30 flaps were successful without any complication. In two cases, the flap needed to be revised due to venous congestion, and debridement was performed in other two cases on partial margin necrosis. The choice of flap for tongue reconstruction could make a difference in the speech outcome. Because of small samples, statistical analysis was not reliable; however, the mean of each measurement was statistically and significantly different between each group of flaps (►Table 3). In particular, radial forearm free flap showed superior mean values of outcomes in retraction, contralateralization, and articulation compared with other flaps.

The speech outcomes were different depending on the recipient vessels. The superficial temporal artery showed statistically and significantly better outcomes in terms of elevation and contralateralization (*p* = 0.002 and 0.018, respectively) (►Table 3). Conversely, the speech outcomes of the reconstructed tongue did not significantly differ based on one or two recipient veins (►Table 3).

The flap dimensions showed a statistically significant relationship with the tongue reconstruction outcome. The length of the flaps had a significantly negative correlation with articulation and intelligibility (*p* = 0.009, *p* < 0.001, respectively), unlike the width (►Table 3).

The dimensions of the resected tumor were significantly related to the speech outcome. The length of the tumor was significantly negatively correlated with all outcomes, except elevation and ipsilateralization (►Table 3). All measurements of speech outcome, except ipsilateralization, had

Table 2 Correlation between adjuvant therapy and speech outcomes (*p*-value)

Outcome	Chemotherapy		Radiotherapy		Dose of radiotherapy	
	Preop.	Postop.	Preop.	Postop.	Preop.	Postop.
Protrusion	0.287	0.237	0.287	0.616	0.287	0.542
Retraction	0.006 ^a	0.065	0.006 ^a	0.073	0.006 ^a	0.056
Elevation	0.061	0.551	0.061	0.425	0.061	0.251
Ipsilateralization	0.243	0.771	0.243	1.000	0.243	0.934
Contralateralization	0.087	0.346	0.087	0.029 ^a	0.087	0.101
Articulation	0.002 ^a	0.544	0.002 ^a	0.907	0.002 ^a	0.861
Intelligibility	0.048 ^a	0.530	0.048 ^a	0.261	0.048 ^a	0.358

^aStatistically significant.

Table 3 Correlation between flap or tumor and speech outcomes (*p*-value)

Outcome	Flaps	Recipient vessel		Flap dimensions		Tumor dimensions		
		Artery	Number of vein	Length	Width	Length	Width	Depth
Protrusion	0.516	0.286	0.906	0.181	0.584	0.008 ^a	0.010 ^a	0.002 ^a
Retraction	0.032 ^a	0.390	1.000	0.072	0.193	0.023 ^a	0.004 ^a	0.001 ^a
Elevation	0.027 ^a	0.002 ^a	0.926	0.153	0.393	0.061	0.030 ^a	0.009 ^a
Ipsilateralization	0.172	0.266	0.945	0.314	0.422	0.343	0.274	0.206
Contralateralization	0.060 ^a	0.018 ^a	0.751	0.141	0.208	0.030 ^a	0.002 ^a	0.006 ^a
Articulation	0.041 ^a	0.229	0.393	0.009 ^a	0.081	0.006 ^a	0.011 ^a	0.001 ^a
Intelligibility	0.001 ^a	0.261	0.622	0.000 ^a	0.268	0.001 ^a	0.001 ^a	0.000 ^a

^aStatistically significant.

statistically negative correlations with the width and depth of the tumor (► **Table 3**).

Discussion

Much effort has gone into optimizing the tongue reconstruction outcomes through revealing correlation between many factors and outcomes with subjective and objective evaluation.¹² Despite many studies, some points, such as diverse size of defects and limited number of factors being considered or nonobjective measurement of the outcomes, remain controversial. To overcome these limitations, through this study, the authors tried to investigate the relationship between factors as many as possible, such as patient demographics, defects, flap types, and even adjuvant therapy. Furthermore, speech comprehension, which is one of the most important functional outcomes in tongue reconstruction, was assessed with objective measurement by a specialized speech therapist. To minimize biasness, cases were restricted to hemiglossectomy.

Underlying medical problems, such as hypertension, obesity, diabetes, and smoking, did not influence the speech outcome of tongue reconstruction. It was proved that the medical conditions of the patients do not compromise the vascularized free flap.¹³ This result was in agreement with those of previous studies and proved that the functional outcome of the free flap is not affected either. Only age and intelligibility were found to have a significant statistical tendency for correlation, and other speech outcomes were not significantly associated with age. The fact that the age of patients could have a significant relationship with speech intelligibility was mentioned in previous studies.^{14,15} However, difference in intelligibility seemed not to be directly correlated with the functional outcome of the reconstructed tongue. Gender did not show any statistically significant correlation with speech outcomes, except for elevation.

Only one patient underwent preoperative adjuvant therapy, along with simultaneous chemotherapy and radiotherapy. Thus, the outcomes were equal in these two adjuvant therapies. Although the impact of each therapy was not distinguished, preoperative adjuvant therapies and the

dose of preoperative radiation made significant differences in speech outcomes, particularly in retraction, articulation, and intelligibility. First, the soft tissue in operation field might already be affected by adjuvant therapies. This could lead to some dysfunction of the remaining muscles which had to be moved to the reconstructed part of the tongue. The dysfunction might not be severe enough to compromise the movement but could influence articulation and intelligibility during actual speech. Second, preirradiated operation field could affect the flap to be used for reconstruction, as radiation-induced fibrosis and damage to the microvasculature before the surgery compromises wound healing in the irradiated field.¹⁶ Third, tumor severity could be another reason for the differences in speech outcomes. The fact that adjuvant therapies were needed might indicate that the tumors were more aggressive or progressed faster than others. Such cases in this study are few; and therefore, further large-scale research will be needed to prove the impact of the preoperative adjuvant therapies.

Unlike preoperative adjuvant therapy, postoperative chemotherapy did not show any difference in speech outcomes. Postoperative chemotherapy is assumed to not influence the result of tongue reconstruction. Otherwise, there would have been statistically significant differences or statistical tendency in postoperative radiotherapy regardless of its dosage. Retraction and contralateralization of tongue movement decreased in the radiation group. It seemed that as a postoperative adjuvant therapy, radiotherapy, not chemotherapy, influenced the surgical outcomes of tongue reconstruction.

Diverse flap types were used in this study. Radial forearm free flap and anterolateral thigh flap were used in most cases, and superficial circumflex iliac artery perforator flap, vertical rectus abdominis musculocutaneous flap, tensor fasciae latae muscle flap, and chimeric anteromedial thigh flap were used in one or two cases. Most measurements of speech outcomes were statistically and significantly different based on the type of flap. Although it was difficult to prove which flap was superior in tongue reconstruction because of the inclusion of a few cases, the radial forearm free flap showed overall better outcomes in speech evaluation. These differences in functional outcomes between flaps should be studied in a larger scale research.

The functional outcomes of free flap-reconstructed tongue differed depending on the recipient artery. The superior thyroidal and facial arteries were used as recipient arteries in this study. Most functional movements were not significantly different; however, elevation and contralateralization showed statistically significant difference between the two arteries. Usually, the pedicle of the reconstructed tongue, anastomosed with the superior thyroidal artery, was placed freely without any anatomical obstacle. Otherwise, the pedicle anastomosed with the facial artery would have had to pass through the lower margin of the mandible, which could have disrupted the blood flow and mobility of the pedicle. This hypothesis could be supported by the result that the functional outcomes of movement were reduced in which were exercised away from the anastomosis site, such as elevation and contralateralization.

The decision of how many recipient veins are optimal in a vascularized free flap is highly controversial. Many microsurgeons recommend double venous anastomosis if possible because it is considered to reduce flap failure, venous thrombosis, and the need for revision.^{17,18} This debate is in progress in the field of head and neck reconstruction as well. Lee et al claimed that two vein anastomoses achieved better outcomes with the anterolateral thigh flap, which is one of the workhorse flaps for head and neck reconstruction.¹⁸ Conversely, Khaja et al proved that two vein anastomoses in head and neck free flap did not reduce flap failure rate or postoperative venous thrombosis.¹⁹ In this study, the number of recipient veins did not have any impact on the speech outcome after tongue reconstruction. Further large-scale studies are warranted to verify the correlation between the number of vein anastomosis and the functional outcome of the free flap in head and neck reconstruction.

The dimension of the flap was an important factor for speech outcome of tongue reconstruction. The length of the flap was either statistically and significantly correlated or had a tendency to affect functional outcomes, such as retraction, articulation, and intelligibility. Most tongue movements require ample tongue length. Thus, sufficient length of the flap is required for that motion. Considering this perspective, our results could be quite convincing. The width of the flap did not have a statistically significant impact on speech outcome. During the maximum movement of the tongue, the vector was vertical to the width of the tongue. This might be the reason why the length was related with speech outcomes, not the width.

Tumor dimension was also another highly influential factor in mobility and speech of the flap-reconstructed tongue. All dimensions, including the length, width, and depth of the tumor, showed statistical significance or tendency in correlation with all speech outcomes except ipsilateralization. Ipsilateralization was not affected by any tumor as well as flap dimensions. Most tongue movements widen the defect size and force the reconstructed part of the tongue to be stretched to cover the defect. Thus, the larger defect the tumor makes, the poorer is the outcome. However, in ipsilateralization, as the tongue moved to the previous defected side, the dimension of the defect would shrink the

most, and the flap placed in the defect could be relaxed. Thus, this motion did not have a relationship with the size of the defect after tumor resection.

This study had various great implications for surgeons who perform tongue reconstruction. In summary, reconstructive surgeons have to be more cautious when patients who require tongue reconstruction had a large tumor or underwent preoperative adjuvant therapy. Tumor severity and irradiated operative field may impact surgical outcomes. In hemi-tongue reconstruction, the radial forearm free flap can be considered a good option, and for recipient artery, the superior thyroidal artery is highly recommended. The length of the flap should be secured sufficiently in flap design for better outcome. If the patient is scheduled for postoperative radiotherapy, the possibility of worsening of speech outcome has to be conveyed.

There were some limitations in this study. The resected structures due to tumor were not classified anatomically. The affected muscles and other soft tissues related to tongue movement were not identified. These could make comparisons and analyses of the outcomes uncertain. In addition, small scale of study was another limitation. Further larger scale studies involving the classification of affected sites are warranted.

In spite of the recent trials by reconstructive surgeons to restore motion or sensory function of the tongue using functional innervated flaps, the authors did not consider any surgical technique in this study to exclude bias.²⁰ The authors will study and discuss about functional tongue reconstruction in future literature.

Conclusion

Many aspects of tongue reconstruction influenced the speech outcome. Particularly, pre and postoperative adjuvant therapy, the type of flap for reconstruction, the choice of recipient artery, and the dimensions of the tumor and the flap were factors that statistically and significantly impacted the functional outcome of the reconstructed tongue. The results of this study could be helpful to the surgeons performing tongue reconstruction with a free vascularized flap.

Funding

None.

Conflict of Interest

None declared.

References

- Engel H, Huang JJ, Lin CY, et al. A strategic approach for tongue reconstruction to achieve predictable and improved functional and aesthetic outcomes. *Plast Reconstr Surg* 2010;126(06):1967–1977
- Laaksonen JP, Rieger J, Harris J, Seikaly H. A longitudinal acoustic study of the effects of the radial forearm free flap reconstruction on sibilants produced by tongue cancer patients. *Clin Linguist Phon* 2011;25(04):253–264
- Baas M, Duraku LS, Corten EM, Mureau MA. A systematic review on the sensory reinnervation of free flaps for tongue reconstruction: Does improved sensibility imply functional benefits? *J Plast Reconstr Aesthet Surg* 2015;68(08):1025–1035

- 4 Brown L, Rieger JM, Harris J, Seikaly H. A longitudinal study of functional outcomes after surgical resection and microvascular reconstruction for oral cancer: tongue mobility and swallowing function. *J Oral Maxillofac Surg* 2010;68(11):2690–2700
- 5 Matsui Y, Ohno K, Yamashita Y, Takahashi K. Factors influencing postoperative speech function of tongue cancer patients following reconstruction with fasciocutaneous/myocutaneous flaps—a multicenter study. *Int J Oral Maxillofac Surg* 2007;36(07):601–609
- 6 Bodin IK, Lind MG, Arnander C. Free radial forearm flap reconstruction in surgery of the oral cavity and pharynx: surgical complications, impairment of speech and swallowing. *Clin Otolaryngol Allied Sci* 1994;19(01):28–34
- 7 Hara I, Gellrich NC, Duker J, et al. Swallowing and speech function after intraoral soft tissue reconstruction with lateral upper arm free flap and radial forearm free flap. *Br J Oral Maxillofac Surg* 2003;41(03):161–169
- 8 Jacobson MC, Franssen E, Fliss DM, Birt BD, Gilbert RW. Free forearm flap in oral reconstruction. Functional outcome. *Arch Otolaryngol Head Neck Surg* 1995;121(09):959–964
- 9 Michiwaki Y, Schmelzeisen R, Hackl T, Michi K. Articulatory function in glossectomized patients with immediate reconstruction using a free jejunum flap. *J Craniomaxillofac Surg* 1992;20(05):203–210
- 10 Nicoletti G, Soutar DS, Jackson MS, Wrench AA, Robertson G, Robertson C. Objective assessment of speech after surgical treatment for oral cancer: experience from 196 selected cases. *Plast Reconstr Surg* 2004;113(01):114–125
- 11 Schliephake H, Schmelzeisen R, Schönweiler R, Schneller T, Altenbernd C. Speech, deglutition and life quality after intraoral tumour resection. A prospective study. *Int J Oral Maxillofac Surg* 1998;27(02):99–105
- 12 Manrique OJ, Leland HA, Langevin CJ, et al. Optimizing outcomes following total and subtotal tongue reconstruction: A systematic review of the contemporary literature. *J Reconstr Microsurg* 2017;33(02):103–111
- 13 Ehrl D, Heidekrueger PI, Ninkovic M, Broer PN. Effect of preoperative medical status on microsurgical free flap reconstructions: a matched cohort analysis of 969 cases. *J Reconstr Microsurg* 2018;34(03):170–175
- 14 Smiljanic R, Gilbert RC. Intelligibility of noise-adapted and clear speech in child, young adult, and older adult talkers. *J Speech Lang Hear Res* 2017;60(11):3069–3080
- 15 Cerny L, Vokral J, Dlouha O. Influence of age on speech intelligibility in babble noise. *Acta Neurobiol Exp (Wars)* 2018;78(02):140–147
- 16 Mueller CK, Schultze-Mosgau S. Radiation-induced microenvironments—the molecular basis for free flap complications in the pre-irradiated field? *Radiother Oncol* 2009;93(03):581–585
- 17 Riot S, Herlin C, Mojallal A, et al. A systematic review and meta-analysis of double venous anastomosis in free flaps. *Plast Reconstr Surg* 2015;136(06):1299–1311
- 18 Lee YC, Chen WC, Chen SH, et al. One versus two venous anastomoses in anterolateral thigh flap reconstruction after oral cancer ablation. *Plast Reconstr Surg* 2016;138(02):481–489
- 19 Khaja SF, Rubin N, Bayon R. Venous complications in one versus two vein anastomoses in head and neck free flaps. *Ann Otol Rhinol Laryngol* 2017;126(10):722–726
- 20 Grinsell D, Yue BY. The functional free innervated medial gastrocnemius flap. *J Reconstr Microsurg* 2014;30(07):451–456