

Surgery of the Palatomaxillary Structure

Ameya A. Jategaonkar, MD¹ Vivian F. Kaul, MD¹ Eric Lee, MD¹ Eric M. Genden, MD, MHA¹

¹Department of Otolaryngology – Head and Neck Surgery, Icahn School of Medicine at Mount Sinai, New York, New York

Address for correspondence Ameya A. Jategaonkar, MD, Department of Otolaryngology- Head and Neck Surgery, Icahn School of Medicine at Mount Sinai, New York, NY
(e-mail: ameya.jategaonkar@mountsinai.org).

Semin Plast Surg 2020;34:71–76.

Abstract

Keywords

- ▶ head and neck surgery
- ▶ maxillectomy
- ▶ palatotomy
- ▶ palate/palatal surgery
- ▶ midface surgery

The palatomaxillary structure plays critical roles in both form and function of the midface. Surgical defects of the palate and maxilla can be associated with significant morbidity and deformity. Various defect classification systems have been used to assist in reconstruction and rehabilitation. Reconstructive options include prosthetic rehabilitation, local flaps, and free tissue transfer. Here, we review the functional and surgical anatomy of the palatomaxillary complex, defect classification systems, and provide an overview of reconstructive options.

The maxillectomy procedure was initially described in the 1820s by Lazar and Syme with Syme including orbital exenteration in his description.^{1,2} The surgery was seldom attempted in the ensuing century due to the significant blood loss encountered, and thus the high mortality associated with the operation. Additionally, the significant resultant deformity also prevented maxillectomy from being more widely practiced. In the modern era, less radical open, transoral, and transnasal approaches to the maxilla have been described.^{3,4} Furthermore, advances in anesthesia, blood replacement, and perioperative management have resulted in increased viability of maxillectomy as a surgical option. Advanced reconstructive techniques have also reduced deformity and functional deficits associated with maxillectomy. Today, the various types of maxillectomies and the diverse reconstructive options have made the maxillectomy an integral operation in the treatment of head and neck pathologies.

While malignancy is the most common indication for maxillectomy, trauma, infection, or other benign pathologies may necessitate complete or partial resection of the palatomaxillary structure. Preoperative planning should include careful evaluation of all components of the maxilla and surrounding structures involved. A thorough understanding of the native maxillary anatomy coupled with an understanding of how the underlying pathology has affected this anatomy is paramount. Any pre-existing functional deficits should be noted as well, including dysphagia, changes in phonation (such as nasality of voice), or extraocular movements. Additionally,

the ultimate nature of the defect should be anticipated to facilitate appropriate reconstructive planning.

Reconstructive approaches to the palatomaxillary structure are diverse and include prosthetic rehabilitation, local/regional reconstruction, and microvascular free tissue transfer.⁵ Dental rehabilitation may also be offered in the form of dentures or osseointegrated implants. Patients who are undergoing palatomaxillary surgery should be counseled regarding this range of options. Ultimately patient considerations, disease characteristics, and surgical factors play an important role in decision making. Here we review the functional and structural anatomy of the palatomaxillary complex, types of maxillectomy defects, and reconstructive options.

Anatomy and Function of the Palatomaxillary Structure

The palatomaxillary structure is a major structural and functional unit of the midface. The soft and bony tissues of this complex are vital to a variety of functions ranging from cosmesis to mastication, deglutition, and respiration. The maxilla is a paired structure that fuses in the midline along the midline palatine suture. Embryologically, maxillary ossification begins from two ossification centers: one for the premaxilla (incisive bone) and a second for the body of the maxilla. These later fuse to form the single maxilla proper. Failure of fusion of each lateral maxilla results in cleft lip/palate abnormalities. After development is complete, the

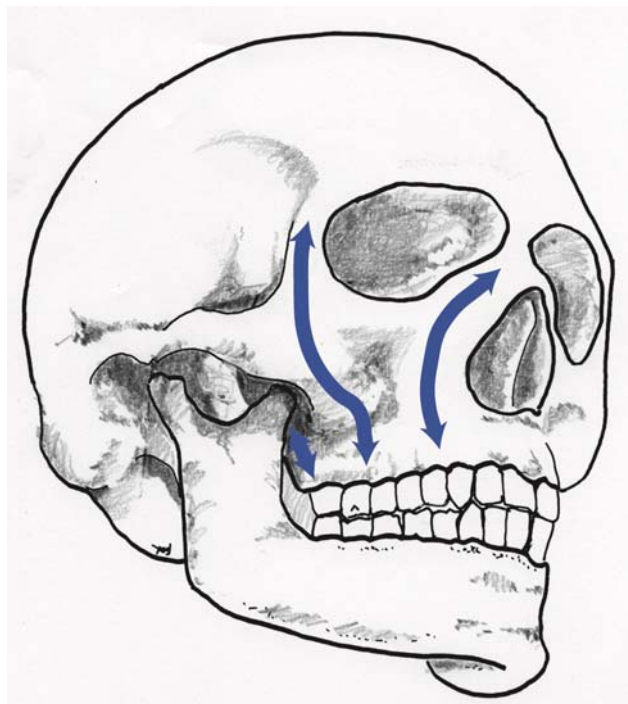


Fig. 1 The vertical buttresses of the maxilla (pictured here as arrows from left to right) are the pterygomaxillary, zygomatic maxillary, and nasomaxillary buttresses. These enable the distribution of the forces of mastication through the maxilla.

adult maxilla is comprised of a body and four processes: zygomatic, frontal, palatine, and alveolar.

The maxilla plays a crucial structural role with bony buttresses that withstand the forces of mastication and provide support for the projection of the face in horizontal and anteroposterior dimensions. The horizontal buttresses that run through the maxilla include the zygomatic buttress and the buttress formed by the arch of the hard palate. The zygomatic process of the maxilla contributes to the zygomatic buttress and to the projection of the malar eminence. The arch of the hard palate helps define the width of the midface and supports the maxillary dentition. The vertical buttresses of the maxilla are the paired nasomaxillary, zygomaticomaxillary, and pterygomaxillary buttresses (► **Fig. 1**). The vertical buttresses play a key role in defining facial height. Functionally these vertical buttresses play a crucial role in resisting the forces of mastication and distributing these forces safely to the skull base. As such the bony maxilla contributes significantly to facial aesthetics and mastication.

The maxilla also contributes to the bony walls of the orbit by forming the inferior orbital rim and the orbital floor. Thus, the maxilla supports the orbital contents and globe. Large defects of the orbital floor can result in displacement of the globe (e.g., enophthalmos) and vision changes.

Another key function of the palatamaxillary structure is to ensure separation of the oral and nasal cavities. The bony structures of the hard palate provide a fixed separation, while the soft palate provides dynamic separation. These are necessary for proper speech and swallow. Depression of the soft palate against the base of tongue during mastication keeps

food in the oral cavity when chewing and enables nasal breathing. A functional soft palate is also necessary to prevent velopharyngeal insufficiency. Incomplete separation between the oral and nasal cavities during swallowing can result in nasal regurgitation. Separation between the oral and nasal cavities is also necessary for speech. Defects in the hard/soft palate can result in a hypernasal voice and difficulty with certain aspects of speech such as “s” and “z” sounds, among others.

When resecting lesions of the palate and maxilla, care should be taken to minimize disruption of the various structural and functional units of the palatamaxillary complex. Similarly when planning reconstruction, both structural and functional deficits should be taken into consideration.

Maxillectomy Defect Classification Systems

Ablative surgery of the palatamaxillary structure can result in a variety of defects based upon the extent of the underlying disease. As such even the term “maxillectomy” can refer to a variety of procedures. Appropriate reconstruction/rehabilitation requires a thorough understanding of the defect. For example, limited palatal defects or those that include only a small portion of the alveolus may be adequately treated with obturation. Conversely extensive defects that include the orbital floor and/or zygoma often necessitate reconstruction with osseous-free tissue to restore facial contours, orbital support, and to facilitate dental rehabilitation.

Given the variety of maxillectomy defects, several classification systems have been proposed.⁶ Each of these methods aims to assist in the planning of reconstruction. Discussed in detail here are two classification systems; those proposed by Brown et al and Okay et al.^{7,8}

Brown et al divide their classification based on the vertical and horizontal components of the defect (► **Fig. 2**).⁷

Vertical

Class 1: These are defects that result from resection of inferior aspects of the maxilla that do not result in an oroantral/oronasal fistula. Included here are isolated hard palate defects, even though these do result in communication between the oral and nasal cavities.

Class 2: Defects that involve the alveolus and antral walls, but spare the orbital floor are class 2 defects.

Class 3: Extended defects that involve the orbital floor but do not extend to the skull base are class 3 defects.

Class 4: These maxillectomy defects involve orbital exenteration and may include skull base defects.

Horizontal

Class a: These defects result from resection of unilateral alveolar and palatine portions of the maxilla. These do not involve the nasal septum or cross midline.

Class b: Subtotal resection that cross midline are class b defects.

Class c: These defects result from complete resection of the alveolar maxilla and hard palate.

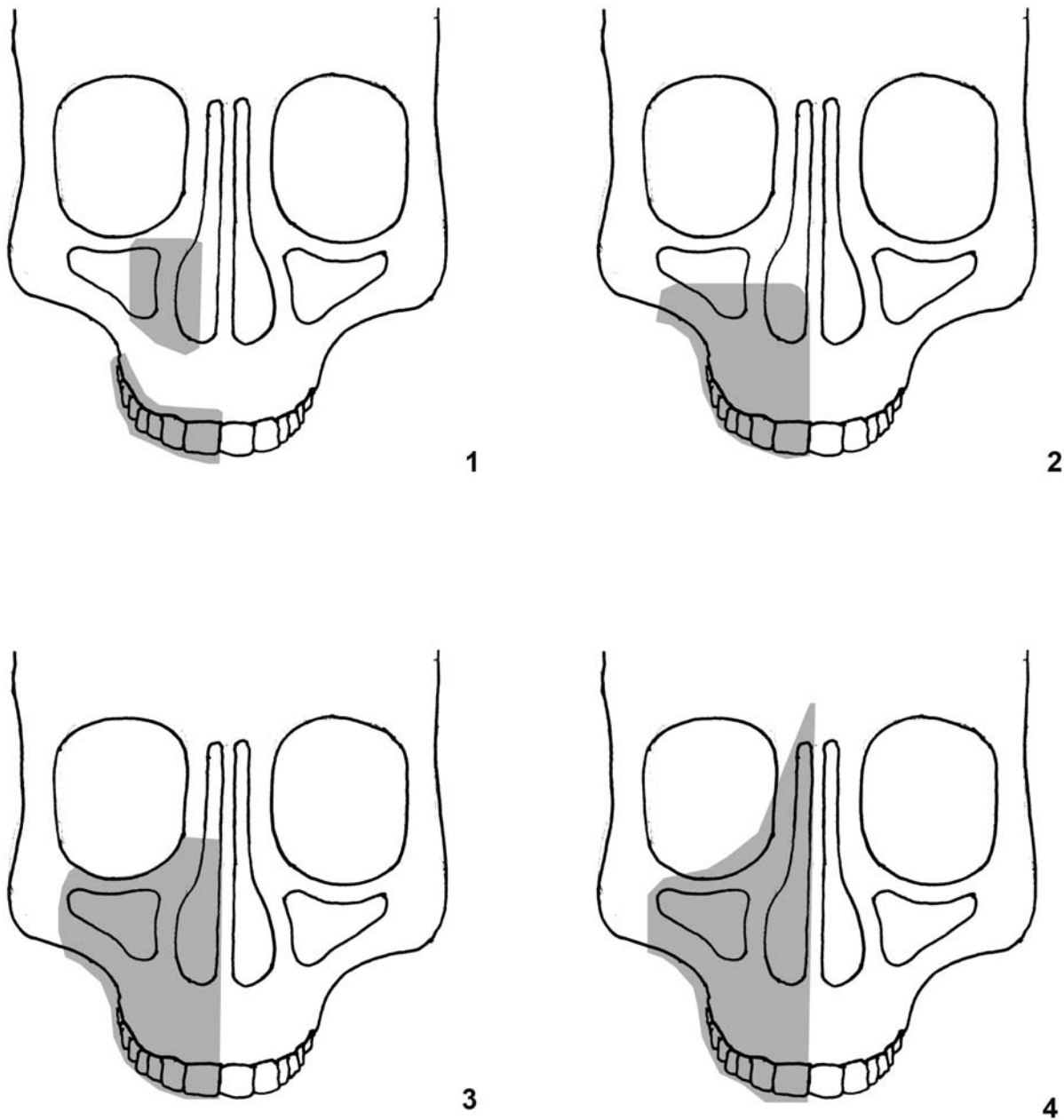


Fig. 2 Pictured here is the vertical component of the Brown maxillectomy defect classification system. The horizontal component of the Brown classification system (not pictured) can be used in conjunction with the vertical component to categorize maxillectomy defects and plan reconstruction.

Another commonly used classification system is that proposed by Okay et al.⁸ This classification system specifically addresses the forces that an obturator/dental prosthetic experiences during mastication. This classification system incorporates the role that remaining native teeth play in supporting any prosthodontics (► **Fig. 3**). The classification system also specifically incorporates defects of the orbital floor and zygomatic process of the maxilla.

Class Ia: Class 1a defects are limited to defects of the palate that do not include any tooth bearing components of the maxilla.

Class Ib: These defects involve the tooth bearing alveolus but are limited to either the premaxilla or a posterior portion of the maxilla. A significant portion of the dental arch should be preserved. Both canines should be spared.
Class II: Lateral defects of the maxilla that include only one canine can be classified as class II defects. Anterior palatal defects that are less than half of the palate are included in class II.

Class III: These defects include any defect that encompasses both canines. Total palatotomy defects and anterior palatotomy defects that include greater than half of the hard palate are included in class III defects.

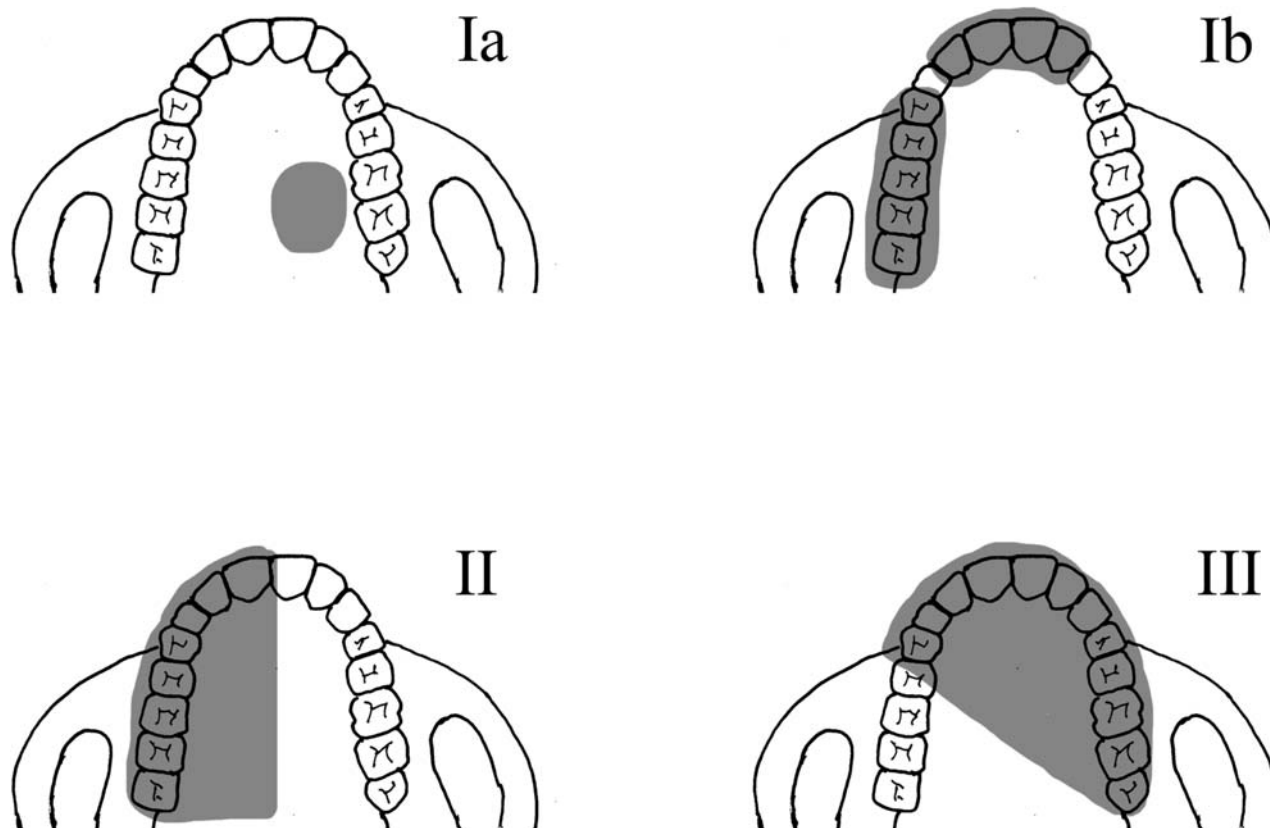


Fig. 3 The Okay classification system can be seen here. Class Ia defects include only the palate and spare the alveolus, while class Ib defects involve limited alveolar defects (spare the canines). Class II and III defects are more extensive and involve either one or both canines, respectively.

Subclass f: This is an additional classification for maxillectomy defects that include the orbital floor

Subclass z: Additional classification for maxillectomy defects that include the zygomatic process of the maxilla

Given the heterogeneity and wide range of maxillectomy defects, these (and other) classification systems aim to predict the structural and functional deficits associated with a given defect and thus can play an important role in planning surgical reconstruction.

Reconstruction of Palatomaxillary Defects

The palatomaxillary complex is crucial to facial aesthetics, orbital support, and functionally plays a key role in mastication, speech, and swallow. Reconstruction must therefore address each of these to ensure restoration of form and function. Options for reconstruction include obturation with prosthetics to free tissue transfer.

Prosthodontics

Patients with smaller defects limited to the palate may be suited for obturation, with options including removable dentures as well as osseointegrated implant-anchored prosthodontia. One advantage of prosthetic rehabilitation is that prostheses can be removed enabling visual inspection of the defect to assess for any recurrence/progression of disease. However, prosthodontics does not adequately address anterior

maxillary deficits, and may be difficult to use in patients with limited manual dexterity. Additionally, obturator use may be difficult in patients with a history of radiation, owing to xerostomia as well as radiation-induced mucositis. In fact, Chigurupati et al demonstrated that history of radiation was the most important predictor for lower quality of life in patients who had an obturator after maxillectomy.⁹ While limited due to its small sample size, a report by Genden et al compared eight patients with Okay classification II (hemipalatectomy) defects.¹⁰ In this study, four patients underwent obturation and four underwent vascularized osseous free-tissue reconstruction. The authors found those undergoing reconstruction with free tissue enjoyed improved mastication and speech assessment scores with less oronasal reflux than those with obturation. In the modern era, prosthodontic use plays a limited role in palatomaxillary reconstruction, primarily in patients with limited defects or poor access to more advanced reconstructive options.

Local/Regional Reconstruction

A variety of local and regional flaps have been described to reconstruct palatomaxillary defects. Bone grafts too have been described in conjunction with these local/regional flaps. Many of these techniques parallel cleft palate reconstruction. Historically, tongue flaps have been described; however, these have fallen out of favor due to the significant functional morbidity incurred and the availability of other reconstructive options. The palatal island flap represents a reliable

mucoperiosteal flap based on the greater palatine artery.¹¹ It can provide excellent reconstruction for patients with limited defects of the hard/soft palate and thus obviate the need for prosthetic rehabilitation. The submental island flap is another reconstructive option for palatal reconstruction.¹² This flap is based upon the submental artery and a thin and pliable skin paddle as large as 15 × 7 cm can be harvested. Buccal myomucosal, buccal fat flaps, and the facial artery musculomucosal flaps may be employed for palatomaxillary reconstruction. Regional flaps include the temporalis muscle flap and the pectoralis flap, though generally these are larger, bulkier flaps. The temporalis flap based off the deep temporal artery may be especially useful in orbitomaxillary defects where volume restoration is important. Its use in conjunction with calvarial bone has been described.

Microvascular Free Tissue Transfer

Microvascular free tissue transfer has evolved to become the preferred technique in maxillary reconstruction. While soft tissue flaps have allowed for restoration of tissue bulk, osseocutaneous free flaps have enabled reconstruction of large bony defects of the midface.^{5,13,14} Additionally, osseointegrated implants can supplement free tissue reconstruction to enable better dental rehabilitation.¹⁵

Cordeiro and Santamaria published a report to attempt to guide free flap decision making.¹⁶ In his algorithm, small soft tissue deficits were reconstructed with radial forearm free flaps, while larger soft tissue requirements were fulfilled with the rectus abdominis. For bony reconstruction, he suggested bone grafting for orbital support, and osseous radial forearm free flaps for anterior and palatal deficits. However, his schema was biased toward soft tissue flaps, did not account for composite deficits, and does not propose a way to deal with dental rehabilitation. Ultimately, no single flap can be considered to be the gold standard for maxillary reconstruction, but rather each defect should be carefully evaluated to determine the ideal reconstructive option, ideally replacing "like with like." Important factors influencing choice of reconstruction include need for soft tissue volume restoration, bony deficits, orbital support, and palatal competence. Soft tissue flaps include the radial forearm fasciocutaneous flap, rectus abdominis flap, anterolateral thigh (ALT) flap, and scapular system flaps. The radial forearm flap is a robust flap based on the radial artery that provides a robust thin and pliable skin paddle well suited for palate reconstruction. The ALT fasciocutaneous flap is also commonly used, and can be taken with or without the vastus lateralis muscle for additional volume. Conversely, muscle only may be taken when skin is not necessary.

Bony flaps include the iliac crest flap, radial forearm osseocutaneous flap, fibular flap, and scapular system flaps. The radial forearm osseocutaneous flap allows the harvest of both skin and bone with a lengthy pedicle in defects where volume replacement is minimal. However, the bone stock is not as robust as other osseous flaps, and is not suitable for dental rehabilitation.

The fibula free flap (based on the peroneal artery) is particularly well suited to reconstruct bony midface defects.

Over 20 cm of bone may be harvested. Additionally, the segmental blood supply of the fibula enables the use of osteotomies to help reconstruct the three-dimensional structures of the maxilla. The bicortical bone of the fibula also supports osseointegrated dental implants. Both the radial forearm and fibular free flap may be harvested concurrently with a two-team approach, reducing total operative time.

The scapular system has also been well described in maxillary reconstruction, with osseous, muscular, and cutaneous options available. Furthermore, chimeric combinations can be harvested off a single pedicle for more complex deficits. Bone may be harvested either from the scapular tip (based on the angular artery) or from the lateral border of the scapula (circumflex scapular artery). The latissimus and/or serratus muscles may also be taken with their branches off of the thoracodorsal artery to provide soft tissue bulk. Finally, a thoracodorsal artery perforator flap can be harvested to provide a robust skin paddle when muscle bulk is not necessary. The scapular flaps are particularly useful in patients who have anomalous lower extremity vasculature or peripheral arterial disease.

Conclusion

The palatomaxillary complex represents a key structural and functional unit of the face. It plays a critical role in facial aesthetics by defining facial height, width, and midface projection. The maxilla is tooth bearing and the bony buttresses of the maxilla also resist and distribute the forces of mastication. The maxilla also forms the orbital floor ensuring stable support for the globe. The palatomaxillary structures also separate the oral and nasal cavities enabling proper speech and swallow. Surgery of the palatomaxillary structure can thus result in significant functional morbidity and deformity. As such, reconstruction of these midface structures is paramount. Various classification schemes for maxillectomy defects have been proposed and they are useful in predicting the deficits associated with a given defect and can aid in planning reconstruction.

Given the complicated anatomy and diverse roles of the maxilla, maxillectomy defects present unique challenges to the reconstructive surgeon. Prosthetic rehabilitation with an obturator can be an option for patients with limited defects or those who are otherwise unable to undergo reconstructive surgery. Prosthodontia can also be coupled with other reconstructive techniques to optimize dental rehabilitation. Various regional flaps such as the palatal island flap, temporalis flap, or the submental island flap are well suited for reconstructing limited defects of the palate/maxilla. Finally, free tissue transfer can enable reconstruction of extensive defects and help restore facial contours, orbital support, and enable dental rehabilitation. It should also be noted that patient factors such as candidacy for major reconstructive surgery and socioeconomic factors (e.g., access to prosthodontists) also play a major role in planning reconstructive surgery. Ultimately careful planning that includes a thorough understanding of palatomaxillary form and function, a defect-oriented reconstructive approach, and an understanding of patient specific factors is needed for successful palatomaxillary surgery.

Funding

No financial disclosures.

Conflicts of Interest

None.

References

- 1 McGuirt WF. Maxillectomy. *Otolaryngol Clin North Am* 1995;28(06):1175–1189
- 2 Harrison DF. The management of malignant tumors of the nasal sinuses. *Otolaryngol Clin North Am* 1971;4(01):159–177
- 3 Smith RR, Klopp CT, Williams JM. Surgical treatment of cancer of the frontal sinus and adjacent areas. *Cancer* 1954;7(05):991–994
- 4 Maniglia AJ. Indications and techniques of midfacial degloving. A 15-year experience. *Arch Otolaryngol Head Neck Surg* 1986;112(07):750–752
- 5 Likhterov I, Roche AM, Urken ML. Contemporary osseous reconstruction of the mandible and the maxilla. *Oral Maxillofac Surg Clin North Am* 2019;31(01):101–116
- 6 Bidra AS, Jacob RF, Taylor TD. Classification of maxillectomy defects: a systematic review and criteria necessary for a universal description. *J Prosthet Dent* 2012;107(04):261–270
- 7 Brown JS, Rogers SN, McNally DN, Boyle M. A modified classification for the maxillectomy defect. *Head Neck* 2000;22(01):17–26
- 8 Okay DJ, Genden E, Buchbinder D, Urken M. Prosthodontic guidelines for surgical reconstruction of the maxilla: a classification system of defects. *J Prosthet Dent* 2001;86(04):352–363
- 9 Chigurupati R, Aloor N, Salas R, Schmidt BL. Quality of life after maxillectomy and prosthetic obturator rehabilitation. *J Oral Maxillofac Surg* 2013;71(08):1471–1478
- 10 Genden EM, Okay D, Stepp MT, et al. Comparison of functional and quality-of-life outcomes in patients with and without palatamaxillary reconstruction: a preliminary report. *Arch Otolaryngol Head Neck Surg* 2003;129(07):775–780
- 11 Genden EM, Lee BB, Urken ML. The palatal island flap for reconstruction of palatal and retromolar trigone defects revisited. *Arch Otolaryngol Head Neck Surg* 2001;127(07):837–841
- 12 Genden EM, Buchbinder D, Urken ML. The submental island flap for palatal reconstruction: a novel technique. *J Oral Maxillofac Surg* 2004;62(03):387–390
- 13 Swartz WM, Banis JC, Newton ED, Ramasastry SS, Jones NF, Acland R. The osteocutaneous scapular flap for mandibular and maxillary reconstruction. *Plast Reconstr Surg* 1986;77(04):530–545
- 14 Shipchandler TZ, Waters HH, Knott PD, Fritz MA. Orbitomaxillary reconstruction using the layered fibula osteocutaneous flap. *Arch Facial Plast Surg* 2012;14(02):110–115
- 15 Okay DJ, Buchbinder D, Urken M, Jacobson A, Lazarus C, Persky M. Computer-assisted implant rehabilitation of maxillomandibular defects reconstructed with vascularized bone free flaps. *JAMA Otolaryngol Head Neck Surg* 2013;139(04):371–381
- 16 Cordeiro PG, Santamaria E. A classification system and algorithm for reconstruction of maxillectomy and midfacial defects. *Plast Reconstr Surg* 2000;105(07):2331–2346, discussion 2347–2348