

Original Article

Tandem Traction Bow Appliance for the Treatment of Skeletal Class III Malocclusion

Shetty Prajwal K.¹, Priyanka S. Udeshi², Kuttappa M.N.³, Nanda kishore P.⁴, Ravi M.S.⁵, Nayak Krishna U.S.⁶

¹Reader, ²Post Graduate student, ³Professor, ⁵Head of the Department, ⁶Principal and Dean, Department of Orthodontics and Dentofacial Orthopedics, ⁴Head, Department of Craniofacial Orthodontics, A.B. Shetty Memorial Institute of Dental Sciences, Nitte Deemed to be University, Deralakatte, Mangalore - 575 018.

Corresponding Author : **Udeshi Priyanka S.**, Department of Orthodontics and Dentofacial Orthopedics, A.B. Shetty Memorial Institute of Dental Sciences, Nitte Deemed to be University, Deralakatte, Mangalore 575018.

Mobile: +91 89047 80424 E-mail: priyankaudeshi13@gmail.com

Received : 11.01.2018

Review Completed : 28.02.2018

Accepted : 03.03.2018

Keywords : Skeletal Class III malocclusion, Maxillary deficiency, Tandem Traction Bow Appliance (TTBA), Growing individuals

Abstract

Background and Objectives: Skeletal class III is a growth related discrepancy which continues and becomes more severe until active growth is completed. Approximately three percent of Indian population exhibits class III malocclusion. This can be due to a mid face deficiency, a large mandible or their combination. Various treatment modalities are available for correction of class III malocclusion in growing children, one of which is the Tandem Traction Bow Appliance (TTBA). This study was planned and designed to evaluate the dental and skeletal effects of TTBA used for the correction of skeletal Class III malocclusion with maxillary deficiency.

Materials and Methods: An in-vivo study designed to study the effects of TTBA on class III malocclusion with maxillary deficiency. The study was carried out on ten patients (age 6-12 years). Pre and post lateral cephalograms were traced and analyzed. Paired t test was used to compare values.

Result: The significant changes seen in the dental and skeletal parameters were upper and lower incisor retraction, Increase in ANB angulations and forward and downward movement of the maxillary arch.

Conclusion: TTBA is effective in early treatment of Skeletal Class III malocclusion. Being intraoral, patient compliance is improved, thus making TTBA easier to use, both for the clinician as well as for the patient.

Access this article online

Quick Response Code



Introduction

Skeletal class III is a growth related discrepancy which continues and becomes more severe until active growth is completed. Approximately three percent of Indian population exhibits class III malocclusion.^[1]This can be due to a maxillary deficiency, a large mandible or their combination.^[2]Growing patients with skeletal class III malocclusion are one the most difficult cases for the clinician to handle.^[3]

Mid face deficiency is characterized by a decrease in the size of the maxilla, either in a transverse or a sagittal direction. This is usually seen as a maxillary constriction and may be accompanied with a cross bite, crowding or

protrusion of teeth.^[4]

Most patients having Class III malocclusion seek orthodontic treatment only after their active growth is completed. Due to this patients undergo psychological and physical trauma during the early phases of life^[3]

Treatment of skeletal Class III malocclusion has been approached by various methods: facemask, magnets, Frankel III, reverse Twin Block and many more. However, these appliances had certain limitations, being either poor patient compliance or esthetic compromise. Maxillary protraction with the help of elastics to an extra oral facemask along with a chin cup is most commonly used for

growing patients. Maxillary expansion is often used along with this to improve the orthopedic effect. It is important that the patient wears the facemask for the treatment to be successful^[5]

However, compliance problems are there due to the appearance of the extra oral appliance and skin irritation from the anchorage pads^[6]

TTBA was introduced by Chun et al (1999) as an intraoral device for the treatment of Class III malocclusion with the aim to overcome these difficulties. It was introduced with the objectives of patient comfort, better oral hygiene and most important of all it can be worn intra orally. Since it is worn intra-orally patients find it more comfortable and esthetic. It is removable making it easy for patient to maintain oral hygiene and allowing treatment to be suspended and restarted whenever clinician deems necessary without bonding or debonding.^[7] Therefore, this study was planned and designed to evaluate the dental and skeletal effects of TTBA used for the correction of skeletal Class III malocclusion with maxillary deficiency.

Materials and Methods

An in-vivo study was carried out to study the effects of TTBA on class III malocclusion on ten patients who reported to the Department of Orthodontics and Dentofacial Orthopedics of our institution.

Actively growing male or female patients in the age group of 6-12 years with SMI 1-4 were selected. Patients showing skeletal Class III due to maxillary deficiency were selected. Patients with anterior cross bite with average or low Mandibular plane angle were selected. Patients with syndrome, cleft lip or palate or having prognathic mandible were excluded from the study.

Materials used

1. Cephalograms taken on a PlanMeca 2002 Proline Cephalometric unit. Helsinki, Finland
2. Cephalometric tracing materials
3. Traction bow
4. Extra oral elastics
5. Upper splint with RME

6. Lower splint with head gear tubes

Appliance design

- a) Maxillary appliance: Consists of a splint covering the palate and occlusal surface of maxillary teeth with a hyrax screw in the center for lateral expansion. Hooks are placed near the canine region for engaging elastics. (Figure 1)
- b) Mandibular appliance: Consists of a splint that covers the buccle and lingual surfaces of mandibular teeth with headgear tubes placed in the molar region for insertion of the traction bow. (Figure 2)
- c) Traction bow: The Traction bow was modified from the one in conventional headgear. Here, the outer face bow was cut short corresponding with the angle of the mouth. Outer bow was bent so as to facilitate the placement of elastics. (Figure 3)
- d) Figure 4 shows Frontal photograph of the patient with the appliance in place.

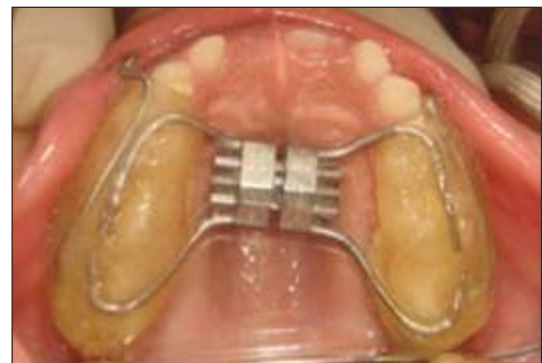

Figure 1 : Maxillary splint

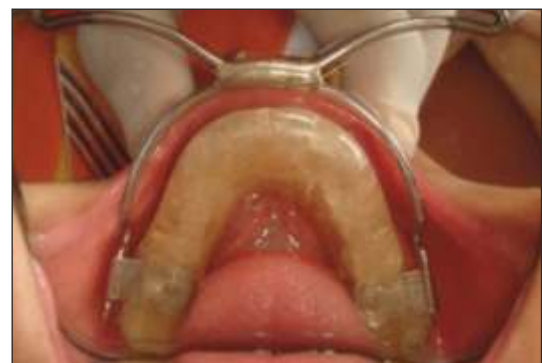

Figure 2 : Mandibular splint along with Traction bow



Figure 3 : Traction bow

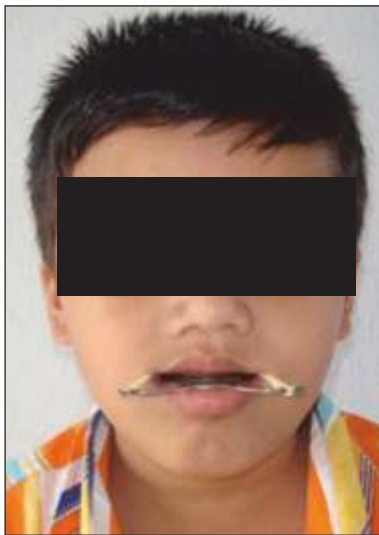

Figure 4 : Frontal photograph of the patient with appliance

Treatment Protocol

Ten patients were selected on the basis of inclusion and exclusion criteria. Pre-treatment lateral cephalogram were taken along with hand-wrist radiographs to check the maturation status. Tandem traction bow appliance was fabricated. Maxillary appliance was bonded on to the tooth surface. Mandibular appliance was removable. In the present study elastic force (measured with the help of a Dontrix gauge) of 300-600 grams was applied at an angle of 15° to 20° below the occlusal plane. This prevented upward and forward rotation of the maxilla. Hooks to which force was applied were placed above the center of resistance of the maxilla. Extra oral elastics were placed from hooks on the maxillary appliance to the traction bow which is attached to the mandibular appliance. The mandibular tubes should be located as posteriorly as possible. Appliance was worn for duration of 15 to 16 hours per day.

The average duration of the treatment was 8.3 months after which lateral cephalograms were taken for evaluation of the changes which had occurred due to the appliance therapy.

In the present study we expanded the maxilla for 4 days (2turns/day) before protraction. Since the posterior anatomic structures displace the maxilla anteriorly, activation of the screw is stopped on the fifth day so that we can know the effects of TTBA only.^[8] The total amount of activation of the screw was 2mm. In instances in which no transverse change is necessary, the maxillary splint is activated once a day for eight days to produce a disruption in the sutural system.^[9]

Patient pre- and post-treatment intraoral and extraoral photos have been depicted in Figures 5-8 respectively. The effect of TTBA was evaluated on cephalogram tracings by the following linear and angular measurements:

Linear measurement

S-A : Changes which have occurred in the position of point A (regarded as the anterior limit of apical base of maxilla) in the pre and post TTBA cephalograms measured from point S (geometric centre of pituitary fossa) to point A in millimeters.

Angular measurements:

Skeletal

SNA: Changes in pre-treatment and post-treatment TTBA SNA angles

SNB: Changes in pre-treatment and post-treatment TTBA SNB angles

ANB: Change in of pre-treatment and post-treatment TTBA ANB angles.

Dental

Dental changes were measured by

IAU: The angle formed by long axis of upper incisor to NA line

IAL: The angle formed by long axis of lower incisor to NB line.

SNI: The angle formed by long axis of upper incisor to SN plane is also compared.

The points and angles taken for the cephalometric analysis are illustrated in figures 9 and 10 respectively.

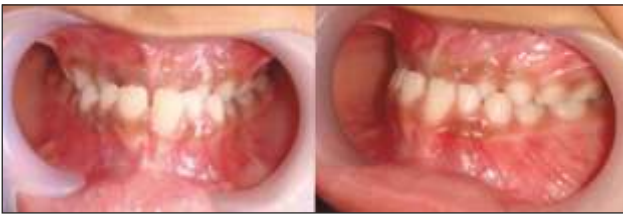

Figure 5 : Pre-treatment intraoral frontal and lateral photographs

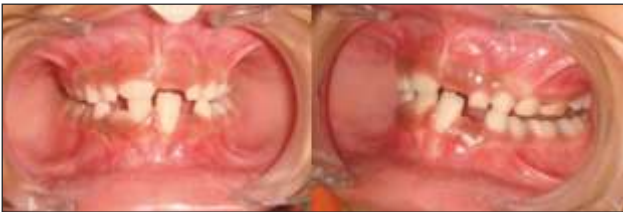

Figure 6 : Post- treatment intraoral frontal and lateral photographs

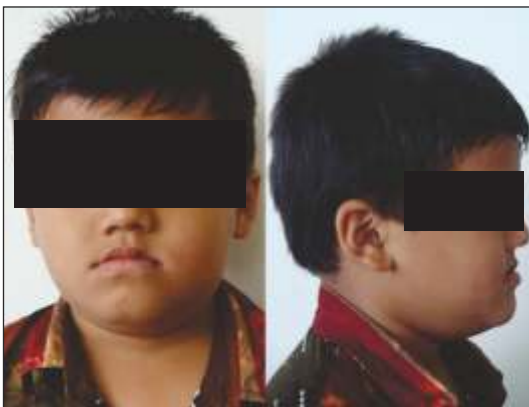

Figure 7 : Pre-treatment extra oral frontal and lateral photographs

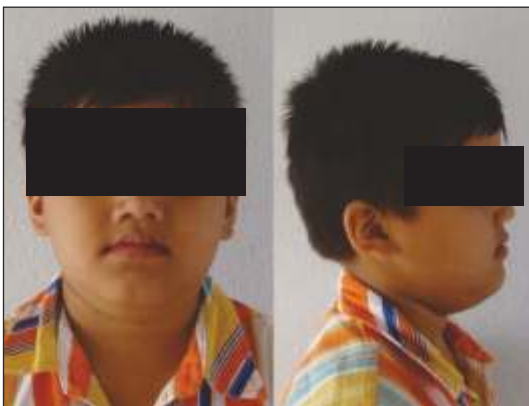

Figure 8 : Post-treatment extra oral frontal and lateral photographs

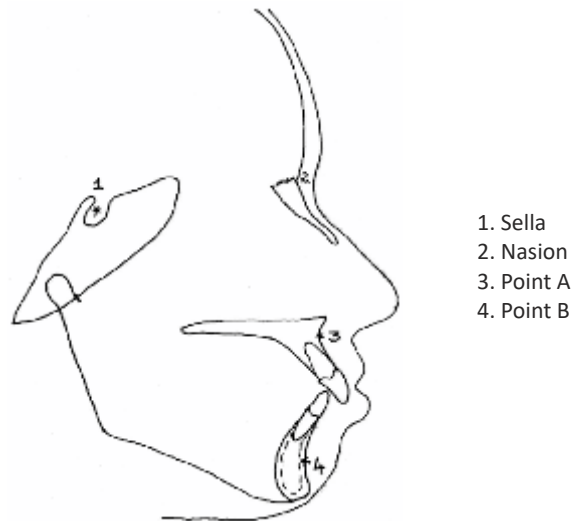


Figure 9 : Points on Lateral Cephalograms

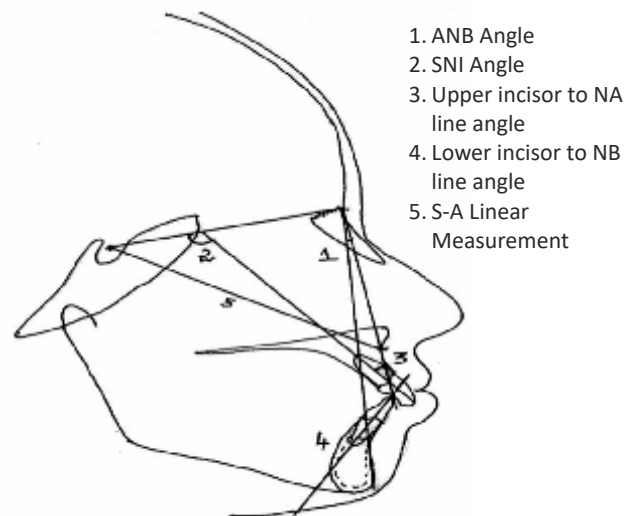


Figure 10 : Angles and linear measurements on lateral cephalograms

Analysis of data and statistics

The results were ascertained by paired t test to compare pretreatment and post treatment changes. The analysis was undertaken using SPSS version 22 (USA) package. A p-value of 0.05 or less was considered for statistical significance.

Results

After an average treatment time of 8.3months of TTBA therapy, post treatment lateral cephalograms were taken and were compared to the pretreatment cephalograms. Angular and linear measurements were compared and subjected to statistical analysis with the following results:

The mean pretreatment S-A measurements (79.15 with a standard deviation of 1.454) was compared with mean post-treatment measurements (81.35 with a standard deviation of 1.292). The maxilla moved in a forward and downward direction.(table:1&graph:1) The point A moved by 2.2mm. The p value was found to be 0.005 which is statistically significant. (table:2)

The mean pretreatment SNA angle (77.40° with a standard deviation of 0.966) was compared with mean post treatment measurements (80.20 with a standard deviation of 0.788). The SNA angle increased by 2.8°(table 1 & graph 2). The p value was found to be <0.005 which was statistically significant. (table 2)

The mean pretreatment SNB angle (79.30 with a standard deviation of 1.251) was compared with mean post treatment measurements (78.90 with a standard deviation of 0.994). The SNB angle decreased by 0.4°(table 1 & graph 3). The p value was found to be < 0.005 which was statistically significant. (Table 2)

The mean pretreatment ANB angle (-1.90° with a standard deviation of 0.737) was compared with mean post treatment measurements (1.30 with a standard deviation of 0.948). The ANB angle increased by 3.2°. (table: 1 & graph : 4). The p value was found to be < 0.005 which was statistically significant. (table 2)

The mean pretreatment upper incisal angulations(38.10 with a standard deviation of 2.813) was compared with mean post treatment measurements (29.80 with a standard deviation of 2.098).The mean upper incisal angulations decreased by 8.3°.(table:1&graph:5). The p value was found to be <.0005 which was statistically significant. (table 2)

The mean pretreatment lower incisal angulations (23.20 with a standard deviation of 9.138) were compared with mean post-treatment measurements (19.60 with a standard deviation of 9.204).The mean lower incisal angulation decreased by 3.6°. (Table 1&graph: 6). the p value was found to be .007 which was statistically significant. (Table 2)

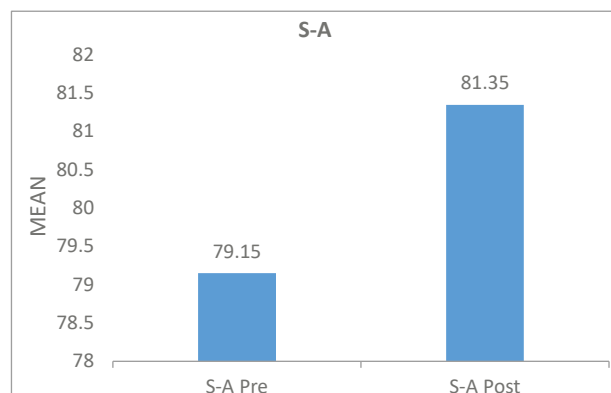
The mean pretreatment Sn to upper incisal angulations (109.50 with a standard deviation of 2.713) was compared with mean post-treatment measurements (110.30 with a standard deviation of 2.058). The incisal angulation had marginally increased by 0.8°. (table 1& graph 7). The p value was found to be .011 which was statistically significant. (Table: 2)

Table 1 : Comparison of the outcome measures before and after treatment in subjects who received TTBA treatment by using paired sample 't' test

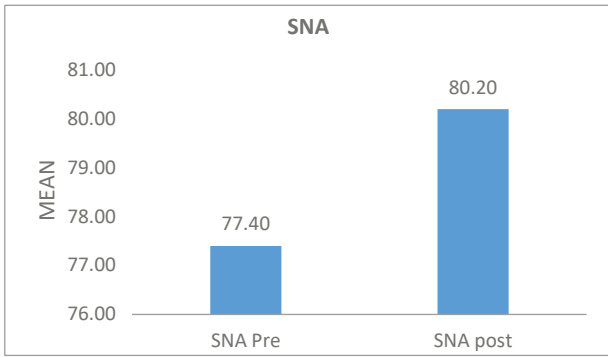
		N	MEAN	STD. DEV
1.	S-A Pre	10	79.15	1.454
	S-A Post	10	81.35	1.292
2.	SNA Pre	10	77.40	0.966
	SNA post	10	80.20	0.788
3.	SNB Pre	10	79.30	1.251
	SNB Post	10	78.90	0.994
4.	ANB Pre	10	-1.90	0.737
	ANB Post	10	1.30	0.948
5.	IA U Pre	10	38.1	2.183
	IA U Post	10	29.8	2.098
6.	IA L Pre	10	23.2	9.138
	IA L Post	10	19.6	9.204
7.	SNI Pre	10	109.5	2.173
	SNI Post	10	110.3	2.058

Table 2 : Comparison of effectiveness of the outcome measures before and after treatment in subjects who received TTBA treatment by using independent sample 't' test

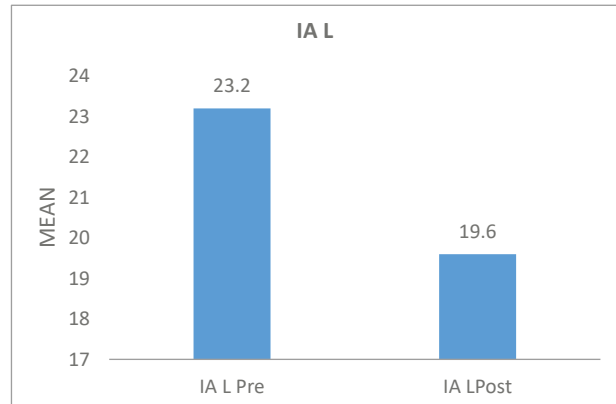
		Mean diff	t	P-value
1	S-A Pre - S-A Post	-2.2	-11.854	0.005*
2	SNA Pre - SNA Post	-2.8	-21.000	<.0005*
3	SNB Pre- SNB Post	0.4	2.449	<.0005*
4	ANB Pre - ANB Post	-3.2	-16.000	<.0005*
5	IA U Pre - IA U Post	8.3	8.032	<.0005*
6	IA I Pre - IA I Post	3.6	3.478	0.007
7	SNI Pre - SNI Post	-0.8	-3.207	0.011



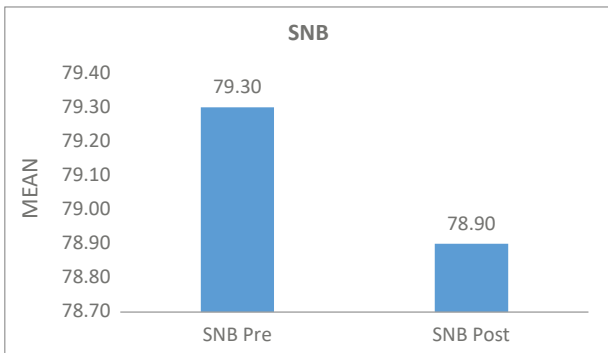
Graph 1 : Comparison of mean pretreatment and post treatment S-A measurements



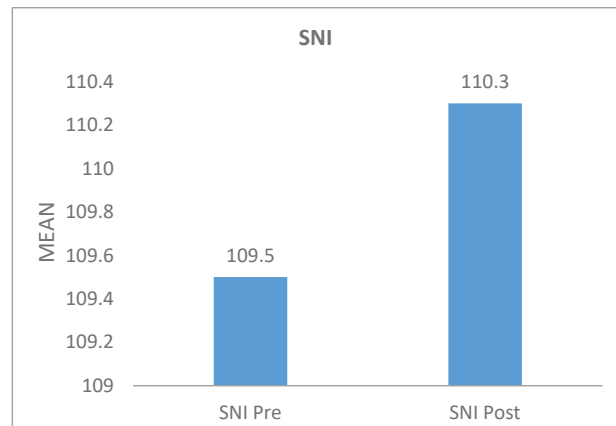
Graph 2 : Comparison of mean pretreatment and post treatment SNA angles



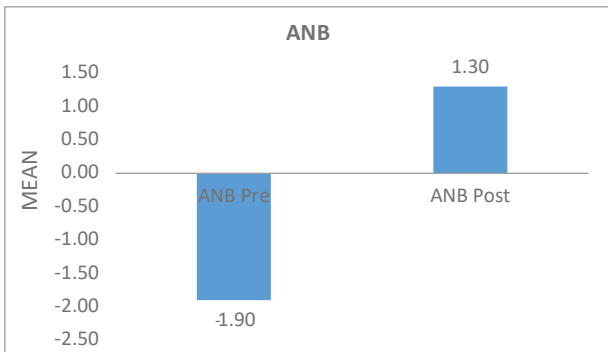
Graph 6 : Comparison of mean pretreatment and post treatment lower incisal angulations



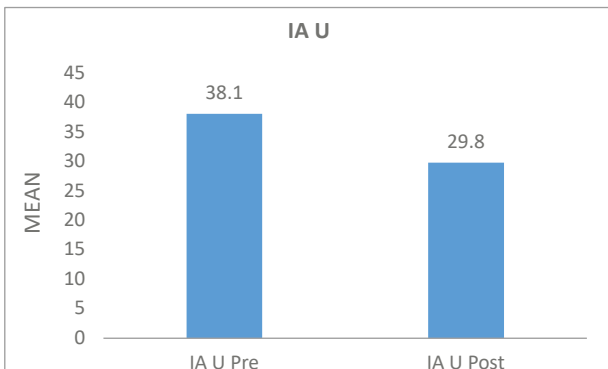
Graph 3 : Comparison of mean pretreatment and post treatment SNB angles



Graph 7 : Comparison of mean pretreatment and post treatment upper incisor angulation in relation to SN plane



Graph 4 : Comparison of mean pretreatment and post treatment ANB angles



Graph 5 : Comparison of mean pretreatment and post treatment upper incisal angulations

Discussion

Age of the patient helps in deciding which treatment modality should be undertaken for patients having Class III malocclusion that is surgery or growth modulation. Early management of skeletal class III malocclusion can be done by traction to the maxilla with maxillary propulsor or a mandibular retropulsar. When there is deficient maxilla, option of treatment is maxillary protraction which can be in the form of class III functional appliance such as reverse pull headgear. As the compliance of the patients with reverse pull headgear is not good, newer appliances like TTBA have come into force. The present study was carried out to evaluate skeletal and dental changes during TTBA therapy.

The RME was activated for 4 days (2turns/day) before protraction. Since the posterior anatomic structures displace the maxilla anteriorly, activation of the screw is

stopped on the fifth day so that we can know the effects of TTBA only.^[8] The total amount of activation of the screw was 2 mm. In instances in which no transverse change is necessary, the maxillary splint is activated once a day for eight days to produce a disruption in the sutural system that facilitates the action of the facial mask.^[5] Some clinicians use an RME even when no cross bite is present.^[10]^[11] The RME should be activated as necessary before placing the protraction head gear. If there is no cross bites, it can be deactivated once the mid palatal suture has been separated.^[12]

Skeletal changes that were related to TTBA wear, (5 linear and angular parameters) were analyzed as follows:

Point A shifted on an average of 2.2 mm ($P = 0.005$) (table:2). Furthermore, within this group, the growth factor plays a larger role as A point grows 0.8 mm per year (measured along SA vector), during this treatment expect approximately 0.5 mm of change in point A due to growth. So we can say that average of 1.8 mm of correction took place due to TTBA. The findings substantiate the results of McNamara et al, who reported forward repositioning of the maxilla as well as an increase in lower anterior face height with the use of the Frankel III appliance.^[13]

The SNA angle increased (-2.8°) and SNB angle decreased significantly (0.4°) leading to increase in ANB angle. Comparing mean pre and post treatment ANB angle, there was a significant change of -3.2° ($P < 0.005$) (table 2) from the initial to immediate post TTBA therapy. This correction indicated that there was improvement in skeletal class III malocclusion. The results were similar to other studies.^[1,2]

Comparing pre and post treatment mean incisal angulations it was noted that there was lingual tipping of both upper and lower incisors. Upper incisors were retro cline in relation to NA line by 8.3° ($p=0.0005$) (table2). Lower incisors were retro cline in relation to NB line 3.6° ($p=0.007$) (table2). As the treatment was undertaken in the early mixed dentition the correction achieved were predominantly skeletal and also due to the clockwise rotation of maxilla along with downward and forward

movement of point A. This can be perceived as a reason for retroclination of upper incisors in relation to NA line^[6]

On comparison of pretreatment and post treatment angulation of SN plane to upper incisor there was an increase in angulation in the post treatment group by 0.8° ($p=0.011$) (table:2) which was of statistical significance. This was in accordance with the previous studies which showed proclination of upper incisors maxillary protraction using propulsions^[14]

Thus the TTBA has the following advantages^[1,7]

Promotes patient compliance, because it is more esthetic and comfortable than extra oral appliances. The TTBA is small enough to be stored in a removable appliance case.

Promotes good oral hygiene, because the lower splint is removable.

Allows early treatment of any Class III malocclusion, due to optimal retention in the deciduous, mixed, or early permanent dentition.

Permits free mandibular movement, with its polished occlusal surface, so that any functional shift is easily corrected.

Requires no additional biteplate for correction of anterior cross bite.

Conclusion

The significant changes seen in the dental and skeletal parameters were upper and lower incisor retraction, skeletal changes by an increase in ANB angulations and forward and downward movement of the maxillary arch. TTBA is effective in early treatment of Skeletal Class III malocclusion. Being intraoral, patient compliance is improved, thus making TTBA easier to use, both for the clinician as well as for the patient.

Limitations

1. No control was taken to assess growth related changes
2. The results were part of a short term study and will differ with long term follow ups
3. A randomized clinical trial is recommended for best level of evidence

References

1. Akhilesh Sharma, Sourabh Ramesh Joshi, Amitha M Hegde, Rajmohan Shetty. Early treatment of class III Malocclusion with Modified Tandem Traction Bow Appliance and a Brief Literature Review. OHDM - Vol. 13 - No. 3 - September, 2014.
2. Zeynep Atalay and Tuba Tortop. Dentofacial effects of a modified tandem traction bow appliance. *European Journal of Orthodontics* 32 (2010) 655–661.
3. Nanda, R. Biomechanical and clinical considerations of modified protraction head-gear, *Am J Orthod Dentofac Orthop* 1980;78:125-139.
4. James A. McNamara. Maxillary transverse deficiency. *Am J Orthod Dentofac Orthop* 2000; p.567-570.
5. Sang J. Sung and Hyoung S. Baik: Assessment of skeletal and dental changes by maxillary protraction. *Am J Orthod Dentofac Orthop* 1998;114:492-502.
6. Valgadge SB, Chougule K. Early treatment of Class III malocclusion with a tandem traction bow appliance. *APOS Trends Orthod* 2016;6:228-31.
7. Yuon-Sic Chun, Sweong Jeong, Joon Row and Sung-Yang. New orthopedic appliance for correction of Class III malocclusion, *JCO* 1999;33:705-711.
8. Toros Alcan, Ahmet Keles, and Nejat Erverdi: The effects of a modified protraction headgear on maxilla. *Am J Orthod Dentofac Orthop* 2000;117:27-38.
9. Petit, H. P. Adaptation following accelerated facial mask therapy. In: McNamara JA Jr, Ribbens KA, Howe RP, eds. *Clinical Alteration of the Growing Face. Monograph 14, Craniofacial Growth Series*. Ann Arbor, Mich: Center for Human Growth and Development, University of Michigan; 1983.
10. James A. McNamara jr: An Orthopedic Approach to the Treatment of Class III Malocclusion in Young Patients, *JCO* 1987;21:598–608.
11. Haas, A.H.: Rapid palatal expansion: A recommended prerequisite to Class III treatment. *Trans. Eur. Orthod. Soc.*, 1973, pp. 311-318.
12. Julie Ann Stagers, Nicholas Germane, and Harry L: Clinical Considerations in the Use of Protraction Headgear. *JCO* 1992;26: 87–91.
13. Baccetti T, McGill J S, Franchi L, McNamara Jr J A and Tollaro I : Skeletal effects of early treatment of Class III malocclusion with maxillary expansion and face-mask therapy. *Am J Orthod Dentofac Orthop* 1998;113 :333–343.
14. Pangrazio-Kulbersh, V.; Berger, J.; and Kersten, G.: Effects of protraction mechanics on the midface, *Am J Orthod Dentofac Orthop*. 1998;14:484-491.