

Original Article

Comparative Distalization Effects Of Conventional Pendulum Appliance And Bone Anchored Pendulum Appliance

Crystal Runa Soans¹, Ashutosh Shetty², Murali P.S.³, Azhar Mohammed⁴, U.S. Krishna Nayak⁵, Keerthan Shashidhar⁶

^{1, 3, 4} Lecturer, ^{2, 5} Professor, ⁶ Post Graduate, Department of Orthodontics and Dentofacial Orthopaedics, A.B. Shetty Memorial Institute of Dental Sciences, Mangalore, Karnataka.

Corresponding Author : Crystal Runa Soans, Lecturer, Department of Orthodontics and Dentofacial Orthopaedics, A.B. Shetty Memorial Institute of Dental Sciences, Deralakatte, Mangalore, Karnataka, E-Mail : drcrystalsoans@gmail.com

Received : 22.07.2017

Review Completed : 29.11.2017

Accepted : 02.02.2018

Keywords : Angles Class II Malocclusion, Molar Distalization, Conventional Pendulum Appliance, Bone Anchored Pendulum Appliance

Abstract :

Introduction: The introduction of intraosseous screws as temporary orthodontic anchorage devices has proved successful in achieving sufficient molar distalization without major anchorage loss in Class II malocclusions. Bone-anchored pendulum appliance is used to obtain an effective and compliance-free molar distalization without anchorage loss.

Aims And Objectives: This prospective study was designed to evaluate and compare the skeletal and dentoalveolar effects produced by 2 types of pendulum appliance with different anchorage modalities - the Bone anchored pendulum appliance (BAPA) and Conventional pendulum appliance (CPA) in subjects with Angle's Class II malocclusion.

Materials and Methods: BAPA group consisted of 5 patients with mean age, 16.4±1.5 years. The CPA group consisted of 5 patients with mean age, 16.6±1.1 years. Lateral cephalograms & dental casts were obtained at pre-treatment stage & after achieving Class I molar relation. Dentoalveolar, skeletal, soft tissue measurements and dental cast measurement were recorded & compared between the groups.

Results and Conclusions: Successful distalization was achieved in both groups in a mean period of 6.2 months for BAPA and 5.2 months for CPA. It was concluded that, both the BAPA and CPA were effective for the distalization of maxillary molars. Though the distal molar movements obtained were similar between the BAPA and the CPA groups, anchorage loss was observed with the CPA in the form of premolar mesialization & incisor proclination, whereas absence of anchorage loss, significant spontaneous distal premolar movement, and distal incisor movement was observed with the BAPA, making it a viable choice compared to the CPA.

Access this article online

Quick Response Code



Introduction

The etiology, components and orthodontic management of Class II malocclusion have been a subject of frequently differing philosophies among practitioners. Treatment modalities for correction of Class II malocclusion have included extraction of teeth, extraoral forces, interarch elastics, functional appliances, noncompliance techniques with Herbst appliance, and, more recently, intra-arch maxillary molar distalizing techniques.¹

Distalization of molars has become a popular non-extraction treatment alternative to get upper molars into a final Class I relationship. The Pendulum appliance, developed by Hilgers², has become one of the more popular

non compliance appliance designs. However certain side effects like anchorage loss in the form of increased overjet and molar tipping were evident.³

The introduction of intraosseous screws as temporary orthodontic anchorage devices has proved successful in achieving sufficient molar distalization without major anchorage loss.^{4,5} Kircelli et al⁶ designed the Bone-anchored pendulum appliance (BAPA), to obtain an effective and compliance-free molar distalization without anchorage loss.

The present study intends to evaluate and compare the dentoalveolar and skeletal effects obtained with Pendulum appliance using (a) conventional anchorage and (b) bone anchorage.

The study was conducted with the following aims and objectives:

1. To evaluate the distalization of the maxillary molars, and the movement of teeth anterior to maxillary first molars, in both CPA and BAPA
2. To compare the dentoalveolar and skeletal effects obtained with Bone anchored pendulum appliance and Conventional pendulum appliance.

Materials and Methods

Source of Data:

This study was conducted in the Department of Orthodontics and Dentofacial Orthopaedics, A.B. Shetty Memorial Institute of Dental Sciences, Mangalore.

The sample of this study consisted of 10 subjects seeking orthodontic treatment with Angle's Class II malocclusion requiring maxillary molar distalization with an average or horizontal growth pattern, in the age group of 14-18 yrs.

An informed consent was taken and the 10 subjects were divided into 2 groups.

GroupA represented 5 orthodontic patients in whom maxillary molar distalization was attempted with a Bone Anchored Pendulum Appliance (BAPA) (Fig 1, 2)

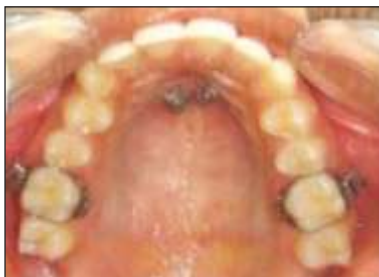

Fig. 1 : Placement of Intraosseous screws intraorally

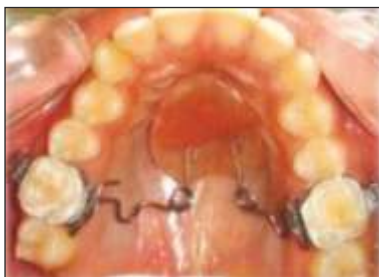

Fig. 2 : Bone Anchored Pendulum Appliance placed intraorally

Group B represented 5 orthodontic patients in whom maxillary molar distalization was attempted with a Conventional Pendulum Appliance (CPA) (Fig 3)

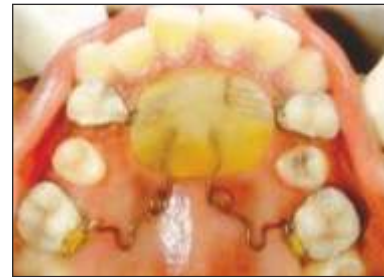

Fig. 3 : Conventional Pendulum Appliance placed intra orally

Inclusion criteria:

1. Patients with good oral hygiene.
2. Patients with average or horizontal growth pattern.
3. Patients with permanent dentition and Class II molar relation.
4. Moderate space deficiency in the maxillary arch and minimal or no crowding in the mandibular arch
5. Patients with fully erupted second molars.

Exclusion criteria:

1. Uncooperative patients
2. Poor oral hygiene
3. Skeletal Class II relation

Methodology

This prospective study was designed to evaluate and compare the skeletal and dentoalveolar effects produced by 2 types of pendulum appliances with different anchorage modalities -the Bone anchored pendulum appliance (BAPA) and Conventional pendulum appliance (CPA) in subjects with Angle Class II malocclusion.

The BAPA group consisted of 5 patients (4 girls, 1 boy; mean age, 16.4±1.5years). The CPA group consisted of 5 patients (4 girls, 1 boy; mean age, 16.6±1.1 years).The treatment results of BAPA group were compared with that ofthe CPA group.

The maxillary second molars were fully erupted in all patients in both the groups. The maxillary third molars were extracted in 8 of the total 10 patients selected for this study. In the remaining subjects, germectomy was not

advised as the tooth buds were highly placed above the second molar roots.

Cephalometric analysis and Dental Cast Measurements

Lateral cephalograms and dental casts were obtained at pre treatment and after achieving Class I molar relation (T2) to assess dentoalveolar, skeletal and soft tissue changes. Cephalometric analysis was done on the cephalograms using various parameters (Fig 3,4,5). Measurements were also recorded on the dental casts (Fig 6).

Skeletal :

1. SNB (°)
2. SNA (°)
3. ANB (°)
4. FMA (°)
5. SnGoGn (°)
6. PTV-A Point (mm)
7. PTV -Palatal plane (°)

Soft tissue :

8. Upper lip to E-Plane (mm)
9. Lower lip to E-Plane (mm)

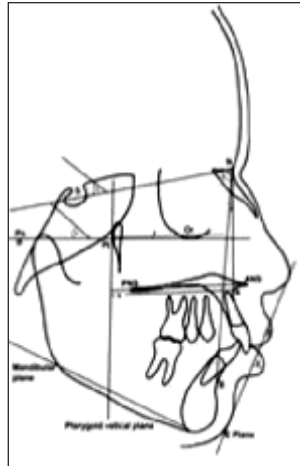


Fig. 4 : Skeletal and Soft tissue measurements

Dental -linear sagittal (mm)

1. Maxillary first molar -PTV
2. Maxillary second premolar - PTV
3. Maxillary first premolar -PTV
4. Maxillary incisor -PTV
5. Mandibular first molar -PTV
- Overjet

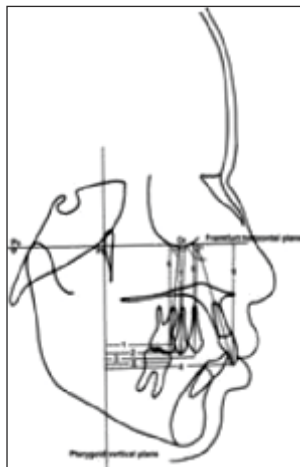


Fig. 5 : Dental linear (Sagittal) measurements

Dental -linear vertical

6. Maxillary first molar -FH
7. Maxillary second premolar -FH
8. Maxillary first premolar -FH
9. Maxillary incisor -FH

Overbite

- Dental - angular (°)
- 10. Maxillary first molar - FH
- 11. Maxillary second premolar -FH
- 12. Maxillary first premolar -FH
- 13. Maxillary incisor -FH

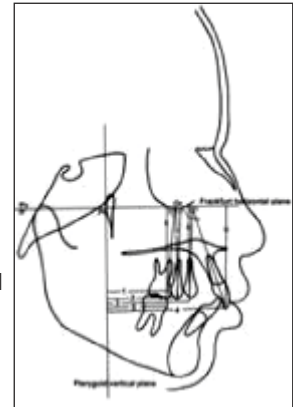


Fig. 6 : Dental linear and Dental angular measurements

1. Intermolar distance (mm)
2. Length of total arch perimeter (mm)
3. Length of anterior arch perimeter (mm)
4. Maxillary first molar - MPP (°)

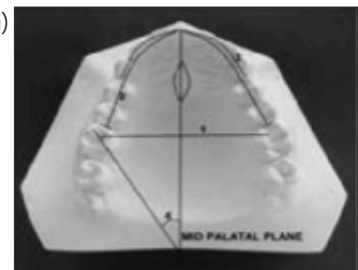


Fig 7. : Dental Cast Measurements

Statistical Analysis

Data obtained was analyzed using Statistical Package for Social Sciences. Analysis was done using SPSS version 14. The total number of samples in each group were 10(5 in BAPA group and 5 in CPA group) Comparison of mean scores were done for various parameters. Paired sample test for angular and linear skeletal measurements before and after treatment (T2-T1), Independent samples test for comparison of angular and linear skeletal measurements before and after treatment (T2-T1) between the groups were used. A p-value of <0.05 was set to be statistically significant.

Results

Clinically successful distalization was achieved in both groups in a mean period of 6.2 months for BAPA and 5.2 months for CPA (Table 1). The p value for the same is <0.05

Table 1 : Duration of months

The data collected presented with the following findings:

Group	N	Minimum	Maximum	Mean	Std. Deviation	p-value
BAPA	5	5.5	7	6.20	.57	0.024
CPA	5	4.5	6	5.20	.57	

Angular and linear skeletal measurements: (Table2,3) (graph 1)

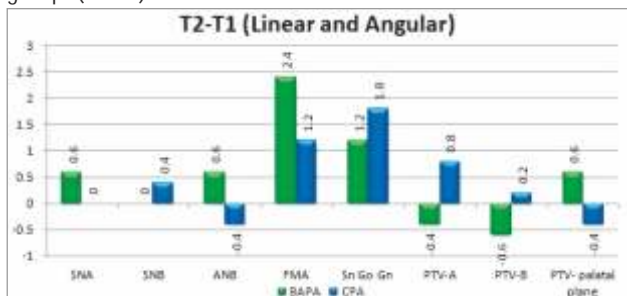
Table 2 : Paired sample test for angular and linear skeletal measurements

Group		T1		T2		p-value
		Mean	SD	Mean	SD	
BAPA	SNA	81.20	1.79	81.80	2.17	0.07
	SNB	79.40	1.52	79.40	2019	1
	ANB	1.80	0.84	2.40	0.89	0.07
	FMA	23.60	1.14	26.00	2.45	0.06
	Sn Go Gn	30.60	1.82	31.80	1.30	0.033
	PTV-A	56.40	3.91	56.00	3.24	0.374
	PTV-B	50.80	2.95	50.20	3.27	0.07
	PTV-PP	1.20	0.84	1.80	0.45	0.07
CPA	SNA	79.80	3.19	79.80	2.95	1
	SNB	77.60	2.70	78.00	2.55	0.62
	ANB	2.20	0.84	1.80	1.10	0.477
	FMA	25.00	5.24	26.20	3.63	0.284
	Sn Go Gn	31.00	3.39	32.80	2.17	0.088
	PTV-A	50.60	3.65	51.40	3.36	0.242
	PTV-B	42.40	7.80	42.60	7.64	0.799
	PTV-PP	1.80	0.84	1.40	0.96	0.099

Table 3 : Independent samples test for angular and linear skeletal measurements (T2-T1)

	BAPA		CPA		p-value
	Mean	SD	Mean	SD	
SNA	0.60	0.55	0.00	1.41	0.416
SNB	0.00	0.71	0.40	1.67	0.642
ANB	0.60	0.55	-0.40	1.14	0.115
FMA	2.40	2.07	1.20	2.17	0.397
Sn Go Gn	1.20	0.84	1.80	1.79	0.516
PTV-A	-0.40	0.89	0.80	1.30	0.128
PTV-B	-0.60	0.55	0.20	1.64	0.332
PTV-Palatal Plane	0.60	0.55	-0.40	0.42	0.012

Graph 1 : Comparison of Pre- Treatment and Post Distalization skeletal (linear and angular) measurements between the two groups (T2-T1)



Soft Tissue Measurements

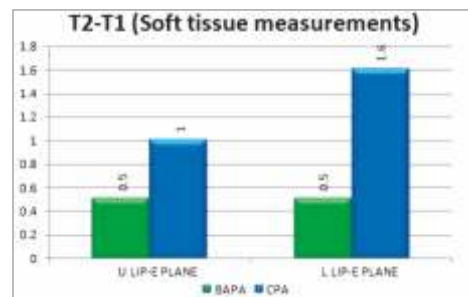
Table 4 : Paired sample test for soft tissue measurements

Group		T1		T2		p-value
		Mean	SD	Mean	SD	
BAPA	U LIP E PLANE	-2.70	3.03	-2.20	3.11	0.089
	L LIP E PLANE	0.80	3.70	1.30	2.82	0.326
CPA	U LIP E PLANE	-2.20	2.28	-1.20	1.92	0.298
	L LIP E PLANE	1.00	1.73	2.60	1.34	0.003

Table 5 : Independent samples test for soft tissue measurements

	BAPA		CPA		p-value
	Mean	SD	Mean	SD	
U LIP E PLANE	0.50	0.50	1.00	1.87	0.580
L LIP E PLANE	0.50	1.00	1.60	0.55	0.063

Graph 2 : Comparison of Pre- Treatment and Post Distalization soft tissue measurements between the two groups (T2-T1)



Dental linear measurements:

Sagittal

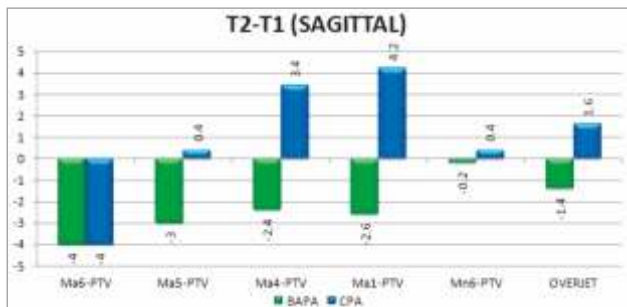
Table 6 : Paired sample test for dental linear (sagittal) measurements

Group		T1		T2		p-value
		Mean	SD	Mean	SD	
1	Ma6-PVT	32.60	3.58	28.60	3.36	<0.001
	Ma5-PVT	36.40	3.36	33.40	3.65	0.005
	Ma4-PVT	44.60	4.51	42.20	4.38	0.024
	Ma1-PVT	63.60	4.67	61.00	4.42	0.019
	Mn6-PVT	32.00	4.00	31.80	3.83	0.374
	OVERJET	4.80	1.79	3.40	1.14	0.108
	2	Ma6-PVT	30.40	2.41	26.40	1.95
Ma5-PVT		30.80	4.66	31.20	5.26	0.704
Ma4-PVT		37.80	4.55	41.20	6.46	0.096
Ma1-PVT		55.00	5.92	59.20	6.38	0.022
Mn6-PVT		28.00	4.00	28.40	3.91	0.178
OVERJET		4.00	0.71	5.60	1.67	0.078

Table 7 : Independent samples test for dental linear (sagittal) measurements (T2-T1)

Sagittal	BAPA		CPA		p-value
	Mean	SD	Mean	SD	
Ma6-PVT	-4.00	0.71	-4.00	1.41	1
Ma5-PVT	-3.00	1.22	0.40	2.19	0.022
Ma4-PVT	-2.40	1.52	3.40	3.51	0.017
Ma1-PVT	-2.60	1.52	4.20	2.59	0.001
Mn6-PVT	-0.20	0.45	0.40	0.55	0.094
OVERJET	-1.40	1.52	1.60	1.52	0.014

Graph 3 : Comparison of Pre- Treatment and Post Distalization dental linear (sagittal) measurements between the two groups (T2-T1)



Dental linear measurements:

Vertical

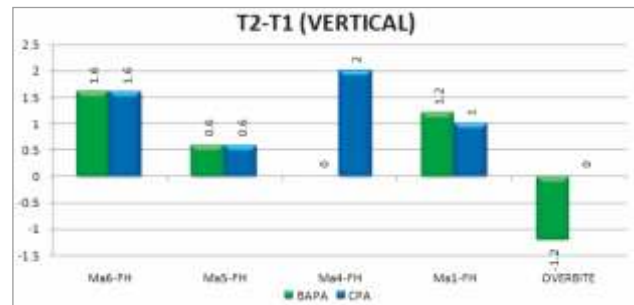
Table 8 : Paired sample test for dental linear (vertical) measurements

Group	Dentolinar	T1		T2		p-value
		Mean	SD	Mean	SD	
BAPA	Ma6-FH	47.40	3.36	49.00	3.74	0.003
	Ma5-FH	48.40	3.85	49.00	3.94	0.07
	Ma4-FH	49.20	4.09	49.20	4.32	1
	Ma1-FH	51.20	4.87	52.40	5.27	0.07
	OVERBITE	3.80	1.10	2.60	0.89	0.004
CPA	Ma6-FH	45.40	3.58	47.00	3.67	0.003
	Ma5-FH	47.20	3.63	47.80	2.59	0.426
	Ma4-FH	48.00	3.39	50.00	4.06	0.022
	Ma1-FH	52.00	4.69	53.00	3.00	0.326
	OVERBITE	3.20	1.30	3.20	0.84	1

Table 9 : Independent samples test for dental linear (vertical) measurements (T2-T1)

Vertical	BAPA		CPA		p-value
	Mean	SD	Mean	SD	
Ma6-FH	1.60	0.55	1.60	0.55	1
Ma5-FH	0.60	0.55	0.60	1.52	1
Ma4-FH	0.00	1.00	2.00	1.22	0.022
Ma1-FH	1.20	1.10	1.00	20.00	0.8429
OVERBITE	-1.20	0.45	0.00	1.22	0.074

Graph 4 : Comparison of Pre- Treatment and Post Distalization dental linear (vertical) measurements between the two groups (T2-T1)



Dental angular measurements

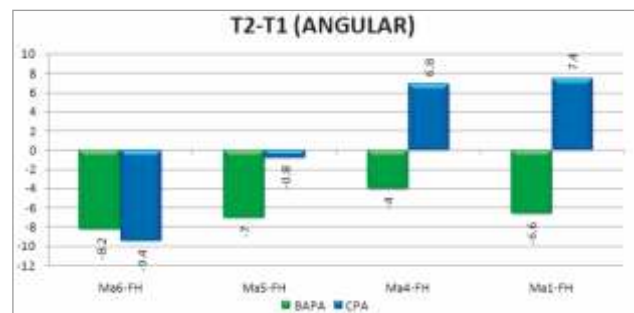
Table 10 : Paired sample test for dental angular measurements

Group	Angular	T1		T2		p-value
		Mean	SD	Mean	SD	
BAPA	Ma6-FH	84.40	1.52	76.20	2.95	0.002
	Ma5-FH	88.00	2.35	81.00	4.69	0.023
	Ma4-FH	90.00	0.71	86.00	4.47	0.092
	Ma1-FH	120.20	8.47	113.60	10.33	0.003
CPA	Ma6-FH	82.00	8.46	72.60	6.66	0.004
	Ma5-FH	84.60	8.05	83.80	7.79	0.294
	Ma4-FH	86.20	6.06	93.00	10.15	0.038
	Ma1-FH	144.60	8.38	122.00	8.00	0.003

Table 11 : Independent samples test for dental angular measurements (T2-T1)

Angular	BAPA		CPA		p-value
	Mean	SD	Mean	SD	
Ma6-FH	-8.20	2.59	-9.40	3.65	0.565
Ma5-PVT	-7.00	4.36	-0.80	1.48	0.017
Ma4-FH	-4.00	4.06	6.80	4.97	0.006
Ma1-FH	-6.60	2.30	7.40	2.51	<0.001

Graph 5 : Comparison of Pre- Treatment and Post Distalization dental angular measurements between the two groups (T2-T1)



Dental cast measurements

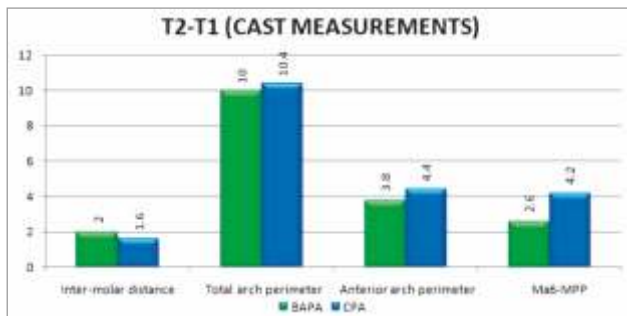
Table 12 : Paired sample test for dental cast measurements

Group	Cast measurements	T1		T2		p-value
		Mean	SD	Mean	SD	
BAPA	Inter - molar distance	47.40	2.30	49.40	2.61	0.047
	Total arch perimeter	79.80	6.02	89.80	5.40	0.007
	Anterior Arch perimeter	49.60	3.36	53.40	3.58	0.003
	Ma6-MPP	33.40	2.70	36.00	2.55	0.007
CPA	Inter - molar distance	46.40	1.95	48.00	2.74	0.078
	Total arch perimeter	77.00	2.92	87.40	4.62	0.002
	Anterior Arch perimeter	49.60	3.78	54.00	4.24	0.001
	Ma6-MPP	32.20	2.49	36.40	2.30	0.001

Table 13 : Independent samples test for dental cast measurements (T2-T1)

	BAPA		CPA		p-value
	Mean	SD	Mean	SD	
Inter - molar distance	2.00	1.58	1.60	1.52	0.694
Total arch perimeter	10.00	4.30	10.40	3.36	0.874
Anterior arch perimeter	3.80	1.30	4.40	1.14	0.461
Ma6-MPP	2.60	1.14	4.20	1.10	0.053

Graph 6 : Comparison of Pre- Treatment and Post Distalization dental cast measurements between the two groups (T2-T1)



Discussion

The pendulum appliance has experienced wide spread clinical use, and various studies have demonstrated its skeletal and dentoalveolar effects.^{7,8,9} It has two main advantages over headgear and Class II elastics.¹⁰ One being, distalization occurs without any cooperation problems on the part of the patients and the other being, only one activation period is needed for the process to be successful. However, associated collateral effects like anterior anchorage loss, which represented 30-43% of the space created between molars and premolars, was a constant finding with use of this appliance as shown in various studies.^{5,7,8,10}

The introduction of bone anchors as anchorage devices has

been a great revolution in orthodontics. Several types of anchors have been used such as conventional osseo integrated implants and, more recently, mini-implants, length-reduced palatal implants etc. Elimination of the osseo integration period (2-6 months), wider range of application sites, simple surgical procedures, and decreased cost make intra osseous screws the preferable anchorage device. In the present study we used 2 screws based on the study by Kircelli et al⁷ to increase the success rate. The site of intraosseous placement was the paramedian region of the palate with a mean bone depth of 10.57mm.

Although the dentofacial effects of the BAPA and CPA have been demonstrated separately in previous studies,^{8, 9,11,12,13-15} comparative treatment results of the two appliance systems in terms of treatment duration, skeletal changes, and soft tissue response and tooth movement with cephalometric and dental cast measurements have not been reported previously.

In our study, the maxillary molars in both groups were distalized successfully to Class I relationships with minimal patient compliance. The average distalization periods were 6.2 months for the BAPA and 5.2 months for CPA. The difference in time taken for treatment was statistically significant. (p=0.024). There was significant amount of distal molar movement in both the BAPA and CPA group. The average distance of molar movement between the 2 groups was similar; 4.0±0.71mm in BAPA group and 4.0±1.41mm in CPA group.

Intraoral distalizing appliances act on the dental crowns at a certain distance from the centre of resistance of the molars, and therefore distal tipping is expected. This tipping is similar to that produced by the cervical headgear. In this study the amount of molar tipping observed were 8.20°±2.59° in the BAPA group and 9.40°±3.56° in the CPA group. The difference between the groups was statistically not significant. (p>0.05)

While most of the studies^{7, 8, 12, and 16} on pendulum appliance have reported molar intrusion, some have reported molar

extrusion as well. In our study, there was a small amount of vertical change seen in the maxillary first molars of both groups. The BAPA group showed molar extrusion of 1.6 ± 0.5 mm and the CPA group showed molar intrusion of 1.60 ± 0.5 mm. These values were statistically significant ($p=0.003$). Distalization techniques tend to increase the extrusion of the molars,^{17,18} and also the bite opening seen in most distalization studies have been attributed to the extrusion of the maxillary first molars.^{13,19} This could explain the molar extrusion and reduction in overbite with the BAPA.

Loss of anchorage was measured at the maxillary 1st premolars and incisors. Premolar and incisor movements were quite different between the 2 groups. In the BAPA group, both the first (2.4 ± 1.52 mm/ $4.0^\circ \pm 4.06$) and second (3.00 ± 1.22 mm/ $7.0^\circ \pm 4.36$) premolars were significantly ($p < 0.05$) distalized and distally tipped spontaneously. The maxillary incisors were significantly ($p < 0.001$) retroclined ($6.6^\circ \pm 2.3^\circ$) and retracted by 2.6 ± 1.52 mm. A significant ($p < 0.05$) decrease in over jet (1.4 ± 1.52 mm) was also observed. The reactive forces arising from the pendulum springs were directly resisted by intraosseous screws, and the premolars and incisors drifted distally due to the stretch of transeptal fibres during the distalization period. These movements could contribute favourably to the overall treatment time. On the other hand, the CPA group showed significant loss of anchorage with mesial tipping and mesial movement of first premolars ($6.8^\circ \pm 4.97^\circ$ / 3.4 ± 3.51 mm), and a small but significant amount of extrusion (2.0 ± 1.22 mm). The incisors were significantly ($p < 0.001$) proclined by $7.4^\circ \pm 2.51^\circ$ / 4.2 ± 2.59 mm and there was significant increase in over jet (1.6 ± 1.52 mm). The use of a Nance button to reinforce anterior anchorage has been suggested by many, but reports state that it does not serve as absolute anchorage during and after molar distalization.^{6,20} The anchorage unit is unable to completely resist mesial forces thereby proclining the maxillary incisors and increasing the overjet. Study by Burkhardt et al,²⁰ support our findings of anchorage loss by incisor tipping.

Skeletal values and soft tissue effects

Pendulum appliance primarily affects the dentition, but there are simultaneous indirect effects on the skeletal and soft tissue structures. In our study, a significant counter clockwise inclination of the palatal plane by an angle of $0.6^\circ \pm 0.55^\circ$ was recorded in the BAPA group. This was confirmed by previous observations by Bussick and McNamara²¹ In the CPA group there was a small amount of decrease in the palatal plane. ($0.4^\circ \pm 0.42^\circ$).

The mandibular plane rotated clockwise in both BAPA and CPA group. The FMA increased by $2.4^\circ \pm 2.07^\circ$ in the BAPA group and $1.2^\circ \pm 2.17^\circ$ in the CPA group. The SnGoGn increased by $1.2^\circ \pm 0.84^\circ$ in the BAPA group and $1.8^\circ \pm 1.79^\circ$ in CPA group. Similar results were demonstrated by other studies with conventional pendulum.^{7,9} The clockwise mandibular rotation can be attributed to the maxillary molars moving distally into the wedge of occlusion and to the cusp interferences.¹¹

Studies on conventional pendulum have shown lip protrusion as a result of the incisor tipping.^{7,9} In this study, a small increase in value was seen from lower lip to esthetic line in the CPA group (1.6 ± 0.5 mm), which was found to be statistically significant ($p < 0.05$).

Dental cast measurements

The transverse changes measured on the dental casts showed a significant increase in the inter molar distance for BAPA group. There was also an increase seen in the CPA group but this value was not statistically significant ($p > 0.05$). There was a significant increase in the total arch perimeter in both groups ($p < 0.05$).

Significant distopalatal rotation of the maxillary first molars was seen in both groups. The CPA group showed more rotation ($4.2^\circ \pm 1.1^\circ$) as compared to the BAPA group ($2.6^\circ \pm 1.14^\circ$), but comparison of mean between the groups was not statistically significant. Distalizing coils act lingually at the center of resistance of the molars, and thus there is a tendency toward distopalatal rotation with a possibility towards molar crossbite.^{7,23} This explains the rotation of the molars as seen in our study.

Conclusions

The following conclusions can be drawn from the study:

- Both the BAPA and CPA are effective for the distalization of maxillary molars and the establishment of a Class I molar relationship.
- The distal molar movements obtained were similar between the BAPA and the CPA groups.
- Anchorage loss was observed with the CPA in the form of premolar mesialization and incisor proclination.

On the contrary, absence of anchorage loss, significant spontaneous distal premolar movement, and distal incisor movement was observed with the BAPA making it a viable choice compared to the CPA. To overcome the limitations associated with this study, future studies with larger sample size, both after treatment and in retention phase, are needed.

References

1. Haas AJ. Headgear therapy: the most efficient way to distalize molars. *SeminOrthod.* 2006; 6:79-90.
2. Hilgers JJ. The pendulum appliance for class II non-compliance therapy. *J ClinOrthod.* 1992; 26:700-713.
3. Joseph AA, Butchard CJ. An evaluation of the pendulum distalizing appliance. *SeminOrthod.* 2000; 6:129-135.
4. Gianelly AA. Distal movement of the maxillary molars. *Am J Orthod.* 1998; 114:66-72.
5. Gelgor IE, Buyukyilmaz T, Karaman AI. Use of the intraosseous screw for unilateral upper molar distalization and found well balanced occlusion. *Head and face medicine.* 2006; 2: 38-42.
6. Gelgor IE, Buyukyilmaz T, Karaman AI. Comparison of 2 distalization systems supported by intraosseous screws. *Am J Orthod DentofacialOrthop* 2007; 131: 161.e1-161.e8.
7. Kircelli BH, Zafer OP, Kircelli C. Maxillary molar distalization with a bone-anchored pendulum appliance. *Angle Orthod.* 2006; 76:650-9.
8. Angelieri F, Rodrigues de Almeida R, Rodrigues de Almeida M, Fuziy A. Dentoalveolar and skeletal changes associated with the pendulum appliance followed by fixed orthodontic treatment. *Am J OrthodDentofacialOrthop.* 2006; 129:520-7.
9. Onçag G, Seçkin O, Dinçer B, Arikan F. Osseointegrated implants with pendulum springs for maxillary molar distalization: a cephalometric study. *Am J OrthodDentofacialOrthop.* 2007; 131:16-26.
10. Kanomi R. Mini-implant for orthodontic anchorage. *J ClinOrthod.* 1999; 31:763-767.
11. Chiu PP, McNamara JA, Franchi I. A comparison of two intraoral molar distalization appliances: distal jet vs pendulum. *Am J OrthodDentofacialOrthop.* 2005; 128:353-65.
12. Fuziy A, Rodrigues de Almeida R, Janson G, Angelieri F, Pinzan A. Sagittal, vertical, and transverse changes consequent to maxillary molar distalization with the pendulum appliance. *Am J OrthodDentofacialOrthop.* 2006; 130:502-10.
13. Patel MP, Janson G, Henriques JF, de Almeida RR, de Freitas MR, Pinzan A, de Freitas KM. Comparative distalization effects of Jones jig and pendulum appliances. *Am J OrthodDentofacialOrthop.* 2009; 135:336-42.
14. Fudalej P, Antoszewska J. Are orthodontic distalizers reinforced with the temporary skeletal anchorage devices effective? *Am J OrthodDentofacialOrthop.* 2011; 139:722-9.
15. Costa A, Pasta G, Bergamaschi G. Intra oral hard and soft tissue depths for temporary anchorage devices. *SeminOrthod.* 2005; 11:10-15.
16. Roberts WE, Smith RK, Silberman Y, Mozsary PG, Smith RS. Osseous adaptation to continuous loading of rigid endosseous implants. *Am J Orthod* 1984; 86:95-111.
17. King KS, Lam EW, Faulkner MG, Hoe G, Major PW. Vertical bone volume in the paramedian palate of adolescents: A computed tomography study. *Am J OrthodDentofacialOrthop.* 2007; 132:7388.
18. Nalcaci R, Bicakci AA, Ozan F. Noncompliance screw supported maxillary molar distalization in a parallel manner. *Korean J Orthod.* 2010; 40: 250-259.
19. Ngantung V, Nanda RS, Bowman SJ. Post treatment evaluation of the distal jet appliance. *Am J OrthodDentofacialOrthop.* 2001; 120: 178-85.
20. Burkhardt DR, McNamara JA Jr, Bacetti T. Maxillary molar distalization or mandibular enhancement: a cephalometric comparison of comprehensive orthodontic treatment including the pendulum and herbst appliances. *Am J OrthodDentofacialOrthop.* 2003; 123: 108-16.
21. Bussick TJ, McNamara JA. Dentoalveolar and skeletal changes associated with the pendulum appliance. *American Journal of Orthodontics and DentofacialOrthopedics.* 2000 Mar 31;117(3):333-43.
22. Wong AMK, Rabie ABM, Hagg u. The use of pendulum in the treatment of Class II malocclusion. *Br Dent J.* 1999; 187: 367-70.
23. Patel MP, Janson G, Henriques JF, de Almeida RR, de Freitas MR, Pinzan A, de Freitas KM. Comparative distalization effects of Jones jig and pendulum appliances. *Am J OrthodDentofacialOrthop.* 2009; 135:336-42.