

Case Report

# Peripheral Ossifying Fibroma of the Posterior Maxilla : A Case Report

Mithula Nair S.<sup>1</sup>, Vidya Ajila<sup>2</sup>, Shruthi Hegde<sup>3</sup>, G. Subhas Babu<sup>4</sup> & Rumela Ghosh<sup>5</sup><sup>1,5</sup>Post Graduate Students, <sup>2,3</sup>Reader, <sup>4</sup>Professor and Head, Department of Oral Medicine and Radiology, A. B Shetty Memorial Institute of Dental Sciences, Nitte University, Mangalore.

\*Corresponding Author : Vidya Ajila, Reader, Department of Oral Medicine and Radiology, A. B Shetty Memorial Institute of Dental Sciences, Nitte University, Mangalore - 575 018. E-mail : ajila\_v@yahoo.com

Received : 07-07-2015

Review Completed : 16-03-2016

Accepted : 19-03-2016

Keywords : Peripheral ossifying fibroma, Gingiva, Maxilla

Abstract :

Peripheral ossifying fibroma (POF) is a reactive lesion usually arising from the interdental gingiva. The etiology is considered to be secondary to trauma or other local irritating factors. POF is almost always confused with pyogenic granuloma and peripheral giant cell granuloma. It usually shows a predominance of incidence in anterior region of maxilla and among females. Lesions are rarely larger than 2 cms in size. Incidence of peripheral ossifying fibroma in the posterior maxilla is also rare. Here we report a large peripheral ossifying fibroma occurring in a 40 year old man in the posterior maxillary region which had extended to the occlusal surface of the third molar region causing pain and erythema.

Access this article online

Quick Response Code



## Introduction

Peripheral ossifying fibroma (POF) is a pathologic condition seen in the oral cavity which occurs as an overgrowth of gingiva due to factors like trauma or irritation. This lesion is often mistaken for various other commonly occurring exophytic type of gingival lesions such as gingival hyperplasia of fibrous type or pyogenic granuloma.<sup>[1]</sup> Peripheral ossifying fibroma is known by various names in the literature such as peripheral cementifying fibroma, calcifying or ossifying fibroid epulis, and peripheral fibroma with calcification.<sup>[2]</sup> Because of their clinical and histologic similarities, some authors believe that these lesions develop initially as pyogenic granulomas which undergo fibrous maturation and calcification. Due to its name, it can be confused with central ossifying fibroma. However, they are separate entities and peripheral ossifying fibromas do not represent the soft tissue counterpart of central

ossifying fibroma.<sup>[3]</sup> Peripheral ossifying fibroma accounts for around 9.6 % of all gingival lesions and 3.1% of all oral tumours.<sup>[4]</sup>

## Case Report

A 40 years- old- male reported to the Department of Oral Medicine and Radiology with concern of a growth in the upper left back teeth region since two months. Patient gave history of pain in that area on brushing and chewing for which he visited a local dentist 15 days ago and medication was taken. Patient did not give any history of any spontaneous bleeding from the site.

Intraoral examination revealed a sessile growth extending from the buccal aspect of 26 to distal of 28 measuring approximately 4x3 cm. (Figure 1) Buccal vestibular obliteration was noted and the growth partially covered the occlusal surface of 28. The growth extended anteriorly

from the distal aspect of upper left first molar upto the distal aspect of upper left third molar. Superiorly it extended upto the sulcus and inferior extent of the lesion was 0.5 cm below the marginal gingiva. The surface mucosa was erythematous. (Figure 2) On palpation, growth was non tender and firm in consistency. The associated maxillary molar teeth were not mobile. The second molar was palatally displaced. Left submandibular lymph node was palpable, mobile and non-tender.

Radiographic examination revealed a well-defined soft tissue radiopacity in the upper left molar region measuring approximately 4x3 cm in diameter. The underlying bone was relatively radiolucent with an altered trabecular pattern. (Figure 3) The radiopacity extended superiorly from the left maxillary sinus and inferiorly upto the alveolar crest. Mesially, it extended from the distal root of upper left first molar upto the distal root of the upper left third molar. Panoramic radiograph also revealed mesial displacement of the roots of the maxillary left second molar and interdental bone loss extending to the middle third of the roots of maxillary left second and third molars. Missing mandibular left first molar was noted. (Figure 3) Waters View showed similar features. (Figure 4) Incisional biopsy of the lesion was suggestive of peripheral ossifying fibroma. Surgical excision of the lesion was done. Due to loss of periodontal support, the maxillary left second and third molars were extracted at the same time. Histopathological examination revealed stratified squamous parakeratinised type of epithelium of variable thickness. In some areas, the epithelium was ulcerated and showed numerous fragmented neutrophils. Connective tissue showed foci of ossification of varying size surrounded by numerous plump and active spindle shaped fibroblasts. Chronic inflammatory cell infiltrate was mainly composed of lymphocytes and plasma cells along with few giant cells. Vascular spaces with extravasated RBC's were also seen. (Figure 5) A final histopathological diagnosis of peripheral ossifying fibroma was given.

#### Discussion

Eversole and Rovin<sup>[5]</sup> first coined the term Peripheral

ossifying fibroma. It is a relatively uncommon, solitary, non-neoplastic gingival growth.<sup>[5]</sup> Earlier, it was believed that POF is a transitional form of pyogenic granuloma, peripheral giant cell granuloma, or irritation fibroma. However, recent reports suggest that the POF is totally a separate clinical entity.<sup>[6]</sup> Gardner<sup>[7]</sup> stated that connective tissue in POF has got unique features that enable a confirmed histopathologic diagnosis, regardless of whether there is presence or absence of calcifications.

The most accepted etiology for occurrence of POF is the inflammatory hyperplasia of cells of periodontal ligament. The inflammatory reaction is said to occur due to trauma or other local irritants such as plaque, calculus, restorations or ill fitting dental appliances.<sup>[8,9]</sup> This theory is supported by the fact that POF occurs exclusively in gingiva and by the presence of oxytalan fibres within the mineralized matrix.<sup>[6,8]</sup>

The highest incidence of peripheral ossifying fibroma is during second and third decades of life and females account for almost two-third of the cases reported.<sup>[9]</sup> The site predilection is higher for the maxillary arch, occurring frequently in the incisor cuspid region.<sup>[9]</sup> In our case, the lesion occurred in a 40-year-old male in the maxillary molar region.

Peripheral ossifying fibroma clinically appears either as a pedunculated or sessile mass, nodular in appearance, arising from the interdental gingiva. The colour can range from pink to red. Ulcerations may be present but are not frequent.<sup>[6]</sup> Most of these lesions range from 1 to 2 cm in size, but there are few reports of cases more than 2 cms.<sup>[8]</sup> In our case, the lesion was 3X2cms in size. Due to its large size and extension to the occlusal surface of the third molar region pain and erythema was noted in our patient. The teeth involved are usually unaffected but may show migration, mobility and delay in eruption of permanent teeth.<sup>[8]</sup> Tooth migration was seen in our case. Peripheral ossifying fibromas are usually solitary. Syndromes associated with multicentric POF are nevoid basal cell carcinoma syndrome, Multiple endocrine neoplasia type II, neurofibromatosis and Gardner's syndrome.<sup>[8]</sup>

The radiographic features may range from mild or no changes to destructive changes. In certain cases the lesion could cause superficial erosion of underlying bone, cupping defect and focal calcifications at centre of lesion.<sup>[2]</sup>  
<sup>8]</sup> No calcifications were evident radiographically in our case; however; radiolucency of the underlying bone was noted.

The common lesions considered in the differential diagnosis include pyogenic granuloma, peripheral giant cell granuloma. In our case because of the appearance of a well-defined radiopacity overlying the maxillary sinus a differential diagnosis of central ossifying fibroma and osteoma was also considered. Diagnosis was confirmed by histopathological evaluation.

The histopathological examination usually shows features such as benign fibrous connective tissue with varying fibroblast, myofibroblast and collagen content, sparse to profuse endothelial proliferation and mineralized material that may represent mature lamellar or woven bone or dystrophic calcifications. Occasionally inflammatory cell infiltration can also be seen.<sup>[9]</sup> The histopathological picture was similar to the above in our case.

The most preferred choice of treatment for peripheral ossifying fibroma is surgical excision.<sup>[3, 10]</sup> The complete excision of the lesion from anterior maxillary region can result in visible gingival defects and appropriate efforts for repairing the same should be carried out. Various techniques like full thickness or partial thickness lateral sliding flap, coronally positioned flap, subepithelial connective tissue graft etc can be used to manage and minimize defects and give an esthetic result.<sup>[10]</sup> In our case,

Figure 1 : Clinical photograph of the lesion.

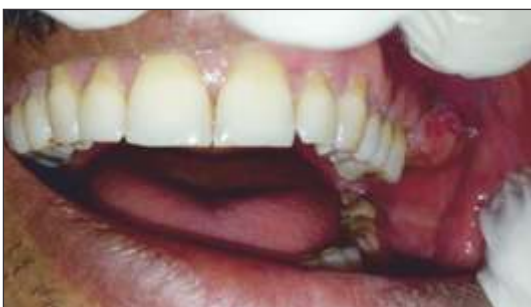

Figure2 : Clinical image of the lesion showing the extension till the occlusal surface of 26 & 27.

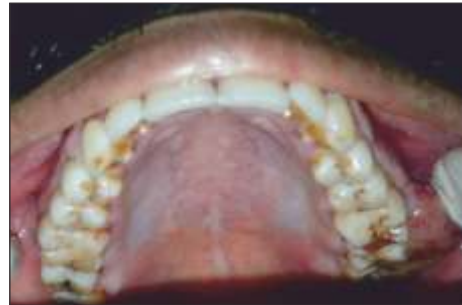

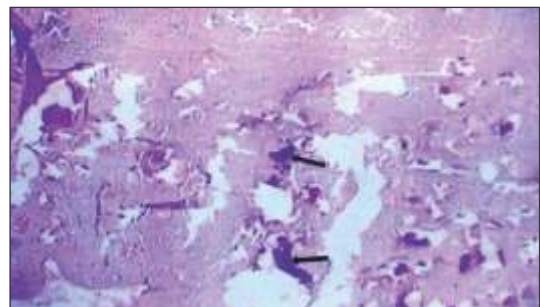
Figure 3 : Panoramic radiograph showing a well-defined radiopaque shadow over the left maxillary posterior region. (White arrows).

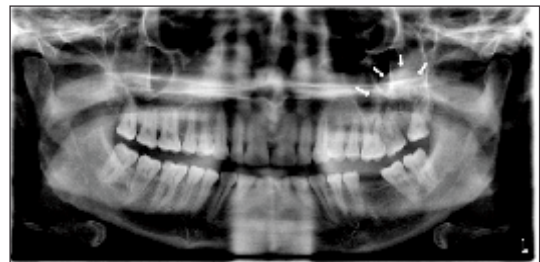

Figure 4 : Waters view showing radiopacity in left posterior maxillary region.

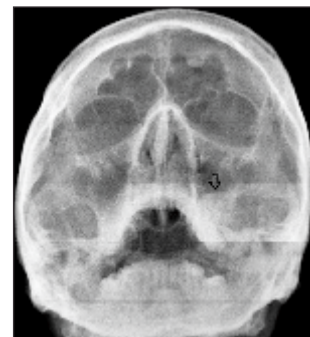

Figure5 : Photomicrograph (10X) showing surface epithelium and underlying connective tissue with ossifications (Black arrows).



surgical excision along with extraction of the involved teeth was done. The recurrence rate of this lesion is very high varying from 7 % to 45%. The high rate of recurrence could

be due to variations in surgical management such as incomplete excision or persistence of local factors.<sup>[2]</sup> Recurrences can be treated with surgical excision.

[10]

### Conclusion

In the present case report the clinical, radiographic and histopathologic features of POFs discussed. Large POF occurring in the posterior maxilla may have varied

radiographic presentations which may lead to wrong diagnosis and management. Confirmatory diagnosis requires histopathologic examination. This report adds to the existing literature about the presentation of POF such as pain and erythema along with appearance of radiopacity in the posterior maxilla, which in turn helps the clinicians for proper diagnosis and treatment.

### References

1. Trasad VA, Devarsa GM, Subba Reddy VV, Shashikiran ND. Peripheral ossifying fibroma in the maxillary arch. *J Indian SocPedodPrev Dent.* 2011; 29:255-9.
2. Bhasin M, Bhasin V, Bhasin A. Peripheral ossifying fibroma Case Rep Dent. 2013; 2013: 497234.
3. Neville BW, Damm DD, Allen CM, and Bouquot JE. Soft tissue tumours in: *Oral and Maxillofacial Pathology*, 2nd ed 2002 Saunders, Philadelphia, pp 451-2.
4. Mishra AK, Bhusari P, Kanteshwari K. Peripheral cemento-ossifying fibroma - A case report. *Int J Dent Hygiene* 2011; 9: 234-7.
5. Eversole LR, Rovin S. Reactive lesions of the gingiva. *J Oral Pathol.* 1972; 1: 30-8.
6. Farquhar T, Maclellan J, Dymont H, Anderson RD. Peripheral Ossifying Fibroma: A case report. *J Can Dent Assoc* 2008; 7:809-12.
7. Gardner DG. The peripheral odontogenic fibroma: an attempt at clarification. *Oral Surg Oral Med Oral Pathol* 1982; 54:40-8.
8. Sudhakar S, Praveen Kumar B, Prabhat MPV. Peripheral Ossifying Fibroma. *Online J Health Allied Scs.* 2009; 8:17.
9. Pal S, Hegde S, Ajila V. The varying clinical presentations of peripheral ossifying fibroma: A report of three cases. *Rev OdontoCienc* 2012; 27: 251-55.
10. Agarwal P, Agarwal M, Bhattacharya H, Saluja M. Peripheral ossifying fibroma. *Journal of Dental Sciences & Oral Rehabilitation* 2012; 51-2.