Article published online: 2020-04-22

NUJHS Vol. 6, No.1, March 2016, ISSN 2249-7110

Nitte University Journal of Health Science

Case Report

Aniridia : A window to wilm's tumour

Samyakta Shetti[1] & Harshavardhan Patil[2]

[1]Postgraduate,[2]Assistant Professor, Department of Ophthalmology, KLE University, JNMC, KLES Dr. Prabhakar Kore Hospital & MRC, Belgaum - 590 001, Karnataka, India.

Correspondence
Samyakta Shetti
Post Graduate, Department of Ophthalmology, KLE University, JNMC, KLES Dr. Prabhakar Kore Hospital & MRC, Belgaum - 590 001, Karnataka, India.
Mobile : +91 99725 35632 E-mail : samyaktashetti@yahoo.com

Abstract

We are reporting a case with aniridia which lead to the diagnosis of Wilm's tumour in a twelve month male child.

Keywords : aniridia,Wilm's tumour,vitA deficiency.

Introduction

Aniridia in majority of the cases occurs isolated without any systemic involvement due to dominantly inherited mutations or deletions of the paired box gene-6 (*PAX6*) where as in minority of cases it occurs as part of the WAGR (Wilms tumor-aniridia-genital anomalies-retardation) syndrome caused by deletion of 11p13, which includes the Wilms' tumor (*WT1*) and aniridia gene (*PAX6*) loci[1]. The major diagnostic feature is congenital partial or complete hypoplasia of the iris; foveal hypoplasia with reduced visual acuity and early onset nystagmus. Other associated ocular abnormalities include cataract, glaucoma and corneal opacification and vascularization.[2]Our case was diagnosed with aniridia leading to diagnosis of Wilm's tumour along with vitamin A deficiency.

Case Report

Twelve months oldmale child presented to us with history of photophobia and whitish lesion in right eye. On ophthalmological examination visual acuity was 20/30 at 38cms with Teller's acuity chart. Conjunctiva of right eye showed bitot's spot temporally and left eye showed conjunctival xerosis. Aniridia in both eyes with clear lens (Figure1) .Bilateral fundus was normal. There was no family history of aniridia or renal tumors. No delay in language and gross-motor development.

Access this article online
Quick Response Code

Subsequently child was referred to nephrologist and was diagnosed with Wilm's tumour .He underwent partial nephrectomy surgery and is on regular cycle of chemotherapy (adrimycin). Child was started immediately on vitamin A 1,00,000 IU I.M,subsequent next day and 4weeks.Follow up after one month showed resolution of bitot's spot and conjunctival xerosis.

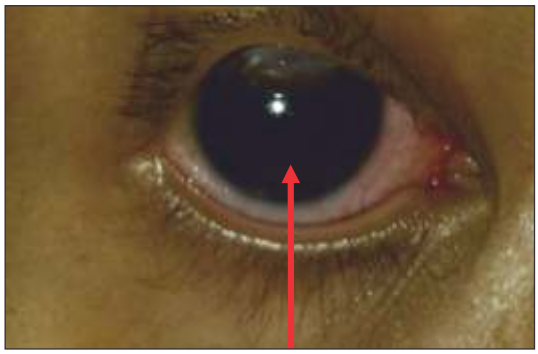

Fig 1: Shows the right eye with aniridia.

Discussion

Aniridia is seen in approximately 1.8/100 000 live births.[3] The incidence ranges from 1:40000 to 1:100000. No significant racial or gender predilection has been described.[4] The frequency of Wilms' tumour-in the general population is one in 10,000 to 50,000 individuals. Fraumeni and Glassfound seven Wilms' tumour patients among 28 cases of aniridia which indicates that Wilms' tumour is more frequent in patients with aniridia than in general population.[5] WAGR syndrome, characterized by the clinical association of Wilms' tumors with aniridia, ambiguous genitalia, genitourinary anomalies, and mental

retardation, which was first described by Miller et al.[6]The underlying defect of Aniridia-Wilms' tumour was found to be a small interstitial deletion of chromosome band 11 p 13 . In patients with WAGR syndrome, the risk for developing a Wilms' tumor has been estimated to be up to 45%.[7] When associated with aniridia, a Wilms' tumor is diagnosed before age 5 years in 80% of cases.[8] In a study of 28 patients with non-familial bilateral aniridia Wilms' tumour syndrome, mental retardation along with microcephaly and craniofacial dysmorphism was observed in 71%, and cataract and glaucoma in 78% of cases .[9] optic nerve hypoplasia resulting from inactivation of the aniridia gene Pax6, which lies telomeric of *WT1* on chromosome 11p13.[10] In our case aniridia with wilm's tumour was associated with ocular signs of vitamin A deficiency such as bitot's spot and conjunctival xerosis.

Therefore, renal ultrasound is recommended every 3-6 months until approximately 5 years of age .[5] Boys are often born with genital abnormalities, such as cryptorchidism or hypospadias, but more rarely ambiguous genitalia. However, genitourinary anomalies are not always present as in our case where no genital malformation was seen. Mental retardation in WAGR ranges from borderline-to-severe. However, individuals with normal intelligence have been reported [11]which was similarly seen our case.All the patients presenting with aniridia must be screened for wilm'stumour.

References

1. Scott DA, Cooper ML, Stankiewicz P, Patel A, Potocki L, Cheung SW. Congenital diaphragmatic hernia in WAGR syndrome. Am J Med Genet 2005;134:430–433
2. Melanie Hingorani, Anthony Moore, Aniridia, Includes: Isolated Aniridia, Wilms Tumor-Aniridia-Genital Anomalies-Retardation (WAGR) Syndrome, Bookshelf ID: NBK1360, 2008;
3. Berlin HS, Ritch R. The treatment of glaucoma secondary to aniridia. Mt Sinai J Med. 1981;48:11;
4. Nelson LB, Spaeth GL, Nowinski TS, Margo CE, Jackson L. Aniridia. A review. SurvOphthalmol. 1984;28:621–642.
5. Framumeni JF, Glass AG. Wilms' tumour and congenital aniridia. JAMA, 1968, 206, 825-828.
6. Miller RW, Fraumeni JF, Manning MD. Association of Wilms' tumor with aniridia, hemihypertrophy and other congenital malformations. N Engl J Med 1964;270:922–927.
7. RICCARDI VM, SUJANSKY E, SMITH AC, FRANCKE U: Chromosomal imbalance in the aniridia-Wilms' tumor association: lip interstitial deletion. Pediatrics 61:604-610, 1978
8. Pinna A, Carta A, Mannazzu MC, Dore S, Balata A, Carta F. WAGR syndrome with deletion of chromosome 11p11.2-13. J AAPOS 2004;8:396–397.
9. Fischbach BV, Trout KL, Lewis J, Luis CA, Sika M. WAGR syndrome: a clinical review of 54 cases. Pediatrics 2005;116:984–988.
10. Wagner KD, Wagner N, Vidal VP, Schley G, Wilhelm D, Schedl A, Englert C, Scholz H: The Wilms' tumor gene WT1 is required for normal development of the retina. *EMBO J* 21: 1398–1405, 2002
11. Huff V. Parental origin of WT1 mutations and mental retardation in WAGR syndrome. Nat Genet 1994;8:13