Article published online: 2020-04-02

Cervical Myelopathy Secondary to Gout: Case Report*

Mielopatia cervical secundária a gota: Relato de caso

Thiago Dantas Matos[1] Kelsen de Oliveira Teixeira[1] Rodrigo Barra Caiado Fleury[1]
Herton Rodrigo Tavares Costa[1] Joel Del Bel Pádua[2] Helton Luiz Aparecido Defino[1]

[1] Department of Orthopedics and Traumatology, Faculdade de Medicina de Ribeirão Preto da Universidade de São Paulo, Ribeirão Preto, SP, Brazil
[2] Department of Pathology, Faculdade de Medicina de Ribeirão Preto da Universidade de São Paulo, Ribeirão Preto, SP, Brazil

Rev Bras Ortop 2020;55(6):796–799.

Address for correspondence Thiago Dantas Matos, MD, Departamento de Ortopedia e Traumatologia, Universidade de São Paulo, Faculdade de Medicina de Ribeirão Preto, Avenida Bandeirantes, 3900, Monte Alegre, Ribeirao Preto, SP, 14049900, Brazil (e-mail: tdmatos@usp.br).

Abstract

Gout is a crystalline arthropathy frequent in the population, but gouty spondyloarthropathy, also called axial gout, is uncommon. The current case report presents a rare case of cervical myelopathy secondary to axial gout. A 50-year-old female patient, without previous pathologies, presented with loss of strength, altered sensitivity, and pyramidal release for 2 years. The computed tomography showed a lytic image in the spinous process of C7, and signs of myelopathy with myelomalacia on magnetic resonance imaging of the cervical spine. After the surgical procedure and biopsy of the material, the diagnosis was gout, and treatment for the pathology was started, with complete improvement of the condition. The diagnosis of axial gout should be included in the spectrum of the differential diagnosis of diseases that affect the spine. Although gouty spondyloarthritis (or spondylitis) is uncommon, there is an underestimated occurrence due to the lack of investigation of the cases. The early diagnosis and treatment of the pathology can prevent patients from presenting complications of the disease, as reported in the present study.

Keywords
- gout
- spinal cord compression
- paraparesis

Resumo

A gota é uma artropatia cristalina frequente na população; entretanto, a espondiloartropatia gotosa, também chamada de gota axial, é incomum. O presente relato de caso apresenta um caso raro de mielopatia cervical secundária a gota axial. Uma paciente de 50 anos de idade, sem patologias prévias, apresentou quadro de perda de força, alteração de sensibilidade e liberação piramidal há 2 anos. A tomografia computadorizada evidenciou imagem lítica no processo espinhoso de C7, e sinais de mielopatia com mielomalácia foram observados na ressonância magnética da coluna cervical. Após o procedimento cirúrgico e biópsia do material, o diagnóstico foi de gota, e o tratamento para a patologia foi iniciado, com melhora completa do quadro. O diagnóstico de gota axial deve ser incluído no espectro do diagnóstico diferencial das doenças que acometem a coluna vertebral. Apesar de a espondiloartrite gotosa ser incomum, há uma ocorrência subestimada devido a não investigação dos casos. O diagnóstico precoce e tratamento da patologia pode evitar que pacientes apresentem complicações da doença, como a relatada no presente estudo.

Palavras-chave
- gota
- compressão da medula espinal
- paraparesia

* Work developed at the Department of Orthopedics and Traumatology of Faculdade de Medicina de Ribeirão Preto, Universidade de São Paulo, Ribeirão Preto, SP, Brazil.

received
August 27, 2019
accepted
December 12, 2019

DOI https://doi.org/10.1055/s-0040-1708514.
ISSN 0102-3616.

Copyright © 2020 by Sociedade Brasileira de Ortopedia e Traumatologia. Published by Thieme Revinter Publicações Ltda, Rio de Janeiro, Brazil

License terms

Introduction

Gout is the most frequent crystalline arthropathy, with an overall prevalence of 0.08%, and it primarily affects males after the fifth decade of life. However, gouty spondyloarthropathy (GS) is uncommon and mimics a variety of diseases that affect the spine, representing a challenge for its diagnosis in clinical practice.[1–3]

Gouty spondyloarthropathy, also called axial gout or spinal gout, was described in 1950 by Kersley et al.,[4] and Kosoff et al. (1953) were the pioneers in reporting gout myelopathy.[5] Axial gout is an uncommon manifestation of this disease, with a broad spectrum of clinical manifestation of the disease, ranging from asymptomatic to severe compression of nervous structures, with paraplegia or tetraparesis.[1] The objective of the present clinical case report is to present the involvement of the spine in gout accompanied by information about this unusual manifestation of the disease, which should be considered in the differential diagnosis.

The study was approved by the institutional research ethics committee under the number CAAE 19635119.8.0000.5440.

Case Report

A 50-year-old female patient was admitted complaining of cervical pain radiating to the upper limbs, and paresthesia in the C6 and C7 dermatome. She reported frequent falls and difficulty in walking for 2 years. Physical examination revealed bilateral weakness of the upper limbs with grade four muscle strength, according to the Medical Research Council (MRC) scale, and with greater involvement of the C6 and C7 myotomes. Hoffmann e Babinski signs were positive on both sides.

The laboratory exams of the preoperative routine showed no changes and no diagnostic hypothesis could be elaborated to clarify the lytic lesions of the posterior elements of C7 (►**Figure 1**). The magnetic resonance exam of the cervical spine showed spinal canal stenosis, mainly in the C6 to C7 levels (►**Figure 2**).

The posterior approach of the cervical spine was performed to allow the stabilization and posterior decompression of the cervical spine, and to allow access to the posterior elements of C7 to obtain the material for the anatomopathological examination. The C4 to T1 arthrodesis and posterior fixation were performed, associated with C5to C7 laminectomy. The spinous process and the C7 arch, which presented the lytic lesion, were referred for anatomopathological examination for diagnostic investigation (►**Figure 3**).

In the postoperative period, the patient showed significant improvement in the cervical pain and neurological symptoms, with good evolution of the surgical wound, without general or specific complications related to the surgical procedure performed.

On macroscopic examination, the C7 lesion was composed of brownish and soft tissue, and the histological sections stained by hematoxylin and eosin (HE) showed that the bone tissue did not present histological changes. Furthermore, we observed an adjacent portion of synovial tissue with villous hyperplasia, mild lymphocytic inflammatory infiltrate, and

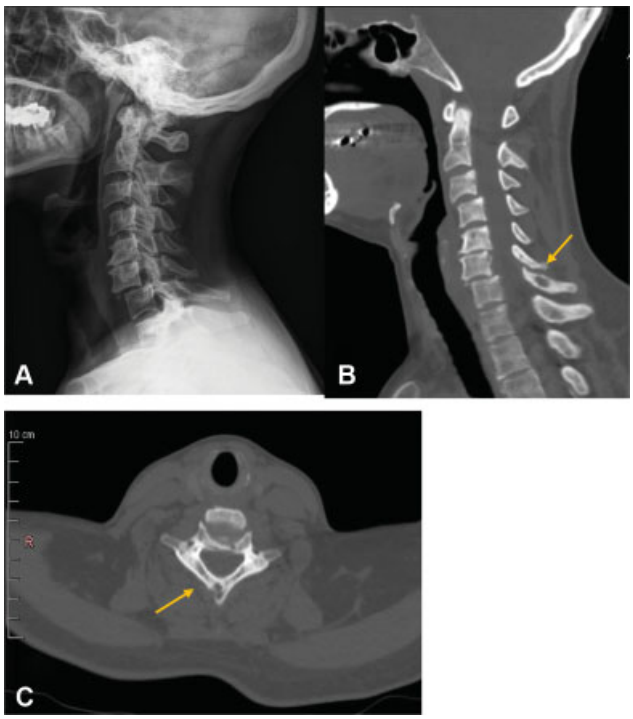

Fig. 1 (A) Profile radiograph of the cervical spine showing degenerative changes in the vertebral segments and anterior displacement of C6. (B) Computed tomography showing lytic lesion of the C7 spinous process in the sagittal section (yellow arrow). (C) Axial section of the computed tomography showing multiple lytic lesions in the posterior elements of C7. (yellow arrow).

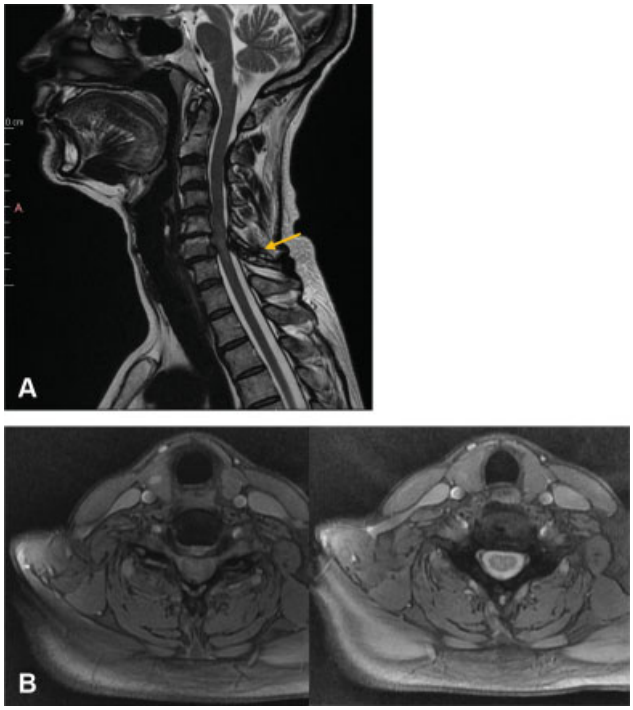

Fig. 2 (A) Magnetic resonance imaging showing C6/C7 cervical stenosis, lytic lesions with an area of inflammatory tissue in the spinous process, and C7 lamina. (B) Axial T2-weighted magnetic resonance imaging showing spinal cord stenosis.

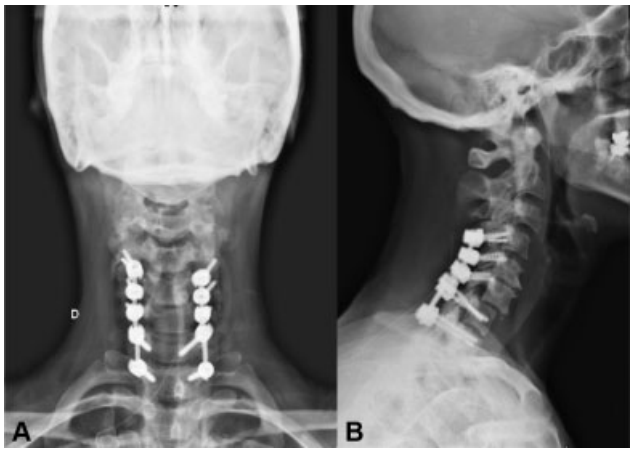

Fig. 3 Postoperative radiographs, (A) Anteroposterior, (B) Profile.

urate deposits surrounded by histiocytes and giant foreign body cells, compatible with the diagnosis of gouty synovitis (►**Figure 4**).

After the result of the anatomopathological exam indicating the diagnosis of gout, complementary exams specific for this disease were performed, and the treatment started with the administration of Allopurinol, 300 mg/day, associated with the appropriate diet. The patient had a good evolution of the pain symptoms related to gout, and the evolution of the results of the tests performed during the follow-up showed a decrease in the values of serum uric acid (►**Table 1**).

Table 1 Laboratory test values during outpatient follow-up

	1st collection	2nd collection	3rd collection	4th collection
Serum uric acid	15.5 mg/dL	8.2 mg/dL	9.7 mg/dL	3.2 mg/dL
Urea		35.7 mg/dL	35.8 mg/dL	31.4 mg/dL
Creatinine	1.0 mg/dL	1.1 mg/dL	1.2 mg/dL	1.0 mg/dL
GTO			23 U/L	23 U/L
GPT			18 U/L	19 U/L

Abbreviations: GTO, glutamic-oxaloacetic transaminase; GPT, glutamic-pyruvic transaminase.

Discussion

Axial gout is an unusual manifestation of gouty arthritis, but clinical case reports exceed the 100, indicating that its occurrence may be underestimated.[1] The diagnosis of axial gout of the patient we are reporting was due to the neurological symptoms she had and to the anatomopathological examination, as there was no clinical evidence of the disease. Axial gout may be more frequent than we consider, and only patients with symptoms have been considered in case reports.[1,6,7] Ninety-eight percent of the patients analyzed in an axial gout review article had neurological symptoms,[1] and the prospective radiological study of patients with gout, showed erosive lesions in the spine in asymptomatic patients.[8]

Male patients with an average age around 60 years have been the most affected by axial gout,[1] contrasting with the patient we report. However, the patient had an increase in uric acid, which is reported in about 69.6% of patients with gout.[1]

All segments of the spine have been affected by axial gout, with the lumbar spine being the most frequent (58.4%). The cervical location, which was observed in our patient, corresponds to the second segment in frequency and is reported in 24.8% of patients. Any spinal structure can be affected, as well as adjacent tissues.[1]

The neurological symptoms observed in this patient agree with most reports, in which 77.9% of the patients had neurological symptoms that were associated with pain in the affected segment of the spine. Radiculopathy is the most frequent symptom, reported in 34.5% of patients, followed by neurogenic claudication (20.4%).[1]

Radiological findings are compatible with changes in osteoarthritis.[9] Although unclear, the mechanisms associated with axial gout have been considered similar to what occurs in the peripheral condition, in which pH, temperature, trauma, and degeneration of the joints are involved in the deposition of

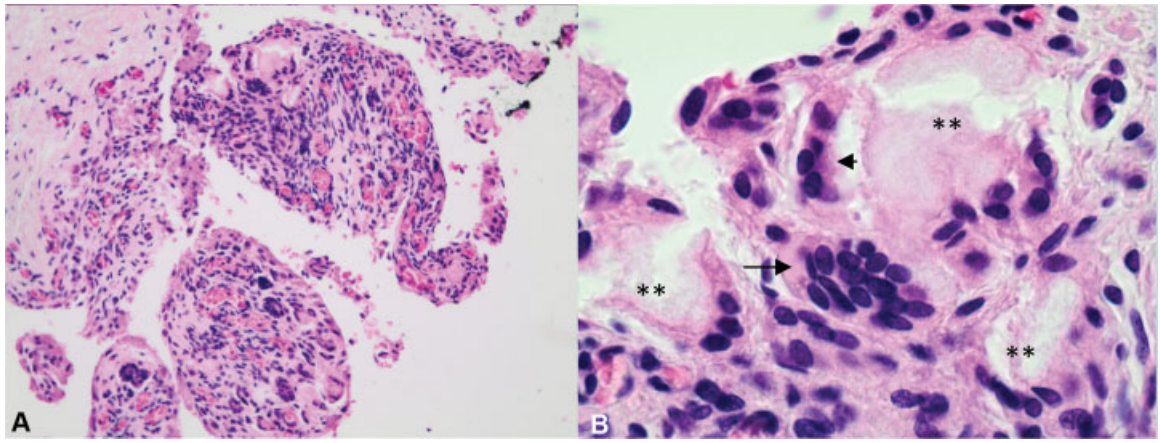

Fig. 4 Histological section stained with hematoxylin and eosin showing hyperplastic synovial tissue with lymphohistiocytic inflammatory infiltrate (A). In greater magnification (B), small deposits of amorphous material can be seen (**), indicative of the presence of urate (the crystals are dissolved in the process of fixation and coloring), surrounded by epithelioid macrophages (short arrow) and multinucleated giant cells (long arrow).

crystals.[9] Radiological changes can vary from soft-tissue edema to bone-tissue erosion.[9] The lytic lesion observed in our patient, with the characteristics of the computed tomography and magnetic resonance images, are typical in this patients with gout but do not allow the diagnosis to be made. These lesions allow only the presumption of the diagnosis, which can be confirmed only with the histopathological examination, as occurred with our patient. Histopathological examination is essential for the definitive diagnosis and exclusion of other diseases that may present a similar image.[1] The collection of material for histopathological examination can be done through puncture or by direct excision during treatment in patients who have neurological deficits and need surgical treatment. However, a thorough clinical, laboratory and radiographic evaluation must precede this step.

The histological characteristic of gout is the deposits of sodium urate surrounded by a variable granulomatous reaction of foreign body type. Urate crystals, which are brown in color, are visible in tissues fixed in alcohol. Fixing in formalin combined with the use of routine aqueous dyes, however, dissolves the crystals, leaving only a typical amorphous protein matrix, grayish with discrete eosinophilic streaks.[10]

Vertebral involvement can be the initial manifestation of gout, and it should be included in the differential diagnosis, especially in patients who have lytic bone lesions with the characteristics previously described.

The clinical case we reported did not have a previous history of gout, and the disease was diagnosed by histopathological examination, resulting from the treatment performed to improve the neurological deficit, because the patient had no symptoms or previous diagnosis of gout.

The diagnosis of gout should be included in the spectrum of the differential diagnosis of diseases that affect the spine, and the treatment of the disease must be carried out together with the treatment of the disease of the spine to avoid the problems caused by gout.[1,4,6,9]

Conflict of Interests
The authors have no conflict of interests to declare.

References

1 Hasegawa EM, de Mello FM, Goldenstein-Schainberg C, Fuller R. Gout in the spine. Rev Bras Reumatol 2013;53(03):296–302
2 Toprover M, Krasnokutsky S, Pillinger MH. Gout in the Spine: Imaging, Diagnosis, and Outcomes. Curr Rheumatol Rep 2015;17 (12):70
3 Fernandes ED, Bergamaschi SB, Rodrigues TC, et al. Aspectos relevantes do diagnóstico e seguimento por imagem na gota. Rev Bras Reumatol 2017;57(01):64–72
4 Kersley GD, Mandel L, Jeffrey MR. Gout; an unusual case with softening and subluxation of the first cervical vertebra and splenomegaly. Ann Rheum Dis 1950;9(04):282–304
5 Koskoff YD, Morris LE, Lubic LG. Paraplegia as a complication of gout. J Am Med Assoc 1953;152(01):37–38
6 Ng W, Sin CH, Wong CH, Chiu WF, Chung OM. Unusual Presentation of Spinal Gout: 2 Cases Report and Literature Review. J Orthop Case Rep 2017;7(06):50–54
7 Volkov A, Rhoiney DL, Claybrooks R. Tophaceous Gout of the Lumbar Spine: Case Report and Review of the Literature. Turk Neurosurg 2015;25(06):954–958
8 Andrés M, Vela P, Volar LC, Avilés Y, Pascual E. Back pain due to lumbar gouty flare–a prospective diagnosis. J Rheumatol 2013;40 (08):1459–1460
9 King JC, Nicholas C. Gouty arthropathy of the lumbar spine: a case report and review of the literature. Spine 1997;22(19): 2309–2312
10 Shidham VM, Galindo L, Gupta D, Jhala N, Shidham G. Urate crystals in tissue: A novel staining method for formalin-fixed, paraffin-embedded sections. Lab Med 1998;29:109–113