

A Rare Case of Primary Malignant Melanoma Presenting with Lower Extremity Weakness

Ehsan Alimohammadi^{1,✉} Guive Sharifi^{2,✉}

¹Department of Neurosurgery, Kermanshah University of Medical Sciences, Imam Reza Hospital, Kermanshah, Iran

²Department of Neurosurgery, Shahid Beheshti University of Medical Sciences, Loghman Hakim Hospital, Tehran, Iran

Address for correspondence Ehsan Alimohammadi, MD, Kermanshah University of Medical Sciences, Imam Reza Hospital, Kermanshah, Iran (e-mail: hafez125@gmail.com).

Indian J Neurosurg:2020;9:208–212

Abstract

keywords

- ▶ intramedullary tumor
- ▶ melanoma
- ▶ retroperitoneum

The authors report a pathologically confirmed case of primary malignant melanoma located in the intradural lumbosacral area, which is extremely rare due to its atypical location and manifestation. However rare, primary malignant melanoma could present as an intradural tumor and cause neurological deficit.

Introduction

Primary malignant melanomas of the central nervous system (CNS) are extremely rare and account for about one percent of all melanomas.¹

Intradural primary malignant melanoma in lumbosacral area is a very rare entity and the exact incidence is still unclear. We report a case of primary malignant intradural melanoma in the lumbosacral area which extended into the retroperitoneal space through the L5 and S1 foramina.

Case Presentation

A 47-year-old woman was admitted to our hospital with a complaint of progressive worsening of severe back pain from approximately 4 weeks ago and weakness in the right lower extremity from a week ago. No remarkable finding was noted in her past medical history. A neurological examination revealed moderate paresis and numbness on the right lower extremity. Motor strength of proximal and distal muscles of the right lower extremity was assessed to be 3/5, whereas the left lower extremity had 5/5 strength. Magnetic resonance imaging (MRI) of the lumbosacral spine showed an intradural mass in the level of L5 and S1 vertebrae which extended into the retroperitoneal space through the right L5 and S1 foramina. The lesion was iso- to hypointense on T2 and slightly hypointense on T1-weighted images. Diffuse contrast

enhancement was also prominent on T1-weighted images after gadolinium (GD) injection (▶ Fig. 1–3). The lumbosacral computed tomography (CT) scan showed an isodense lesion at the same levels that enlarged the foramina and eroded the bone (▶ Fig. 4).

During the operation, laminectomies were performed from L5 to S1 levels. The first interesting thing, which was seen was the severe enlargement of L5 and S1 nerve roots. A dark black vascular tumor was observed immediately after dural incision (▶ Fig. 5,6). This pigmented tumor showed clear invasion of L5 and S1 roots under the operative microscope. The tumor was dissected from the rootlets and it was excised grossly as much as safely possible. The tumor extended into the retroperitoneal space through the enlarged L5 and S1 roots. The postoperative course was eventful. She had recovery in motor strength in the early postoperative period.

Histopathological sections demonstrated a highly cellular lesion composed of clusters of atypical cells (▶ Fig. 7). The cells had pleomorphic nuclei with irregular borders and prominent nucleoli. Some of the nuclei contained vacuoles. There was some mitosis and abundant intra- and extracellular pigments. Immunohistochemical staining revealed positive immunoreactivity for S100 protein and human melanoma black-45.

After confirmation of the diagnosis, the patient underwent a thorough systemic examination and survey. Any other foci of melanoma, including skin and orbit, could not be found

DOI <https://doi.org/10.1055/s-0040-1708081>
ISSN 2277-954X.

© 2020. Neurological Surgeons' Society of India.

This is an open access article published by Thieme under the terms of the Creative Commons Attribution-NonDerivative-NonCommercial-License, permitting copying and reproduction so long as the original work is given appropriate credit. Contents may not be used for commercial purposes, or adapted, remixed, transformed or built upon. (<https://creativecommons.org/licenses/by-nc-nd/4.0/>)

Thieme Medical and Scientific Publishers Pvt. Ltd., A-12, 2nd Floor, Sector 2, Noida-201301 UP, India

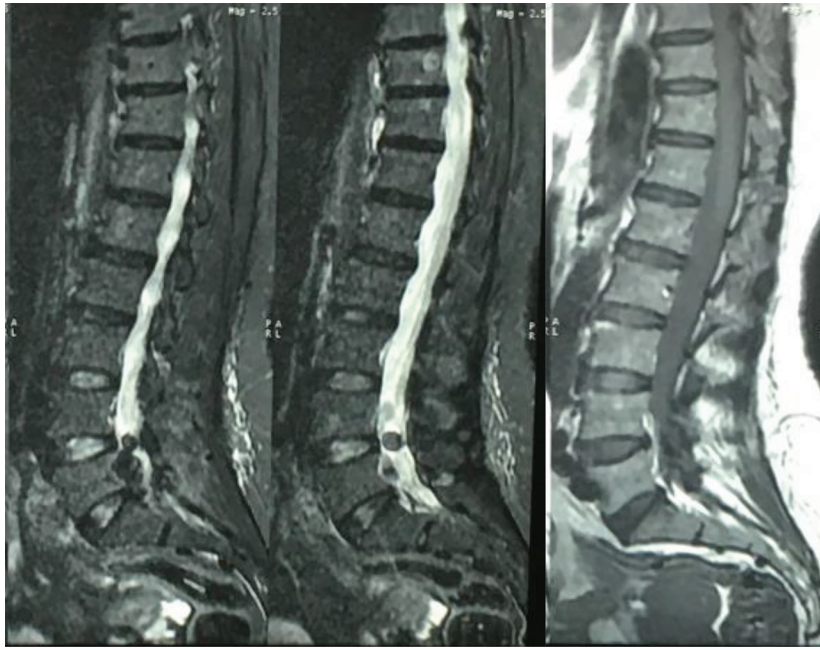


Fig. 1 Sagittal MRI view of the lumbosacral area. The tumor is hypointense in T1 and T2 images. MRI, magnetic resonance imaging.

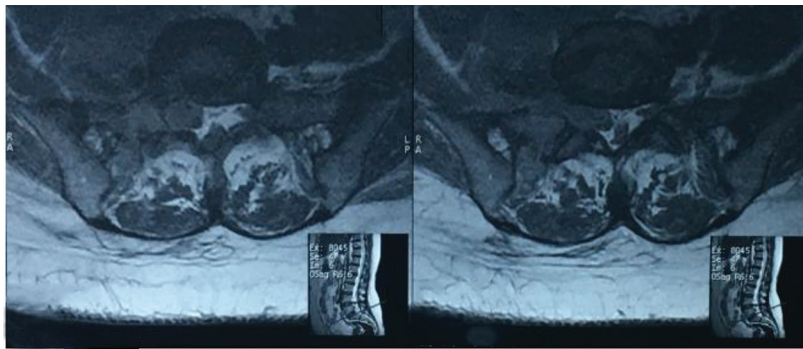


Fig. 2 Axial MRI view at L5 and S1 level. The tumor expanded the right S1 foramina and extended into the retroperitoneal space. MRI, magnetic resonance imaging.

and primary malignant melanoma was confirmed. Palliative chemotherapy was begun by the oncology service, and she died 6 months later.

Discussion

Skin is the most common origin for melanoma, but other places such as gastrointestinal system and orbit were also reported.² About 10% of all cases arise from noncutaneous regions. Primary and metastatic intradural melanomas are rare.³

According to the study by Fuld et al, the thoracic region is the most common place of primary spinal melanoma and about half of the cases were observed in this area.⁴ The lumbosacral region is the rare place for melanoma presentation as a primary or metastatic tumor. Metastasis from cutaneous melanoma is the most common differential diagnosis of primary melanoma. In approximately 10% of patients with secondary melanoma, the primary site is unknown.⁵ Other

differential diagnoses are melanotic schwannoma and other neuroectodermal tumors, which could be excluded by negative immunohistochemical (IHC) stains for neuroendocrine markers such as (neuron-specific enolase) NSE, chromogranin, and synaptophysin.^{6,7}

Cutaneous and extracutaneous melanomas are histopathologically similar. S-100 protein, HMB-45, melanin A, and vimentin are used as immunohistochemical markers which help diagnosis of melanoma.^{8,9}

Hence S-100 has the highest sensitivity for the differentiation of melanocytes, it is used as a screening tool. However, S-100 is also found in several other tissues, including nerve sheath tumors and gliomas.^{10,11}

HMB-45 and melanin A are the two most common melanocyte-specific monoclonal antibodies used for the diagnosis of melanoma. The sensitivity of HMB-45 and melanin A for melanoma is approximately 93 to 100%.^{11,12} Vimentin is almost always present in malignant melanoma with a sensitivity of 93%.¹³

The interesting point about melanoma histopathology is the absence of melanin pigment in approximately 50% of cases.⁷

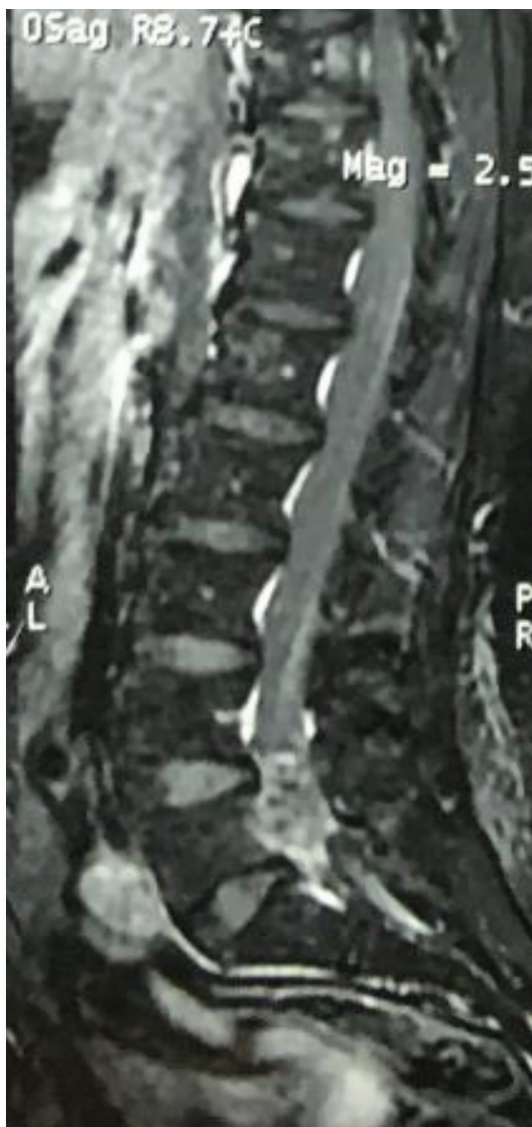


Fig. 3 Sagittal T1 MRI with GD enhancement. The tumor was enhanced diffusely. GD, gadolinium; MRI, magnetic resonance imaging.

The best modality for the diagnosis of spinal cord tumors is MRI. Spinal cord melanomas are usually slightly hyperintense on T1, iso- to hypointense on T2 weighted images, and show homogeneous mild enhancement after intravenous GD injection. These features are prominently related to paramagnetic features of melanocytes.^{14,15} However, it is difficult to diagnose melanoma on imaging and the definite way to diagnose melanoma involves histopathological studies. Hence, survival of primary and secondary melanoma is different, and differentiation of primary from secondary melanoma is important.

The life expectancy of metastatic melanoma is about one year, while survival of primary melanoma is reported to be approximately 6 years.^{2,16} The prognosis of extracutaneous melanoma is worse than cutaneous melanoma. According to Hayward's criteria for the diagnosis of primary CNS melanoma, the following two conditions are needed: Absence of malignant melanoma outside the CNS and histopathological confirmation.^{2,17}

The clinical course of melanoma is variable. Surgical resection is the first modality for primary melanomas; however, complete resection of the lesion is palliative and does not prevent further metastasis. Postoperative radiotherapy or chemotherapy was recommended by several authors. However, no evidence establishes the role of adjuvant therapy on the improvement of survival. Recently, the application of immunotherapy and molecular-targeted therapy in the treatment of malignant melanoma have improved.^{5,6}

We reported a pathologically confirmed case of primary malignant melanoma located in the intradural lumbosacral area, which is extremely rare due to its atypical location and manifestation. She did not show any signs and symptoms of melanoma at admission. During surgery, after laminectomy, the interesting point was the severe enlargement of L5 and S1 foramina in the affected side which enlarged the foramina. After opening the dura along with the root, the dark black vascular tumor was observed, which extended into the retroperitoneal space. The origin of the tumor is exactly unclear for us. This could originate intradurally and extended to retroperitoneal space or might be originated from retroperitoneal space and extend to intradural space through L5 and S1 foramina. Both of these possibilities are extremely rare.

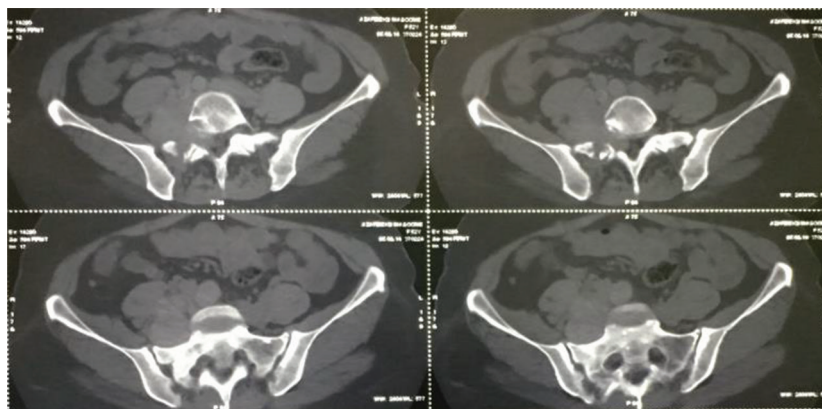


Fig. 4 Axial CT scan view at L5 and S1 level. The tumor expanded the right S1 foramina and extended into the retroperitoneal space. Bone erosion was seen. CT, computed tomography.

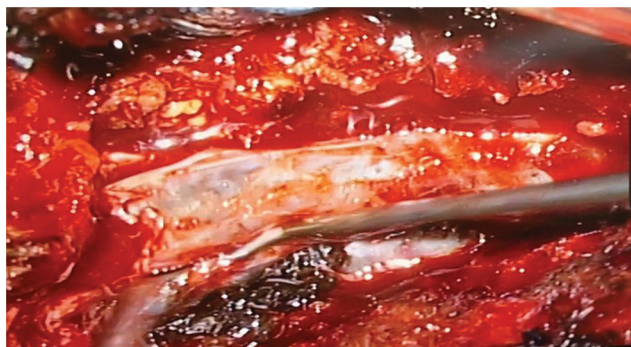


Fig. 5 During surgery, the dark gray-pigmented intradural lesion was exposed after dural incision along the L5 root.



Fig. 6 A dark black tumor was observed.

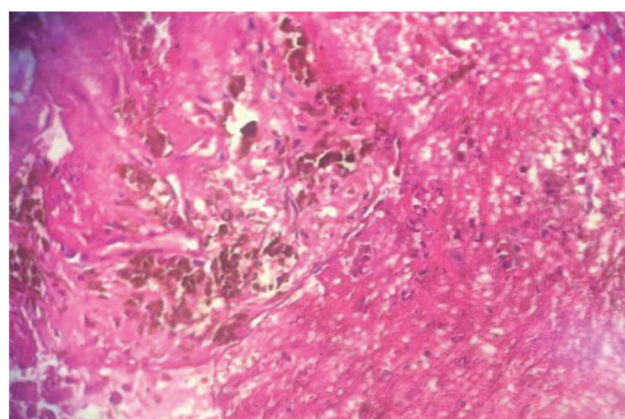
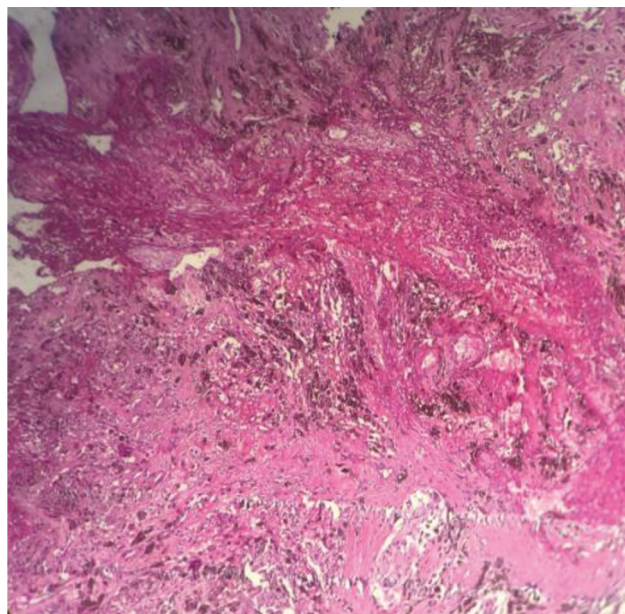


Fig. 7 Histopathological sections demonstrated a highly cellular lesion composed of clusters of atypical cells. The cells had pleomorphic nuclei with irregular borders and prominent nucleoli.

Conclusions

However rare, primary malignant melanoma could present as an intradural tumor and cause neurological deficit.

Funding

None.

Conflict of Interest

None declared.

References

- Li YP, Zhang HZ, She L, et al. Primary extramedullary spinal melanoma mimicking spinal meningioma: a case report and literature review. *Oncol Lett* 2014;8(1):339–344
- Fuld AD, Speck ME, Harris BT, et al. Primary melanoma of the spinal cord: a case report, molecular footprint, and review of the literature. *J Clin Oncol* 2011;29(17):e499–e502
- Pappenheim E, Bhattacharji SK. Primary melanoma of the central nervous system. Clinical-pathological report of a case, with survey and discussion of the literature. *Arch Neurol* 1962;7:101–113
- Farrokh D, Fransen P, Faverly D. MR findings of a primary intramedullary malignant melanoma: case report and literature review. *Am J Neuroradiol* 2001;22(10):1864–1866
- Sivendran S, Glodny B, Pan M, Merad M, Saenger Y. Melanoma immunotherapy. *Mt Sinai J Med* 2010;77(6):620–642
- Ko JM, Fisher DE. A new era: melanoma genetics and therapeutics. *J Pathol* 2011;223(2):241–250
- Jungbluth AA, Busam KJ, Gerald WL, et al. A103: An anti-melan-a monoclonal antibody for the detection of malignant melanoma in paraffin-embedded tissues. *Am J Surg Pathol* 1998;22(5):595–602
- Larson TC III, Houser OW, Onofrio BM, Piepgras DG. Primary spinal melanoma. *J Neurosurg* 1987;66(1):47–49
- Hayward RD. Malignant melanoma and the central nervous system. A guide for classification based on the clinical findings. *J Neurol Neurosurg Psychiatry* 1976;39(6):526–530
- Nishihara M, Sasayama T, Kondoh T, Tanaka K, Kohmura E, Kudo H. Long-term survival after surgical resection of primary spinal malignant melanoma. *Neurol Med Chir (Tokyo)* 2009;49(11):546–548
- Chamberlain MC, Tredway TL. Adult primary intradural spinal cord tumors: a review. *Curr Neurol Neurosci Rep* 2011;11(3):320–328
- Rager EL, Bridgeford EP, Ollila DW. Cutaneous melanoma: update on prevention, screening, diagnosis, and treatment. *Am Fam Physician* 2005;72(2):269–276
- Yamaguchi T, Shioaki Y, Koide K, et al. A case of primary malignant melanoma of the esophagus and analysis of 193 patients

- in Japan [article in Japanese]. *Nippon Shokakibyō Gakkai Zasshi* 2004;101(10):1087–1094
- 14 Greco Crasto S, Soffietti R, Bradac GB, Boldorini R. Primitive cerebral melanoma: case report and review of the literature. *Surg Neurol* 2001;55(3):163–168, discussion 168
 - 15 Cuevas LM, Daud AI. Immunotherapy for melanoma. *Semin-Cutan Med Surg* 2018;37(2):127–131
 - 16 Garbe C, Eigentler TK, Keilholz U, Hauschild A, Kirkwood JM. Systematic review of medical treatment in melanoma: current status and future prospects. *Oncologist* 2011;16(1):5–24
 - 17 Liubinas SV, Maartens N, Drummond KJ. Primary melanocytic neoplasms of the central nervous system. *J Clin Neurosci* 2010;17(10):1227–1232