

# Smith–Lemli–Opitz’s Syndrome as a Possible Cause of Recurrent Pregnancy Loss: A Case Report

Anjali Mitra, MD<sup>1</sup> Shelley Dolitsky, MD<sup>1</sup> Stacy Yadava, MD<sup>1</sup> Elena Ashkinadze, MS, CGC<sup>1</sup>

<sup>1</sup>Department of Obstetrics, Gynecology and Reproductive Sciences, Rutgers Robert Wood Johnson Medical School, New Brunswick, New Jersey

Address for correspondence Anjali Mitra, MD, Department of Obstetrics, Gynecology and Reproductive Sciences, Rutgers Robert Wood Johnson Medical School, 125 Paterson Street, New Brunswick, NJ 08901 (e-mail: mitraa1@rwjms.rutgers.edu).

Am J Perinatol Rep 2020;10:e118–e120.

## Abstract

### Keywords

- ▶ Smith–Lemli–Opitz’s syndrome
- ▶ expanded carrier screening
- ▶ recurrent pregnancy loss

Based on the known carrier frequency of Smith–Lemli–Opitz’s syndrome (SLOS), the prevalence of this disease should be significantly higher than what is observed in the population. This may be due to a higher rate of pregnancy loss in affected embryos. Here, we present the case of a couple who underwent expanded carrier screening (ECS) after experiencing three first trimester pregnancy losses. Both parents were found to be carriers of SLOS mutations, and DNA analysis of the fetal remains of the third loss revealed the aborted fetus had inherited both the maternal and paternal mutations. This suggests SLOS as a reason for this patient’s recurrent pregnancy loss (RPL), and therefore, ECS should be considered as part of the RPL work-up.

Smith–Lemli–Opitz’s syndrome (SLOS) is an autosomal recessive condition characterized by multiple congenital anomalies and intellectual disability. It is caused by a mutation in *DHCR7* (11q12–13), which codes for 7-dehydrocholesterol (7-DHC) reductase. There is a discrepancy between the expected incidence of SLOS based on carrier frequency and the observed incidence of disease. The observed incidence is 1/26,500, contrasted with an expected rate of 1/3,906.<sup>1,2</sup> This may be explained by one of two possibilities: undiagnosed disease presenting with a mild clinical phenotype or a higher rate of pregnancy loss in affected embryos. While the clinical presentation of SLOS is well studied, little is known regarding the likelihood of pregnancy loss in affected fetuses.

Here, we describe a couple who was evaluated for recurrent pregnancy loss (RPL) and were each found to be carriers of SLOS mutations. We will explore SLOS carrier status as a potential explanation for poor reproductive outcomes as well as how expanded carrier screening (ECS) both diagnosed and helped dictate management.

## Case Presentation

The patient is a 35-year-old gravida 5, para 2-0-3-2, who presented for genetic counseling after three first trimester

miscarriages and two healthy children. Chromosome analysis was not available for the first two losses, as studies were never initiated and there was no longer available tissue for DNA extraction and molecular testing. Tissue was obtained from the third loss and microarray analysis was performed, which confirmed normal male pattern. At this point, the patient and her husband were considering assisted reproduction with in vitro fertilization (IVF) for the purpose of preimplantation genetic testing. Prior to their first cycle, they were offered ECS.

Both the patient and her husband were then found to be carriers for SLOS. The patient was found to carry a mutation associated with a severe phenotype (*DHCR7*: c.964-1G > C), while her husband had a mutation with a milder phenotype (*DHCR7*: c.976G > T).<sup>1</sup> With this new information, targeted DNA testing of the fetal remains of the third loss was performed for the specific parental mutations. The fetus was found to be positive for both the paternal and maternal mutations, resulting in an affected embryo.

Based on this new information, the couple was subsequently counseled regarding their reproductive options including IVF for the purpose of preimplantation genetic testing for the SLOS mutations or spontaneous conception with invasive prenatal diagnostic testing. The couple

received  
December 16, 2019  
accepted  
December 20, 2019

DOI <https://doi.org/10.1055/s-0040-1705131>.  
ISSN 2157-6998.

Copyright © 2020 by Thieme Medical Publishers, Inc., 333 Seventh Avenue, New York, NY 10001, USA.  
Tel: +1(212) 760-0888.

License terms



verbalized that they would terminate if they had an affected fetus, and therefore, opted to pursue spontaneous conception and earlier testing with chorionic villus sampling (CVS). The CVS results confirmed a fetal karyotype 46,XY and was negative for both parental SLOS mutations, and they went on to have a healthy son (→ Fig. 1).

## Discussion

This case suggests a possible link between embryonic SLOS and pregnancy loss. Additional case reports have suggested that first trimester loss can occur in pregnancies with severe phenotypes.<sup>3</sup> Early loss of these affected pregnancies would help explain the difference between expected and observed incidence of disease.

Smith-Lemli-Opitz can present with a wide variety of phenotypes ranging from intellectual disability, dysmorphic facies to lethal multiorgan anomalies, such as holoprosencephaly. It is theorized that the normal function of 7-DHC reductase is to promote autoprolysis and covalent bonding of sonic hedgehog protein and cholesterol, forming an active cholesterol product. SLOS mutations interfere with normal enzymatic function of 7-DHC reductase, resulting in abnormal or modified sonic hedgehog protein. This can lead to holoprosencephaly and other malformations.<sup>4</sup>

Prenatal diagnosis of SLOS is challenging due to the variation in phenotypic presentation. When multiple anomalies are identified on ultrasound, further testing for this disorder should be offered if the patient desires invasive

testing. Generally, SLOS may be considered in the differential diagnosis when anomalies are seen on ultrasound and a normal fetal karyotype is established. However, most cases of prenatal diagnosis for SLOS are prompted after the couple already has one affected child. Fetal testing can be done via CVS or amniocentesis for either DNA testing for the known familial mutations or for biochemical analysis. Almost all tissues of an affected fetus will demonstrate elevation in 7-DHC.<sup>5</sup>

At this institution, in patients who experience RPL, karyotype is performed on available tissue with reflex to microarray if the karyotype is normal. Karyotyping of the parents and microarray of the products of conception are important components of the RPL work-up.<sup>6</sup> This case demonstrates that in addition to these studies, ECS may be beneficial in the RPL work-up. Furthermore, the information obtained from ECS can be vital in counseling on future reproductive expectations and utility of assisted reproductive technologies.

With widespread use of ECS, we may identify more individuals at risk for affected pregnancies prior to conception. Before the availability of ECS, carrier testing was limited to disorders in specific ethnicities due to a higher founder mutation rate. Individuals with a family history of a specific disease were offered carrier testing. However, the majority of affected children are born to couples with no previous family history.<sup>5,7</sup> The American College of Obstetricians and Gynecologists now recommends that OB/GYNs and genetic counselors offer ECS to all patients in the preconception or prenatal period. In an increasingly global era, ECS could be used as an

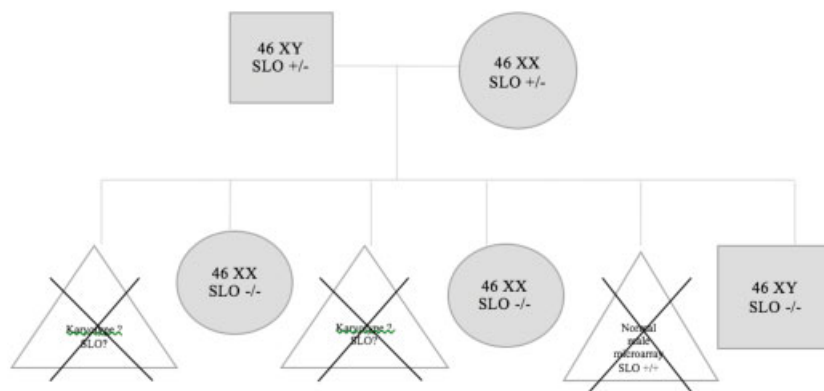


Figure 1. Pedigree of patient

### FIGURE LEGEND

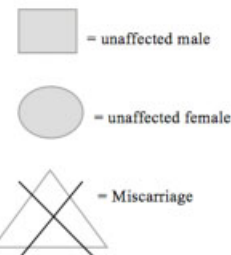


Fig. 1 Pedigree of patient.

important tool to elucidate the carrier status of couples with RPL and this is perhaps another indication to offer it.

Interestingly, no research has been done regarding RPL as an indication for ECS. This case shows that there may be potential benefit in identifying couples who are carriers for recessive mutations that can result in lethal phenotypes, such as SLOS. As we continue to universally offer ECS in this genomic era, more data will become available to investigate the utility of ECS for the RPL work-up.

#### Conflict of Interest

None.

#### References

- 1 Jezela-Stanek A, Ciara E, Małunowicz E, Chrzanowska K, Latos-Bieleńska A, Krajewska-Walasek M; Smith-Lemli-Opitz syndrome Collaborative Group. Differences between predicted and established diagnoses of Smith-Lemli-Opitz syndrome in the Polish population: underdiagnosis or loss of affected fetuses? *J Inherit Metab Dis* 2010;33(Suppl 3):S241–S248
- 2 Lazarin GA, Haque IS, Evans EA, Goldberg JD. Smith-Lemli-Opitz syndrome carrier frequency and estimates of in utero mortality rates. *Prenat Diagn* 2017;37(04):350–355
- 3 Balogh I, Koczok K, Szabó GP, et al. Mutational spectrum of Smith-Lemli-Opitz syndrome patients in Hungary. *Mol Syndromol* 2012;3(05):215–222
- 4 Ryan AK, Bartlett K, Clayton P, et al. Smith-Lemli-Opitz syndrome: a variable clinical and biochemical phenotype. *J Med Genet* 1998;35(07):558–565
- 5 Kratz LE, Kelley RI. Prenatal diagnosis of the RSH/Smith-Lemli-Opitz syndrome. *Am J Med Genet* 1999;82(05):376–381
- 6 Kutteh WH. Novel strategies for the management of recurrent pregnancy loss. *Semin Reprod Med* 2015;33(03):161–168
- 7 Committee Opinion No. 691: Carrier Screening for Genetic Conditions. *Obstet Gynecol* 2017;129(03):e41–e55