

IMMEDIATE IMPLANT PLACEMENT WITHOUT FLAP ELEVATION - A REVIEW

Vinaya Bhat¹ & Mahek R. Bangawala²

¹Professor, ²Intern, Department of Prosthodontics and Crown & Bridge,
A.B. Shetty Memorial Institute of Dental Sciences, Nitte University, Mangalore - 575 018, Karnataka, India.

Correspondence :

Mahek R. Bangawala

Mahetwad Street, Nr. Police Station, Chikhili - 396 521, Navsari, Gujarat.

Mobile : +91 9035 63782 E-mail : mrbangawala.29@gmail.com

Abstract :

Background : Not elevating a flap has its own advantages in preserving soft tissue contour around the implant. Thus, aesthetic outcome will be best achievable in anterior region with immediate implant placement without flap elevation.

Summary of content : In present era, the outcome of placing implants into teeth sockets immediately following extraction is as predictable as placing into healed sockets. This procedure can be completed in two ways, one is with mucoperiosteal flap elevation and the other is without flap elevation.

This review article explains the indications, contraindications & factors affecting immediate implant placement without flap elevation. Furthermore it explains advantages - disadvantages of this procedure, case selection criteria & present approach towards this procedure.

Conclusion : Immediate dental implant placement in extraction sockets has been practiced universally from time to time. The advantage of this procedure over the conventional implant placement is obvious and especially so in the aesthetic zone. However careful selection of the patients and meticulous surgical procedure are critical in achieving success in Immediate Implant Placement without flap elevation.

Keywords : Dental implants, Immediate placement, Flapless technique etc.

Introduction :

From the time of invention of dental implants by Branemark in 1952, field of prosthodontics is witnessing a sea of changes in treating edentulous patients. Ever since, implant dentistry is undergoing continuous modifications and invention of newer techniques. Recently, it has reached greater heights in the form of placing implants immediately after extraction which not only gives better aesthetic outcome but also preserves the soft and hard tissue.¹

placement a mucoperiosteal flap was reflected. However, they observed that there is increased bone loss and collapse of interproximal papilla.² According to Cardarapoli et al³, reflecting a flap can lead to remodeling of the exposed bone surface. Mahmood et al⁴ in their article, they described immediate implant placement in interforamina area of mandible. Here implants were bilaterally splinted & retained over denture & fixed bridges. According to Campelo et al⁵ and Covani et al⁶, reflecting a flap induces gingival recession, papilla destruction & crestal bone resorption. Hence, the immediate implant placement procedure was thought of without reflecting a mucoperiosteal flap by Al-Ansari et al⁷ in 1998. They had noticed reduced bleeding, maintenance of tissue contour & reduced post-operative patient discomfort with flapless immediate implant placement.⁷ Moreover maintenance of available anatomical structure is much easier than to reconstruct the new one.⁴

Several techniques of immediate implant placement with flap elevation have been described earlier. In a technique described by Schwartz et al in 1997 for immediate implant

Access this article online

Quick Response Code



This paper reviews the advantages, disadvantages, indications, contraindications, case selection and the procedural aspects of this technique in detail.

Indications :

Being esthetic zone, maxillary anterior regions are the most common indications for placing implant immediately after extraction. Flapless immediate implant placement is preferred as the amount of recession through this method is only 1-1.5 mm after 1 yr which is considered negligible.²

Patients with high demand for esthetics are a definitive indication for flapless procedure as the ultimate outcome with this procedure is excellent.^{2,7}

Intact gingiva without recession and socket walls without any bony defects at the time of implant placement are another indication for this procedure. Absence of any periodontal diseases is also a positive sign.⁸

Fractured tooth at the gingival margin with non-vitality and root length less than 13 mm is indicative of proceeding with immediate implant placement without flap elevation rather than post & core treatment.⁷

Endodontic failure, radicular caries and non-restorable crowns are indications for immediate implant placement without flap elevation.⁹

Contraindications:

Past history of involvement of the tooth with periodontal disease is a definite contraindication of flapless procedure, as there is insufficient hard and soft tissue in this area.¹⁰⁻¹² Since flapless procedure is a "blind" procedure, implant placement is difficult.⁴

Many a times the tooth in the site of implant placement would have unhealthy periapical hard and soft tissues with loss of vascular supply. Placement of implant without flap in such areas is deemed to be a failure.¹⁰ A flap procedure facilitating curettage of the infection site would be more suitable for such situations.⁴ As per described by Mahmood et al⁴, Nemcovsky et al has recommended delayed implant placement at least after 4-6 weeks in such cases.

Presence of soft tissue recession, dehiscence and fenestrations are a positive contraindication for flapless technique.⁹

Insufficient bony walls especially the facial wall cannot be managed with a flapless procedure for implant placement.⁸ This condition requires grafting procedure and hence cannot be carried out without good vision of the surgical site.⁹

All the relative contraindications for any surgical procedures like, smoking and presence of systemic disease are contraindications for this procedure also.⁸

Procedure:

Patient Selection Criteria:

- A) Level of gingival margin- It is important to have a gingival margin at the Cemento-Enamel Junction level. Gingival recession prior to the extraction indicates periodontally compromised patient which leads to recession after healing and gives poor aesthetic result. These situations lead to failure of implant due to compromised healing as vascular supply will be poor.²
- B) Condition of socket wall- Extraction of the tooth should be atraumatic. Intact socket walls indicate good vascular supply which induces rapid healing and increase initial stability. During extraction or prior to extraction if any of the socket wall is damaged, bone grafts are necessary to complete the procedure and to induce bone healing.²
- C) Absence of bony defects- If any bony defects like dehiscence or fenestration are present, it needs special approach for placing implant. Hence such patients should not be taken up for this procedure.²
- D) Tissue bio type- Thick tissue bio type is always preferred over thin tissue bio type. Thick tissue bio type will be more resilient where as thin bio type increase the chances of recession.^{7,8}
- E) Age of the patient and history of systemic diseases- Young patients with no history of any systemic diseases respond well to surgical procedures and osseointegration will be quicker.²

Surgical Procedure:^{6,13}

1. Routine pre surgical procedure of rinsing with chlorhexidine for 1 minute is carried out.
2. Under Local anesthesia, the tooth is extracted as atraumatically as possible. The supracrestal fibres are severed atraumatically using a no.15 blade with 360° intrasulcular incision prior to extraction. Socket walls can be explored using periodontal probe for integrity. (Fig. 1,2 & 3)
3. Socket walls are debrided and good curettage is done of extraction socket.⁴
4. Implant site is prepared with standard drills using bony walls as guide to 3-4 mm beyond the socket level. It was proven in the study done by Mahmood et al⁴ that this procedure protects the bone from excessive heat generation as suggested by Schwartz et al & it reduces edema & excessive post operative pain as suggested by Garber et al & Locante et al.⁴
5. Bony walls are used as a guide for placement of implant and fingers are placed over buccal mucosa while drilling for implant in order to prevent bone perforation.⁶
6. Implants are placed and soft tissue edges are sutured

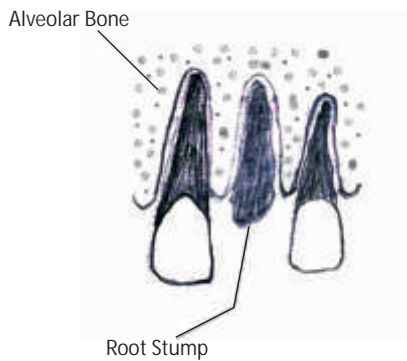
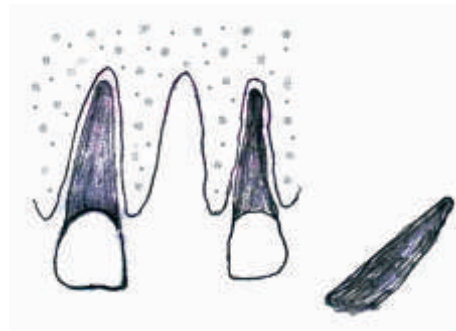



Fig. 1



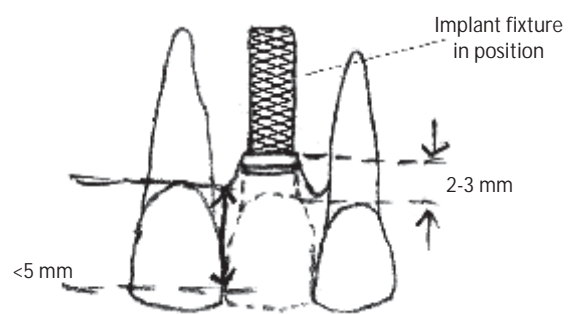
Atraumatic removal of root stump

Fig. 2



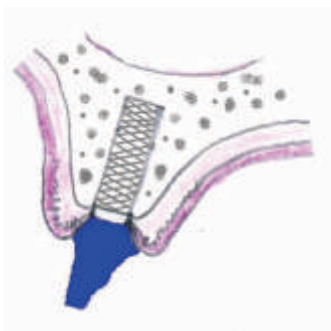Intact facial plate & gingiva

Fig. 3



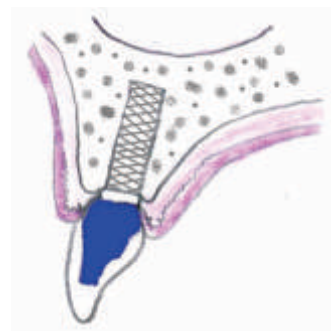
Implant placement without flap elevation

Fig. 4



Custom abutment placed

Fig. 5



Implant crown placed

Fig. 6

(Fig. 4). Attaining primary stability of >30Ncm is crucial if implant has to be immediately loaded. Primary stability can be checked through torque wrench or Periotest.¹ According to Juodzbalys, minimum of 30% of implant surface in terms of length, width and depth of insertion has to be fixed in bone to achieve & maintain primary stability.⁴

7. Antibiotics and Anti-inflammatory medicines are prescribed for 7 days.
8. Second stage is performed after 4-6 months.
9. Incision is made only to remove the surgical screw and to place the healing abutment.
10. Prosthesis is fabricated. (Fig. 5 & 6)

Factors Affecting Procedure:

- A) Tissue bio type - Thick tissue gives better result as recession will be less.⁸ Average facial crestal bone loss with thick tissue bio type is usually less than 1 mm whereas with thin tissue bio type it is 1-1.5 mm.²
- B) Condition and thickness of the facial wall - Overall aesthetic outcome and gingival margin level depends on the condition of the facial wall of the socket. Before tooth extraction condition of the facial wall has to be probed. Width of 4-5 mm and height of 10 mm are essential for immediate implant placement.²
- C) Position of the Implant shoulder - Implant should be placed more lingually in order to prevent facial bone loss.⁹⁻¹⁰ This position is decided by drawing an imaginary line connecting mesial and distal adjacent tooth. Implant shoulder should always lie lingual to this imaginary line.²
- D) Vascular supply of the socket wall - This factor affects healing part of the implant placement. Good vascular supply helps in achieving rapid primary stability and

osseointegration. Poor vascular supply increases risk of implant failure as bone formation will be affected which directly affects the stability of the implant.⁸

- E) Implant design – Grit blasted and acid etched implants are most suitable for immediate implant placement without flap elevation & early loading.¹⁰ They achieve faster osseointegration, better bone implant interface, higher removal torque value & greater primary stability.⁴ In addition to, Implant has to be greater in length & diameter than that of extraction socket to increase bone implant contact (BIC).⁴
- F) Maintenance of primary stability - Primary implant stability basically depends on type of implant used and surgical procedure followed for placement.⁴ Cavalchia & Bravi suggested that implant has to be firmly anchored to the bone to maintain primary stability as during healing of necrotic bone it can reduce.⁴ Primary implant stability is of more significance esp. in case of immediate loading.⁴
- G) Connection of the provisional crown - Insertion of temporary crown immediately after implant placement helps in achieving primary stability and also prevents the overgrowth of the papilla. This temporary crown is always kept out of occlusion at least 1-2 mm as suggested by Block et al also that healing process does not get affected by occlusal forces.^{2,4,9,12} There are significant effects of immediate provisionalization on interdental papilla level and interdental bone level. It not only provides support but also reduces bone loss and as a result maintenance of bone level minimizes collapse of the soft tissue.¹⁴ As described by Mahmood et al⁴, Garber et al has reported excellent results of immediate provisionalization.

Advantages - Disadvantages of the Procedure:

ADVANTAGES	DISADVANTAGES
Avoids additional surgical procedure ^{4,10,15}	Technique sensitive ^{2,4}
Rapid primary stability ^{4,8}	Bone grafts/membranes are often required ⁸
Psychological benefit as edentulous period is reduced ^{4,7,9,16}	Do not allow clinician to modify mucosal position ²
Preserves hard & soft tissue – (maximum recession of 1-1.5 mm) ⁸	Unpredictable soft & hard tissue loss – blind procedure ^{4,7,8}
Good aesthetic outcome - black triangles are omitted ^{8,17}	Risk of implant failure is high due to incorrect position & sometimes due to facial wall perforation ^{4,8}

Evaluation of the Treatment Outcome with Flapless Technique:

Albrektsson et al 1986 & Buser et al 1990 has given criteria for determining success of the implant treatment.¹⁵

In order to measure the overall outcome of immediate implant placement with this procedure clinical indices like pain, mobility, crestal bone loss, aesthetic outcome and condition of periodontium have been used.¹⁷

Percussion and forces upto 500g is used to evaluate pain and discomfort. However, this force does not indicate integration of implant with bone but only measure the impact force. Presence of pain indicates inflamed tissue surrounding implant or fixture impinging on nerve or implant is mobile.¹⁷

Primary stability of 30-35 Ncm is important for successful osseointegration especially in case of immediate implant placement without flap elevation.^{1,4,18} The other method of assessing implant stability is by resonance frequency analysis (RFA).⁷ Healthy implants have an average mobility of around 75 microns, which is invisible clinically. Brunski has considered micromovements of more than 150 microns adversely affects healing & leads to fibrous interface.¹⁹ Mobility of the implant can be checked by applying vertical or horizontal forces upto 500gm. Presence of clinical mobility indicates failure of osseointegration.¹⁷

The flapless procedure for immediate implant placement prevent alveolar bone loss both in height and width.⁹ Crestal bone loss after healing is measured by radiographic evaluation. Several studies have shown that marginal bone loss after 1year usually lies between 0.5-1 mm.¹⁷

Correct clinical, surgical and prosthetic procedure for replacing missing teeth using immediate implant placement without flap elevation helps clinician to achieve and maintain good aesthetic results.⁹ Aesthetics Outcome of Immediate Implant Placement Without Flap Elevation is measured by using two indices: modified SES and PES.² According to Jemt et al 1997 & Caradarpoli et al Papilla

Index Score (PIS) is used for assessing the integrity & size of interproximal papilla adjacent to implant.^{3,20} In PIS evaluation also, Immediate implant placement without flap elevation gives excellent aesthetic results as it leaves the periosteum intact on the bone & thus preserves the blood supply.⁴ Maximum cases treated by this technique and measured by these two indices during follow up shows good aesthetic result.¹⁷ But as the vertical distance increases between the contact point of crown and implant there will be significant loss of Papilla over period of time.²¹ Moreover implant should be 3-4 mm apical to the free gingival margin to optimize aesthetics.¹⁸

Condition of periodontium can be evaluated by probing depth which is used if pathological signs like radiolucencies, purulent exudate or bleeding are present.¹⁷ Few cases shows peri-implant mucositis with or without facial mucosa recession. One of the reason for the recession of facial mucosa is that immediate implant placement without flap elevation doesn't prevent facial crestal bone loss. Moreover recession is seen in higher proportion in thin tissue bio-type cases.² However good maintenance of Oral hygiene and regular check up under supervision reduces the chances peri-implant mucositis and failure of implant.

Immediate implant placement without flap elevation has been found to be a safe and successful treatment showing success rate of more than 90%(94.5%-100%) over 12 months⁹⁻¹⁰ with maximum patient satisfaction in terms of aesthetics, phonetics and psychological.⁴

Special Considerations & Present Approach:

Nowadays in order to achieve rapid primary stability and moreover strengthening socket walls bone grafts and barrier membranes are used. Deproteinized Bovine Bone Material (DBBM) are the most commonly used either alone or in conjunction with expanded barrier membrane.¹⁰ Connective tissue graft taken from palate has also shown promising result when used along with barrier membrane.⁸ However this discrepancy within 2 mm does not require any type of bone regenerative procedure.^{7,10} And moreover

use of barrier membrane is associated with clinical complications like bacterial infection and impaired bone healing.¹⁵ Various studies have shown that these bone augmentation procedures reduce horizontal resorption of facial bone but do not produce any significant reduction in vertical resorption.¹⁰ Thus, bone grafts and barrier membrane are useful in relieving geometric discrepancy and accelerating bone formation.⁹

A recent article by Arango et al²² suggested that a xenograft material can be incorporated into soft tissue without any inflammatory reaction which provide substance to improve the soft tissue profile.

In order to achieve predictable aesthetics by minimizing buccal contour change & to induce the thickness of peri-implant soft tissue, the following matter has to be kept in mind¹⁸:

- a) Atraumatic removal of tooth without flap elevation
- b) Placement of bone graft in residual gap and
- c) Provisionalization of screw retained provisional restoration which serves as a socket seal device.

The other method follow to achieve good bone healing and to overcome gap discrepancy is to use conical implants⁴ or implants with rough surface and larger than extraction socket in terms of length and diameter.⁴

References:

1. Zahran A, El-Refai M, Amir T, Fouda M. Clinical Evaluation of Flapless Free Hand Immediate Implant Placement in Fresh Extraction Sockets. *The Journal of Implant & Advanced Clinical Dentistry*. 2010;2:55-63
2. Stephen TC, Ivan BD, Eric CR, and John GC. Case series Immediate Implant Placement Postextraction Without Flap Elevation. *The Journal of Clinical Periodontology*, Jan. 2009;80(2):163-72
3. Cardaropoli G, Lekholm U, Wennström JL. Tissue alterations at implantsupported single-tooth replacements: a 1-year prospective clinical study. *Clin Oral Impl Res*. 2006 Apr; 17(2):165-71.
4. Prof. Dr. Mahmood Aly, Dr. Sarah Mohammed Arafat. Immediate loading of Implants Placed into Fresh Extraction Sockets with Periapical Lesions without Augmentation. *Smile Dental Journal* 2008; 3(4):6-21.
5. Campelo LD, Camara JR. Flapless implant surgery: a 10-year clinical retrospective analysis. *Int J Oral Maxillofac Implants*. 2002 Mar-Apr; 17(2):271-6.
6. Covani U, Barone A, Cornelini R, Crespi R. Soft tissue healing around implants placed immediately after tooth extraction without incision: a clinical report. *Int J oral Maxillofac Implants*. 2004 Jul-Aug; 19(4):549-53.
7. Abd El Salam El Askary. *Immediate Aesthetic Implant Therapy* (Ch. 6). *Fundamentals of Aesthetic Implant Dentistry* second ed. 2007:179-207.
8. Richard U. Koh, Ivan Rudek, and Hom-Lay Wang. Immediate Implant Placement: Positives and Negatives. *The Journal of Implant Dentistry*. 2010; 19(2):98-103.
9. Ruby S, Paolo G, Alessandro C and Enrico P. Post Extraction Implant Placement with Immediate Provisionalization and Finalization Using a Simplified Technique: Technical Notes and a Case Report. *The Open Dentistry Journal* 2012; 6:164-69.
10. Stephen T, Daniel B, Prof. Dr. Med Dent. Clinical And Aesthetic Outcomes of Implants Placed in Post-Extraction Socket. *The International Journal of Oral and Maxillofacial Implants* 2009; 24:186-217.
11. Saadoun AP. Immediate implants placement and temporization in extraction and healed sites. *Compend Contin Educ Dent*. 2002 Apr; 23(4): 309-24.
12. Block M, Finger I, Castellon P, Lirettle D. Single-tooth immediate provisional restoration of dental implants: technique and early results. *J Oral Maxillofac. Surg*. 2004 Sep; 62(9):1131-8.
13. Seanson L, Gough M and Hemmings K. *Textbook of Implantology in General Dental Practice*.
14. Chong-Hyun Han, Jeong-Wan-Paik, Keun-Woo-Lee, Dong-Hoo-Han, Moon-Kyu-Chung, Sunjai Kim. Implant of Immediate & Non Immediate Provisionalization on the Soft Tissue Aesthetics of Final Restorations on Immediately Placed Implants. *Journal of Korea Academy of Prosthodontics* 2008; 43(3):238-45.
15. A Husein. Immediate ITI Implants in Management of Anterior Missing

In this way, present approach in this procedure conveys that Flaps and Implants are the trends of dentistry.

Conclusion :

In the modern era of aesthetics, significant modifications are being carried out to achieve good results in all spheres of dentistry. Field of implant dentistry has been undergoing several changes in its techniques and materials ever since it was identified as the most aesthetic treatment choice in the anterior region. From delayed placement to immediate placement of implants, it has moved to soft tissue concerns regarding aesthetics. The prevalence of recession that occurs upon placement "with flap" elevation has given way to the innovative technique of placing the fixtures "without" elevating the flap.

Recently, this procedure is being implemented in both, delayed as well as immediate placement of dental implants in achieving the increased demand for aesthetics. However, this procedure has its own disadvantages and contraindications which have to be kept in mind prior to selecting the patients. In this review paper all aspects of this procedure have been explained. Diligent case selection and the procedural aspects are critical factors in achieving success with this technique of implant placement.

- Tooth : A Case Report. Archives of Orofacial Sciences. 2006; 1:67-70.
16. Kan JY, Rungcharassaeng K., Lozada JL, Bilaminar Subepithelial Connective Tissue Grafts for Immediate Implant Placement and Provisionalization in the aesthetic zone. The Journal of California Dental Association 2005; 33:865-71.
 17. Misch CE, Perel ML, Wang H, Sammartino G, Steigman M, Alberto Rebaudi, Pablo Galindo-Moreno, Ady Palti. Implant Success, Survival, and Failure: The International Congress of Oral Implantologists Pisa Consensus Conference. The Journal of Implant Dentistry. 2008; 17(1):5-9.
 18. Stephen JC, Maurice AS, Henry S, David AG, Hanae S, Guido OS and Dennis PT. The Dual Zone Therapeutic Concept of Managing Immediate Implant Placement & Provisional Restoration in Anterior Extraction Sockets. Compendium July/August 2012; 33(7):524-34.
 19. Brunski JE. In vivo bone response to biomechanical loading at the bone/dental-implant interface. Adv Dent Res. 1999 Jun; 13:99-119.
 20. Jemt T. Regeneration of the gingival papillae after single-implant treatment. Int J Periodont Rest Dent. 1997 Aug; 17(4):326-33.
 21. Mark RR, Michael SB and Donald EM. Correlation of Papilla to Crestal Bone Levels Around Single Tooth Implants in Immediate or Delayed Crown Protocols. Journal of Oral & Maxillofacial Surgery 2005; 63:1184-95.
 22. Araújo MG, Linder E, Lindhe J. Bio-Oss collagen in the buccal gap at immediate implants: a 6-month study in the dog. Clin Oral Implants Res. 2011; 22(1):1-8.