

CYTOLOGICAL EXPERIENCE OF PAEDIATRIC RETROPERITONEAL GANGLIONEUROMA- A RARE CASE REPORT

Harish S. Permi¹, Sandeep Rai², Raghushankar³,
Padma Shetty⁴, Sunil Kumar Y.⁵ & Kiran H.S.⁶

^{1,3,5} Associate Professors, ^{2,4} Professors, ⁶ P.G. Students, ^{1,4,5,6} Department of Pathology, ^{2,3} Department of Paediatric Surgery, K.S. Hegde Medical Academy of Nitte University, Deralakatte, Mangalore - 575 018, Karnataka, India.

Correspondence

Harish S. Permi

Associate Professor, Department of Pathology, K.S. Hegde Medical Academy, Nitte University, Deralakatte, Mangalore 575018, Karnataka, India.

Mobile: 9964131827 Email: drharish01@gmail.com.

Abstract :

Ganglioneuroma is a benign tumor that originates from primordial neural crest cells which migrate from the mantle layer of the developing spinal cord to the sympathetic ganglia, adrenal medulla, and other sites. The most affected anatomical sites are the posterior mediastinum, retroperitoneum, adrenal gland, head and neck. It occurs most commonly in children over 10 years of age and consists of ganglion and Schwann cells. We report a case of 9 – year- old male child who presented with mass per abdomen in the right hypochondrium. Fine needle aspiration cytology showed mature ganglion cells and cluster of Schwann cells suggestive of Ganglioneuroma. Cytology diagnosis was confirmed by histopathological examination of tru-cut biopsy and subsequently excised specimen. On regular follow he is doing fine without any symptoms.

Keywords: Retroperitoneal, paediatric, cytology, Ganglioneuroma.

Introduction :

Ganglioneuroma is a rare, benign, neuroblastic tumor arising mainly from the central or peripheral autonomic nervous system, especially the sympathetic system. Peripheral neuroblastic tumors, including neuroblastomas, ganglioneuroblastomas and ganglioneuromas, are rare and constitute only 6% of tumors in children. Ganglioneuromas are the most differentiated and benign form of Peripheral neuroblastic tumors and the majority of Ganglioneuromas display as slow growing, solitary lesions that may or may not have an effect on neighbouring structures. ^[1] In the current literature, reports of ganglioneuromas diagnosed by fine-needle aspiration and its cytological appearance are scarce. ^[2] This case report

highlights the diagnosis of ganglioneuroma by fine needle aspiration cytology and stress to consider the diagnosis when cytology smears show mature ganglion and Schwann cells.

Case Report :

A 9-year-old boy presented with mass in the right hypochondrium since two years. Local examination showed firm, solid, non-tender mass in the right hypochondrium. Routine haematological and biochemical tests were within normal limits. Ultrasonography of abdomen showed a solid and well circumscribed lesion. CT scan abdomen showed large hypodense lesion measuring 12.5x11x14 cm located in the sub hepatic region. USG guided FNAC from the mass showed moderately cellular comprising of spindle shaped cells which had wavy nucleus (Schwann cells) and large polygonal cells having abundant granular cytoplasm, eccentrically located vesicular nucleus with prominent nucleolus (mature ganglion cells) suggesting the diagnosis of ganglioneuroma. [Figure 1] Tru-cut biopsy and subsequent excision of mass confirmed the cytological diagnosis. On regular follow up he is fine without any symptoms.

Discussion :

Ganglioneuroma is a rare benign tumor composed of nerve fibers and mature ganglion cells. ^[3] It is a well differentiated

Access this article online

Quick Response Code



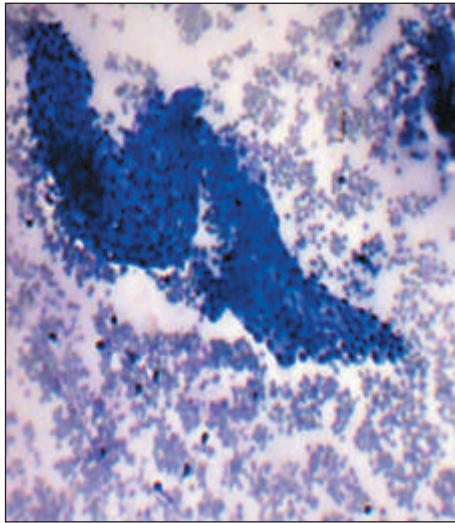


Figure 1 : Microscopy show cluster of benign spindle cells (Schwann cells) in a hemorrhagic background. (MGG stain X400)

benign tumor of the sympathetic nervous system. These tumors belong to the family of neoplasm that exhibits a wide range of differentiation with neuroblastoma at one end and ganglioneuroma at the other end. Because it share morphologic features with other both benign and malignant neural tumors, accurate preoperative diagnosis is often difficult. Nonetheless, it is critical for proper management.^[4] Solitary GNs most commonly occur in infants and young children, slightly more often in girls than boys, with a female-to-male ratio of about 3:1. The majority are diagnosed before the patient is 10 years of age. GNs are typically located in the thoracic cavity (60-80%, posterior mediastinum), the abdominal cavity (10-15%, adrenal gland, retroperitoneum, pelvic, sacral and coccygeal sympathetic ganglia, and the organ of Zuckerkandl) and the cervical region (5%). Other less common sites are the middle ear, the parapharynx, the skin, the orbital space and the gastrointestinal tract.^[2] Fine needle aspiration smear of nerve sheath tumors are usually low to moderately cellular, containing cohesive elongated or spindle-shaped cells in a background of myxoid material. The cells contain spindle-shaped nuclei which are very slender with pointed ends. The most striking feature of GN is the presence of mature ganglion cells; mature ganglion cells are characterized as possessing a large nucleus with dispersed chromatin and a conspicuous nucleolus which was seen in our case. It is important to recognize that,

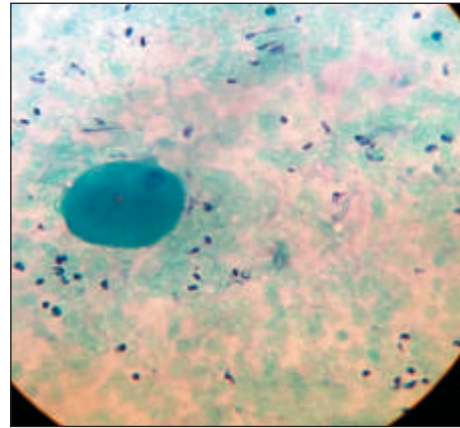


Figure 2 : Microscopy showing mature ganglion cell and spindle shaped cells. (PAP stain X400)

although only neuroblastic neoplasms disclose ganglion cells, pseudosarcomatous proliferations such as proliferative fasciitis and proliferative myositis may show ganglion cell-like cells. These reactive proliferative lesion smears exhibit a mixture of isolated cells and sheets of closely packed spindle cells (fibroblast-like) and giant polyhedral cells with round nuclei and prominent nucleoli (ganglion cell-like cells). The nuclei of spindle cells vary from fusiform to round and plump. The morphologic picture could compromise a correct diagnosis. However, the clinical course of proliferative reactive lesions as well as the immunoprofile of the ganglion cell-like cells can help to elucidate the real origin of the lesion.^[5] A complete resection of the lesion should be recommended and multisectioning of the whole specimen must be performed, paying particular attention for small foci of hemorrhage or necrosis in order to confirm or rule out the diagnosis of GNB. Clinical data and ancillary procedures such as immunohistochemistry and electron microscopy may contribute to the diagnosis.

Conclusion :

Ganglioneuroma is a rare benign tumor composed of nerve fibers and mature ganglion cells. In the current literature, reports of ganglioneuromas diagnosed by fine-needle aspiration and its cytological appearance are scarce. Our case report highlights the preoperative diagnosis of ganglioneuroma by fine needle aspiration cytology and stress to consider the diagnosis when cytology smears show mature ganglion and Schwann.

References :

1. M. Ramani, O. H. Radhika Krishna, K. Ramesh Reddy, Chanakya, R. Sowjanya. "An Interesting Case of differentiated Neuroblastoma-Ganglioneuroma of the Neck in a 5 year old Female Child". *Journal of Evolution of Medical and Dental Sciences* 2013; 2: 24: 4298-4301.
2. Marco A Ponce Camacho, Ricardo Diaz de Leon Medina, Ivett Miranda Maldonado, Raquel Garza Guajardo, Jorge Hernandez Salazar, Oralia Barboza Quintana. A 5 year old girl with a congenital ganglioneuroma diagnosed by fine needle aspiration biopsy: A case report. *CytoJournal* 2008; 5:5.
3. Yen H, Cobb CJ. Retroperitoneal ganglioneuroma: a report of diagnosis by fine needle aspiration cytology. *Diagn Cytopathol* 1998; 19:385-7.
4. Hee Kyung Kim, Dong Wha Lee, So Young Jin. Fine needle aspiration cytology of ganglioneuroma. *Korean Journal of Pathology* 2003; 14:12-16.
5. Wong NL. Fine needle aspiration cytology of Pseudosarcomatous reactive proliferative lesions of soft tissue. *Acta Cytol* 2002; 46:1049-55.