

A CASE OF SPHENOID SINUS MUCOCELE FOLLOWING ENDOSCOPIC SINUS SURGERY FOR FUNGAL SINUSITIS

Satheesh Kumar Bhandary B.¹ & Vadisha Srinivas Bhat²

¹Professor, ²Associate Professor, Department of Otorhinolaryngology, K.S. Hegde Medical Academy Deralakatte, Mangalore - 575 018, Karnataka, India.

Correspondence:

Satheesh Kumar Bhandary B.

Professor, Department of Otorhinolaryngology, K.S. Hegde Medical Academy, Deralakatte, Mangalore, Karnataka, India
Mobile : +91 9845130517 E-mail : sakubaraj@yahoo.com

Abstract :

Paranasal sinus mucoceles are common in frontal sinus, followed by ethmoid and maxillary sinuses. Sphenoid sinus is the least common site of mucocele, representing less than 2% of all paranasal sinus mucoceles. Here we present a case of sphenoid sinus mucocele, developing in a patient, who underwent endoscopic sinus surgery for fungal sinusitis involving the sphenoid sinus, presented with headache as the only complaint. The mucocele was diagnosed radiologically and was treated surgically by endoscopic sinus surgery.

Keywords : Mucocele; Sphenoid sinus; Fungal sinusitis; Headache; Endoscopic sinus surgery.

Introduction:

Mucocele of paranasal sinuses are benign cystic lesions lined by respiratory epithelium within the paranasal sinuses. They develop due to retention of mucoid secretions within a sinus, as a result of obstruction of the ostium of the sinus. The obstruction may be secondary to chronic sinusitis, trauma or prior surgery involving the sinus ostium. The retention of secretions lead to expansion of the bony walls of the sinus. However bony destruction is not common in mucoceles. Paranasal sinus mucoceles are commonest in frontal sinus, followed by ethmoid labyrinth and maxillary sinus. Mucoceles involving sphenoid sinus is very rare representing less than 2% of paranasal sinus mucoceles.¹ Diagnosis can be confirmed by imaging. Endoscopic surgery is the treatment of choice for this disease.

Case history :

A 50 year old man referred with history of headache of three months duration. He did not have any nasal symptoms other than headache. He was a diabetic being treated with oral hypoglycemics. While evaluating for headache, MRI brain was done which showed an iso to hypointense opacity

involving the sphenoid sinus on T1 weighted images, with expansion of the bony walls. In T2 weighted images, the opacity was hyperintense (Fig 1). Nasal endoscopy did not show any abnormal findings in the nasal cavity. We performed Endoscopic sinus surgery, and fungal debris was cleared from the sphenoid sinus. Fungal culture showed aspergillus. Endoscopic cleaning of the sinus was done after a week and again after second and third weeks. Sinus mucosa was healthy and patient was symptom free for two years. After two years, he again came with history of headache of similar nature, without any other symptoms. Nasal examination was normal. MRI of paranasal sinuses showed iso to hyperintense signal on T1 weighted images and hyperintense signal in T2 weighted images. There was expansion of the walls of the sphenoid sinus, with extension of the lesion into the orbital apex, and also causing indentation of the temporal lobe in middle cranial fossa (Fig 2,3). Superiorly it was bulging into the suprasellar system. The pituitary fossa was thinned out and displaced posteriorly (Fig 4). Intersinus septum of sphenoid was not seen, as it was removed during the previous surgery. However, the bony walls were preserved without erosion anywhere. Radiological findings are consistent with a mucocele of the sphenoid sinus. Endoscopic sphenoid sinusotomy was done and the mucocele was marsupialized. Endoscopic cleaning was done after a week. Patient is under follow up for last five months and is symptom free during this period.

Access this article online

Quick Response Code



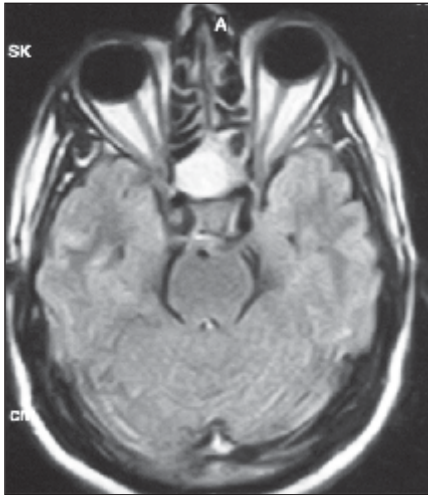


Fig 1 : MRI Axial cut T2 weighted image showing Fungus in sphenoid sinus

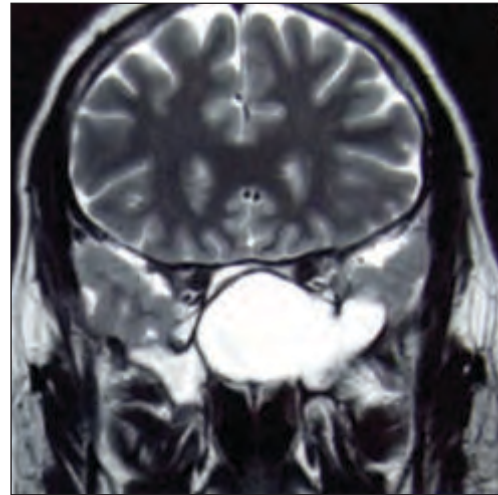


Fig 2 : MRI Coronal View T2 weighted image showing mucocele in sphenoid

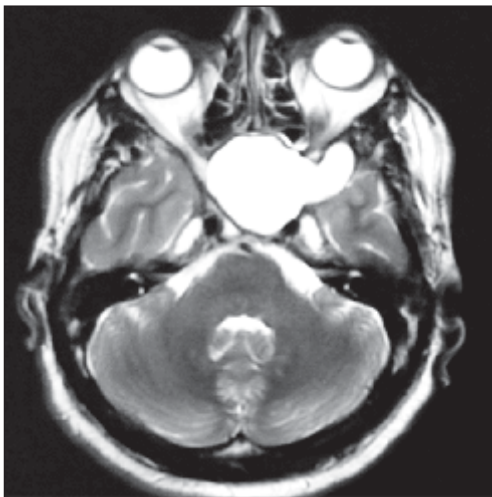


Fig 3 : MRI Axial cut T2 weighted image showing mucocele in sphenoid

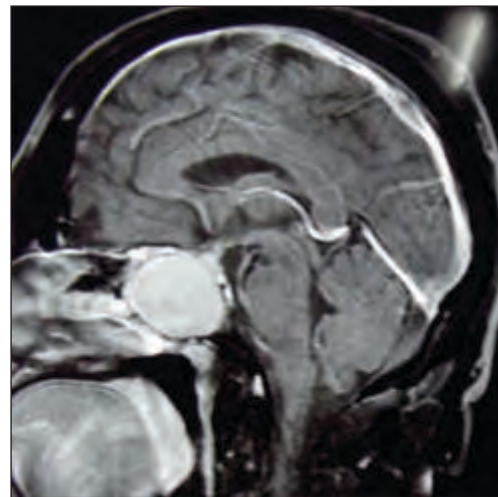


Fig 4 : MRI sagittal cut T2 weighted image showing mucocele in sphenoid displacing the pituitary fossa posteriorly

Discussion:

Mucocele of the paranasal sinus are encapsulated cystic lesions within a sinus. They develop as a retention cyst within a mucous gland of a sinus, or due to obstruction of sinus ostium resulting in accumulation of secretion and expansion of the bony walls of the sinus. Obstruction of sinus ostium are commonly due to chronic sinusitis; and occasionally due to prior surgery involving this structure. They are often seen in frontal and ethmoidal sinuses, and less often in maxillary sinus. Mucoceles involving sphenoid sinus are very rare, amounting to less than 2% of all paranasal sinus mucoceles.¹ The case we presented here is a sphenoid sinus mucocele, developed in a patient

surgically treated for fungal ball in the sphenoid sinus.

The symptoms of sphenoid sinus mucocele include ocular symptoms, headache, facial pain and nasal discharge. Clinical manifestations depend on the extension of the mucocele into the surrounding structures like optic nerve, optic chiasma, cavernous sinus, internal carotid artery, Pituitary fossa, Maxillary nerve and cranial nerves III, IV and VI.² Soon SR et al in their series of 10 cases of sphenoid sinus mucoceles, found ocular symptoms are commonest (50%) followed by headaches(30%).³ Nugent GR et al found headache as the commonest symptom, followed by visual disturbance.⁴ Our patient had only headache as a presenting symptom, without any other nasal or ocular

symptoms, even though the mucocele was large, and on imaging was shown to extend into the orbital walls and indentation over the temporal lobe and pituitary fossa.

Diagnosis of sphenoid sinus mucocele can be confirmed with CT scan and MRI of paranasal sinuses, as the sinus per se is inaccessible to clinical examination. CT scan will delineate the limits of the mucocele and is useful in determining bone remodelling and bone erosion. Mucoceles do not enhance with contrast, except when inflamed causing a pyocele.² MRI features of sphenoid sinus mucocele depend largely on the protein content. Some show hypointensity on T1 weighted images and hyperintensity on T2 weighted images. Sometimes there may be hyperintensity on both T1 and T1 weighted images.⁵ Hyperintensity is due to high protein content. Occasionally T2 weighted images may be hypointense owing to the presence of thick mucus.⁶

Surgical decompression followed by marsupialization is the treatment of choice for sphenoid sinus mucocele, which can be well accomplished by the aid of endoscopes. The natural ostium of the sinus need to be widened to empty the content of the mucocele. Partial removal of the middle turbinate provides direct entrance into the sphenoid sinus through the anterior sinus wall.⁷ However this is not required in all cases, as we could open the sphenoid sinus without disturbing the turbinates. A second look endoscopic examination after a week is needed to clean the crusting near the widened ostium and to keep the ostium patent. Endoscopic surgery can also be combined with navigating system.⁸ Patient will be symptom free the next day after surgery with the release of pressure within sinus cavity. Recurrence is not seen in a case where a wide opening is created.

References:

1. Kosling s, Hintner M, Brandt S, Schulz T, Bloching M. Mucoceles of the sphenoid sinus. *Eur J Radiol* 2004;51:1-5
2. Hung-Wen Kao, Chung-Ping Lo, Yi-Chin Hsu, Ying-Chun Chiu, Chih-Hsien Hsiao and Cheng-Yu Chen. Sphenoid sinus mucocele presenting with Optic canal syndrome. *J Med Sci* 2006;26(2):061-064
3. Soon SR, Lim CM, Sethi DS. Sphenoid sinus mucocele:10 cases and literature review. *J Laryngol Otol*. 2010; 124(1):44-7
4. Nugent GR, Sprinkle P, Bloor BM. Sphenoid sinus mucoceles. *J Neurosurg* 1970;32:443-451
5. Akan H, Cihan C And Celenk C. Dentomaxillofacial radiology 2004;33:342-344
6. Mafee MF, Carter BL. Nasal Cavity and paranasal sinus. In:Valvassori GE, Mafee Mf, Carter BL(eds). *Imaging of the head and neck*. New York:Thieme;1995, pp 286-288
7. Stankiewicz JA. Sphenoid sinus mucocele. *Arch Otolaryngol Head Neck Surg*. 1989 Jun;115(6):735-40
8. Nagatani T, Saito K, Yoshida J. Treatment of a sphenoid sinus mucocele using an endoscope combined with a navigating system: a case report. *J Clin Neurosci*. 2001 Sep;8(5):456-60