

LIGHT WEIGHT HOLLOW DENTURE – A CASE SERIES

Laxman Singh Kaira¹, Krishan Singh Negi², Shalini Parihaar³, Rahul Bisht⁴

¹Assistant Professor, ²Associate Professor, ⁴Senior Resident, Department of Dentistry,
Veer Chandra Singh Garhwali Government Medical Sciences and Research Institute, Srinagar Garhwal, Uttarakhand,
³Private Practitioner, Lucknow, Uttar Pradesh

Correspondence:

Laxman Singh Kaira,

Faculty Residence, Flat No. 4, Type 2, Veer Chandra Singh Garhwali Government Medical Sciences and Research Institute,
Srinagar Garhwal, Uttarakhand

Mobile : +91 87559 02525 E-mail : laxmansingh6@gmail.com

Abstract :

It is the prosthodontist's responsibility to fabricate a prosthesis incorporating stability, retention and support which ultimately provide satisfaction to the patient. But in the certain conditions such as long lip length or severely resorbed ridges with increased inter ridge distance, the weight of a maxillary denture is often a dislodging factor. Hence, a light weight denture is required for better retention. This article describes 2 case reports of completely edentulous patient successfully rehabilitated with a hollow denture where a simplified technique of fabricating a light weight maxillary denture was used.

Keywords: Dental education, dental health, dental health promotion, tooth loss

Introduction :

Physiological, esthetic and functional variables are associated with successful conventional complete denture therapy. Despite the development of dentures supported by osseointegrated implants; rehabilitation of resorbed residual ridges is still a challenge. Conventional restoration of the severely atrophied mandibular ridge has sparked a number of designs to accommodate patients who have difficulty wearing a mandibular denture. The success of a complete denture relies on the principles of retention, stability and support. The prosthodontist's skill lies in applying these principles efficiently in critical situations. Severely resorbed maxillary edentulous ridges that are narrow and constricted with increased inter ridge space provide decreased support, retention and stability. The consequent weight of the processed denture only compromises them further. This article describes a case

report of an edentulous patient with resorbed ridges where a simplified technique of fabricating a light weight maxillary complete denture was used for preservation of denture bearing areas. It is

obvious that in large maxillofacial defects and in severe resorption of the edentulous ridges, there is a decreased denture bearing area for support, retention and stability. Increased interridge space compounds this problem. To decrease the leverage, reduction in the weight of the prosthesis was recommended and was also found to be beneficial. Reducing the weight of a maxillary prosthesis has been shown to be beneficial when constructing an obturator for the restoration of a large maxillofacial defect^{1,2}. It has also been proved that prosthesis weight can be reduced by making the denture base hollow. Different approaches like using a solid 3-dimensional spacer, including dental stone¹⁻⁶, silicone putty^{7,8}, modelling clay^{9,10}, or cellophane wrapped asbestos¹¹ have been used during laboratory processing to exclude denture base material from the planned hollow cavity of the prosthesis.

Holt⁷ processed a shim of acrylic resin over the residual ridge and used a spacer (Insta-mold; Nobilium, Albany, NY). The resin was indexed and the second half of the denture processed against the spacer and shim. The spacer was then removed and the 2 halves luted with autopolymerized acrylic resin using the indices to facilitate positioning. The primary disadvantage of such techniques is that the junction between the 2 previously polymerized portions of

Access this article online

Quick Response Code



the denture occurs at the borders of the denture. This is a long junction with an increased risk of seepage of fluid into the denture cavity increasing the risk of leakage. Fattore et al.¹² used a variation of a double flask technique for obturator fabrication by adding heat polymerizing acrylic resin over the definitive cast and processing a minimal thickness of acrylic resin around the teeth using a different drag. Both portions of resin were then attached using heat-polymerized resin.

O'Sullivan et al.¹³ described a modified method for fabricating a hollow maxillary denture. A clear matrix of trail denture base was made. The trail denture base was then invested in the conventional manner till the wax elimination. A 2 mm heat polymerized acrylic resin shim was made on the master cast using a second flask. Silicone putty was placed over the shim and its thickness was estimated using the clear template. The original flask with the teeth was then placed over the putty and shim and the processing was done. The putty was later removed from the distal end of the denture and the opening was sealed with autopolymerizing resin. Though this technique was useful in estimation of the spacer thickness, but removal of putty was found to be difficult especially from the anterior portion of the denture. Moreover, the openings made from the distal end had to be sufficiently large to retrieve the hard putty. In this case reports, two edentulous male patients with severely resorbed ridges and increased inter-ridge distances were treated with a hollow maxillary denture, using common salt and putty as spacer has been described.

Case Report 1 :

A 55-year-old patient walked into the outpatient department of prosthodontics with a chief complaint of replacing missing teeth. He had been edentulous for 10 years and had been wearing dentures for 7 years. On examination, he had severely resorbed ridges, the upper being narrow and constricted and with an interridge space of 32 mm. Both maxillary and mandibular ridges were severely resorbed (Figure 1). His upper lip was long, the inter-ridge distance was more than normal and vertical

dimension of occlusion (VDO) and vertical dimension at rest (VDR) were more than average. The previous denture of the patient was heavy with attrited teeth and was under extended. Hence, it was decided to fabricate a new set of denture for the patient.

The treatment options for complete denture available to the patient were:

- a. Implant supported complete denture
- b. Conventional Complete denture
- c. Hollow maxillary complete denture and conventional mandibular complete denture.

After analysing each available option, it was decided to fabricate hollow maxillary complete denture. The patient also approved of the treatment modality as it was light in weight, inexpensive and non-surgical procedure.

Technique:

Preliminary and final impressions were made in conventional manner. At the time of jaw relation due consideration was given to adjust maxillary occlusal rims properly as to provide proper aesthetics to the patient with long upper lip. Teeth were selected and arranged in balanced occlusion and try-in was done first for anterior teeth and then for posterior teeth. All the procedures were carried out by conventional method till the dewaxing stage. After dewaxing

Half of the heat cure PMMA (Trevalon, Dentsply India Pvt. Ltd., Gurgaon, India) in dough stage was positioned accurately over the dewaxed mould and then salt crystals were placed over it.

(Figure 2 &3)

Above that, the remaining heat cure resin was packed and cured at 74 degree C for 7-8 hours. Cured denture was retrieved and 3 holes were made in the thickest palatal area (Figure 4). All the residual salt crystals were removed by flushing water with the high pressure syringe through the holes. After making sure that all the salt crystals have been removed, the escape holes were closed with autopolymerizing resin (Trevalon, Dentsply India Pvt. Ltd.,

Gurgaon, India). The hollow cavity seal was verified by immersing the denture in water, if no air bubbles are evident, an adequate seal is confirmed (Figure 5). The dentures were inserted in the patient's mouth and instructions regarding care, hygiene and maintainance were given (Figure 6).

Case report 2 :

A 65-year-old patient walked into the department of prosthodontics with a chief complaint of chronic stomach upset due to inability to eat properly. Patient was taking antacids for the same. He had been edentulous for 3 years and had been wearing dentures for 2 years. Artificial teeth were severely attrited. The lower denture was broken & was repaired. Intraoral examination revealed a severely resorbed upper ridge (Figure 7). So as an alternative the patient was treated with a hollow complete maxillary denture. Till the dewaxing stage all steps were same as in conventional denture. After dewaxing Half of the heat cure PMMA (Trevalon, Dentsply India Pvt. Ltd., Gurgaon, India) in dough stage was positioned accurately over the dewaxed mould and then polyvinylsiloxane is mixed and were placed over it (Figure 8) . Above that, the remaining heat cure resin was packed and cured at 74 degree C for 7-8 hours. Two small openings were made with a bur into the denture base distal to most posterior teeth to remove the spacer (Figure 9 & 10). The polyvinylsiloxane was then removed by scraping with a sharp instrument. The cavity was cleaned and disinfected. Later, these openings were closed with the autopolymerizing resin (Trevalon,Dentsply,Gurgaon) in dough stage. The dentures were then polished in usual manner. The sealing of the cavity was then verified by placing it in water and checked for any bubbles (Figure 11). The dentures were inserted in the patient's mouth and instructions were given (Figure 12).

Discussion :

Rehabilitation of patient with severely resorbed ridges and long lip length is a challenge to the dentist. Even though, the choice for rehabilitation can be implant supported overdenture, and ridge augmentation but many a times the patient who come with such a problem are geriatric

patients with systemic illness, economic constrains, possess reluctance for a long. duration treatment procedure and unwillingness for any kind of surgical procedure. Hence, the best way is to rehabilitate them with the conventional way. Apart, from modifying the impression technique to get maximum denture bearing area, modifying the type of denture may also be better accepted by the patient. In general, a conventional (heavy) denture whether maxillary or mandibular is likely to cause poor denture bearing ability. Extensive volume of the denture base material in prosthesis provided to patients with large maxillofacial defects or severe residual ridge resorption is always a challenge to prosthodontists. To increase the retention and stability of heavy prosthesis, many methods have been tried like utilising the undercuts, modifying the impression technique, use of magnets, use of implants, etc.¹⁴

The first technique has advantages over the second technique. The salt crystals being heat labile melt during the curing procedure and thorough flushing after curing results in no crystals remaining in the denture thereby maintaining the integrity of the denture, avoiding the tedious effort to remove the spacer material from the denture. This technique of lost salt technique is simple to execute and utilizes a very cheap and easily available spacer material.

The technique 2 described has advantages for hollow denture fabrication. Leakage and difficulty in gauging resin thickness are problems inherent in. The procedures described in this article overcome these problems. Heat-polymerizing portion of the denture against polymerized resin may reduce leakage at the junction of the portions of the denture. The small window in the cameo surface facilitates recovery of the spacer in an area that is not commonly adjusted after denture insertion and has a small margin along which leakage could occur. The Silicone putty is used as a spacer advantages, including its stability, its ability to be carved, and the fact that it does not adhere to acrylic resin. The cyanoacrylate bond between the resin and the putty may be easily removed.

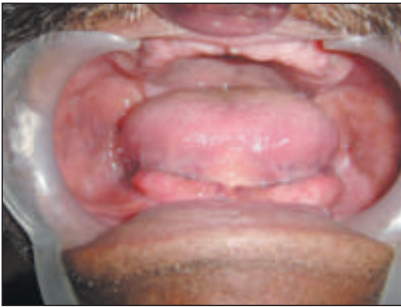

Figure 1 Preoperative photograph

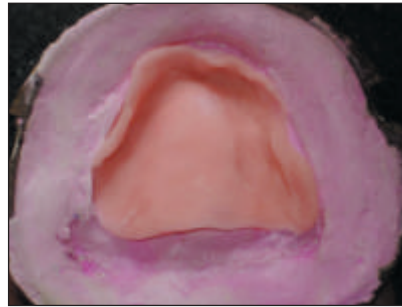

Figure 2 heat cure packing

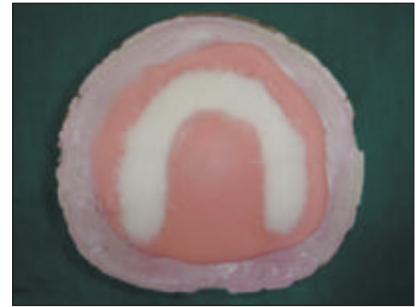

Figure 3 salt placement over heat cure

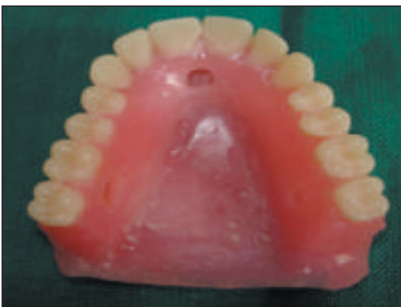

Figure 4 holes were made in polished surface

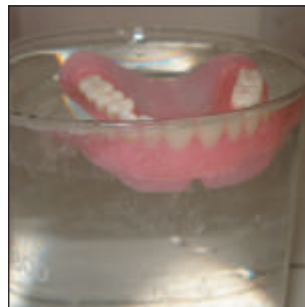

Figure 5 Hollow denture

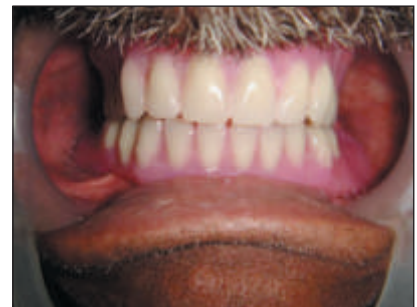

Figure 6 Postoperative photograph

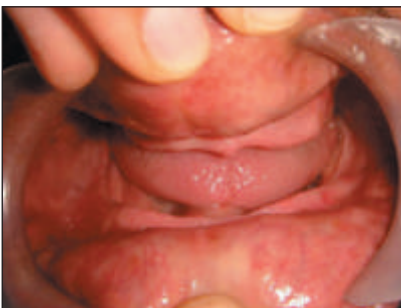

Figure 7 Preoperative view

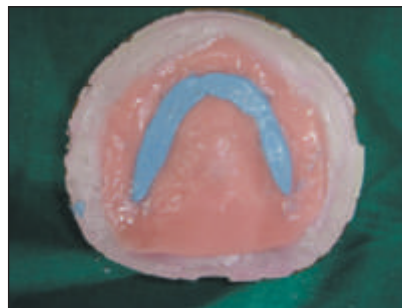


Figure 8 Putty placement

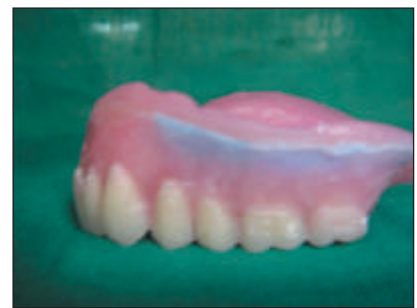

Figure 9 Cured denture

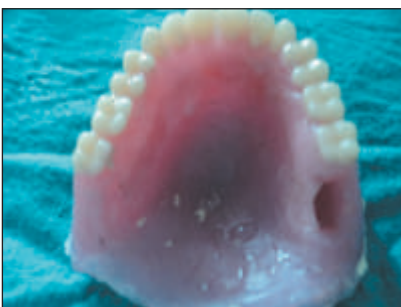

Figure 10 Holes were made in posterior region

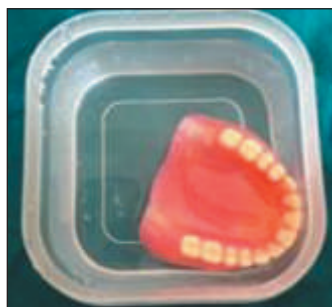

Figure 11 Hollow denture

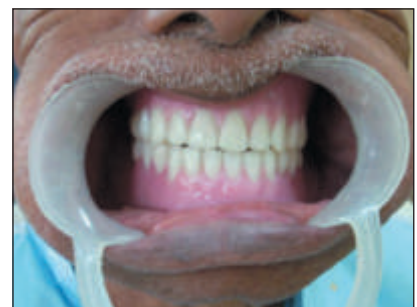

Figure 12 Happy patient

Summary :

Rehabilitation of severely resorbed ridges is a challenge to the prosthodontist. Even though, the choice of rehabilitation can be overdentures, implant retained overdentures, ridge augmentation, etc., many a times the patients who comes with such a problem are geriatric

patients with many systemic illness. Hence, the best way is to rehabilitate them with conventional complete dentures. Apart, from modifying the impression technique to get maximum denture bearing area, modifying the type of denture also may be better accepted by patients. Hence, less denture weight provides for healthy and comfortable living.

References

1. El Mahdy AS. Processing a hollow obturator. *J Prosthet Dent* 1969;22:682-6.
2. Brown KE. Fabrication of a hollow bulb obturator. *J Prosthet Dent* 1969;21:97-103.
3. Ackerman AJ. Prosthetic management of oral and facial defects following cancer surgery. *J Prosthet Dent* 1955;5:413-32.
4. Nidiffer TJ, Shipman TH. Hollow bulb obturator for acquired palatal openings. *J Prosthet Dent* 1957;7:126-34.
5. Rahn AO, Boucher LJ. *Maxillofacial prosthetics: principals and concepts*. St. Louis. Elsevier; 1970, p.95
6. Chalian VA, Barnett MO. A new technique for constructing a one-piece hollow obturator after partial maxillectomy. *J Prosthet Dent* 1972; 28: 448-53.
7. Holt RA Jr. A hollow complete lower denture. *J Prosthet Dent* 1981; 45:452-4
8. Jhanji A, Stevens ST. Fabrication of one-piece hollow obturators. *J Prosthet Dent* 1991; 66:136-8.
9. DaBreo EL. A light-cured interim obturator prosthesis. A clinical report. *J Prosthet Dent* 1990; 63:371-3.
10. Elliott DJ. The hollow bulb obturator: its fabrication using one denture flask. *Quintessence Dent Technol* 1983; 7:13-4.
11. Worley JL, Kniejski ME. A method for controlling the thickness of hollow obturator prostheses. *J Prosthet Dent* 1983; 50:227-9.
12. Fattore LD, Fine L, Edmonds DC. The hollow denture: an alternative treatment for atrophic maxillae. *J Prosthet Dent* 1988; 59:514-6.
13. O'Sullivan M. The hollow maxillary complete denture: A modified technique. *J Prosthet Dent* 2004; 91:591-94.
14. Kalavathy N, Shetty MM, Premnath, Pawashe K, Patel R KV: Hollow mandibular complete denture - A case report. *SRM University Journal of Dental Sciences*, 2010;1(3): 243-246.