

Case Report

LUMBAR EXTRADURAL SPONTANEOUS HEMATOMA WITH ACUTE PARAPARESIS

Deepak Hegde¹, H.R. Rai², Lawrence John Mathias³, Vinay Kumar C.⁴

¹ Assistant Professor, ^{2&3} Professors, ⁴ Resident

Department of Orthopaedics, K. S. Hegde Medical Academy, Nitte University, Deralkatte, Mangalore - 575 018, India.

Correspondence:

Deepak Hegde

Department of Orthopaedics, K. S. Hegde Medical Academy, Nitte University, Deralkatte Mangalore - 575 018, India.

E-mail : deepakortho123@rediffmail.com

Abstract :

Introduction: Primary epidural hematomas or "hematorrachis" are rare and less frequent in the lumbar region. It presents with acute onset of severe back pain and rapid development of signs of compression

Objective: To report a case of lumbar extradural spontaneous hematoma with acute paraparesis.

Case Report: A 65 year old male presented with acute back ache of 2 weeks duration with Radicular pain and numbness of both feet. He had progressive asymmetrical weakness of the lower extremities without bowel/bladder involvement and inability to walk. Radiograph of spine shows Grade 1 listhesis of L4-L5. MRI of LS Spine s/o synovial cyst at L2-L3 level. Left Facet joint arthropathy L2-L3. Patient underwent L2 laminectomy with removal of synovial cyst and hematoma

Results: The patient had motor improvement of grade 3 power in hip and knee flexors and EHL AND EDL. 3 months follow up showed grade 4 of all lower limb muscles with sensory numbness present on L3-L4 and L4-L5.

Conclusion: Spontaneous spinal extradural hematoma should be suspected in any patient who complains of local or referred spinal pain associated with acute limb weakness, sensory deficits, with or without cauda equina symptoms.

Introduction :

Primary epidural hematomas or "hematorrachis" are rare and less frequent in the lumbar region. It presents with acute onset of severe back pain and rapid development of signs of compression of cord.

Case report :

A 65 year old male presented with acute back ache of 2 weeks duration with Radicular pain and numbness of both feet. He had progressive asymmetrical weakness of the lower extremities without bowel/bladder involvement and inability to walk. No constitutional symptoms/trauma/systemic illness. He was a known alcoholic and smoker. On evaluation of the spine no deformity and paraspinal region normal.

Neurology : Upper limbs

:normal, Straight leg raising test: bilateral free, Lower limbs :hip and knee -3/5, Ankle dorsiflexion-0/5, Plantar flexion-1/5, Toes-1/5. Sensations were reduced over L3-L4, L5-S1 dermatome bilaterally. Deep tendon reflexes were absent and Bilateral plantar reflexes were equivocal.

Investigations :

Blood investigations: Bleeding profile is normal. Liver function tests are normal. Radiograph of spine shows Grade 1 listhesis of L4-L5. MRI of LS Spine s/o synovial cyst at L2-L3 level. Left Facet joint arthropathy L2-L3.

Treatment :

Patient underwent L2 laminectomy with removal of synovial cyst and hematoma. The synovial cyst located on the left facet joint was removed. A large hematoma measuring about 3x4cm was present extradural compressing the spinal cord with adhesion over the dura was seen. A brownish red mass dorsally extending from L1 to L2 compressing the dura & cord was present. There was no

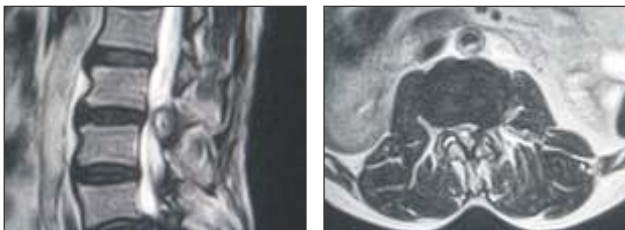
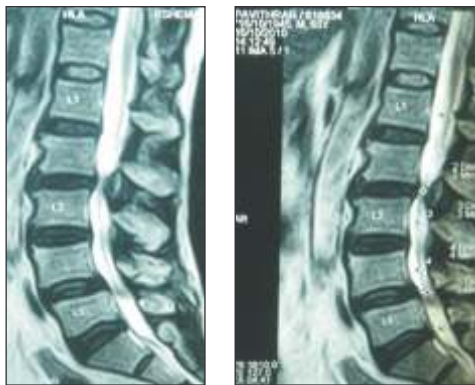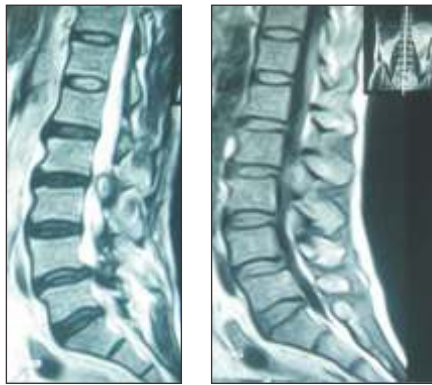Access this article online

Quick Response Code

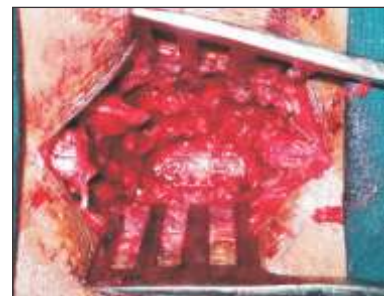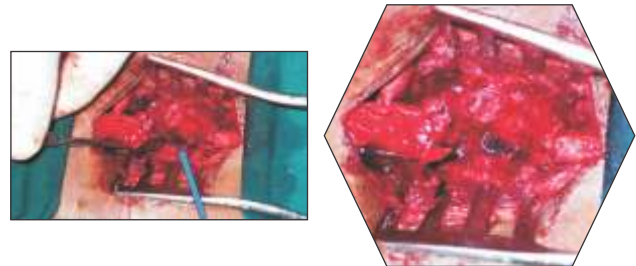
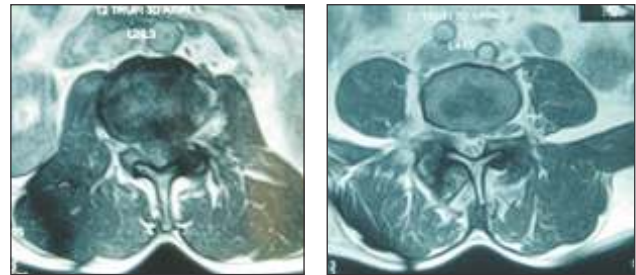
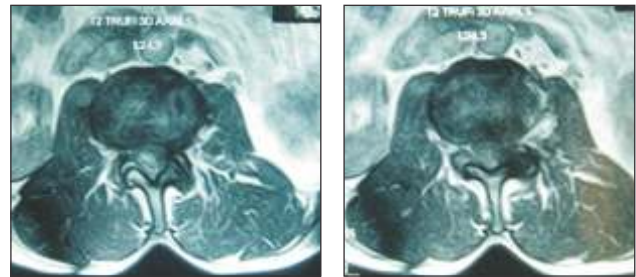


active bleeding and no osseous involvement .The material was sent for biopsy. Histopathology shows hematoma, fibrous tissue and no evidence of tumour or synovial cells.

SAGITAL IMAGES



L2-L3 T2 TRUFI AXIAL IMAGES



POST EVACUATION

Postoperatively the patient had motor improvement of grade 3 power in hip and knee flexors and EHL AND EDL. 3 months follow up showed grade 4 of all lower limb muscles with sensory numbness present on L3-L4 and L4-L5.

Conclusion :

Spontaneous spinal extradural hematoma should be suspected in any patient who complains of local or referred spinal pain associated with acute limb weakness, sensory deficits, with or without cauda equina symptoms.

Discussion :

Spontaneous Spinal Extradural Hematoma

"Hematorrachis".First case was seen in 1897, William Bain.It is a rare entity.It has a frequency of < 1% of spinal space-occupying lesions.AETIOLOGY: Acute onset of severe back pain with rapidly develop signs of compresion of cord or cauda equina.Predisposing factors include hemophilia,coagulopathy, anticoagulation (25%–70% of cases), vascular anamoly, Paget's disease .In many reports , spinal epidural hematomas develop in various traumatic

conditions, including lumbar punctures, epidural anaesthesia, missile injury, fall down, being struck in the back by objects, spinal manipulation treatment and other blunt trauma of the back area. The pathogenesis of spinal epidural hematoma remains unknown. Some authors have suggested that spinal epidural hematoma may have developed due to bleeding from rupture of spinal epidural artery resulting from sudden stretching of these vessels. Others have advocated that spinal epidural hematoma might have originated from the epidural venous plexus. The veins in epidural venous plexus are composed of thin valve-less vessels. Therefore the veins may be vulnerable to rupture in conditions of sudden change in venous pressure. Diagnosis of spinal epidural hematoma is usually made using computed tomography scan or MRI. MRI in particular is critical for diagnosis of spinal epidural hematoma. MRI demonstrates location and extent of hematoma, degree of cord compression and provides the surgeon with the necessary information to plan

appropriate management for this condition. MRI can also differentiate between various potential causes of neurologic deficits in patients with spinal injuries, such as traumatic disc rupture, spinal cord edema, spinal cord contusion, spinal canal encroachment by fractured bony fragment and spinal subdural or subarachnoid haemorrhage. Prompt surgical evacuation of hematoma with laminectomy has been regarded as standard treatment for symptomatic spinal epidural hematoma. Critical factors related to outcome are the preoperative neurological deficits, the time interval from the onset of symptoms to surgical decompression, the duration of complete neurologic symptoms and the intramedullary signal intensity on the MRI. In our case, we prepared for emergent evacuation of the spinal epidural hematoma by multilevel laminectomy after the MRI. However, the patient's neurologic symptoms, especially paraplegia, improved rapidly about 24 hours after the onset of initial symptoms with surgical interventions.

References :

1. Bain, W: A Case of Hemorrhachis. Brit. Med. Jour., 2, 455, 1897.
2. Hopkins, S. D.: Extradural Spinal Meningeal Hemorrhage. N. Y. Med. Jour., 70, 296, 1899.
3. Facet cyst haematoma in the lumbar spine: a report of four cases. N Miyatake, T Aizawa, H Hyodo, H Sasaki, T Kusakabe, T Sato. Journal of Orthopaedic Surgery 2009; 17(1):80-4
4. "Spontaneous Epidural Hematoma Presenting as Paraplegia": A Case Report. Agarwal S, Levy J, Capulong & E Weiss DL. Arch Phys Med Rehabil Vol 86, 2; 2005
5. "Acute Spontaneous Spinal Epidural Hematoma Causing Cauda Equina Syndrome": A Case Report. Park DS, Moon KJ, Lee SJ, Juhng SK, & Park GY. Arch Phys Med Rehabil Vol 76, 2; 1995
6. "Primary cavernous hemangioma of epidural space with compressive features": A rare entity
7. Kumar A et al. J. Spinal Surg. Vol 2; (1) July 2010
8. Kim IY, Kim SH, Kim JH, et al. Rapid spontaneous resolution of a traumatic cervical epidural hematoma. Br J NeuroSurg 2005; 19:451-2