

# ELLIS VAN CREVELD SYNDROME WITH PARTIAL ATRIOVENTRICULAR CANAL DEFECT, PERSISTENT LEFT SUPERIOR VENA CAVA, DUAL CORONARY SINUS OSTIAE - A CASE REPORT

Mundayat Gopalakrishnan<sup>1</sup>, Manjunath Kamath<sup>2</sup>,  
Krishna Prasad Patla<sup>2</sup> & Kodangala Subramanyam<sup>3</sup>

<sup>1</sup>Division of Cardiovascular and Thoracic Surgery, <sup>2</sup>Division of Cardiac Anaesthesiology, <sup>3</sup>Division of Cardiology, K.S. Hegde Medical Academy, Nitte University, Mangalore - 575 018, Karnataka, India

Correspondence:

Mundayat Gopalakrishnan,  
4C, KSHEMA Staff Quarters, Mangalore 575018, Karnataka, India.  
Tel : +91 824 2204747, Fax : +91 824 2204162  
E-mail : drmgk23@hotmail.com

## Abstract:

Ellis van Creveld syndrome (EVCS) is a congenital defect with skeletal and cardiac anomalies. We have operated on a 30 year old female with EVCS having single atrium, severe mitral and tricuspid regurgitation, bilateral superior venacavae, double coronary sinus ostiae. Anterior Mitral cleft repair, a tricuspid annuloplasty, rerouting of left superior venacava and septal patching were done. She made a smooth recovery.

Keywords: congenital heart disease, partial AV canal defect

## Case Report :

Ellis van Creveld syndrome is a very rare clinical entity with skeletal and cardiac defects. We have operated on a patient with this condition having single atrium, mitral and tricuspid regurgitation, left superior vena cava, dual coronary sinus ostiae

A 30 year old female with polydactyly was having echo features of large single atrium, mitral and tricuspid regurgitation, mild pulmonary hypertension. An intraoperative trans- esophageal echocardiogram (TEE) was consistent with the previous Echo findings. A midline sternotomy was done. The pulmonary artery, right atrium, right ventricle were dilated. Left innominate vein was absent. There was a single atrium with a septal rim at the superior wall (Fig1)

Dual coronary sinus openings were seen with a ridge separating the two. One was in the normal anatomic location close to the septal tricuspid leaflet and other was near the posterior annulus of mitral valve. Left SVC was opening separately into left atrium. Mitral anterior leaflet cleft was identified.

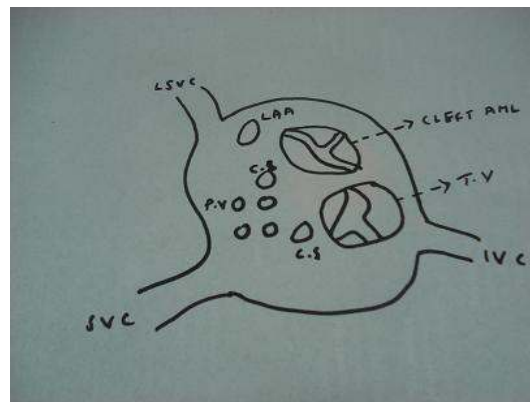


FIG: 1 LSVC-left Superior vena cava, SVC- Superior vena cava, IVC- Inferior vena cava, LAA-left atrial appendage, CS-coronary sinus opening, TV-tricuspid valve, AML- anterior mitral leaflet, PV-pulmonary vein

Mitral cleft repaired with interrupted simple 5<sup>0</sup> prolene sutures. Septal pericardial patch was inserted with interrupted sutures at the inter-valvar area and continuous sutures in the remaining region. Rerouting of LSVC into right atrium was done. Both the coronary sinus openings were left in the left atrium to avoid conduction problems. A small fenestration was made in the septal patch to decompress the atrial chambers in the event of residual incompetence. A DeVega annuloplasty was done on tricuspid valve. Intraoperative TEE revealed trivial MR, TR,

good septal patching with trivial left to right shunting.

The patient made an uneventful recovery. Postoperative Echo revealed trivial MR, trivial TR, no tricuspid stenosis, trivial left to right shunt. She has come for postoperative review at 10 weeks and 2 years with echo showing similar findings and the flow through the fenestration in septal patch almost ceased.

Comments :

EVCS is a rare genetic disorder which involves numerous anomalies including post-axial polydactyly, congenital heart defects (most commonly an atrial septal defect with common atrium), pre-natal tooth eruption, fingernail dysplasia, and malformation of the wrist bones. It has got autosomal recessive inheritance.

There are only few reports of cardiac surgical repairs done for this condition. Our patient had postaxial polydactyly, nail dystrophy and cardiac defects. The presence of dual coronary sinus openings has not been reported previously. The immediate surgical result has been good. She needs follow up to detect late atrioventricular valve regurgitation.

References :

1. Haci A , Cüneyt K, Kemal B, Kolbakir F, Ellis-van Creveld Syndrome Associated With Thymic Hypoplasia, *Asian Cardiovasc Thorac Ann* 2002;10:336-338
2. Gianluca B , Antonio A, Gabriele R, Sergio F, Stephen P. S, Di Donato RM, Double-Outlet Right Atrium: Anatomic and Clinical Considerations, *Ann Thorac Surg*; 2007;83:619-621
3. Özcan Ö, Kemal A, Hasan T, Özgür T, Goldenhar's Syndrome; *Asian Cardiovasc Thorac Ann* 2002; 10:267-269

There is one report of a 16-month-old girl with the classic signs of this syndrome along with thymic hypoplasia. Mitral clefts were repaired by direct suturing. The single atrium was repaired by creating a new septum with a pericardial patch, leaving the coronary sinus in the left atrium (1). In another series, Double-outlet right atrium (DORA) was described in which the right atrium empties into both ventricles. Eleven patients survived the surgical repair, the only death occurred in the lone patient with Ellis van Creveld syndrome (2)

There is a case report of a 12-year-old male with postaxial polydactyly on the right hand, congenital heart disease and facial asymmetry. Investigations confirmed the diagnosis of a congenital disease, Goldenhar's syndrome (3). Features of this resembles EVCS except for the gross facial asymmetry and autosomal dominant inheritance

There was one case of EVCS with polydactyly and atrioventricular canal defect in a series of 61 cases of atrioventricular canal defects (4). There was another one case among 72 cases of atrioventricular canal defects (5)

4. Toshifumi M, Takehiro K, Jun-ichi O, Toshihide A, Jun et al, Left atrioventricular valve regurgitation after repair of incomplete atrioventricular septal defect' *Ann Thorac Surg* 2004, 77: 2157-2162
5. Reddy VM, McElhinney DB, Brook MM, Parry AJ et al, Atrioventricular valve function after single patch repair of complete atrioventricular septal defect in infancy: How early should repair be attempted?; *J Thorac Cardiovasc Surg* 1998; 115: 1032-1036