

LIPOSARCOMA OF SPERMATIC CORD PRESENTING AS INDIRECT INGUINAL HERNIA- A RARE CASE REPORT

Padma Shetty K, Harish S. Permi, Michelle Mathias, Kishan Prasad, Teerthanath S, Jayaprakash Shetty K, Department of Pathology, K.S. Hegde Medical Academy of Nitte University, Deralakatte, Mangalore, Karnataka, India.

Correspondence:

Harish S. Permi,

Assistant Professor, Dept of Pathology, K.S. Hegde Medical Academy of Nitte University, Deralakatte, Mangalore, Karnataka (State), INDIA (Country). Mobile No : 99641 31827 E-mail : drharish01@gmail.com

Abstract:

Liposarcoma in the inguinal region though rare are clinically significant lesions. Preoperative diagnosis is difficult since the clinical findings are very similar to that of inguinal hernia. We report a rare case of Liposarcoma of the spermatic cord in 85 year old male, clinically diagnosed as left sided indirect inguinal hernia. Surgical excision specimen showed multiple globular lipomatous masses which were yellowish and grey tan with areas of myxoid degeneration and necrosis seen. Microscopic examination showed adipocytes arranged in lobules with numerous blood vessels, lipoblasts and myxoid stroma confirming the diagnosis of myxoid liposarcoma. He is on regular follow up since two years without any recurrence or metastasis. Our case report highlights the importance of sampling and examination of fatty masses in the inguinal region to rule out the possibility of liposarcoma as they are mistaken for lipoma at surgery.

Keywords : Liposarcoma, spermatic cord, indirect inguinal hernia.

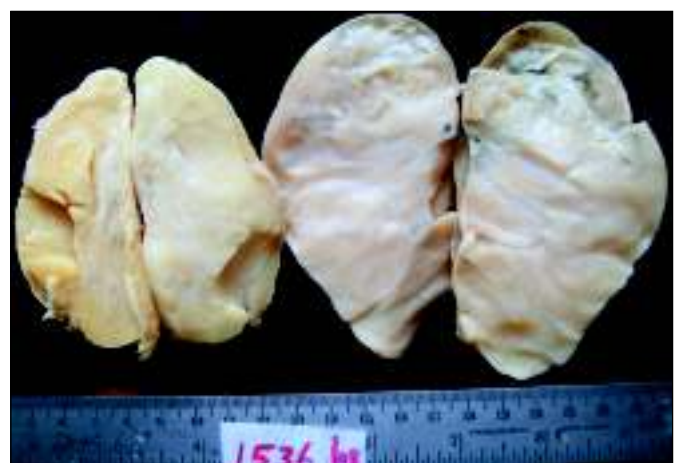Introduction

Liposarcoma is a malignant mesenchymal tumor of the adipose tissue. ⁽¹⁾ Its incidence in the paratesticular region is very low, varies from 10-12 percent of all soft tissue sarcoma between fifth and seventh decades. The two major sites of liposarcoma are the extremities, particularly the thigh and the retroperitoneum which account for about two-third of all cases. ⁽²⁾ Its clinical presentation characterized by symptom which is usually late and nonspecific. ⁽³⁾ They presumably have a good prognosis. Well differentiated Liposarcoma have no metastasis with high five year survival rates. ⁽⁴⁾ Since the inguinal region communicates with the retroperitoneum, liposarcoma in both the regions may be detected during hernia repair operations. ⁽⁵⁾ We report a rare case of liposarcoma of spermatic cord presented clinically with indirect inguinal hernia.

Case report

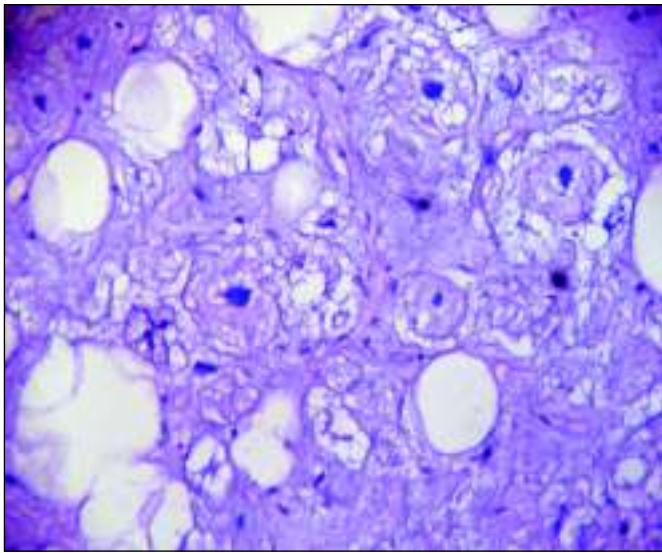
A- 85- yr old male presented with swelling and pain in the scrotal and left inguinal region since 1 year with sudden increase in the last two months. He was a known asthmatic and hypertensive on treatment. Local

examination showed swelling in the left scrotal region measuring 15x15 cms. The swelling was not reducible on lying down. It was tender and soft in consistency. Routine haematological, biochemical and serological investigations were within normal limits. Scrotal ultrasonography showed bilateral hydrocele with left inguinoscrotal hernia. The clinical diagnosis of bilateral hydrocele with left inguinal hernia was made and treated surgically for hydrocele and hernia. At operation, multiple diffuse lipomatous swellings were seen along the spermatic cord which were excised and sent for



Gross picture showing globular yellowish and grey tan lipomatous masses .

histopathological examination. Gross examination showed multiple globular lipomatous masses, larger measuring 12x7x6 cms. Cut section of the lipomatous masses was yellowish and grey tan with areas of myxoid degeneration and necrosis seen. (Figure 1) Microscopic examination showed adipocytes arranged in lobules with numerous blood vessels and lipoblasts seen. (Figure 2)



Microscopy picture showing adipocytes arranged in lobules with numerous blood vessels and lipoblasts. (Hematoxylin and Eosin X 100)

The lipoblasts are large cell having cytoplasmic vacuolations indenting the pleomorphic nucleus. In the stroma there were scattered multinucleated floret like giant cells and atypical lipocytes. Foci of necrosis haemorrhage and myxoid change was also seen. Final diagnosis of myxoid Liposarcoma was considered. The postoperative course was uneventful. He was on regular follow up since two years without any recurrence or metastasis.

Discussion

Liposarcoma in the paratesticular region is rare representing 7-10% of intrascrotal masses. (6) Sarcomas account for 90% of malignant lesions of the spermatic

cord of which liposarcoma form approximately 3-7%. (6) They are most likely to involve the spermatic cord than the testicular tunis; occasionally there may be extension from retroperitoneal sarcomas. (4) Diagnosis of liposarcoma in the inguinal region preoperatively is not easy because unlike other sarcomas they have a long clinical history and on examination is diagnosed as inguinal hernia or lipoma at surgery (7). Histologically the differential diagnosis of liposarcoma is benign fatty tumors, fibromatosis, fibrosarcoma and malignant peripheral nerve sheath tumor (MPNST). The presence of atypical cells with large hyperchromatic nuclei within the fibrous septa or in the fat, variation in size of adipocytes and presence of lipoblasts favours the diagnosis of liposarcoma.(4) our case showed similar histological features. Low grade fibrosarcoma and malignant peripheral nerve sheath tumors are more cellular with a fascicular architecture. MPNST are at least focally S-100 positive.(4) The treatment of choice is radical orchidectomy with high ligation of the cord (8), while some recommend wide excision of the mass (7). Though some authors recommend radiation and chemotherapy for both primary and metastasis (9), the use of these treatment modalities is still controversial. (10) More than half of the cases of paratesticular well differentiated Liposarcoma showed recurrence with progression to low or high grade dedifferentiation in some of the recurrence. (4) Our patient was treated by surgical excision of the masses .On regular follow up since two years there was no recurrence or metastasis in our patient.

We conclude that awareness and histopathological confirmation of fatty masses in the inguinal region is necessary as Liposarcoma have prolonged clinical course with late recurrences.

References

1. Alejandro Garcia Morna, Juan Fermin Lozano Salinas, Federico Valdes Sepulveda, Homero Zapata, Lauro Salvador Gomez Guerra. Liposarcoma of the Spermatic cord; our experience and a literature review. *Actas Urologicas Espanolas* 2009; 33:811-5.
2. Channara Sookluan. Giant Retroperitoneal Liposarcoma Presenting as Indirect Inguinal Hernia. *J Parpakkiao Hosp Clin Med Educat Center* 2006; 22:151-7.
3. Hirofumi N, Yoshio N, Minoru H, Tomoki Y, Kaori S, Hirokazu U ,et al, Retroperitoneal Liposarcoma Presenting a Indirect Inguinal Hernia. *Acta Med. Okayama* 2001; 55:51-4.
4. Elizabeth Montgomery, Cyril Fisher. Paratesticular Liposarcoma-Clinicopathologic Study. *American Journal of Surgical Pathology* 2003; 27:40-7.
5. Elizabeth Montgomery, Robert Buras. Incidental Liposarcomas identified during Hernia repair operations. *Journal of Surgical Oncology* 1999; 71:503.
6. Panagis A, Karydas G, Vasilakakis J, Chatzipaschalis E, Lambropoulou M, Papadopoulos N. Myxoid Liposarcoma of the Spermatic Cord: A Case Report and review of the literature. *Int Urol Nephrol* 2003; 35:369-72.
7. Hirofumi Noguchi, Yoshio Naomoto, Minoru Haisa, Tomoki Yamatsuji, Kaori Shigemitsu, Hirokazu Uetsuka et al. Retroperitoneal Liposarcoma presenting as Indirect Inguinal Hernia. *Acta Med Okayama* 2001; 55:51-4.
8. Hassan J. M, Quisling SV, Melvin WV, Sharp KW. Liposarcoma of the Spermatic Cord masquerading as an incarcerated Inguinal Hernia. *Am J Surg Pathol* 2003; 69:163-5.
9. Kinne DW, Chu FC, Huvos AG, Yagoda A, Fortner JG: Treatment of primary and recurrent retroperitoneal liposarcoma. Twenty five year experience at Memorial Hospital. *Cancer* 1973 81, 53-64.
10. Weiss SW and Rao VK. Well differentiated liposarcoma (atypical lipoma) of deep soft tissue of the extremities, retroperitoneum and miscellaneous sites. A follow up study of 92 cases with analysis of the incidence of "dedifferentiation". *Am. J Surg. Pathol* 1992; 16: 1051-8.