


# Ulnar Shortening Osteotomy: Our Experience\*

## *Osteotomias de encurtamento da ulna: A nossa experiência*

Afonso Nobre Pinto Cardoso<sup>1</sup>  Rui Viegas<sup>1</sup> Patrícia Gamelas<sup>1</sup> Pedro Falcão<sup>1</sup> Carolina Baptista<sup>1</sup>  
Filipa Santos Silva<sup>1</sup>

<sup>1</sup>Department of Orthopedics and Traumatology, Hospital Beatriz Ângelo, Loures, Portugal

Rev Bras Ortop 2020;55(5):612–619.

Address for correspondence Afonso Nobre Pinto Cardoso, MD, Department of Orthopedics and Traumatology, Hospital Beatriz Ângelo, Av. Carlos Teixeira, 514, Loures, 2674, Portugal (e-mail: afonso.cardoso@hbeatrizangelo.pt).

### Abstract

**Objective** The objective of the present study was to evaluate the clinical and radiographic results of our series regarding ulnar shortening osteotomy, as well as to briefly review the pathology, indications and surgical options of ulnocarpal conflict.

**Methods** We performed a retrospective analysis of consecutive patients who were treated with ulnar shortening osteotomy between January 2012 and June 2017 at our hospital. We clinically evaluated pain, articular range of motion, grip strength and functional outcomes using the quick-DASH questionnaire. We radiographically measured the pre- and postoperative ulnar variance and the shortening performed.

**Results** We identified eight operated patients, and it was possible to evaluate seven of them. Pain decreased in this population (visual analogue scale [VAS] score changed from 7 to 2.6,  $p < 0.05$ ), there was a decrease in quick-DASH (64 to 28,  $p < 0.05$ ) and we found a decrease in the articular amplitude  $\sim 7^\circ$  for flexion ( $p = 0.2$ ), and of  $5.5^\circ$  for supination ( $p = 0.3$ ), as well as decreasing grip strength to about 86% on the contralateral side ( $p = 0.07$ ). The ulnar variance changed from a mean of +5.5 mm to -1.1 mm ( $p < 0.05$ ). Two out of 8 patients (25%) presented plaque-related symptoms and one of them underwent a new intervention to extract the material.

**Conclusions** Ulnar shortening osteotomy is an effective surgical procedure both in the treatment of ulnocarpal conflict and in the discharge of the ulna. The results presented agreement with other results published in the literature, with good clinical and radiographic results.

### Keywords

- ▶ osteotomy
- ▶ ulna
- ▶ wrist joint
- ▶ retrospective studies

### Resumo

**Objetivo** O objetivo do presente estudo foi avaliar os resultados clínicos e radiográficos da nossa casuística relativamente a osteotomias de encurtamento da ulna, bem como rever sumariamente a patologia, as indicações e as opções cirúrgicas do conflito ulnocárpico.

**Métodos** Realizamos uma análise retrospectiva de pacientes consecutivos que foram tratados com osteotomia de encurtamento da ulna entre janeiro de 2012 e junho de 2017 no nosso hospital. Avaliamos clinicamente a dor, amplitude articular, força da

\* Work carried out at the Department of Orthopedics and Traumatology, Hospital Beatriz Ângelo, Loures, Portugal.

**Palavras-chave**

- ▶ osteotomia
- ▶ ulna
- ▶ articulação do punho
- ▶ estudos retrospectivos

garra e resultados funcionais recorrendo ao questionário quick-DASH. Medimos radiograficamente a variância ulnar pré- e pós-operatória e o encurtamento realizado.

**Resultados** Identificamos oito pacientes operados, tendo sido possível avaliar sete destes. Nesta população, obtivemos uma diminuição da dor (escala analógica visual [VAS, na sigla em inglês] de 7 para 2.6,  $p < 0,05$ ), uma diminuição do quick-DASH (64 para 28,  $p < 0,05$ ) e constatamos uma diminuição da amplitude articular  $\sim 7^\circ$  para a flexão ( $p = 0,2$ ), de  $5,5^\circ$  para a supinação ( $p = 0,3$ ), bem como diminuição da força da garra para cerca de 86% do lado contralateral ( $p = 0,07$ ). A variância ulnar foi alterada de uma média de +5.5 mm para -1.1 mm ( $p < 0,05$ ). Dois em 8 pacientes (25%) apresentaram sintomatologia relacionada com a placa, sendo que um deles foi submetido a nova intervenção para extração do material.

**Conclusões** A osteotomia de encurtamento da ulna é um procedimento cirúrgico eficaz, tanto no tratamento do conflito ulnocárpico, como na descarga da ulna. Os resultados apresentados vão ao encontro aos demais publicados na literatura, tendo-se obtido bons resultados clínicos e radiográficos.

**Introduction**

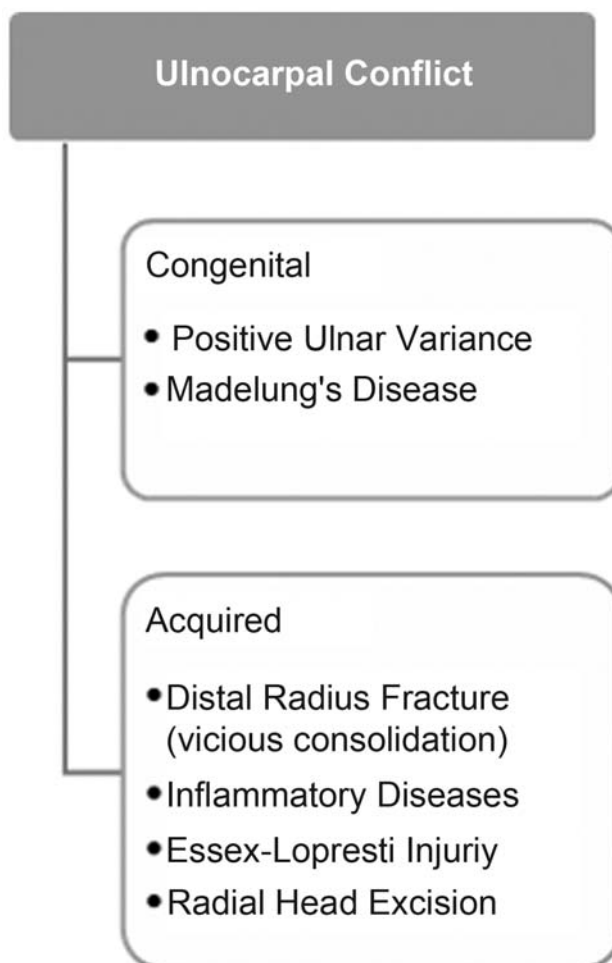
The ulnar side of the wrist is made up of several important overlapping anatomical structures, leading to complex differential diagnosis and various therapeutic options. In this context, it is often called the “black box” of the wrist.<sup>1</sup> These anatomical structures are essential to the balance between the need for stability to handle activities that require strength, and the need for mobility in activities that require articular range of motion.

Pain in this region may have many causes, whether acute, traumatic or chronic, degenerative. Common causes include isolated lesions of the triangular fibrocartilage complex (TFCC), of the lunotriquetral ligament, and ulnar conflict syndromes.<sup>1</sup> There are different types of ulnar conflict, including conflict associated with a semilunar type II of Viegas, radioulnar conflict, styloid-carpal conflict and, finally, ulnocarpal conflict (UC).<sup>2</sup>

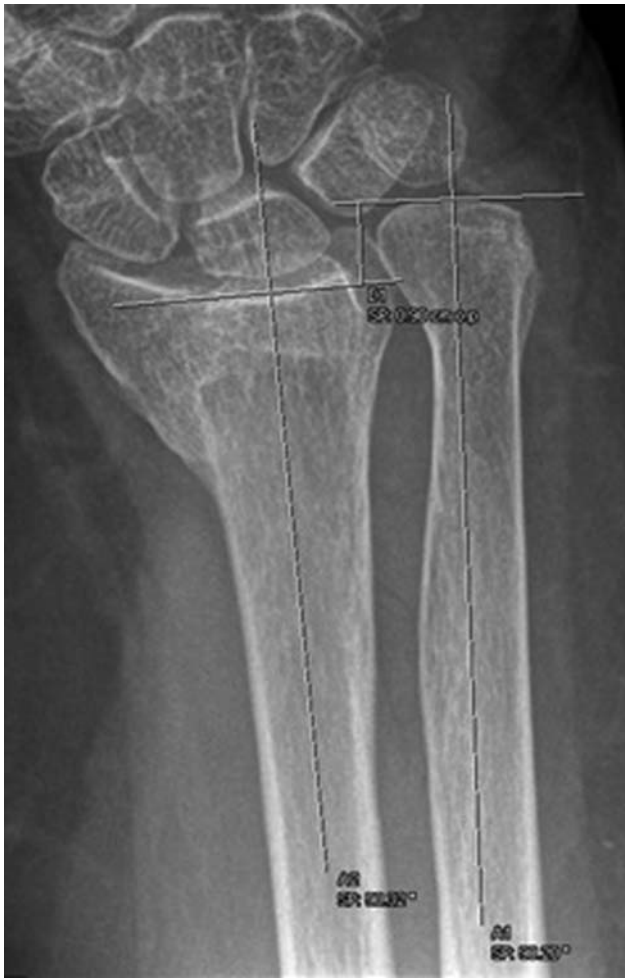Ulnocarpal conflict, or Ulnocarpal Impaction Syndrome, is characterized by being a degenerative pathology derived from the impact of the distal ulna with the pyramidal and the semilunar. This process can lead to ligament changes, chondromalacia of the pyramidal, of the semilunar or of the distal ulna.<sup>3</sup> The causes of UC are divided between constituent and acquired causes. (→ **Figure 1**).

The treatment of this condition involves conservative treatment or surgical treatment. Surgically, Milch<sup>4</sup> described a shortening osteotomy of the ulna to treat UC after distal radius fractures; this procedure often remains the treatment of choice, especially when there is a positive ulnar variance.<sup>4-7</sup>

With the present study, we intend to evaluate the clinical and radiographic results of our series regarding ulnar shortening osteotomy, as well as to briefly review the pathology, indications and surgical options of UC.



**Fig. 1** Causes of ulnocarpal conflict.



**Fig. 2** Measurement of preoperative ulnar variance. After drawing two lines perpendicular to the radius and ulna axis, the distance between them is measured.

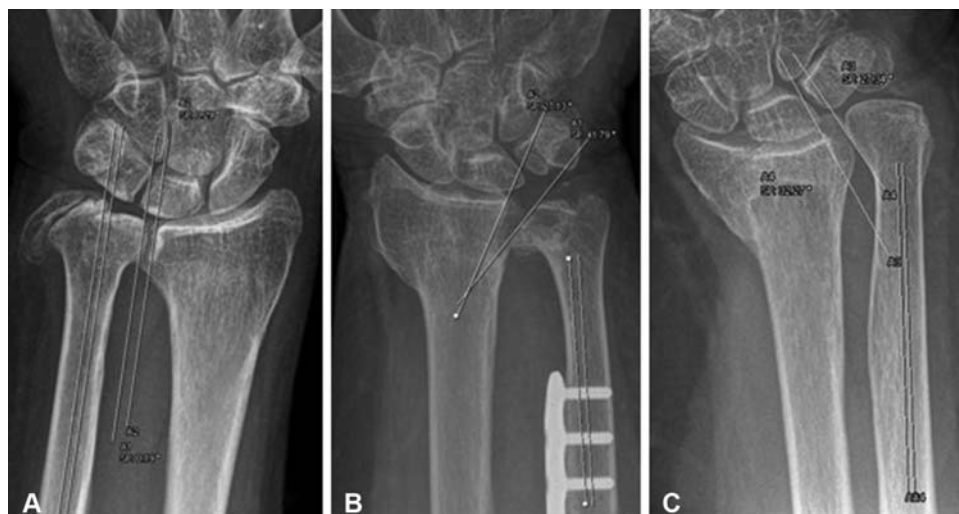## Material and Methods

After obtaining approval from the institutional ethics committee, we performed a retrospective analysis of consecutive

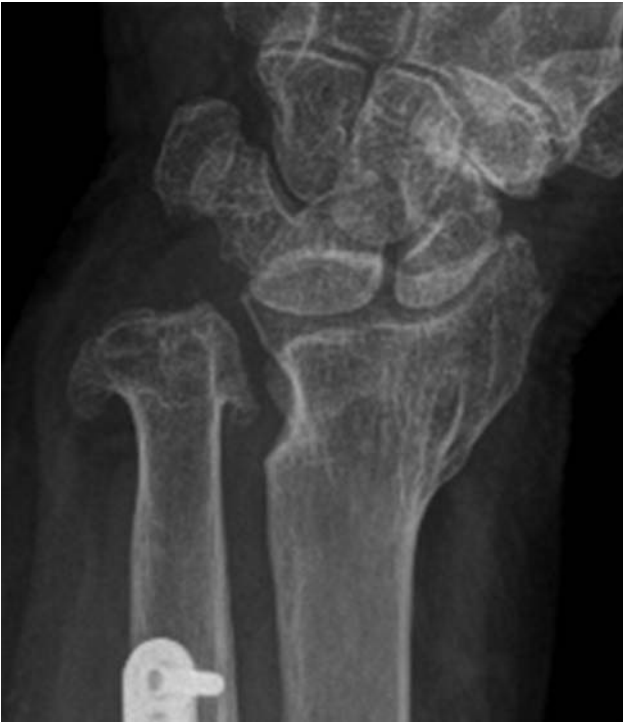patients who were treated with ulnar shortening osteotomy between January 2012 and June 2017 at our hospital. Of these eight patients, seven were available for further evaluation in the context of the present study. Most patients were female (7; 87.5%). The mean age was 61 years old (17–85 years old) with a mean follow-up of 18.9 months (5–50 months). The right side was affected in most cases (5 in 8 cases, 62.5%). The operated side was the dominant in 4 of the 7 cases (57%). Seven of the 8 patients (87.5%) had a history of previous fracture. The other case was a patient with idiopathic positive ulnar variance. The diagnosis was made using the clinic and radiographic evidence of UC and, when necessary, with confirmation of the diagnosis or investigation of additional diagnoses by wrist arthroscopy (3/8 patients, 37.5%), with treatment of associated injuries (TFCC lesions, type 2A).

Clinical outcomes were measured with a visual analog scale (VAS) for current pain, and for pain before the surgical procedure. The quick-disabilities of the arm, shoulder and hand (DASH) questionnaire was carried out, taking into account the current situation and the preoperative situation, in its Portuguese version.<sup>8</sup> The articular amplitude of the current wrist (extension, flexion, supination, pronation, ulnar deviation and radial deviation) was measured with the aid of a goniometer, and compared with the contralateral side. Current grip strength was measured with the aid of a BASELINE hydraulic hand-held dynamometer (Fabrication Enterprises Inc., White Plains, NY, USA) and compared with the contralateral side. Complications, current complaints and reinterventions were also recorded.

Pre- and postoperative mean ulnar variance and shortening were radiographically analyzed using the perpendicular method, based on the radiographs present in the electronic medical records of the patient (–Figure 2). The presence and evolution of degenerative changes and the type of distal radioulnar joint (DRUJ) were also recorded (–Figure 3). The obliquity of the distal radioulnar joint was analyzed and classified into 1 of 3 types<sup>9</sup> (–Figure 3). The relevance of this analysis is related to the fact that a type III joint,



**Fig. 3** Evaluation of the distal radioulnar joint type: in type I (A), the sigmoid cavity of the radius and the respective joint portion of the ulna are parallel to the ulna axis. In type II (oblique) (B), these surfaces are oblique toward the ulna; and in type III (reverse oblique) (C), this angle moves away from the ulna.



**Fig. 4** Degenerative changes of distal radioulnar joint after ulna shortening osteotomy.

when submitted to a shortening osteotomy, has a higher probability of progressing to arthrosis, and it is therefore considered a relative contraindication for this procedure<sup>10</sup> (► **Figure 4**).

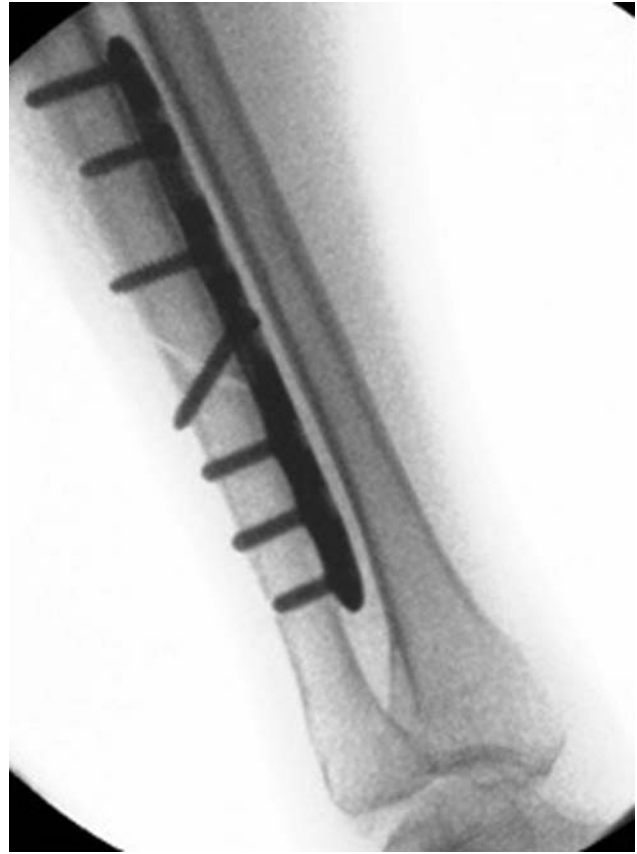Data means were compared and analyzed using the Student t-test for paired samples, or the Wilcoxon test, depending on the normality of the data. Correlation between data was analyzed with the Spearman correlation coefficient. Data normality was tested with the Shapiro-Wilk test. P-values < 0.05 were considered significant. The dedicated statistical software IBM SPSS Statistics for Windows, version 21 (IBM Corp., Armonk, NY, USA) was used.

### Surgical Technique

Surgical planning begins with the evaluation of the wrist radiographs of the patient. The desired degree of shortening of the ulna is calculated based on the posteroanterior radiograph, aiming to achieve a - 2mm variance after surgery (► **Figure 2**). If the patient has a TFCC symptomatic lesion, or a suspected diagnosis, we complement the arthroscopic ulnar approach with appropriate treatment of the lesions found.

Regarding the path of approach, we conducted a direct ulnar approach. Next, we preferably used a six-hole plate for ulna shortening and the respective surgical technique with cutting guide (► **Figure 5**). We prefer, whenever possible, to place the plate volarly, because it has better muscle coverage.

In the postoperative period, the patient is kept immobilized with a forearm and palm cast splint for 10 days. After this time, joint amplitude exercises are encouraged followed by strengthening exercises at week 4. If joint amplitude gain and/or strength are unsatisfactory, the patients are referred for physical therapy.



**Fig. 5** Evaluation of alignment and shortening after ulnar osteotomy with fluoroscopy support.

### Results

The results of the clinical and radiological evaluation are presented in ► **Table 1**. Six out of seven patients reported they would repeat the surgery, and none of them were incapacitated for work. Only one patient reports current limitation in his day-to-day activity. Three patients presented a type I DRUJ injury, 3 patients presented type II, and 2 patients presented type III. One patient (12.5%) presented degenerative changes (► **Figure 3**).

In our patient population, 2 patients (25%) had plaque-related symptoms with indication for removal, and one patient refuses another surgical intervention. The other patient showed resolution of the symptoms with the removal of the material and is satisfied with the surgeries. It is noteworthy that the patient who refuses the indication for material removal is the only one with increased pain, low satisfaction with surgery, with current limitation and with increased DASH. Objectively, he had decreased supination (50° versus mean of 88° of the other patients). His pain complaints are located mainly at the forearm level, on the plate, not on the wrist, either static or dynamically.

Our patient data suggest a strong correlation between supination amplitude and ulnar deviation obtained (rs 0.771,  $p < 0.05$ ), between supination amplitude and shortening performed (rs 0.816,  $p < 0.05$ ), between ulnar deviation and shortening performed (rs 0.787,  $p < 0.05$ ) and between

**Table 1** Summary of clinical and radiographic evaluation of operated patients

	Preoperative / contralateral limb	Postoperative	Difference	<i>p</i> -value
VAS Scale	7 (1–10)	2.6 (0–5)	–4.4	<u>0.037</u>
Quick-DASH	64 (3–95)	28 (2–78)	–36	<u>0.036</u>
Flexion	58°	51°	–7°	0.228
Extension	59.3°	60°	+ 0.7	0.739
Supination	88.5°	83°	–5.5°	0.317
Pronation	90°	90°	0°	1.000
Ulnar Deviation	37.9	37.1°	0.7°	0.748
Radial deviation	27.9	27.9°	0°	1.000
Strength	16,9Kg	14.6Kg	86%	<u>0.027</u>
Ulnar variance	+5.5 mm (1–9mm)	–1.1 mm (- 3–0mm)	6.5 mm	<u>0.011</u>

Abbreviations: DASH, disabilities of the arm, shoulder and hand; VAS, visual analogue scale. Statistically significant differences are underlined.

postoperative quick-DASH and supination amplitude (rs 0.802,  $p < 0.05$ ). It should be noted that in our sample, the two patients with the highest postoperative quick-DASH scores (64.5 versus 13.2), when compared to the others, are also those with lower supination amplitudes (65° versus 90°), lowest ulnar deviation (27.5° versus 41°) and those that underwent a greater shortening (8.5 versus 5.9 mm).

There are no reports of other complications such as pseudoarthrosis.

## Discussion

The ulnocarpal joint, having a relatively limited contact area, is a joint that carries a significant load and is therefore at risk of degenerative processes associated with overload. From a pathophysiological point of view, UC originates from chronic compression associated with overload of this joint, and positive ulnar variance, whether idiopathic or acquired, plays a major role in its development. With a neutral variance, the ulna transmits ~ 18% of the load, while with a positive variance of only 2.5 mm, the transmission rises to 42%.<sup>11</sup> With a negative variance of 2.5 mm, it transmits only 4% of the load.<sup>11</sup> A change in the distal radius inclination to 40° of dorsal inclination increases the load transmission through the ulna to ~ 65%.<sup>12</sup> However, biomechanical studies have not shown this load change in wrists with constitutional positive variance. These wrists are subject to a higher incidence of TFCC perforations, which is probably related to the fact that there is an inverse relationship between the ulnar variance and the thickness of the TFCC.<sup>13</sup> This fact also leads to chronic degenerative changes associated with increased load transmission. Biomechanically, it is also important to mention that during the grip, and especially with the pronation, there may be a physiological increase of 2 mm in the ulnar variance and, consequently, the unfolding of the entire degenerative process affecting the structures in overload<sup>14</sup> (– **Figure 6**).

The diagnosis of this pathology is based on the symptoms, signs and radiological findings. The clinical picture is a patient with progressive pain in the ulnar side of the wrist

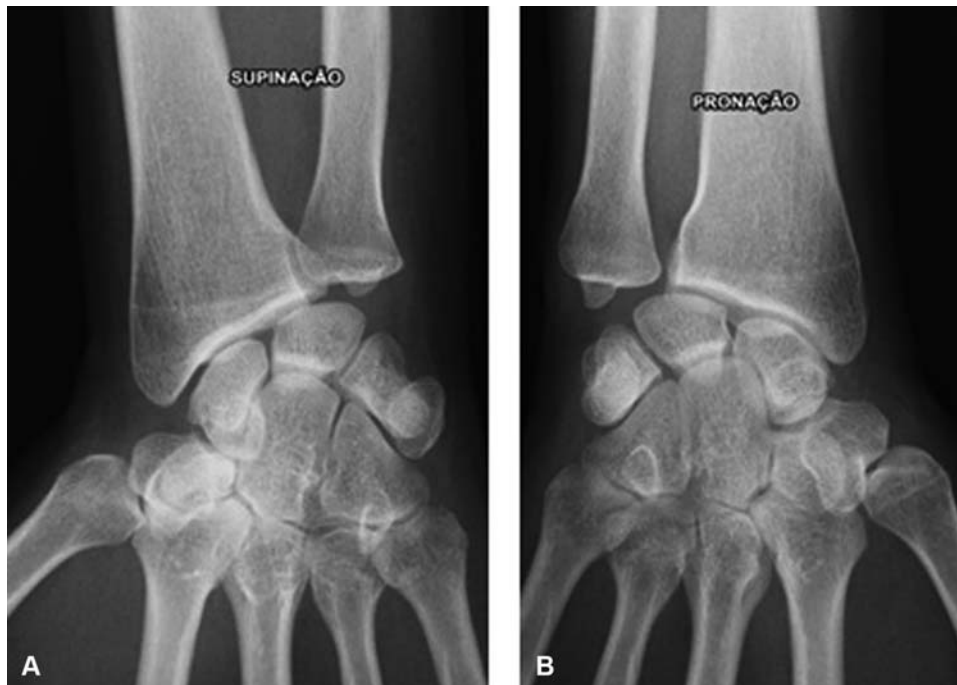that worsens with ulnar deviation, pronation and grip.<sup>3</sup> Signs include pain on palpation and local edema. Articular amplitude may be variably affected. On objective examination, a positive ulnar fovea sign, and a positive ulnocarpal stress test, are characteristic.<sup>15</sup>

Radiologically, the most useful diagnostic tests are radiography and magnetic resonance imaging (MRI). Findings of interest on radiography are positive ulnar variance, degenerative changes such as subchondral sclerosis or the existence of cystic formations in the semilunar, the pyramidal, or the distal ulna.<sup>16</sup> In some cases, for the diagnosis, it may be necessary an incidence in pronation, of closed fist, or a combination of both, by the dynamic changes in ulnar variance mentioned above.<sup>17</sup> Magnetic resonance imaging plays an important role in detecting early changes associated with this conflict and in differential diagnosis with Kienbock disease.<sup>16</sup>

Treatment of this condition should begin conservatively by modifying the activities of the patient, resting orthoses, analgesic or anti-inflammatory medication, and joint infiltration with corticosteroids.

Surgical treatment should only be considered after conservative treatment failure and in the absence of DRUJ arthrosis. Its purpose is to reduce the load transmitted by the ulna. In a patient with negative or neutral ulnar variance, an effective procedure to reduce patient symptomatology may be arthroscopic debridement of intra-articular lesions (TFCC, articular surfaces, lunotriquetral ligament). In these cases, we act only on the symptomatology of the patient, and not on the pathophysiological process. Therefore, a procedure to reduce ulnar variance often remains necessary. In a patient with positive or dynamic positive ulnar variance, surgical options are primarily diaphyseal or metaphyseal osteotomies, or partial distal ulnar resections.

While the latter procedure has the advantage of avoiding open surgery and material placement, it should be borne in mind that only procedures proximal to the secondary stabilizers of the TFCC, by increasing their tension, contribute to the stabilization of the DRUJ and of the ulnar region of the carpus, and prevent secondary cases of instability, facts confirmed in



**Fig. 6** Forearm supination (A) and pronation (B) showing the dynamic difference in ulnar variance.

biomechanical studies.<sup>18,19</sup> In addition, the alignment of the ulna and the sigmoid cavity of the radius should be evaluated, as certain patterns (type III) may lead to degenerative changes of the DRUJ after such procedures.<sup>9,11,20</sup>

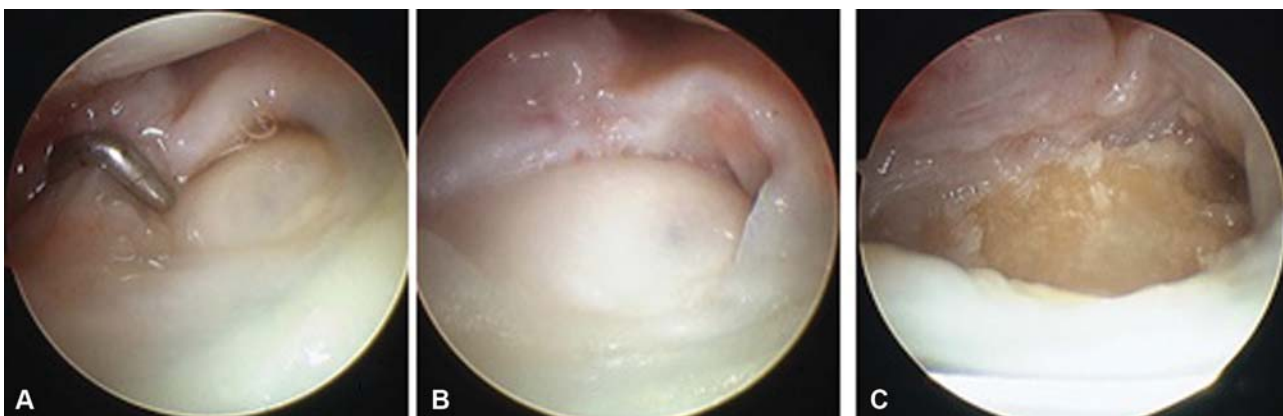
The *wafer procedure*, described by Feldon, consists of a distal (arthroscopic or open) partial ulnar resection, where the distal 2 to 4 mm of the ulna are excised, with preservation of the insertions of the TFCC, of the ulnar styloid, and of the articular surface of the DRUJ.<sup>21</sup> Good results are described with this technique, without the problems related to the diaphyseal osteotomies<sup>21-23</sup> (→ **Figure 7**).

By contrast, the diaphyseal ulna shortening osteotomies have the advantage of preserving the ulnocarpal joint, the DRUJ and its constituents. This surgical option takes precedence in cases of positive variance secondary to fractures since, by correcting the length of the ulna, it tensions the ulnocarpal

ligaments and the interosseous membrane, improving stability of the DRUJ and of the lunotriquetral joint.<sup>18,19,24</sup> To perform this diaphyseal shortening, three different osteotomy techniques are described: transverse, oblique and *step-cut*. Oblique osteotomies are associated with faster consolidation than transverse osteotomies.<sup>25</sup> Darlis et al.<sup>26</sup> described the *step-cut* technique, also with good results.

Metaphyseal osteotomies, although not presenting the problem of material irritation and the risk of pseudoarthrosis, as the diaphyseal osteotomies do, alter the orientation of the distal joint surface of the ulna and do not benefit from such biomechanical effects.<sup>5,6</sup>

In our hospital, we prefer ulna shortening osteotomies to correct this pathology, especially when associated with fracture, and we chose, as described, the diaphyseal oblique section.



**Fig. 7** (color image) Arthroscopic Wafer Procedure. After the identification of a fibrocartilage lesion (A), soft tissue regularization was performed (B), followed by partial distal ulnar resection (C).

**Table 2** Summary of Studies on Ulna Shortening Osteotomies

Study	n	Quick-DASH	Pain (VAS)	Articular amplitude	Grip strength	Complications
Moermans et al. <sup>27</sup>	28	40 to 26	–	80 to 88%	67 to 75%	Pseudarthrosis or consolidation delays (17%) Material conflict (20%)
Doherty et al. <sup>28</sup>	28	37.2	7.9 to 3.1	–10°	80%	Pseudarthrosis (17.9%) OMR (39.3%)
Fufa et al. <sup>29</sup>	33	11 (0–39)	2	–	–	OMR (30%)
Rajgopal et al. <sup>30</sup>	72	40.2 (PRWE)	–	–	–	Pseudarthrosis or consolidation delays (21.3%) CRPS (6.7%) OMR (45.3%)

Abbreviations: CRPS, complex regional pain syndrome; n, number of patients; OMR, osteosynthesis material removal; PRWE, patient-rated wrist evaluation.

The evolution, final value or comparison with the contralateral side of the various analyzed parameters is presented.

Other authors have demonstrated the usefulness of this technique in several studies, summarized in ►Table 2. In line with the results presented, our experience also shows an ability to reduce pain in these patients. As for the range of motion, the decreased postoperative flexion, and the supination, they have shown according to the presented literature. The same goes for decreasing grip strength. It is noteworthy that the decrease in flexion in these patients may be due to the fracture-induced deformity itself, and not due to the treatment performed, due to decreased physiological volar inclination of the radius. Regarding complications, we have recorded two cases of material conflict, a percentage consistent with the above-described observations.

As noted above, although a type III DRUJ is a relative contraindication for this surgery, in our series we present two cases with this joint conformation. In these cases, the risk-benefit ratio of this technique is evaluated more carefully, and the surgical option is chosen when the patient's complaints justify it. To date, these two patients have no significant arthrosis or complaints that differ from the rest of the patients.

Regarding the correlations found in the present study, to the best of our knowledge, the relationships between quick-DASH, supination, ulnar deviation, and apparently greater ulnar shortening performed, are not described in the literature. However, given the size of our sample, we simply refer to them, without considering causal considerations or pathophysiological explanations. These will be aspects to address, if this trend continues in a future review, as our sample increases.

As limitations of the present study, it should be noted that the preoperative assessment of pain and functional capacity using quick-DASH was performed at the date of the last follow-up, and therefore is subject to a bias (*recall bias*). Moreover, the small number of patients, and the short follow-up, prevent us from finding greater statistical significance in the results, and may underestimate the rate of complications. However, there seems to be a clear trend in line with the results described in the literature.

## Conclusion

The present study, and the consequent literature review, point to the validity of this surgical technique, its indications and the good clinical and radiographic results that can be obtained with it. With the large and growing number of patients with distal radius fractures often undergoing conservative treatment, the number of patients with sequelae of these fractures is likely to increase. In cases of vicious consolidation, in which the causes of functional impotence and pain originate in a UC, this procedure may play an increasingly prominent role in treating our patients.

### Conflict of Interests

The authors declare that there are no conflict of interests.

## References

- Sachar K. Ulnar-sided wrist pain: evaluation and treatment of triangular fibrocartilage complex tears, ulnocarpal impaction syndrome, and lunotriquetral ligament tears. *J Hand Surg Am* 2008;33(09):1669–1679
- Viegas SF. The lunatohamate articulation of the midcarpal joint. *Arthroscopy* 1990;6(01):5–10
- Sammer DM, Rizzo M. Ulnar impaction. *Hand Clin* 2010;26(04):549–557
- Milch H. Cuff resection of the ulna for malunited Colles' fracture. *J Bone Joint Surg Am* 1941;23:311–313
- Chun S, Palmer AK. The ulnar impaction syndrome: follow-up of ulnar shortening osteotomy. *J Hand Surg Am* 1993;18(01):46–53
- Loh YC, Van Den Abbeele K, Stanley JK, Trail IA. The results of ulnar shortening for ulnar impaction syndrome. *J Hand Surg [Br]* 1999;24(03):316–320
- El-Karef E. Staged reconstruction for malunited fractures of the distal radius. *J Hand Surg Br* 2005;30(01):73–78
- Orfale AG, Araújo PMP, Ferraz MB, Natour J. Translation into Brazilian Portuguese, cultural adaptation and evaluation of the reliability of the Disabilities of the Arm, Shoulder and Hand Questionnaire. *Braz J Med Biol Res* 2005;38(02):293–302
- Sagerman SD, Zogby RG, Palmer AK, Werner FW, Fortino MD. Relative articular inclination of the distal radioulnar joint: a radiographic study. *J Hand Surg Am* 1995;20(04):597–601
- Tolat AR, Sanderson PL, De Smet L, Stanley JK. The gymnast's wrist: acquired positive ulnar variance following chronic epiphyseal injury. *J Hand Surg Br* 1992;17(06):678–681

- 11 Palmer AK, Werner FW. Biomechanics of the distal radioulnar joint. *Clin Orthop Relat Res* 1984;(187):26–35
- 12 Werner FW, Palmer AK, Fortino MD, Short WH. Force transmission through the distal ulna: effect of ulnar variance, lunate fossa angulation, and radial and palmar tilt of the distal radius. *J Hand Surg Am* 1992;17(03):423–428
- 13 Palmer AK, Glisson RR, Werner FW. Relationship between ulnar variance and triangular fibrocartilage complex thickness. *J Hand Surg Am* 1984;9(05):681–682
- 14 Fischer J, Thompson NW, Harrison JW. *Triangular Fibrocartilage Complex Lesions—A Classification*. London: Springer London; 2014:371–372
- 15 Nakamura R, Horii E, Imaeda T, Nakao E, Kato H, Watanabe K. The ulnocarpal stress test in the diagnosis of ulnar-sided wrist pain. *J Hand Surg Br* 1997;22(06):719–723
- 16 Cerezal L, del Piñal F, Abascal F, García-Valtuille R, Pereda T, Canga A. Imaging findings in ulnar-sided wrist impaction syndromes. *Radiographics* 2002;22(01):105–121
- 17 Tomaino MM. The importance of the pronated grip x-ray view in evaluating ulnar variance. *J Hand Surg Am* 2000;25(02):352–357
- 18 Nishiwaki M, Nakamura T, Nakao Y, Nagura T, Toyama Y. Ulnar shortening effect on distal radioulnar joint stability: a biomechanical study. *J Hand Surg Am* 2005;30(04):719–726
- 19 Moritomo H. The distal interosseous membrane: current concepts in wrist anatomy and biomechanics. *J Hand Surg Am* 2012;37(07):1501–1507
- 20 Hollevoet N, Verdonk R, Van Maele G. The influence of articular morphology on non-traumatic degenerative changes of the distal radioulnar joint. A radiographic study. *J Hand Surg Br* 2006;31(02):221–225
- 21 Feldon P, Terrono AL, Belsky MR. Wafer distal ulna resection for triangular fibrocartilage tears and/or ulna impaction syndrome. *J Hand Surg Am* 1992;17(04):731–737
- 22 Tomaino MM. Results of the wafer procedure for ulnar impaction syndrome in the ulnar negative and neutral wrist. *J Hand Surg [Br]* 1999;24(06):671–675
- 23 Constantine KJ, Tomaino MM, Herndon JH, Sotereanos DG. Comparison of ulnar shortening osteotomy and the wafer resection procedure as treatment for ulnar impaction syndrome. *J Hand Surg Am* 2000;25(01):55–60
- 24 Nishizuka T, Tatebe M, Hirata H, Shinohara T, Yamamoto M, Iwatsuki K. Simple debridement has little useful value on the clinical course of recalcitrant ulnar wrist pain. *Bone Joint J* 2013; 95-B(12):1687–1696
- 25 Rayhack JM, Gasser SI, Latta LL, Ouellette EA, Milne EL. Precision oblique osteotomy for shortening of the ulna. *J Hand Surg Am* 1993;18(05):908–918
- 26 Darlis NA, Ferraz IC, Kaufmann RW, Sotereanos DG. Step-cut distal ulnar-shortening osteotomy. *J Hand Surg Am* 2005;30(05):943–948
- 27 Moermans A, Degreef I, De Smet L. Ulnar shortening osteotomy for ulnar ideopathic impaction syndrome. *Scand J Plast Reconstr Surg Hand Surg* 2007;41(06):310–314
- 28 Doherty C, Gan BS, Grewal R. Ulnar shortening osteotomy for ulnar impaction syndrome. *J Wrist Surg* 2014;3(02):85–90
- 29 Fufa DT, Carlson MG, Calfee RP, Sriram N, Gelberman RH, Weiland AJ. Mid-term results following ulna shortening osteotomy. *HSS J* 2014;10(01):13–17
- 30 Rajgopal R, Roth J, King G, Faber K, Grewal R. Outcomes and complications of ulnar shortening osteotomy: an institutional review. *Hand (N Y)* 2015;10(03):535–540