



# Resection of a Recurrent Cervicomedullary Junction Fibromyxoid Sarcoma through a Far Lateral Approach

Vincent Nguyen<sup>1</sup> William Mangham<sup>1</sup> Jaafar Basma<sup>1</sup> Nickalus Khan<sup>1</sup> Jeffrey Sorenson<sup>1</sup>

L. Madison Michael II<sup>1</sup>

<sup>1</sup> Department of Neurosurgery, University of Tennessee, Memphis, Tennessee, United States

**Address for correspondence** L. Madison Michael II, MD, Department of Neurosurgery, University of Tennessee, 847 Monroe Avenue, Suite 427 Memphis, TN 38163, United States (e-mail: mmichael@semmes-murphey.com).

J Neurol Surg B 2021;82(suppl S1):S39–S40.

## Abstract

**Objectives** This study describes a far lateral approach for the resection of a recurrent fibromyxoid sarcoma involving the ventrolateral brainstem, with emphasis on the microsurgical anatomy and technique.

**Design** A far lateral craniotomy is performed in the lateral decubitus position and the transverse and sigmoid sinuses exposed. After opening the dura, sutures are placed to allow gentle mobilization of the sinuses. The recurrent tumor is immediately visible. The involved dura is resected and aggressive internal debulking is performed. Subarachnoid dissection gives access to the lower cranial nerves. The tumor is dissected off the affected portions of the brainstem. A dural graft is used to reconstitute the dura. Photographs of the region are borrowed from Dr. Rhoton's laboratory to illustrate the microsurgical anatomy.

**Participants** The senior author performed the surgery. The video was edited by Dr. V. N. chart review, and literature review were performed by Drs. W.M. and J.B.

**Outcome measures** Outcome was assessed with the extent of resection and post-operative neurological function.

**Results** A near gross total resection of the lesion was achieved. The patient developed a left vocal cord paresis, but her voice was improving at 3-month follow-up.

**Conclusion** Understanding the microsurgical anatomy of the craniocervical junction and ventrolateral brainstem and meticulous microneurosurgical technique are necessary to achieve adequate resection of lesions involving the ventrolateral brainstem. The far lateral approach provides an adequate corridor to this region.

The link to the video can be found at: <https://youtube/uYEhgPbgrTs>.

## Keywords

- far lateral
- sarcoma
- craniovertebral
- skull base
- tumor
- microsurgery
- neurosurgery
- intraoperative rupture
- clipping



## Conflict of Interest

None declared.

[www.thieme.com/skullbasevideos](http://www.thieme.com/skullbasevideos)

[www.thieme.com/jnlsbvideos](http://www.thieme.com/jnlsbvideos)

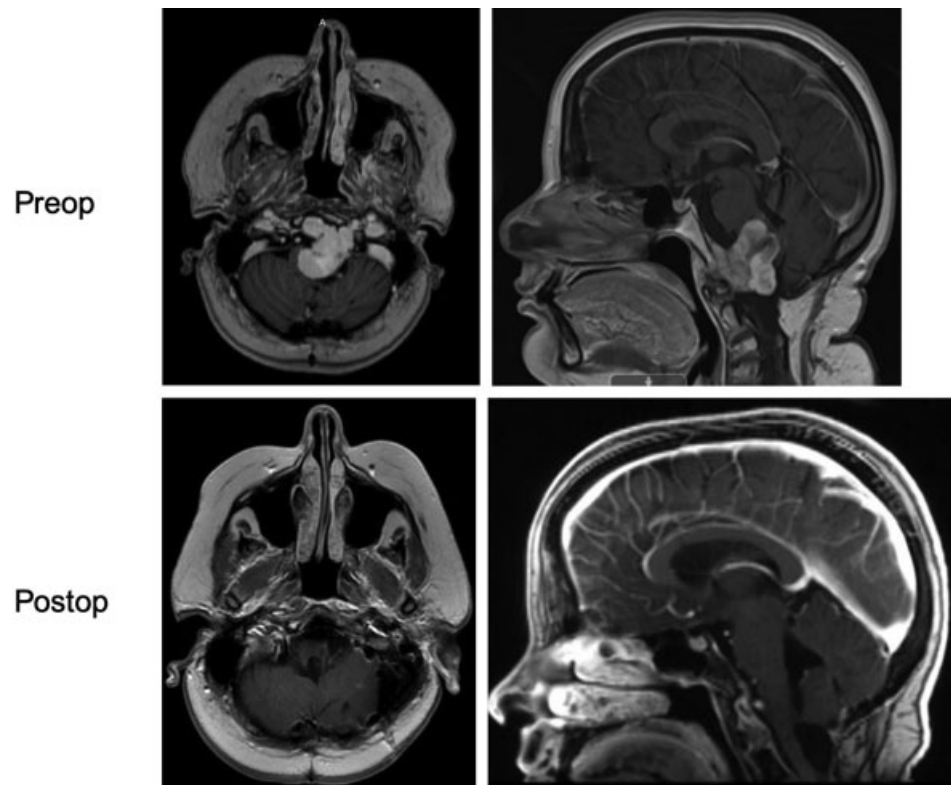
received  
April 2, 2019  
accepted after revision  
September 29, 2019  
published online  
March 13, 2020

DOI <https://doi.org/10.1055/s-0040-1701688>.  
ISSN 2193-6331.

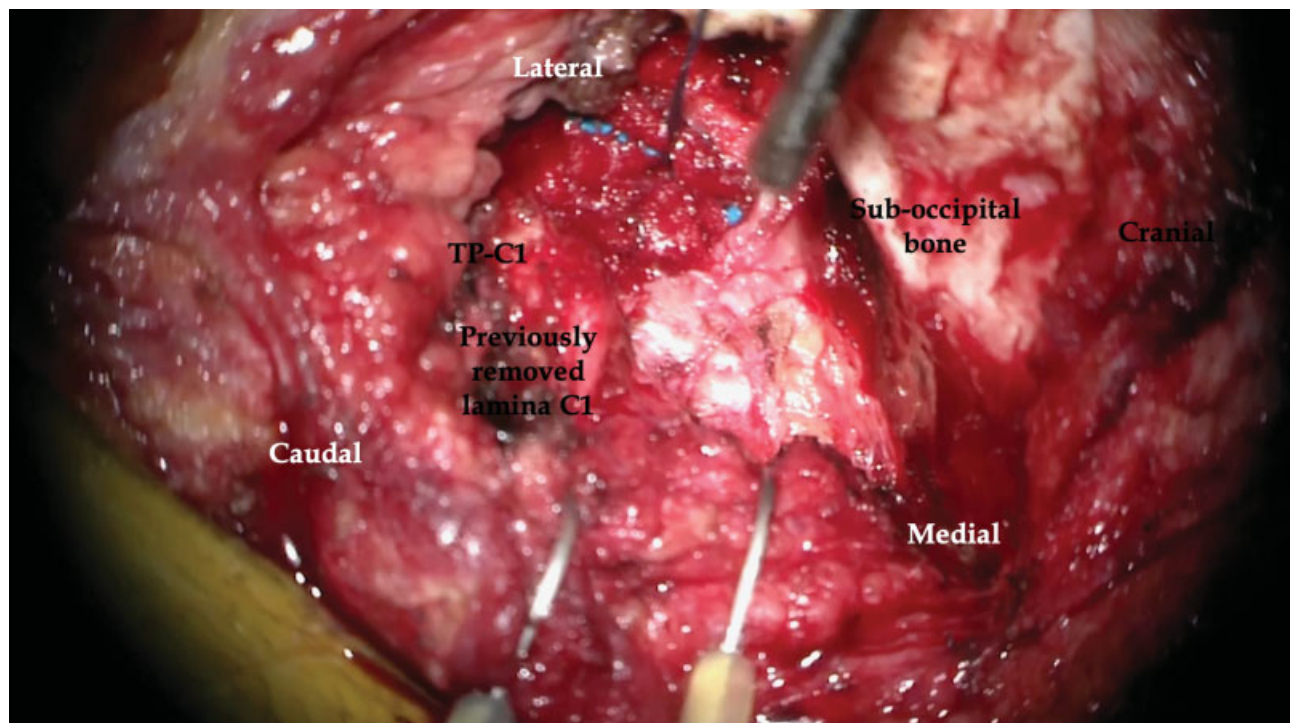
© 2020. The Author(s).

This is an open access article published by Thieme under the terms of the Creative Commons Attribution-NonDerivative-NonCommercial-License, permitting copying and reproduction so long as the original work is given appropriate credit. Contents may not be used for commercial purposes, or adapted, remixed, transformed or built upon. (<https://creativecommons.org/licenses/by-nc-nd/4.0/>)

Georg Thieme Verlag KG, Rüdigerstraße 14, 70469 Stuttgart, Germany



**Fig. 1** Postoperative imaging shows near gross total resection of the large recurrent fibromyxoid sarcoma.



**Fig. 2** A far lateral approach offers an adequate corridor for resection of this large recurrent tumor previously approached through a midline suboccipital approach.