







Prevalence of the Linburg-Comstock Anomaly in a Brazilian Population Sample*

Prevalência da anomalia de Linburg-Comstock em uma amostra populacional brasileira

Leonardo Coêlho de Alencar Barreto¹  Carlos Henrique Fernandes¹  Luis Renato Nakachima¹ 
 João Baptista Gomes dos Santos¹  Marcela Fernandes¹  Flavio Faloppa¹ 

¹ Department of Orthopedics and Traumatology, Universidade Federal de São Paulo, São Paulo, SP, Brazil

Address for correspondence Leonardo Coêlho de Alencar Barreto, MD, Departamento de Ortopedia e Traumatologia, Universidade Federal de São Paulo, Rua Borges Lagoa 786, Vila Clementino, São Paulo, SP, Brasil (e-mail: leoemcel@hotmail.com).

Rev Bras Ortop 2020;55(3):317–322.

Abstract

Objective To determine the prevalence of the Linburg-Comstock anomaly in a Brazilian population sample.

Methods A cross-sectional observational study was carried out between October 2017 and April 2018. We included male and female volunteers aged 18 years or older. The presence of the Linburg-Comstock anomaly was determined by performing the clinical tests described by Linburg and Comstock. The data were analyzed using the GraphPad Prism software, and we considered differences with $p < 0.05$.

Results The study analyzed 1,008 volunteers (2,016 hands) with a mean age of 38.3 years, 531 (52.67%) of which were male, and 477 (47.33%) were female. The Linburg-Comstock anomaly was diagnosed in 564 (55.95%) individuals, and it was bilateral in 300 (53.2%) of them, right-sided in 162 (28.72%), and left-sided in 102 (18.08%). No significant differences were found when comparing the prevalence between genders. However, the prevalence of the right-sided anomaly in the male population ($n = 99$; 70.21%) was higher than in the female one ($n = 63$; 51.21%), with $p = 0.0016$. In addition, the presence of pain by the maneuver described by Linburg and Comstock was more prevalent in women ($n = 150$; 54.94%) than in men ($n = 105$; 36.08%), with $p = 0.0001$. These results show the importance of epidemiological studies on the Linburg-Comstock anomaly, mainly in order to investigate the presence of associated conditions.

Conclusion The prevalence of the Linburg-Comstock anomaly in the studied population was of 55.95%, and it was bilateral in 53.2% of the volunteers. The presence of the connection was observed more frequently in the right side and among men, but the pain symptom was more frequent among women.

Keywords

- ▶ congenital hand deformities
- ▶ finger joint abnormalities
- ▶ tendons
- ▶ prevalence
- ▶ anatomy

* Work developed at the Discipline of Hand Surgery and Upper Limb, Department of Orthopedics and Traumatology, Universidade Federal de São Paulo, São Paulo, SP, Brazil.

Resumo

Objetivo Determinar a prevalência da anomalia de Linburg-Comstock em uma amostra populacional brasileira.

Métodos Estudo observacional transversal realizado no período de outubro de 2017 a abril de 2018. Foram incluídos voluntários dos gêneros feminino e masculino, com idade igual ou superior a 18 anos. A presença da anomalia de Linburg-Comstock foi determinada pela realização dos testes clínicos descritos por Linburg e Comstock. Os dados foram analisados por meio do *software* GraphPad Prism, sendo consideradas diferenças com valores de $p < 0,05$.

Resultados O estudo analisou 1.008 voluntários (2.016 mãos) com idade média de 38,3 anos, dos quais 531 (52,67%) eram do gênero masculino, e 477 (47,33%) eram do gênero feminino. A anomalia de Linburg-Comstock foi diagnosticada em 564 voluntários (55,95%) da população estudada, sendo bilateral em 300 (53,2%), direita em 162 (28,72%), e esquerda em 102 (18,08%). Não foram encontradas diferenças significativas quando se comparou a prevalência entre os gêneros. Porém, foi encontrada uma maior prevalência da anomalia unilateral direita na população masculina ($n = 99$; 70,21%) do que na feminina ($n = 63$; 51,21%), com $p = 0,0016$. Além disso, a presença da dor pela manobra descrita por Linburg e Comstock foi mais prevalente nas mulheres ($n = 150$; 54,94%) do que nos homens ($n = 105$; 36,08%), com $p = 0,0001$. Estes resultados mostram a importância dos estudos epidemiológicos sobre a anomalia de Linburg-Comstock, principalmente com o intuito de investigar a presença de afecções associadas.

Conclusão A prevalência da anomalia de Linburg-Comstock na população estudada foi de 55,95%, sendo bilateral em 53,2% dos voluntários. A presença da conexão foi observada com maior frequência do lado direito em homens, mas o sintoma dor foi mais frequente nas mulheres.

Palavras-chave

- ▶ deformidades congênitas da mão
- ▶ anormalidades nas articulações dos dedos
- ▶ tendões
- ▶ prevalência
- ▶ anatomia

Introduction

Since the 19th century, anatomists know the interconnection between the flexor pollicis longus (FPL) tendon and the flexor digitorum profundus (FDP) tendon.¹ Its clinical importance and its association with carpal tunnel syndrome were defined in 1979, and it became known as the Linburg-Comstock (LC) anomaly.¹

This interconnection produces the loss of digital independence, that is, the active bending movement of the thumb is accompanied by simultaneous involuntary flexion of the index finger, alone or accompanied by other long fingers.^{1,2} This interconnection has an average width of 1 mm, and can remain generally concealed under the thick synovia.²

The FPL and FDP muscles in humans originate phylogenetically from the same mesodermic mass. Evolutionarily, these tendons became independent and move separately. In other primates there is an interconnection between these tendons that prevents independent movement.³

The etiology of the LC anomaly may be congenital or acquired.⁴ The known etiological factors include excessive use of the hands, injuries to the forearm, and posttraumatic tenosynovitis.⁵⁻⁸ Most carriers of this anomaly are asymptomatic. However, some carriers may present symptoms such as intermittent pain in the palm of the hand, distal wrist and forearm, finger numbness, tingling and nocturnal

pain. Considering these symptoms, the anomaly may be associated with carpal tunnel syndrome and chronic pain in the forearm.^{4,8-11}

In patients with the LC anomaly, repetitive hand movements can aggravate the symptoms and compromise their activities, especially in the case of musicians, surgeons, typists, carpenters and police officers.^{9,12}

The diagnosis of the anomaly is clinical, as described in the literature.^{1,2} High resolution ultrasound examinations and magnetic resonance imaging may help in the confirmation and location of the anomalous interconnection.¹³ In symptomatic cases, non-operative management with a splint, oral anti-inflammatory medicines and stretching exercises were not successful regarding long-term clinical improvement. Thus, surgical treatment seems to be the therapy of choice.⁵ Surgical excision of the anomalous interconnection has been able to relieve the symptoms when present.^{5-7,14,15}

In the general population, the prevalence of the LC anomaly is variable in the different regions of the world,¹⁶ with a prevalence of 20% in Canada,⁴ 32.2% in Turkey,¹⁷ 35% in Malaysia,¹⁸ 37% in France,¹¹ 39% in Saudi Arabia¹² and between 60% and 70% in England.^{5,14} Some of these studies mix the prevalence observed in anatomical dissections, in patients and volunteers, making it difficult to establish the real prevalence of the connection.

We believe that this prevalence variation may be due to ethnic factors. In this context, the objective of the present study was to identify the prevalence of the LC anomaly in a population sample from a multiethnic Brazilian city.

Materials and methods

Type of study and casuistic

The present study is of the cross-sectional observational type, and it involved the participation of volunteers. We considered volunteers patients who attended the university hospital in the period between October 2017 and April 2018 seeking medical care without complaints in the upper limbs, as well as their companions. We included in this sample female and male volunteers, aged 18 years or older. The research was approved by the Medical Ethics Committee under number 2481991. All patients were informed about the assessments and they signed the free and informed consent form (FICF) that authorized the realization of the present research.

Clinical Diagnosis

The clinical diagnosis of the interconnection between the FPL and FDP tendons was performed by means of two clinical tests described by Linburg and Comstock.¹ The first test consisted of requesting the volunteer to perform the active thumb flexion movement with the forearm in supination and the hand spread. The presence of the anomaly was considered when any degree of concomitant flexion of one or more long fingers was observed (► **Figure 1A**). When the presence of the connection was observed in the first test, the second test was conducted, and it consisted of requesting the volunteer to perform the active flexion of the thumb with the forearm in supination and the hand spread, while the examiner maintained the passive extension of the long fingers (► **Figure 1B**). The aim of this study was to investigate if the performance of the test caused pain in the distal volar region of the forearm and wrist. The volunteers were surveyed by three independent examiners who underwent training in the same institution. Each volunteer was evaluated by one of the examiners. The flowchart of the methodology can be observed in ► **Figure 2**.

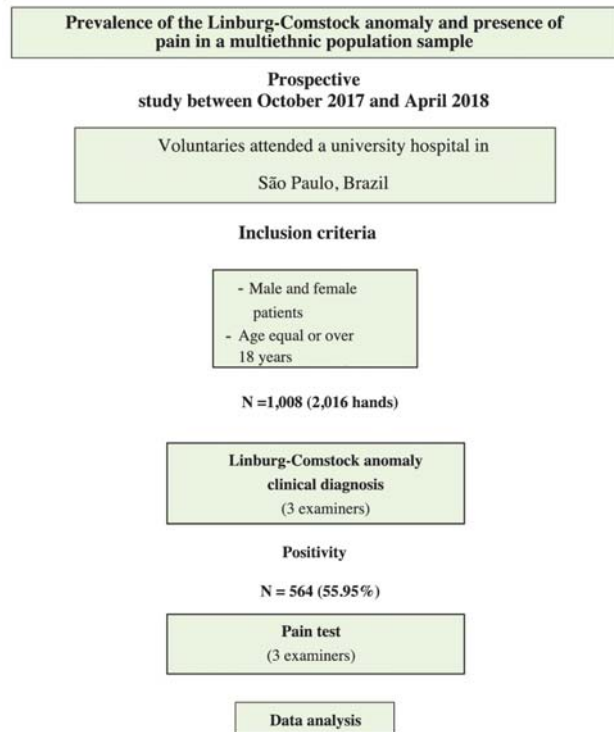


Fig. 2 Flowchart of the methodology adopted in the present study.

Statistical Analysis

The data was catalogued in Excel Office 2010 (Microsoft Corp., Redmond, WA, US) spreadsheets. The Chi-squared test was used to analyze the homogeneity among the proportions. For the statistical analyses, the GraphPad Prism (GraphPad Software, Inc., San Diego, CA, US) software, version 5.0, was used, considering the level of 5% as statistically significant.

Results

During the study period, 1,008 individuals were analyzed, corresponding to 2,016 hands. The sample presented a mean age of 38.42 years old (18 to 72 years). It consisted of 531 men

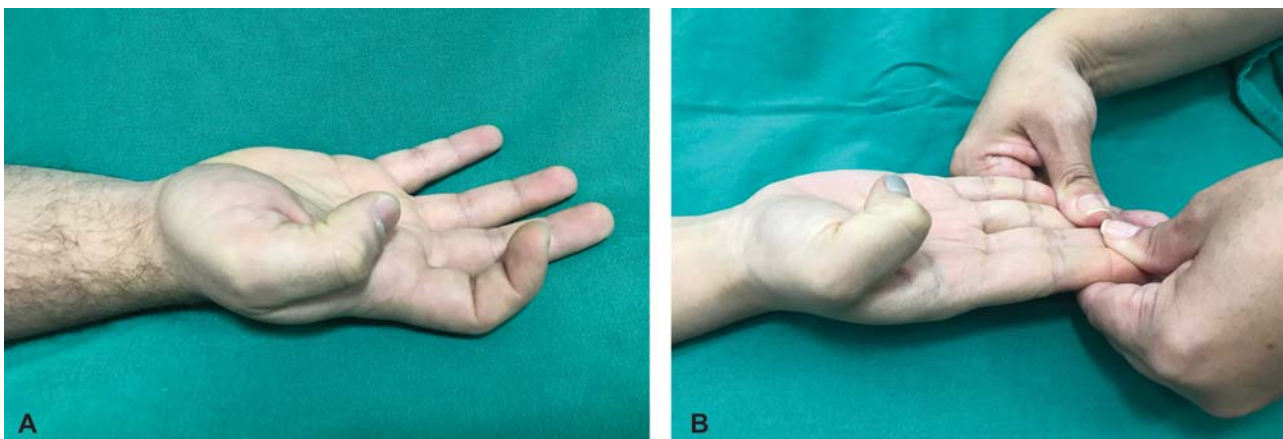


Fig. 1 (A) Test for the diagnosis of the Linburg-Comstock anomaly. Active flexion of the thumb causes concomitant involuntary flexion of the second finger. (B) Pain identification test. Active thumb flexion while the examiner maintains the passive extension of the long fingers to assess the presence of pain.

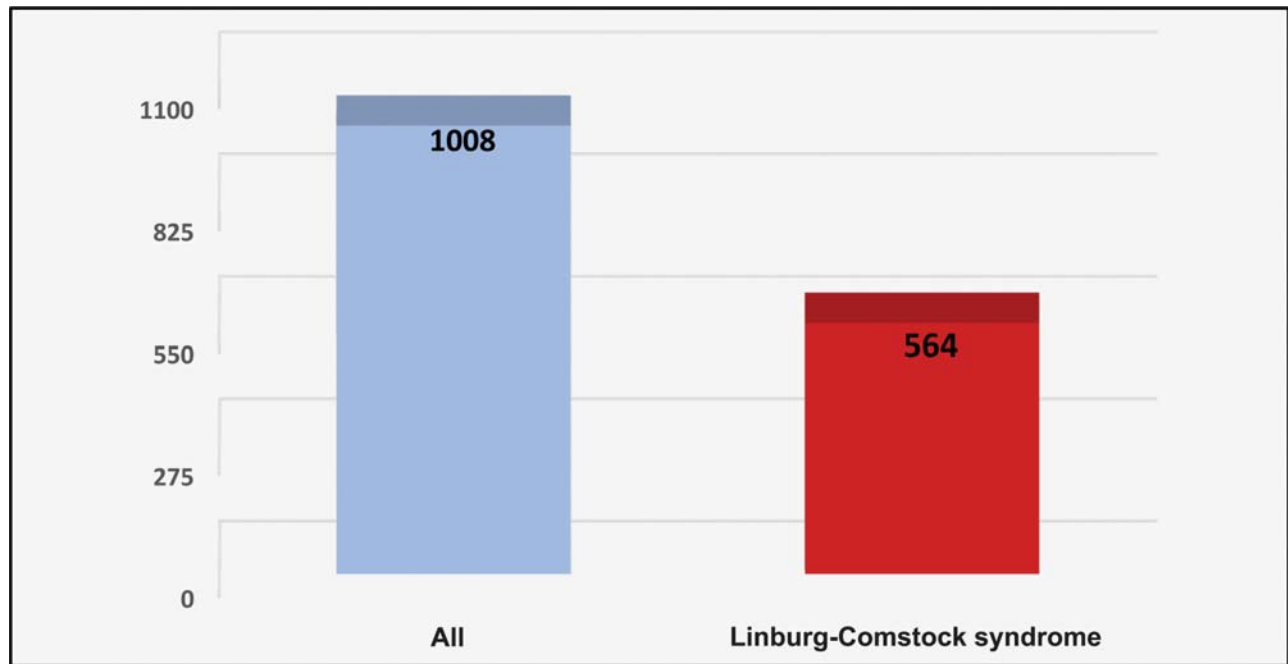


Fig. 3 Prevalence of the Linburg-Comstock anomaly in a sample of the Brazilian population. 1,008 individuals were analyzed.

(52.67%) and 477 women (47.33%). The presence of the LC anomaly was identified in 564 (55.95%) volunteers of the population of 1,008 individuals (► **Figure 3**).

When analyzing the prevalence of the LC anomaly according to gender (► **Table 1**), it is possible to note that the prevalence is similar in both genders (men: $n=291$; 54.80%; women: $n=273$; 57.23%), with no statistically significant differences.

The LC anomaly was bilateral in 300 individuals (53.2%), right-sided in 162 individuals (28.72%), and left-sided in 102 individuals (18.08%) (► **Figure 4**).

However, a difference was identified in the prevalence of the right-sided anomaly, with a higher frequency in the male population ($n=99$; 70.2%) in relation to females ($n=63$; 51.21%), with $p=0.0001$.

Of the 564 volunteers diagnosed with the LC anomaly, the presence of pain was observed in 255 individuals (45.21%), and, according to gender, we found that there was a higher prevalence of pain among females ($n=150$; 54.94%) in relation to males ($n=105$; 36.08%), with $p=0.0001$ (► **Table 2**)

Discussion

Studies on the LC anomaly have been conducted and published worldwide, but no studies were found on the prevalence of the anomaly in Brazil. The present study analyzed 1,008 individuals for 6 months, and it identified, through clinical diagnosis, the prevalence of the LC anomaly in 564 (55.95%) individuals. Studies conducted in England also presented a high prevalence of the anomaly, from 60% to 70%,^{5,14} which is similar to that observed in the present study. Other studies showed lower prevalence, of 20% in Canada,⁴ 35% in Malaysia,¹⁸ between 27.8% and 32.2% in Turkey,¹⁷ 39% in Saudi Arabia¹² and 15% in Italy.¹⁹ The divergences between the various regions of the globe can be justified by ethnic and methodological differences. We can observe that some studies have presented the prevalence of groups of specific risk, such as musicians,^{9,14} secretaries,^{17,20} students^{12,18} and soldiers.²⁰

The sample of the present study had a mean age of 38.42 years (18 to 72 years), and consisted of 531 (52.67%) men and 477 (47.33%) women. These data show that the population

Table 1 Linburg-Comstock anomaly according to gender and laterality

	Men				Women				p-value
	Yes		No		Yes		No		
	n	%	N	%	n	%	n	%	
Linburg-Comstock anomaly	291	54.8	240	45.19	273	57.23	204	42.77	0.4377
Bilateral	150	51.54	141	48.46	150	54.94	123	45.06	0.7769
Right-sided	99	70.2	42	48.46	63	51.21	60	48.79	0.0016
Left-sided	42	29.8	57	57.58	60	48.79	21	25.92	0.8977

Note: The Chi-squared (χ^2) test was used, and values of $p < 0.05$ were considered statistically significant.

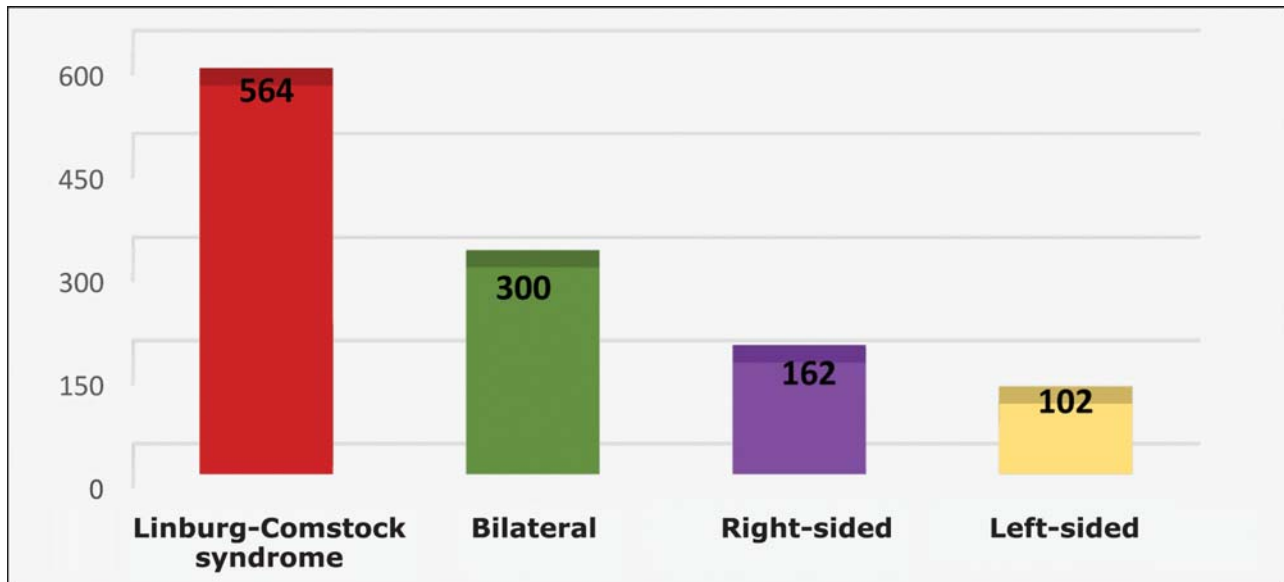


Fig. 4 Prevalence of the Linburg-Comstock anomaly in a multiethnic population according to the laterality. 1,008 Individuals were analyzed.

Table 2 Presence of pain caused by the Linburg-Comstock anomaly according to gender

	Yes		No		<i>p</i> -value
	n	%	n	%	
Men	105	36.08	186	63.92	0.0001
Women	150	54.94	123	45.06	

Note: The Chi-squared (χ^2) test was used, and values of $p < 0.05$ were considered statistically significant.

analyzed occupies an active age group similar in age to the ones in other studies that reported mean ages between 23 and 33 years old.^{5,12,17} A recent meta-analysis showed that the LC anomaly is significantly higher in women compared to men.¹⁶ In our study, the prevalence of the anomaly was equivalent in both genders.

Several studies have shown the higher prevalence of unilateral anomalies in relation to bilateral anomalies.^{1,9,12,18} The pioneer Linburg-Comstock study showed rates of 31% of unilateral and of 14% of bilateral anomalies.¹ Our study, unlike previous ones, showed a higher frequency of bilateral anomalies ($n = 300$; 53.2%), in relation to the right-sided ($n = 162$; 28.72%) and left-sided ($n = 102$; 18.08%) anomalies (► **Figure 3**). Although our data originate from the general population, they are similar to those reported in the study by Miller et al,¹⁴ who observed the frequency of 50% of the anomaly in both hands of musicians. The higher frequency of the anomaly in the right hand found in our study was also observed in other studies.^{5,12} In terms of gender, the prevalence was similar among men and women. However, a difference in the prevalence of the right-sided anomaly was identified, with a higher frequency among the male population ($n = 99$; 70.21%) in relation to women ($n = 63$; 51.21%), with $p = 0.0016$. This finding is in line with those by Low et al,¹⁸ who observed a higher frequency of unilateral anomalies in both genders.

Occult tenosynovitis and pain can be complications generated by the LC anomaly. These symptoms impact the quality of life of the affected individuals.^{2,5,17} Symptomatic carriers may experience wrist or forearm pain when performing tasks that require thumb movements, such as using cutlery, tying shoelaces, typing and writing, or playing musical instruments.^{5,12,14}

Although the LC anomaly is rarely symptomatic, we observed the onset of pain in the volar region of the distal forearm and wrist ($n = 255$; 45.21%) in individuals with the maneuver described to assess this symptom. Pain was more frequent in women ($n = 150$; 54.94%) than in men ($n = 105$; 36.08%), with $p = 0.0001$. In Turkey, a study evaluated secretaries who were carriers of the LC anomaly: in the case group, the prevalence of pain was of 25.3%, and, in the control group, it was of 21.2%.¹⁷ Another study in Turkey analyzed active soldiers carrying the LC anomaly, and showed that 37% of the participants felt pain.²⁰ The high frequency of pain found in women in our study may be justified by the fact that this population performs housework and manual work.

Symptomatic cases may be treated with medication or surgery.^{5,8,9} Steroid treatment does not seem to have long-term benefits,^{5,9} and the surgical treatment, although rarely necessary, has shown efficacy.^{5,6,8,13} Thus, individuals with intermittent pain may be directed to surgery aimed at reducing the symptomatology and improving the quality of life.

The LC anomaly seems to be associated with ancestry, as the Turkish population has shown a higher frequency compared to Europeans. However, English studies have shown high prevalence as well.^{5,14} On the other hand, Hispanics showed a higher frequency, and the those of African descent showed a lower prevalence.¹⁶ Due to the fact that Brazil is a multiethnic nation, we still do not know the impact of ancestry on the prevalence of the LC anomaly, but, according to our findings, this miscegenation tends to increase the prevalence of the LC abnormality. According to Instituto Brasileiro de Geografia e Estatística (Brazilian Institute of Geography and Statistics, IBGE, in Portuguese)²¹ the city of São Paulo is composed of several ethnicities,

with 63.9% of Caucasians, 34.6% of Blacks (sum of the black and brown populations), 2.2% of Asian and 0.1% of Indigenous peoples, so this extract displays a good representativeness of the Brazilian population.

The present study has methodological strengths that involve the fact that this is the first study in a miscegenated population, the sample and the clinical diagnosis involving three independent examiners. However, it has some limitations that include the absence of demographic data, such as the occupation and ethnicity of the volunteers. In addition, the study was conducted in the city of São Paulo, which, despite being considered a cosmopolitan city, may not provide the real prevalence for the entire the country.

Thus, the results presented contribute to increase the knowledge about the prevalence of the LC anomaly in Brazil, and can promote changes in public health services involving treatments with the aim of improving the quality of life of symptomatic individuals.

These data show the need for further epidemiological studies on the LC anomaly to prevent professional impairment or loss of quality of life of the affected individuals. Another important point would be to encourage the investigation of the presence of the LC anomaly and its relationship with affections of the forearm and wrist, as well as the suitable treatment for symptomatic patients.

Conclusion

Our study revealed a prevalence of the LC anomaly of 55.95% (564) of 1,008 volunteers, with a higher frequency of bilateral anomalies. Men were more affected by the right-sided anomaly, and women showed a higher frequency in the pain test.

Conflict of interests

The authors have no conflict of interests to declare.

References

- Linburg RM, Comstock BE. Anomalous tendon slips from the flexor pollicis longus to the flexor digitorum profundus. *J Hand Surg Am* 1979;4(01):79-83
- Gancarczyk SM, Strauch RJ. Linburg-Comstock anomaly. *J Hand Surg Am* 2014;39(08):1620-1622
- Stahl S, Stahl S, Calif E. Failure of flexor pollicis longus repair caused by anomalous flexor pollicis longus to index flexor digitorum profundus interconnections: a case report. *J Hand Surg Am* 2005;30(03):483-486
- Rennie WRJ, Muller H. Linburg syndrome. *Can J Surg* 1998;41(04):306-308
- Badhe S, Lynch J, Thorpe SKS, Bainbridge LC. Operative treatment of Linburg-Comstock syndrome. *J Bone Joint Surg Br* 2010;92(09):1278-1281
- Furukawa K, Menuki K, Sakai A, Oshige T, Nakamura T. Linburg-Comstock syndrome: a case report. *Hand Surg* 2012;17(02):217-220
- Lombardi RM, Wood MB, Linscheid RL. Symptomatic restrictive thumb-index flexor tenosynovitis: incidence of musculotendinous anomalies and results of treatment. *J Hand Surg Am* 1988;13(03):325-328
- Lin B, Sreedharan S, Chin AYH. Linburg-Comstock phenomenon following forearm laceration. *Hand Surg* 2012;17(02):221-224
- Karalezli N, Karakose S, Haykir R, Yagisan N, Kacira B, Tuncay I. Linburg-Comstock anomaly in musicians. *J Plast Reconstr Aesthet Surg* 2006;59(07):768-771
- Yoon HK, Kim CH. Linburg-Comstock syndrome involving four fingers: a case report and review of the literature. *J Plast Reconstr Aesthet Surg* 2013;66(09):1291-1294
- Hamitouche K, Roux JL, Baeten Y, Allieu Y. [Linburg-Comstock syndrome. Epidemiologic and anatomic study, clinical applications]. *Chir Main* 2000;19(02):109-115
- Alzahrani MT, Almalki MA, Althunayan TA, Almohawis AH, Alme-haid FF, Umadani LV. Functional Anatomy of the Hand: Prevalence of the Linburg-Comstock Anomaly in a Young Saudi Population. *J Musculoskelet Surg Res* 2018;2(01):21-25
- Karalezli N, Haykir R, Karakose S, Yildirim S. Magnetic resonance imaging in Linburg-Comstock anomaly. *Acta Radiol* 2006;47(04):366-368
- Miller G, Peck F, Brain A, Watson S. Musculotendinous anomalies in musician and nonmusician hands. *Plast Reconstr Surg* 2003;112(07):1815-1822
- Takami H, Takahashi S, Ando M. The Linburg Comstock anomaly: a case report. *J Hand Surg Am* 1996;21(02):251-252
- Yammine K, Erić M. Linburg-Comstock variation and syndrome. A meta-analysis. *Surg Radiol Anat* 2018;40(03):289-296
- Bulut T, Tahta M, Ozturk T, Zengin EC, Ozcan C, Sener M. Linburg-Comstock: Is Overuse an Etiological Factor? *Plast Surg (Oakv)* 2017;25(04):268-271
- Low TH, Faruk Senan NA, Ahmad TS. The Linburg-Comstock anomaly: incidence in Malaysians and effect on pinch strength. *J Hand Surg Am* 2012;37(05):930-932
- Cigni S. Sindrome di Linburg-Comstock: evidenze clinico-ecografiche e speculazioni anatomiche. *G Ital Ortop Traumatol.* 2010;36:244-253
- Ortak T, Uraloğlu M, Orbay H, Koç MNSO, Sensöz O. Linburg-Comstock anomaly: seems to be harmless but may be fatal. *Plast Reconstr Surg* 2007;119(06):1976-1977
- IBGE - Instituto Brasileiro de Geografia e Estatística. Censo Demográfico 2010. Características da População e dos Domicílios. Disponível em: <https://ww2.ibge.gov.br/home/estatistica/populacao/censo2010/>