





Percutaneous Treatment of Meckel Cave Arachnoid Cyst: Case Report, Surgical Strategy and Literature Review

Tratamento percutâneo de cisto aracnóide do cavum de Meckel: Relato de caso, estratégia cirúrgica e revisão da literatura

Jose Augusto Malheiros Filho¹ Antonio Gilson Prates Junior¹  Emmanuel Oliveira Vasconcelos e Sá¹ 
Luiza Cançado Guerra D'Assumpção¹  Lucas Rodrigues de Souza¹ 

¹Neurosurgery Service, Hospital das Clínicas, Universidade Federal de Minas Gerais, Belo Horizonte, MG, Brazil

Address for correspondence Antonio Gilson Prates Junior, MD, Hospital das Clínicas da Universidade Federal de Minas Gerais, Belo Horizonte, MG, 31270-901, Brazil (e-mail: antonio.ufop@gmail.com).

Arq Bras Neurocir 2020;39(1):22–26.

Abstract

Arachnoid cysts are benign intracranial lesions. They are usually located in the middle fossa, but can be found in other locations. We present a case of symptomatic Meckel cave (MC) arachnoid cyst - a very rare location - and a treatment strategy not elsewhere described before for this condition. A 54-year-old female with trigeminal neuralgia with previous history of radiofrequency rhizotomy treatment 6 years before admission had been experiencing pain recurrence with progression, which required successive increases in carbamazepine dosage. Magnetic Resonance Imaging (MRI) showed dilatation of the right MC with extension to the petrous apex. The lesion was compatible with arachnoid cyst, and due to the worsening of the clinical condition, surgical treatment was chosen. Percutaneous puncture of the cyst through the foramen ovale with injection of intracystic fibrin sealant was performed. The patient woke up from anesthesia with pain improvement and was discharged asymptomatic the next day. After 12 months of follow-up, she remained pain-free. In the literature review, we found only eight cases reported as MC arachnoid cyst. These are likely to progress and become symptomatic owing to their communication with the subarachnoid space and a unidirectional valve mechanism. Pain improvement with this technique is probably secondary to the interruption of these mechanisms.

Keywords

- ▶ Meckel cave
- ▶ arachnoid cyst
- ▶ petrous apex cephaloceles
- ▶ trigeminal neuralgia
- ▶ percutaneous treatment

Resumo

Os cistos aracnoides são lesões intracranianas benignas. Geralmente estão localizados na fossa média, mas podem ser encontrados em outros locais. Apresentamos um caso de cisto aracnoide sintomático no cavum de Meckel (CM) – localização muito rara – e uma estratégia de tratamento nunca antes descrita para esta condição. Uma mulher de 54 anos com neuralgia do trigêmeo e histórico de tratamento com rizotomia por

received
October 1, 2019
accepted
November 8, 2019

DOI <https://doi.org/10.1055/s-0039-3402492>.
ISSN 0103-5355.

Copyright © 2020 by Thieme Revinter Publicações Ltda, Rio de Janeiro, Brazil

License terms



Palavras-chave

- ▶ cavum de Meckel
- ▶ cisto aracnoide
- ▶ cefalocele do ápice petroso
- ▶ neuralgia do trigêmeo
- ▶ tratamento percutâneo

radiofrequência 6 anos antes da admissão apresentava recorrência da dor com progressão, exigindo aumentos sucessivos na dosagem de carbamazepina. Ressonância magnética mostrou dilatação do CM à direita com extensão ao ápice petroso. A lesão era compatível com cisto aracnoide e, devido ao agravamento do quadro clínico, optou-se por tratamento cirúrgico. Foi realizada punção percutânea do cisto através do forame oval com injeção de selante de fibrina intracístico. A paciente acordou da anestesia com melhora da dor e recebeu alta assintomática no dia seguinte. Após 12 meses de acompanhamento, a paciente permaneceu sem dor. Na revisão da literatura, encontramos apenas oito casos relatados como cisto aracnoide do CM. É provável que estes progridam e se tornem sintomáticos devido à sua comunicação com o espaço subaracnóideo e a um mecanismo de válvula unidirecional. A melhora da dor com essa técnica é provavelmente secundária à interrupção desse mecanismo.

Introduction

Arachnoid cysts are benign intracranial lesions that account for 1% of nontraumatic intracranial lesions.^{1,2} They are usually located in the middle fossa, but can be found in other locations - such as the suprasellar, the posterior fossa, the interhemispheric, the quadrigeminal cistern and the cerebral convexity. They are usually asymptomatic lesions, but may become symptomatic depending on location and size.³ There are several treatment options, including endoscopic or microsurgical fenestration, microsurgical excision and cyst shunt. We present a case of symptomatic arachnoid cyst in a very rare location that was treated by a strategy not described elsewhere.

Case Report and Surgical Strategy

A 54-year-old female was admitted in our service with trigeminal neuralgia in the territories of the ophthalmic and maxillary trigeminal branches. She had a history of radiofrequency rhizotomy treatment 6 years before, and at that time, the patient presented improvement and good pain maintenance control with carbamazepine 400 mg a day. Ten months before seeking assistance, the patient recurred and experienced pain progression, which required successive increases in carbamazepine dosage up to 900 mg a day - dose to which she presented adverse reactions. Due to recurrence and worsening of the clinical condition, propae-

deutic were requested. The magnetic resonance imaging (MRI) showed dilatation of the right Meckel cave (MC) with extension to the petrous apex. The lesion presented as hyperintense on T2-weighted imaging, hypointense on T1-weighted imaging (▶ **Figure 1**); suppression of the signal in the T2-weighted fluid-attenuated inversion recovery and absence of diffusion restriction on diffusion weighted imaging - description compatible with arachnoid cyst. There were no neurovascular conflicts or other lesions associated with the trigeminal nerve topography. Owing to daily episodes of excruciating pain and intolerance to drug treatment, surgical treatment was chosen.

Percutaneous puncture of the cyst through the foramen ovale with injection of intracystic fibrin sealant was performed. The patient did not tolerate the sedation, so the procedure took place under general anesthesia. A 20-Gauge spinal needle was inserted through the ascending extraoral transoval route guided by lateral incidence fluoroscopy.⁴ The introduction pathway started 3 cm lateral to the labial commissure and ascended until the intersection point between the coronal plane 3 cm anterior to the tragus and the sagittal plane of the pupil. After touching the skull base, the needle was directed under fluoroscopy to the foramen ovale, using as reference point the clivus intersection with the petrous pyramid. After entrance, the position of the needle was confirmed by fluoroscopy (▶ **Figure 2A**) and through

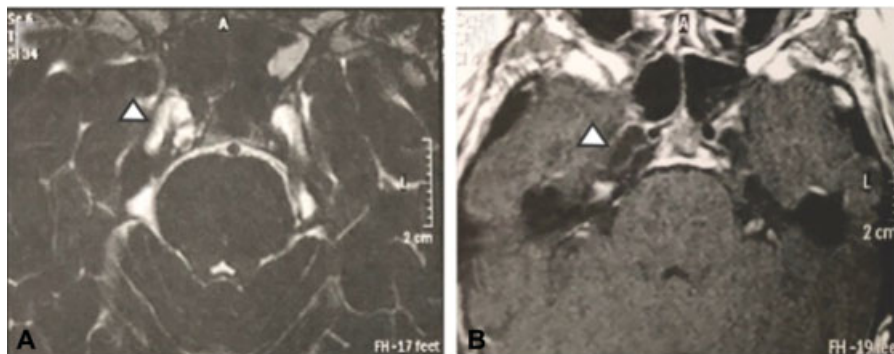


Fig. 1 Meckel cave (MC) arachnoid cyst on magnetic resonance imaging (MRI). (A) T2-weighted MRI image showing right MC dilatation with cerebrospinal sign (arrow). (B) T1-weighted MRI image showing right MC dilatation (arrow).

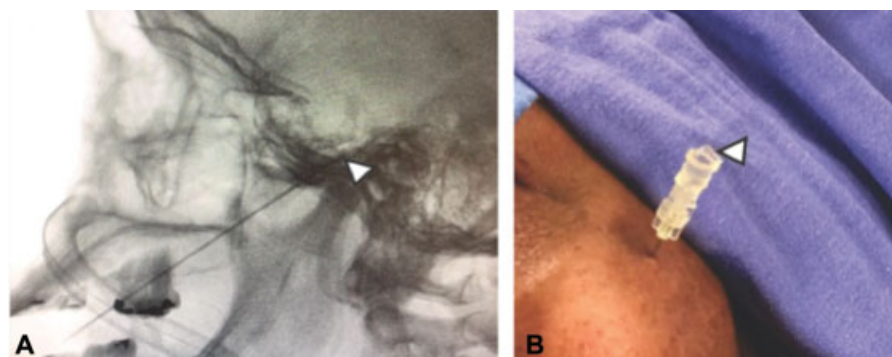


Fig. 2 Surgical technique. (A) Fluoroscopy-guided foramen ovale puncture. Note the tip of the needle in the intracranial compartment (arrow). (B) Puncture point 3 cm lateral to lip rhyme. Note the leakage of cerebrospinal fluid through the needle (arrow).

cerebrospinal fluid (CSF) leakage through its lumen (→**Figure 2B**). On account of active CSF drainage after the puncture, we chose not to inject contrast. Then 2 mL of Tissuecol was injected and the needle was removed. The patient woke up from anesthesia with pain improvement and was discharged asymptomatic the next day. The MRI performed on the first postoperative day revealed reduction of the cyst dimensions and partial filling of the cyst by T2-weighted hypointense material extending through the cisternal segment of the trigeminal nerve (→**Figure 3**). After 12 months of follow-up, tapering of carbamazepine dose was achieved and the patient remained pain-free using only 400 mg a day.

Discussion

Arachnoid cysts are collections of intracranial CSF surrounded by arachnoid layers. They can be primary

or secondary. The primaries are benign malformations originated from arachnoid division during development resulting in anomalous CSF collections. The secondary ones are less common and are associated with neoplasms, infections, bleeding, trauma or surgery.^{2,3} Depending on their location and size, arachnoid cysts may become symptomatic.

In a literature review, we found only eight cases reported as MC arachnoid cyst (→**Table 1**).^{2,5-11} The average age of the patients was 41 years old – with a range from 1 to 58 years old – and there was a female predominance (5 out of 8). The most affected side was the right side (five out of eight). In all but one case, there was trigeminal neuralgia in 1 or more branches territories, associated or not with symptoms of other cranial pairs, such as diplopia, vertigo, and hearing loss. The patient in whom no neuralgia was reported was a 1.5-year-old child with exophthalmos and diplopia.¹⁰ In only three cases the lesion was referred to as restricted to the MC, and in one of these, no MRI was performed and the lesion was not described in details in the article.¹⁰ We can conclude that MC cysts tend to extend to adjacent regions, especially to the petrous apex – as occurred in the case reported in the present paper.

Of the reported cases, two were treated with drugs alone; five were treated surgically and one had spontaneous resolution. Of the five surgically treated patients, four underwent craniotomy treatment and only one underwent percutaneous treatment with cyst aspiration through the foramen ovale puncture.² In this patient, the control MRI presented cyst persistence and the author attributed the improvement to possible rhizotomy by injected contrast or needle injury.² Moreover, these data show the importance of preoperative differential diagnosis by MRI of lesions in the MC because in all patients undergoing craniotomy, the diagnosis of arachnoid cyst was made intraoperatively, excluding the possibility of less invasive treatment.^{5,6,10,11}

There are reports of petrous apex cephaloceles. These are uncommon lesions, rarely described in the literature and sometimes radiologically indistinguishable from arachnoid cysts of the MC. They are considered by some authors to be the same entity^{2,8}. Defined as cystic lesions with a cerebrospinal fluid-like sign at the petrous apex that protrude through the posterolateral wall of the MC, they can be

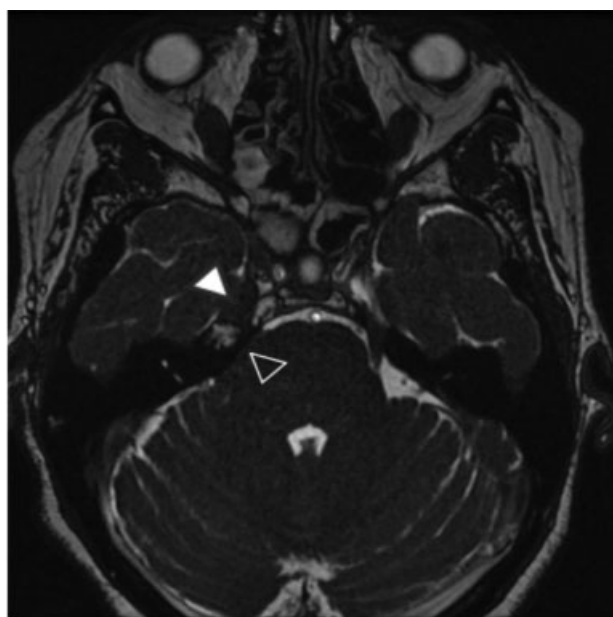


Fig. 3 Postoperative T2-weighted magnetic resonance imaging showing partial filling of the cyst by hypointense material (white arrow) extending through the cisternal segment of the trigeminal nerve (black arrow).

Table 1 Cases Reported in the Literature

Author	Age (years old), gender	Symptoms	Location, side	Treatment
Wörner et al ⁵	44, M	Dysesthesia in V3, vertigo and diplopia	Meckel cave, CPA, R	Open resection
Batra et al ⁶	55, F	Pain and paresthesia in V3	Petrous apex, Meckel's cave, R	Open fenestration
Bigder et al ²	57, F	Pain in V2, temporal muscle atrophy and hemifacial paresthesia	Meckel cave, L	Percutaneous drainage
Fois et al ⁷	42, F	Sensorineural hearing loss and neuralgia	Meckel cave, petrous apex, B	Medication
Jacob et al ⁸	32, F	Diplopia and pain in V1	Meckel cave, R	Spontaneous resolution
Grasso et al ⁹	40, M	Neuralgia in V2-V3	Meckel cave, middle fossa and greater wing of sphenoid, L	Medication
Beck et al ¹⁰	1, M	Exophthalmia and diplopia	Meckel cave, R	Open resection
Jelsma et al ¹¹	58, F	Neuralgia and hemifacial hypoesthesia	Meckel cave, petrous apex, R	Open fenestration

Abbreviations: B, bilateral; CPA, cerebellopontine angle; F, female; L, left; M, male; R, right; V1, ophthalmic trigeminal branch; V2, maxillary trigeminal branch; V3, mandibular trigeminal branch.

composed of dura mater and arachnoid or just arachnoid – being described as meningoceles and arachnoid cysts.^{12–15} However, dilatation may be restricted to the petrous apex without dilatation of the MC and they are usually not associated with trigeminal neuralgia, but with sixth cranial nerve neuropathy and otological symptoms.^{8,12} Possibly, they are part of the same spectrum of disease of the arachnoid cyst in the MC differing only in presentation and progression.

Meckel cave arachnoid cysts are likely to progress and become symptomatic due to their communication with the subarachnoid space and a unidirectional valve mechanism that only allows CSF entry. This communication between the cyst and the CSF system may allow the transmission of pulsations to the nerve and cyst enlargement causing trigeminal neuralgia by a mechanism similar to neurovascular compression.⁹

We describe a noninvasive, effective and safe technique for the treatment of Meckel cave arachnoid cysts. We did not find in the literature a description of the same strategy. The improvement mechanism with this technique is probably the interruption of the communication between the cyst and the cerebrospinal fluid system, which prevents the transmission of pulsations to the nerve and enlargement of the cyst.

Conclusion

Meckel cave arachnoid cysts are rare lesions in which pre-operative differential diagnosis is very important for proper surgical planning and for individualized treatment with less morbidity. Filling the cyst with fibrin sealant by percutaneous puncture was effective for symptomatic control of the

patient with minimal associated morbidity. We consider that this technique should be considered for surgical treatment of this lesion.

Conflict of Interests

The authors have no conflict of interests to declare.

References

- Vernooij MW, Ikram MA, Tanghe HL, et al. Incidental findings on brain MRI in the general population. *N Engl J Med* 2007;357(18):1821–1828
- Bigder MG, Helmi A, Kaufmann AM. Trigeminal neuropathy associated with an enlarging arachnoid cyst in Meckel's cave: case report, management strategy and review of the literature. *Acta Neurochir (Wien)* 2017;159(12):2309–2312
- Mustansir F, Bashir S, Darbar A. Management of Arachnoid Cysts: A Comprehensive Review. *Cureus* 2018;10(04):e2458
- Gusmão SNS, de Oliveira MM, Arantes AA Junior. Rizotomia trigeminal por radiofrequência para tratamento da neuralgia do trigêmeo - resultados e modificação técnica. *Arq Neuropsiquiatr* 2003;61(2-B):434–440
- Wörner BA, Noll M, Rahim T, Fink U, Oeckler R. Recurrent arachnoid cyst of Meckel's cave mimicking a brain stem ischaemia. Report of a rare case. *Zentralbl Neurochir* 2003;64(02):76–79
- Batra A, Tripathi RP, Singh AK, Tatke M. Petrous apex arachnoid cyst extending into Meckel's cave. *Australas Radiol* 2002;46(03):295–298
- Fois P, Lauda L. Bilateral Meckel's cave arachnoid cysts with extension to the petrous apex in a patient with a vestibular schwannoma. *Otol Neurotol* 2011;32(05):e36–e37
- Jacob M, Gujar S, Trobe J, Gandhi D. Spontaneous resolution of a Meckel's cave arachnoid cyst causing sixth cranial nerve palsy. *J Neuroophthalmol* 2008;28(03):186–191
- Grasso G, Passalacqua M, Giambardino F, Cacciola F, Caruso G, Tomasello F. Typical trigeminal neuralgia by an atypical

- compression: case report and review of the literature. *Turk Neurosurg* 2014;24(01):82–85
- 10 Beck DW, Menezes AH. Lesions in Meckel's cave: variable presentation and pathology. *J Neurosurg* 1987;67(05):684–689
 - 11 Jelsma F, Ross PJ. Traumatic intracranial arachnoid cyst involving the Gasserian ganglion. Case report. *J Neurosurg* 1967;26(04):439–441
 - 12 Moore KR, Fischbein NJ, Harnsberger HR, et al. Petrous apex cephaloceles. *AJNR Am J Neuroradiol* 2001;22(10):1867–1871
 - 13 Alkilic-Genauzeau I, Boukobza M, Lot G, George B, Merland JJ. CT and MRI features of arachnoid cyst of the petrous apex: report of 3 cases. *J Radiol* 2007;88:1179–1183
 - 14 Alorainy IA. Petrous apex cephalocele and empty sella: is there any relation? *Eur J Radiol* 2007;62(03):378–384
 - 15 Isaacson B, Coker NJ, Vrabec JT, Yoshor D, Oghalai JS. Invasive cerebrospinal fluid cysts and cephaloceles of the petrous apex. *Otol Neurotol* 2006;27(08):1131–1141