



Functional Evolution after Percutaneous Endoscopic Lumbar Discectomy, an Earlier Evaluation of 32 Cases*

Evolução funcional após discectomia endoscópica lombar, uma avaliação mais precoce de 32 casos

Bruno César Aprile¹  Marcelo Campos Moraes Amato² Cézar Augusto de Oliveira¹

¹ Department of Spine, Clínica SOU, São Paulo, SP, Brazil

² Department of Spine, Instituto Amato, São Paulo, SP, Brazil

Address for correspondence Bruno César Aprile, MD, Clínica SOU, R. Arcipreste Andrade 727, cj 145, Ipiranga, São Paulo, SP, 04268-020, Brazil (e-mail: dr.brunoaprive@gmail.com).

Rev Bras Ortop 2020;55(4):415–418.

Abstract

Objective To determine time period for hospital discharge and pain and function improvement in patients submitted to percutaneous endoscopic lumbar discectomy (PELD).

Methods Retrospective evaluation of length of stay and visual analog scale (VAS), Oswestry disability index (ODI), and Roland-Morris questionnaire results in 32 patients undergoing PELD at the preoperative period and at 2 days and 1, 2, 4, 6 and 12 postoperative weeks.

Results All patients were discharged in less than 6 hours. There was a statistically significant improvement between the results obtained before the procedure and 2 days postsurgery: the mean VAS for axial pain went from 6.63 to 3.31, the VAS for irradiated pain went from 6.66 to 2.75, the Oswestry score went from 44.59 to 33.17%, and the Roland-Morris score went from 14.03 to 10.34. This difference progressively improved up to 12 weeks in all questionnaires. Regarding the Oswestry score, minimum disability values (19.39%) were observed at 6 weeks.

Conclusion All 32 patients were discharged within 6 hours. Pain and function improved significantly after 48 hours, with further significant and progressive improvement until the 3rd month.

Keywords

- ▶ vertebral spine
- ▶ intervertebral disc dislocation
- ▶ outcome evaluation (healthcare)
- ▶ endoscopy

Resumo

Objetivo Determinar o tempo de alta hospitalar e o período de melhora funcional e da dor dos pacientes submetidos a discectomia endoscópica percutânea lombar (DEPL).

Métodos Avaliação retrospectiva do tempo de internação e dos questionários escala visual análoga (EVA), índice de incapacidade Oswestry (IIO), e Roland-Morris de 32 pacientes submetidos a DEPL nos períodos pré-operatório e com 2 dias, e 1, 2, 4, 6, e 12 semanas pós-operatórias.

Resultados Todos os pacientes receberam alta em menos de 6 horas houve melhora estatística entre o período pré-operatório e 2 dias pós-operatório, sendo o valor

* Work developed at Clínica SOU and at Instituto Amato, São Paulo, SP, Brazil.



Palavras-chave

- coluna vertebral
- deslocamento do disco intervertebral
- avaliação de resultados (cuidados de saúde)
- endoscopia

médio do questionário EVA axial de 6,63 para 3,31, do EVA irradiado de 6,66 para 2,75, do IIO de 44,59% para 33,17% e do Roland-Morris de 14,03 para 10,34. Tal diferença apresentou melhora progressiva até 12 semanas em todos os questionários. O IIO atingiu valores de incapacidade mínima (19,39%) com 6 semanas de avaliação.

Conclusão Todos os 32 pacientes receberam alta hospitalar em até 6 horas. Houve melhora significativa dos sintomas funcionais e de dor já com 48 horas, apresentando ainda melhora adicional significativa e progressiva até o 3° mês.

Introduction

The standard treatment for symptomatic lumbar disc herniation without instability is microdiscectomy decompression (MDL).¹ Other less aggressive techniques have been developed, such as percutaneous endoscopic lumbar discectomy (DEPL), which shows sufficient evidence of similar medium- and long-term safety and effectiveness when compared to MDL.²⁻⁴ There is no consensus or definitive scientific evidence regarding the superiority of this technique over MDL. When comparing medium- and long-term (6 months and more than 2 years), primary outcomes (pain improvement, complication incidence, and functional outcomes) some studies show similar results,^{5,6} whereas others demonstrate DEPL superiority over MDL in both primary⁷⁻⁹ and secondary outcomes (surgical time, length of stay and bleeding volume).^{10,11} Supported by studies with earlier initial assessment,^{12,13} we have designed a patient evaluation protocol that starts much earlier than most studies on DEPL, beginning 48 hours after surgery, while the first assessment usually takes place within 4 to 6 weeks. Since the technique's medium- and long-term safety and effectiveness are proven,¹⁴⁻¹⁸ we want to verify when clinical improvement actually begins, which may be a determining factor in choosing between surgical techniques with similar results.

Materials and Methods

We retrospectively evaluated prospectively collected data from 32 consecutive patients undergoing DEPL. All patients had single lumbar disc hernia, with symptoms for more than 3 months, accompanied by radiculopathy or not, and failed conservative treatment. All patients underwent elective surgeries, either interlaminar or transforaminal (in cases with foraminal disc disease), performed at private or accredited clinics and hospitals in São Paulo, SP, Brazil, between 2014 and 2017. Patients received postoperative analgesia, consisting in nimesulide 100 mg, every 12 hours for 7 days, dipyrone 1 g, every 8 hours for 10 days, and tramadol hydrochloride 50 mg up to every 8 hours, as required.

Patients with spondylolisthesis, previous lumbar surgeries, and spinal stenosis were excluded.

In addition to the time of hospital discharge, the visual analog scale (VAS, for both axial and irradiated pain), Oswestry disability index (ODI) and Roland-Morris questionnaire scores were recorded preoperatively, at 2 days, and at 1, 2, 4, 6, and 12 weeks postoperatively.

This research was approved by the ethics committee of the institution under number CAAE 90766918.8.0000.5449.

Results

The study included 21 men and 11 women (N=32) aged between 22 and 71 years (mean age, 39.8 years). The average scores at each questionnaire are shown in ►Figures 1, 2, and 3 and ►Table 1.

The mean results showed a statistically significant reduction in scores between preoperative values and those obtained 2 days after surgery; the VAS for axial pain went from 6.63 to 3.31; the VAS for irradiated pain went from 6.66 to 2.75; the Oswestry score went from 44.59 to 33.17%, and the Roland-Morris score went from 14.03 to 10.34. This difference progressively improved up to 12 weeks postoperatively. Regarding the Oswestry score, minimum disability values (19.39%) were observed at 6 weeks.

In the comparison between average results obtained at 2 days and 12 weeks after surgery, there was a statistically significant reduction in the VAS for axial pain, which went from 3.31 to 1.94; in the Oswestry score, which went from 33.17 to 14.31%, and in the Roland-Morris score, which went from 10.34 to 3.97; the reduction of VAS for irradiated pain from 2.75 to 1.78, however, showed no statistical difference.

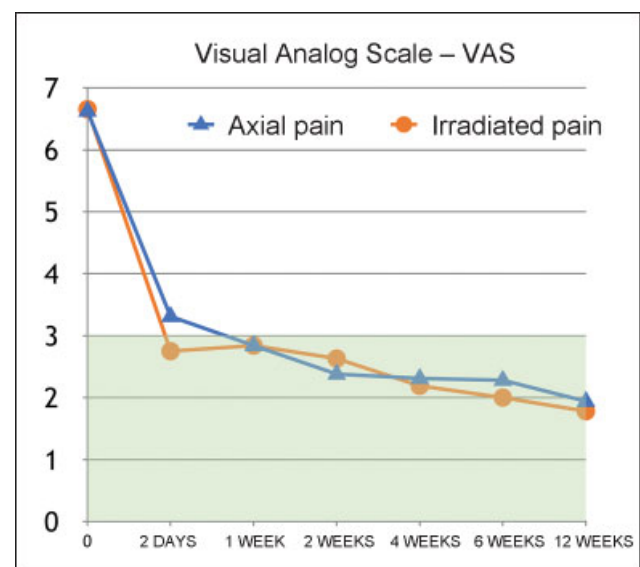


Fig. 1 Visual analog scale.

OSWESTRY

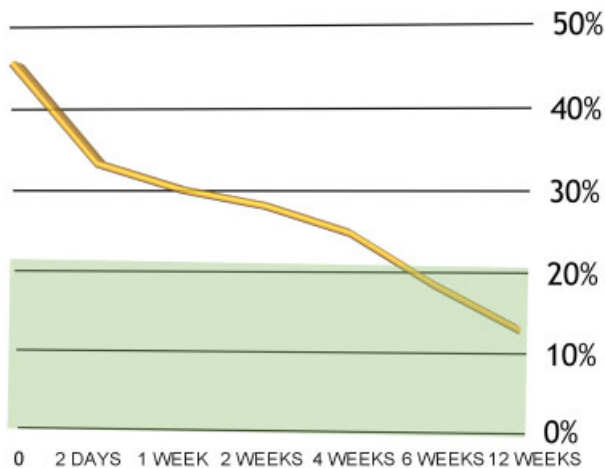


Fig. 2 Oswestry questionnaire.

All patients were discharged within 6 hours. There was no readmission or supplementary surgery. Two patients (6.45%) presented de novo disc herniation without neurological deficit; both decided on conservative treatment, with progressive improvement.

There were no cases of significant bleeding, dural injury, or motor neurological deficit. There was one case (3.13%) of orthostatic headache with no dural lesion identified at the procedure, with resolution at 6 weeks, without fistula formation or cerebrospinal fluid collection. In addition, there was one case (3.13%) of dysesthesia at the operated dermatome,

ROLAND MORRIS

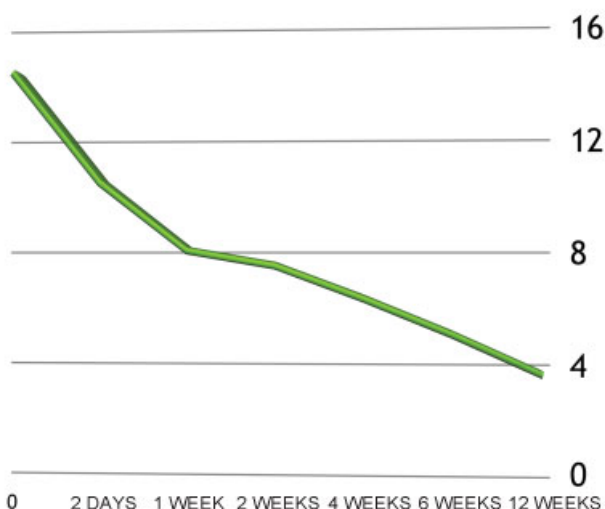


Fig. 3 Roland-Morris questionnaire.

Table 1 Average questionnaire scores

	VAS for axial pain	VAS for irradiated pain	Oswestry	Roland-Morris
0	6.63	6.66	44.59	14.03
2 DAYS	3.31	2.75	33.17	10.34
1 WEEK	2.84	2.84	30.22	8.06
2 WEEKS	2.38	2.63	28.38	7.56
4 WEEKS	2.31	2.19	25.31	6.47
6 WEEKS	2.28	2	19.39	5.28
12 WEEKS	1.94	1.78	14.31	3.97

Abbreviation: VAS, Visual analog scale.

with resolution in 3 weeks with medication and physical therapy.

Statistical analysis was performed at Minitab 18.1 (Minitab, Inc, State College, PA, USA), with analysis of variance in a generalized linear model and Tukey paired comparisons for time variables. Grouping was performed using the Tukey method and a 95% confidence interval.

Discussion

Among the minimally invasive spinal surgeries, DEPL has advantages, including the possibility of performing it under local anesthesia, paraspinal structures preservation, and minimal postoperative pain.¹⁹ Although these characteristics favor early discharge and faster recovery, previous studies began their evaluations only 4 or 6 weeks after surgery, losing the chance to assess whether there is an earlier improvement of the symptoms, one of the real benefits of this method.^{14–18}

The improvement observed in the present study, when preoperative pain and functional questionnaires scores were compared with those obtained 12 weeks after surgery, is compatible with that of other published series.^{19,20} Choi et al.⁴ showed parameters improvement starting at the 1st month. However, the confirmation of a significant reduction in pain and functional questionnaires scores beginning at 2 days after surgery is unprecedented, thus demonstrating an even earlier symptom improvement with DEPL.

In a literature review, Birkenmaier et al.¹¹ only considered the last functional evaluation, with 2 or more years of follow-up. Other authors¹⁷ do not specify when questionnaires were applied. Therefore, despite the existence of studies demonstrating the superiority of DEPL over MDL due to lesser tissue injury,⁷ expressive pain relief and reduced complication incidence,⁸ reduced surgical time and better disc height preservation,^{18,21} we still do not know for sure when pain improves and the required length of stay, since published results are conflicting. This work intends to confirm that DEPL-induced improvement is earlier than usually reported.

The earliest improvement was observed in pain-related questionnaires, followed by functional questionnaires; this may be the result of a postoperative fear, from both patients

and physicians, in resuming usual activities due to the risk of a de novo disc herniation.

Hospital discharge in less than 6 hours for 100% of the cases is consistent with the description of DEPL as an outpatient surgery. Most studies describe early discharges but fail to quantify its exact timing. In 2009, Lee et al.¹⁹ described a series of 25 patients who underwent DELP with a mean length of stay of 0.9 day; however, other series reported later discharges.²² The literature shows recurrence rates ranging from 0 to 11.1%,²³ with up to 20.9% of reoperation rate;⁴ our results are consistent with such findings, with a recurrence rate of 6.45%, and a reoperation rate of 0%.

Conclusion

All 32 patients from this series were discharged within 6 hours of the end of the procedure. Patients present significant improvement of painful and functional symptoms starting at 48 hours postoperatively. Pain and functional scores continued to improve up to 12 weeks after surgery. In this series, functional and pain scores improved earlier than described in the literature for patients undergoing DEPL.

Conflict of Interests

The authors declare that there are no conflict of interests.

References

- Botelho RV, Canto FT, Carvalho MV, et al. Diretrizes Clínicas na Saúde Suplementar - Hérnia de disco Lombar no Adulto: Tratamento Cirúrgico. São Paulo: Sociedade Brasileira de Ortopedia e Traumatologia e Sociedade Brasileira de Neurocirurgia; 2011
- Peng CWB, Yeo W, Tan SB. Percutaneous endoscopic lumbar discectomy: clinical and quality of life outcomes with a minimum 2 year follow-up. *J Orthop Surg Res* 2009;4:20
- Ruetten S, Komp M, Merk H, Godolias G. Full-endoscopic interlaminar and transforaminal lumbar discectomy versus conventional microsurgical technique: a prospective, randomized, controlled study. *Spine* 2008;33(09):931-939
- Choi KC, Kim JS, Park CK. Percutaneous Endoscopic Lumbar Discectomy as an Alternative to Open Lumbar Microdiscectomy for Large Lumbar Disc Herniation. *Pain Physician* 2016;19(02):E291-E300
- Phan K, Xu J, Schultz K, et al. Full-endoscopic versus microendoscopic and open discectomy: A systematic review and meta-analysis of outcomes and complications. *Clin Neurol Neurosurg* 2017;154(01):1-12
- Ruan W, Feng F, Liu Z, Xie J, Cai L, Ping A. Comparison of percutaneous endoscopic lumbar discectomy versus open lumbar microdiscectomy for lumbar disc herniation: A meta-analysis. *Int J Surg* 2016;31:86-92
- Pan L, Zhang P, Yin Q. Comparison of tissue damages caused by endoscopic lumbar discectomy and traditional lumbar discectomy: a randomised controlled trial. *Int J Surg* 2014;12(05):534-537
- Feng F, Xu Q, Yan F, et al. Comparison of 7 Surgical Interventions for Lumbar Disc Herniation: A Network Meta-analysis. *Pain Physician* 2017;20(06):E863-E871
- Ahn SS, Kim SH, Kim DW, Lee BH. Comparison of Outcomes of Percutaneous Endoscopic Lumbar Discectomy and Open Lumbar Microdiscectomy for Young Adults: A Retrospective Matched Cohort Study. *World Neurosurg* 2016;86:250-258
- Li X, Han Y, Di Z, et al. Percutaneous endoscopic lumbar discectomy for lumbar disc herniation. *J Clin Neurosci* 2016;33:19-27
- Birkenmaier C, Komp M, Leu HF, Wegener B, Ruetten S. The current state of endoscopic disc surgery: review of controlled studies comparing full-endoscopic procedures for disc herniations to standard procedures. *Pain Physician* 2013;16(04):335-344
- Casimiro M. Short-Term Outcome Comparison Between Full-Endoscopic Interlaminar Approach and Open Minimally Invasive Microsurgical Technique for Treatment of Lumbar Disc Herniation. *World Neurosurg* 2017;108:894-900.e1
- Li M, Yang H, Yang Q. Full-Endoscopic Technique Discectomy Versus Microendoscopic Discectomy for the Surgical Treatment of Lumbar Disc Herniation. *Pain Physician* 2015;18(04):359-363
- Kapetanakis S, Giannopoulou E, Charitoudis G, Kazakos K. Health-related quality of life (HRQoL) following transforaminal percutaneous endoscopic discectomy (TPED) for lumbar disc herniation: A prospective cohort study - early results. *J Back Musculoskeletal Rehabil* 2017;30(06):1311-1317
- Chen HT, Tsai CH, Chao SC, et al. Endoscopic discectomy of L5-S1 disc herniation via an interlaminar approach: Prospective controlled study under local and general anesthesia. *Surg Neurol Int* 2011;2:93
- Porchet F, Bartanusz V, Kleinstueck FS, et al. Microdiscectomy compared with standard discectomy: an old problem revisited with new outcome measures within the framework of a spine surgical registry. *Eur Spine J* 2009;18(Suppl 3):360-366
- Li XC, Zhong CF, Deng GB, Liang RW, Huang CM. Full-Endoscopic Procedures Versus Traditional Discectomy Surgery for Discectomy: A Systematic Review and Meta-analysis of Current Global Clinical Trials. *Pain Physician* 2016;19(03):103-118
- Markovic M, Zivkovic N, Ruetten S, Ozdemir S, Goethel D. Full-endoscopic interlaminar versus microsurgical operations in lumbar compressive lesions surgery: prospective randomized trial of overall 570 patients. *J Pain Relief* 2017;6(06):1-7
- Lee DY, Shim CS, Ahn Y, Choi YG, Kim HJ, Lee SH. Comparison of percutaneous endoscopic lumbar discectomy and open lumbar microdiscectomy for recurrent disc herniation. *J Korean Neurosurg Soc* 2009;46(06):515-521
- Ruetten S, Komp M, Merk H, Godolias G. Full-endoscopic cervical posterior foraminotomy for the operation of lateral disc herniations using 5.9-mm endoscopes: a prospective, randomized, controlled study. *Spine* 2008;33(09):940-948
- Lee SH, Chung SE, Ahn Y, Kim TH, Park JY, Shin SW. Comparative radiologic evaluation of percutaneous endoscopic lumbar discectomy and open microdiscectomy: a matched cohort analysis. *Mt Sinai J Med* 2006;73(05):795-801
- Righesso O, Falavigna A, Avanzi O. Comparison of open discectomy with microendoscopic discectomy in lumbar disc herniations: results of a randomized controlled trial. *Neurosurgery* 2007;61(03):545-549, discussion 549
- Matsumoto M, Watanabe K, Hosogane N, et al. Recurrence of lumbar disc herniation after microendoscopic discectomy. *J Neurol Surg A Cent Eur Neurosurg* 2013;74(04):222-227
- Tenenbaum S, Arzi H, Herman A, et al. Percutaneous posterolateral transforaminal endoscopic discectomy: clinical outcome, complications, and learning curve evaluation. *Surg Technol Int* 2011;21:278-283