




# Functional Results of Transverse Extended Incision in Cervical Neck Dissection

Carlos Miguel Chiesa-Estomba<sup>1</sup>  Jon Alexander Sistiaga-Suarez<sup>1</sup> Izaskun Thomas-Arrizabalaga<sup>1</sup>  
Jose Angel González-García<sup>1</sup> Ekhiñe Larruscain<sup>1</sup> Xabier Altuna<sup>1</sup>

<sup>1</sup>Department of Otorhinolaryngology – Head and Neck Surgery, Hospital Universitario Donostia, País Vasco, Spain

Int Arch Otorhinolaryngol 2021;25(1):e27–e34.

Address for correspondence Carlos Chiesa, MD, MSc, Department of Otorhinolaryngology – Head and Neck Surgery, Hospital Universitario Donostia, Calle Virgen del Carmen, #28, 5to C. CP. 20012, San Sebastian, Donosti, País Vasco, Spain (e-mail: chiesaestomba86@gmail.com).

## Abstract

**Introduction** Multiple incisions have been described for the surgical approach of cervical neck nodes. All of these descriptions are associated with better or worse exposure of the surgical field as well as with different functional and aesthetic results, which are not always satisfactory.

**Objective** Compare the transverse cervical incision with the classic incision in J or U.

**Methods** This is a retrospective study of 47 patients who required cervical neck dissection between June 15, 2016 and June 15, 2017. A transversal incision was made in these surgeries, and their results were then compared with those of a group of 57 patients treated between January 1, 2010 and January 1, 2012, in whose cases an incision in J or U was made.

**Results** Regarding the incision type, complications were present in 4 (8.5%) cases in the transversal incision group, and in 7 (12.2%) patients of the group of traditional incisions in J or U, without statistical differences ( $p = 0.078$ ). The only variables associated with complications of healing in the two groups was body mass index (BMI) < 18.5. The patients showed subjective satisfaction with the aesthetic result of the transverse incision, with an average of 7.51 vs 6.20 in the J or U incision.

**Conclusion** The transverse incision represents a safe, aesthetic, and oncologically adequate option, associated with a lower cicatricial retraction rate, without significant complication rate and allowing adequate exposure of the surgical field, similar to the obtained with the classic incision in J or U.

## Keywords

- ▶ cervical neck dissection
- ▶ postoperative complication
- ▶ scar

## Introduction

Since the original description of radical neck dissection proposed by Crile in 1906,<sup>1</sup> which included the resection of the sternocleidomastoid (SCM) muscle, the jugular vein (YV), and the spinal nerve (SN), to the evolution of the technique to the functional neck dissection following the

fascial plane described by Suarez<sup>2</sup> and popularized by Gavilan<sup>3</sup> and Bocca,<sup>4</sup> passing through the classification of selective and modified radical neck dissection proposed by the American Academy of Otolaryngology-Head and Neck Surgery (AAO-HNS),<sup>5</sup> multiple cervical incisions have been described with the purpose of carrying out this type of surgical intervention.

received  
December 11, 2018  
accepted  
October 30, 2019  
published online  
April 24, 2020

DOI <https://doi.org/10.1055/s-0039-3402439>.  
ISSN 1809-9777.

© 2020. Fundação Otorrinolaringologia. All rights reserved.  
This is an open access article published by Thieme under the terms of the Creative Commons Attribution-NonDerivative-NonCommercial-License, permitting copying and reproduction so long as the original work is given appropriate credit. Contents may not be used for commercial purposes, or adapted, remixed, transformed or built upon. (<https://creativecommons.org/licenses/by-nc-nd/4.0/>)  
Thieme Revinter Publicações Ltda., Rua do Matoso 170, Rio de Janeiro, RJ, CEP 20270-135, Brazil

Kocher, in 1880,<sup>6</sup> and Kuettner, in 1898,<sup>7</sup> would describe the first incisions for neck node dissection. In 1951, Martin would report the incision in double Y,<sup>8</sup> and MacFee, in 1960, would describe the double transverse incision.<sup>9</sup> Meanwhile, in Europe, the bi-mastoid incision, related by Gluck-Sorensen and Tapia, as well as the J incision, described by Paul-André, became more popular.<sup>10</sup> In 1957, Attie described the use of transverse cervical incision as the technique of choice when performing radical neck dissection<sup>11</sup> and since 1979, thanks to the studies performed by Becker, this incision became popular in the United States.<sup>12</sup>

Among all the incisions, it will be essential to follow some criteria that help us choose the best one. These criteria can be grouped as follows: 1) Adequate exposure of the surgical field, 2) Adequate blood flow to the apron flaps, 3) Adequate relationship of the incision to the YV and the carotid artery (CA), 4) Easy conversion or adequate to access to the resection of a primary tumor, 5) Useful to create the tracheal stoma 6) Compatible with any reconstructive effort and 7) Aesthetically acceptable.<sup>6</sup>

In our center, the extended cervical (horizontal) transverse incision was introduced in 2012, and it began to be systematically performed in any cervical neck dissection since 2014, modifying and expanding the incision when the primary tumor resection was required. Once the procedure is standardized, we can present our results below.

## Materials and Methods

A retrospective analysis was performed with the approval of the ethics committee of our institution. Forty-seven patients diagnosed with malignant head & neck tumors between June of 2016 and June of 2017 who required a primary surgical treatment or rescue, accompanied by a selective, radical modified or radical neck dissection with at least 6 months of postoperative follow-up in which an extended transverse incision was used were included as a study group. All tumors were classified according to the criteria of the *Union Internationale Contre le Cancer* (UICC) and the American Joint Committee on Cancer (AJCC—7th edition). All patients requiring a surgical

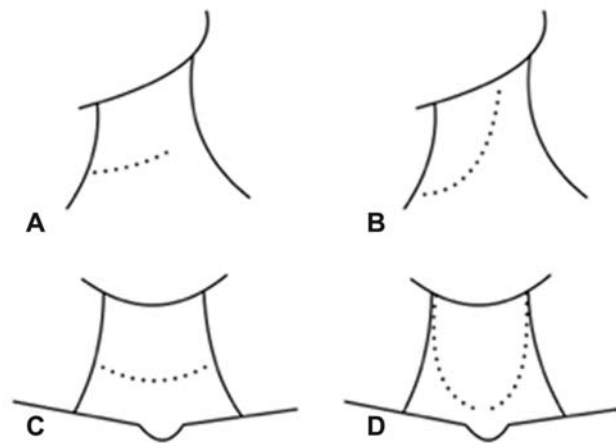
reintervention or cutaneous reconstruction were excluded. As a control group, we included a historical retrospective cohort of those patients who required surgical treatment for similar indications, between January of 2010 and January of 2012, in which the incision used was in J (Paul-Andre) or classic U (Gluck-Sorensen-Tapia). (→Fig. 1).

Patients previously treated by radiotherapy (RT) or chemotherapy/radiotherapy (CT/RT) and who were considered candidates for salvage surgery due to tumor recurrence received standard RT as organ preservation treatment at doses of 2 Gy daily, for a total dose of between 64 and 70 Gy. The patients who required CT were given a regimen of cisplatin (100 mg/m<sup>2</sup>) every 3 weeks. In the postoperative setting, some patients precise postoperative radiation therapy treatment for a total dose of between 66 and 70 Gy for those with high-risk factors, and 50 and 54 for those with low-risk factors.

Regarding the surgical technique, a transverse (horizontal) incision was performed at the level of the midline of the thyroid cartilage when a selective supraomohyoid or cervical jugular dissection was involved. When the neck dissection includes level V, the incision will be drawn at the level of the cricothyroid membrane. The extension of the incision will depend on the type of neck dissection to be performed. In case of unilateral neck dissection, the incision will start from the posterior edge of the SCM muscle and will exceed 2 cm of the midline in the contralateral direction. If it is necessary to include the level V, the incision may extend up to 3 cm behind the posterior edge of the ESCM. In the case of bilateral cervical neck dissection, the incision would extend on both sides of the neck to the posterior border of the SCM. The upper flap will be elevated until the lower border of the jaw is palpated, and the lower flap is then raised to the level of the clavicle. If a first intraoral approach is necessary, the incision will rise parallel to the tassel of the chin, and we will have to incise the midline at the level of the lip. If it is necessary to include the parotid in the neck dissection, we will start by making a modified Blair incision and continue our incision at the level of a horizontal fold of the neck. Once elevated, both flaps are fixed with Lone Star surgical elastic bands (Lone Star Surgical, Laredo, TX, USA) (→Fig. 1).

Due to the absence of specific scales validated regarding aesthetic results in cervical incisions after oncological surgery, a visual analogue scale (VAS) was presented to each patient 6 months after surgery questioning about the aesthetic results and life quality, and the surgeons were consulted regarding the wound results. Great auricular nerve damage was evaluated subjectively according to the patient's sensation the day after surgery in the ward round.

The statistical analysis was performed using the JASP - Version 0.8.5.1 computer software (University of Amsterdam, Amsterdam, Netherlands). The Kolmogorov-Smirnov was used to assess the normal distribution. The quantitative variables within the study are expressed as a mean ± standard deviation; the results are expressed as both total and percentage. The Chi-squared test and the Fischer test were used in the univariate analysis. The comparison concerning partial or total necrosis of the flap, aesthetic results and quality of life between both groups was performed using the Student *t*-test for paired data and the *p*-value < 0.05 was considered significant.



**Fig. 1** A) Unilateral transverse - Horizontal incision B) Incision in J of Paul-Andre. C) Bilateral transverse - Horizontal incision D) Bimastoid incision in U of Gluck-Sorensen-Tapia.

## Results

A total of 104 patients were included. Forty-seven patients in the study group, 38 men (80.9%) and 9 women (19.1%) with an average age of 62.79 years ( $\pm 12.19$ ; min: 35/max: 84). Fifty-seven patients were included in the control group, 35 men (61.4%) and 22 women (38.6%) with an average age of 62.02 years ( $\pm 11.28$ ; min: 30/max: 82). The clinical and demographic data can be seen in **Table 1**.

Sixty-nine cervical neck dissections were performed in the study group, and 70 in the control group. The type of surgery can be reviewed in **Table 2**, the type of cervical neck dissection performed and the frequency of these can be reviewed in **Table 3**. It was possible to isolate an average of  $18 \pm 7$  (min: 11/max: 39) lymph nodes in the study group, while in the historical control group an average of  $16 \pm 5$

lymph nodes were isolated (min: 6/max: 29). Regarding complications related to the incision or the elevation of both flaps, we did not find significant differences regarding complications between both ( $p = 0.078$ ) (**Table 4**). In the univariate analysis, factors that could be associated with an alteration in healing were included, with malnutrition being the only factor related to flap damage ( $p = 0.001$ ). Regarding the aesthetic result, the patients showed subjective compliance according to VAS, with a mean of 7.25 in the study group and 6.20 in the historical cohort ( $p = 0.002$ ). According to their quality of life, the patients in the study group report a mean of 6.91 versus a 7.71 in the historical cohort ( $p = 0.721$ ). The aesthetic assessment of the surgeon regarding the wound results in the follow-up was favorable in 65.7% of the cases in the study group and 60% of cases in the historical cohort (**Table 5**).

**Table 1** Demographic data and statistical comparison of the variables associated with failure during the post-surgical healing

Variable	Transverse incision - N (%)	J or U incision - N (%)	P (UA)
Sex			
Men	38 (80.9)	35 (61.4)	
Women	9 (19.1)	22 (38.6)	
Age	62.79 $\pm$ 12.1 (Min: 25/Max: 84)	62.02 $\pm$ 11.28 (Min: 30/Max: 82)	0.984
ASA			
1	0 (0)	1 (1.8)	0.830
2	24 (51.1)	25 (43.9)	
3	22 (46.8)	31 (54.4)	
4	1 (2.1)	0 (0)	
COPD			
Yes	8 (17)	10 (17.5)	0.736
No	39 (83)	47 (82.5)	
Cardiopathy			
Yes	14 (29.8)	17 (29.8)	0.602
No	33 (70.2)	40 (70.2)	
Smoker			
Yes	33 (70.2)	19 (33.3)	0.249
No	8 (17)	8 (14)	
Ex	6 (12.8)	30 (52.6)	
Mean number of packages per year	38.5 $\pm$ 28.88 (Min 10/Max: 100)	26.58 $\pm$ 16.7 (Min: 12/Max: 60)	
Alcohol			
Yes (> 70 g/day)	36 (76.6)	44 (77.19)	0.605
No (< 70 g/day)	11 (23.4)	13 (22.8)	
BMI < 18.5			
Yes	8 (17)	4 (7)	0.001
No	39 (83)	53 (93)	

(Continued)

**Table 1** (Continued)

Variable	Transverse incision - N (%)	J or U incision - N (%)	P (UA)
Obesity			
Yes	14 (29.8)	2 (3.5)	0.190
No	33 (70.2)	55 (96.5)	
Hypertension (HTA)			
Yes	20(42.6)	21 (36.8)	0.700
No	27 (57.4)	36 (63.2)	
Diabetes Mellitus (DM)			
Yes (non-insulin dependent)	11 (23.4)	11 (19.3)	0.100
No	36 (76.6)	46 (80.7)	
Tx	0 (0)	7 (12.3)	0.018
T1	5 (10.6)	7 (12.3)	
T2	17 (36.2)	24 (42.1)	
T3	7 (14.9)	9 (15.8)	
T4	18 (38.3)	10 (17.54)	
N0	24 (51.1)	18 (31.6)	0.365
N1	11 (23.4)	13 (22.8)	
N2a	3 (6.3)	14 (24.6)	
N2b	8 (17)	7 (12.3)	
N2c	1 (2.1)	3 (5.3)	
N3	0 (0)	2 (3.5)	
M0	47 (100)	57 (100)	
M1	0 (0)	0	
Histology			0.771
- Squamous cell carcinoma	44 (94.6)	51 (89.5)	
- Adenocarcinoma	3 (5.4)	4 (7.1)	
- Melanoma	0 (0)	1 (1.8)	
- Undifferentiated nasopharyngeal carcinoma	0 (0)	1 (1.8)	
RT or previous CT/RT	6 (12.7)	14 (24.6)	0.079
Parcial o total flap damage	4 (8.5)	7 (12.2)	0.078

Abbreviations: BMI, body mass index; COPD, chronic obstructive pulmonary disease; CT, chemotherapy; DM, ; HTDA, ; RT, radiotherapy. P (UA), univariate analysis.

The statistical result for partial or total damage of the flap corresponds to the comparison between both groups.

## Discussion

Before performing a cervical neck dissection, it is essential to know the vascularization patterns of the skin in the neck. Kambic and Sirca, in 1967, showed that the lateral cervical cutaneous vascularization was directed vertically, receiving blood supply from the descending perforating branches of the facial, submental, occipital, posterior auricular and external carotid arteries, as well as from the ascending branches of the transverse cervical and suprascapular artery. Also, the plati-smocutaneous branches of the superior thyroid artery irrigate the skin of the anterior region in the neck.<sup>13</sup> In 1985, Rabson et al, in a study performed on cadavers, describe the presence

of arterial perforators of the platysma muscle to the skin of the neck as well as the anastomosis between them, which will guarantee arterial blood supply at this level during the elevation of the apron flap.<sup>14</sup>

Despite the different incisions described in the literature, it is evident that most of them do not respect the natural skin tension lines originally described by Langer,<sup>15</sup> with the increased risk of contractures at the level of the scar or the appearance of keloids or hypertrophic scars. The alteration of these tension lines secondary to cicatricial retraction will condition the range of cervical mobility,<sup>16</sup> causing pain, in some cases, which may be disabling, directly affecting the physical activity and quality of life of the patient.

**Table 2** Type of surgery performed

Type of surgery	Transverse incision – N (%)	J or U incision – N (%)
TL + CND	12 (26.5)	12 (21.1)
TLM + CND	5 (10.6)	7 (12.28)
THPLM + CND	5 (10.6)	3 (5.26)
Glossectomy + CND	5 (10.6)	5 (8.8)
Transoral oropharyngectomy + CND	9 (19.1)	2 (3.5)
FM + CND	1 (2.1)	0 (0)
RND	4 (8.5)	5 (8.8)
MND	0 (0)	10 (17.5)
Parotidectomy + CND	3 (6.4)	4 (7.32)
Submaxilectomy + CND	1 (2.1)	1 (1.8)
Maxilectomy + CND	1 (2.1)	0 (0)
Cheek Mucosa + CND	1 (2.1)	0 (0)
Regional flap		
- Pec major flap	4 (8.5)	3 (5.3)
- Supraclavicular island flap	2 (4.25)	0 (0)
- FAMM	2 (4.25)	0 (0)
Free Flap		
- Radial forearm flap	1 (2.1)	2 (3.5)
- Fibula	1 (2.1)	0 (0)

Abbreviations: CND, cervical neck dissection; FAMM, facial artery musculo-mucosal flap; FM, floor of the mouth; MND, modified neck dissection; RND, radical neck dissection; THP, transoral hypopharyngeal Co2 laser microsurgery; TL, total laryngectomy; TLM, transoral Co2 laser microsurgery - glottis and supraglottis are included.

Since the inclusion of RT in the treatment schemes of head and neck tumors, there has been an increased risk of healing failure. From the initial works presented by Ellis<sup>17</sup> and Stell,<sup>18</sup> who described failures in the wound primary closure of 79% and 55% of the cases, respectively, several series report similar results, with the posterior flap and the trifurcation area being the most frequent sites of necrosis and dehiscence, leading to an increased risk of carotid exposure and blowout.<sup>19</sup> Acar et al,<sup>20</sup> in a series in which included 320 patients who had undergone a J incision, described a dehiscence rate of 12.6%, a rate of apron flap necrosis of 3.3%, and contracture at the

**Table 3** Type of cervical neck dissection performed and mean of isolated lymph nodes

Type (Levels)	Transverse incision (%)	Mean of node isolated	J or U Incision (%)	Mean of node isolated
JND (II-IV)	49 (71.3)	18 ± 7 (Min: 11/Max: 39)	55 (78.57)	16 ± 5 (Min: 6/Max: 29)
SOHND (I-III)	14 (20.3)	18 ± 8 (Min: 13/Max: 33)	6 (8.57)	14 ± 7 (Min: 8/Max: 21)
RMND (I-V)	3 (4.34)	21 ± 7 (Min: 18/Max: 26)	5 (7.14)	19 ± 4 (Min: 17/Max: 24)
Parotidectomy + ND (II, III y V)	3 (4.34)	17 ± 3 (Min: 16/Max: 22)	4 (5.71)	15 ± 5 (Min: 13/Max: 19)
Total	69 (100)	18 ± 7 (Min:11/Max: 39)	70 (100)	16 ± 5 (Min: 6/Max 29)

Abbreviations: JND, jugular neck dissection; RMND, radical modified neck dissection; SOHND, supraomohyoid neck dissection.

**Table 4** Postsurgical complications

Type	Transverse incision number (%)	J or U incision number (%)
Bleeding	7 (14.9)	2 (3.6)
Marginal paresis	4 (8.51)	2 (3.6)
Surgical flap dehiscence	3 (6.38)	5 (8.77)
Tracheal stoma suture dehiscence	1 (2.1)	1 (1.8)
Lymphatic leak	2 (4.2)	2 (3.6)
Seroma	1 (2.1)	1 (1.8)
Partial flap necrosis	0 (0)	1 (1.8)
Superior flap lymphedema	6 (12.7)	No data available
GAN lesion	5 (10.6)	No data available

Abbreviation: GAN, great auricular nerve.

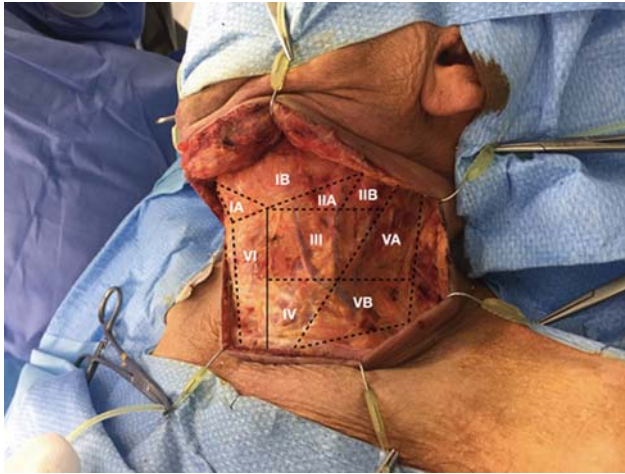
**Table 5** Quality of life of patients and subjective perception of the surgical wound

Variable	Transverse incision	J or U incision	p
Aesthetic perception of the patient (VAS 0–10)	7.25	6.20	0.002
Quality of life (VAS 0–10)	6.91	6.71	0.721
Surgeon’s assessment			
- Wound with correct healing	65.7%	60%	
- Wound with a flat adherent scar	20%	25%	
- Cutaneous retraction without functional affectation.	8.6%	7%	
- Cutaneous retraction with functional affectation	5.7%	8%	

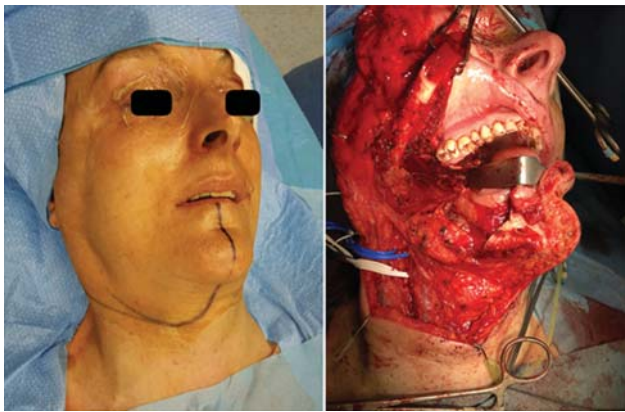Abbreviation: VAS, visual analogue scale.

cervical level in up to 3% of cases. A recent study published by Guillier et al compares the use of the Paul-André, or J incision, with the transverse incision, with the perception regarding the aesthetic result by the surgeon and patient satisfaction between both groups being the only statistically significant parameters, in both cases in favors of the transverse incision





**Fig. 2** Horizontal incision and exposure of all cervical levels. With preservation of the great auricular nerve.



**Fig. 3** Mandibular swing to approach a parapharyngeal space tumor.

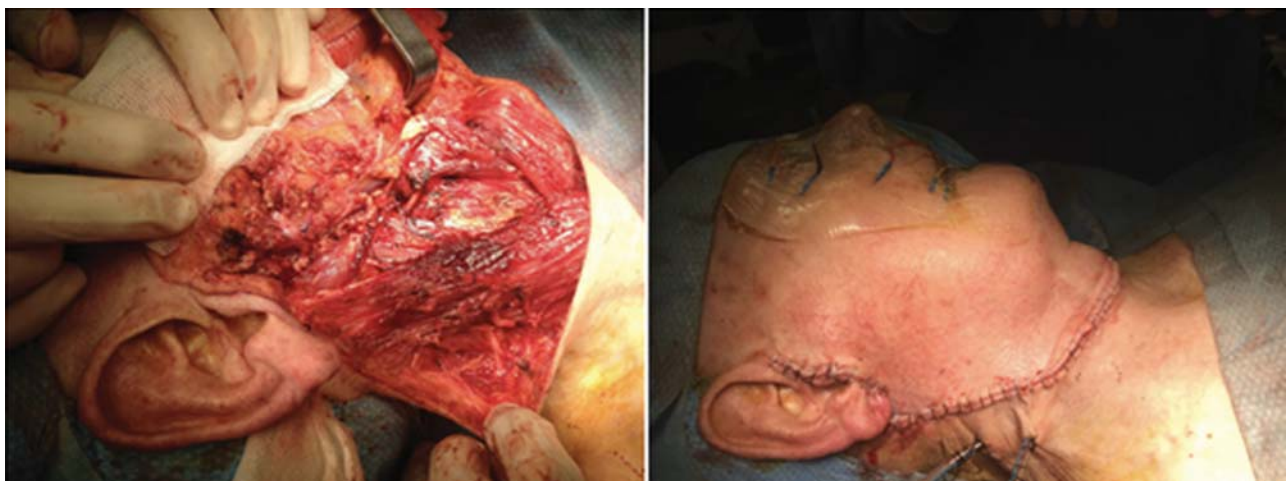
group.<sup>21</sup> In our study, we found significant results regarding aesthetic perception, but we could not find any difference according to the quality of life in patients. According to the surgeon's perception of the scar during the follow-up, correct healing was found in 65.7% of the patients in the study group and 60% of patients in the historical cohort.

Concerning the extended transverse incision, since its original description, one of the main drawbacks has been the lack of exposure. However, in **–Figs. 2, 3 and 4**, we can see how with this incision we can correctly expose the totality of the cervical areas and even when we need to combine the cervical incision with other approaches for the primary lesion. In our series, although we found more N2-N3 patients in the control group, no statistical difference was found between both groups ( $p = 0.365$ ); moreover, there was no need for the surgeon to limit lymph node resection due to inadequate field exposure in any of the cases. Additionally, the mean number of isolated lymph nodes per neck dissection, which was  $18 \pm 7$  (min: 11/ max: 39), is in relation to the oncological parameters previously described.<sup>22</sup> On the other hand, we must emphasize the importance of avoiding angles and their propensity to necrosis during flap elevation as well as a horizontal direction opposite to the large vessels,

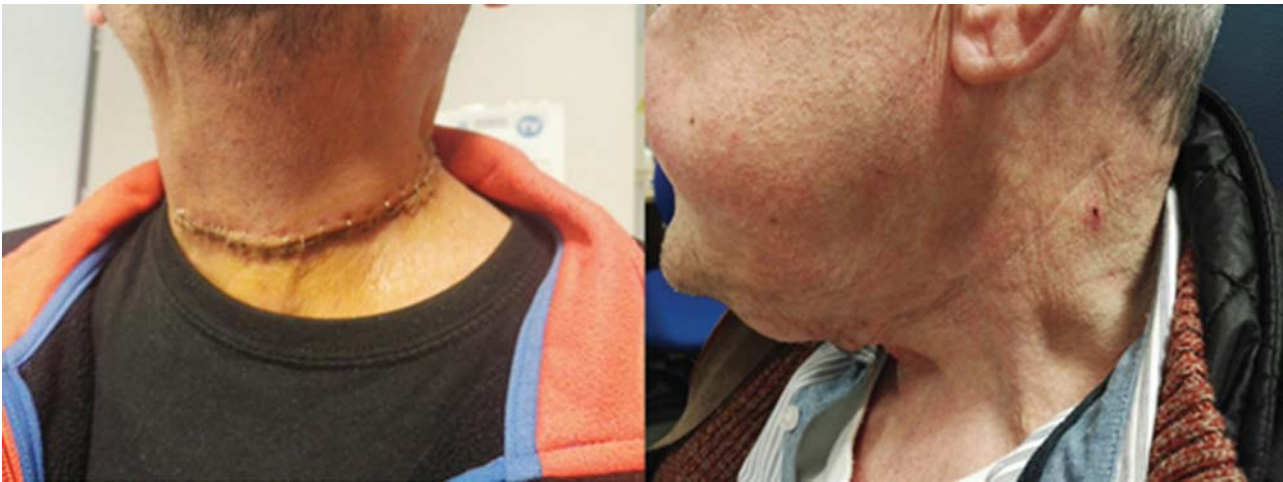In this way, this cervical incision guarantees a safe approach when the surgeon performs an oncological cervical procedure and, due that the direction of the incision is related to the natural lines of skin tension in the neck, the suture will have an adequate relaxation that will decrease the appearance of cicatricial retraction, guaranteeing an aesthetic benefit in patients subjected to a mutilating surgical procedure. (**–Figs. 5 and 6**)

According to the complications rates associated with healing in this group of patients, only 4 (8.5%) patients in the transverse incision group presented dehiscence of the operative wound, while 7 (12.2%) in the historical group showed a dehiscence of the wound without finding differences between both groups ( $p = 0.078$ ). The only factor related to the appearance of these complications in those patients was a body mass index lower than 18.5. Theoretically, the transverse incision could create scarring interfering with the lymphatic draining of the flap, especially compared with a J or hockey-stick incision, in our cohort 6 (12.7%) patients developed superior flap lymphedema related to this problem, all of them resolved during the follow-up.

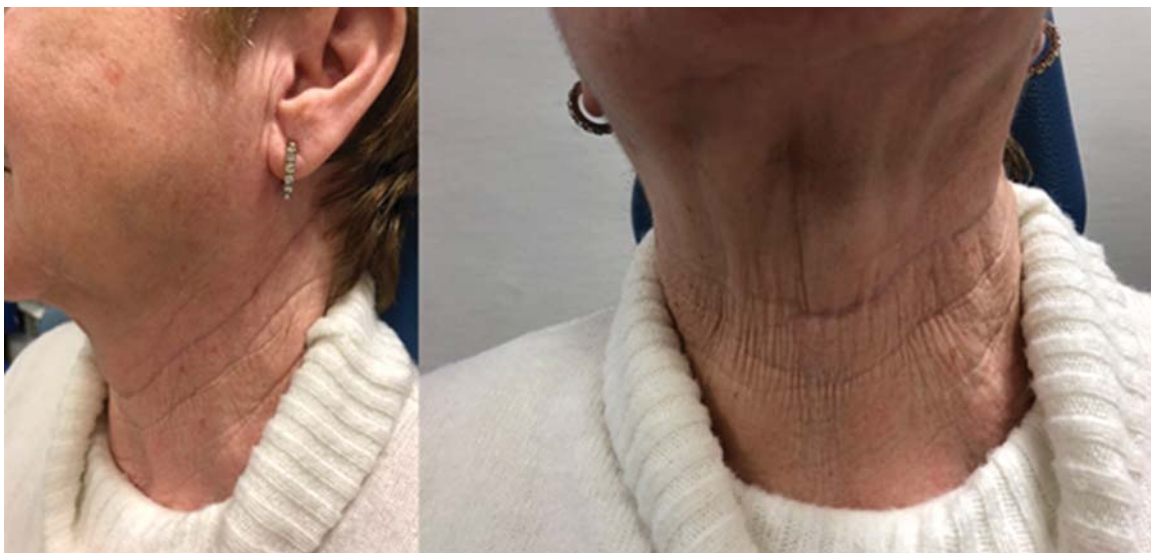Furthermore, during the elevation of the flap using a transverse incision, the great auricular nerve (GAN) can be at risk, affecting the sensation at the level of the ear lobule.



**Fig. 4** Left superficial parotidectomy + carnial neck dissection.



**Fig. 5** Patient on his 6th postoperative day of left radical neck dissection (left). Patient after 1 month postoperatively due to selective jugular neck dissection – levels II-IV (right).



**Fig. 6** Left supraomohyoid cervical neck dissection 6 months after surgery

Careful dissection is needed to avoid this kind of complication and even doing this, the risk still exists. In our cohort, 5 (10.6%) patients suffered alteration of sensibility at the level of the auricle after the transverse incision, secondary to an injury during the flap elevation. However, due to the retrospective nature of data obtained from the historical cohort, we cannot evaluate the rate of lymphedema or GAN damage to compare and extract any conclusion. None of the patients presented hypertrophy scarring or keloid onset during follow-up.

Another important consideration is the use of regional free flaps during head & neck surgery. In both cohorts, patients who precise the use of myomucosal pectoralis major flap for pharyngeal reinforcement after salvage total laryngectomy were included, in this patient, the bulky effect of the pedicle can be considered an aesthetic problem. However, no difference was found between the groups. Also, the use of fascio-cutaneous

flaps like the supraclavicular artery island flap or radial forearm free flap for tongue reconstruction or pharyngeal wall reconstruction after total laryngectomy as well as one patient who precise a fibula free flap after a segmental mandibulectomy were included in the final analysis without any significant difference when compared with other patients. However, all those patients who needed a skin flap reconstruction after an ablative procedure of the head and neck were excluded.

Finally, we must highlight the limitations of the present study, which include the retrospective nature of the study, the absence of albumin level in both groups, the lack of a specific test to assess the quality of life of patients, the rate of patients affected by shoulder pain after neck dissection, and the difference in the proportion of patients having radiation prior to the neck surgery; with radiation being less frequent in the transverse incision group (13%) when compared with the other incisions (25%).

## Conclusion

The transverse incision represents a safe, aesthetic and oncological adequate option, associated with a lower cicatricial retraction rate, a lower rate of complications and allowing adequate exposure of the surgical field similar in comparison with the classic J or U incision.

### Conflicts of Interest

The authors have no conflicts of interest to declare.

## References

- Crile GW. Excision of cancer of the head and neck. With special reference to the plan of dissection based on 132 operations. *JAMA* 1906;47:1780–1786
- Suarez O. El problema de las metástasis linfáticas y alejadas del cáncer de laringe e hipofaringe. *Rev Bras Otorrinolaringol* 1963; 23:83–99
- Gavilán J, Moñoux A, Herranz J, Gavilán C. Functional neck dissection: Surgical technique. *Oper Tech Otolaryngol–Head Neck Surg* 1993; 4:258–265
- Bocca E, Pignataro O, Sasaki CT. Functional neck dissection. A description of operative technique. *Arch Otolaryngol* 1980;106 (09):524–527
- Robbins KT, Clayman G, Levine PA, et al; American Head and Neck Society; American Academy of Otolaryngology–Head and Neck Surgery. Neck dissection classification update: revisions proposed by the American Head and Neck Society and the American Academy of Otolaryngology–Head and Neck Surgery. *Arch Otolaryngol Head Neck Surg* 2002;128(07):751–758
- Kocher Th. Extirpatio linguae. *Deutsche Zeitschrift für Chir.* 1880; 13:146
- Küttner H. Ueber die lymphgefäße und lymphdrüsen der Zunge mit beziehung auf die verbreitung des zungencarcinoms. *Beitrag für Klinischen Chir.* 1898;21:732
- Martin H, Del Valle B, Ehrlich H, Cahan WG. Neck dissection. *Cancer* 1951;4(03):441–499
- Macfee WF. Transverse incisions for neck dissection. *Ann Surg* 1960;151:279–284
- Folz BJ, Silver CE, Rinaldo A, Ferlito A. Themistocles Gluck: biographic remarks emphasising his contributions to laryngectomy. *Eur Arch Otorhinolaryngol* 2011;268(08):1175–1179
- Attie JN. A single transverse incision for radical neck dissection. *Surgery* 1957;41(03):498–502
- Becker GD. The extended single transverse neck incision for composite resections. *Surg Gynecol Obstet* 1979;148(01):90–92
- Kambic V, Sirca A. [Vascularization of the skin of the neck and its significance for the cutting method in radical neck dissection]. *HNO* 1967;15(02):46–49
- Rabson JA, Hurwitz DJ, Futrell JW. The cutaneous blood supply of the neck: relevance to incision planning and surgical reconstruction. *Br J Plast Surg* 1985;38(02):208–219
- On the anatomy and physiology of the skin. IV. The swelling capabilities of skin by Professor K. Langer presented at the meeting of 27th November 1861. *Br J Plast Surg* 1978;31(04):273–276
- Chagas JF, Pascoal MB, Aquino JL, et al. Single transverse extended incision for radical neck dissection. *Rev Col Bras Cir* 2016;43(04): 270–275
- Ellis M. Surgical techniques following irradiation of the neck. *J Laryngol Otol* 1963;77:872–908
- Stell PM. Transverse incisions for radical neck dissection. *Br J Surg* 1969;56(04):286–288
- Babcock WW Jr, Conley J. Neck incision in block dissection. Experiences with the long anterior cervical flap incision. *Arch Otolaryngol* 1966;84(05):554–557
- Acar A, Dursun G, Aydin O, Akbaş Y. J incision in neck dissections. *J Laryngol Otol* 1998;112(01):55–60
- Guillier D, Moris V, Al Hindi AA, et al. Surgical approaches in neck dissection: Comparing functional, oncologic and aesthetic aspects of transverse cervicotomy to Paul André's approach. *Ann Chir Plast Esthet* 2017; pii: S0294–1260(17)30122–X [ Epub ahead of print ]. Doi: 10.1016/j.anplas.2017.07.017
- Robinson TJ, Thomas S, Dinan MA, Roman S, Sosa JA, Hyslop T. How Many Lymph Nodes Are Enough? Assessing the Adequacy of Lymph Node Yield for Papillary Thyroid Cancer. *J Clin Oncol* 2016; 34(28):3434–3439