


Piezosurgery in Hallux Valgus Correction: Distal Linear Osteotomy Operative Technique Using Piezoelectric Tools

Alessandro Russo¹  Silvio Caravelli² Massimiliano Mosca² Mauro Girolami³ Alessandro Ortolani⁴
 Simone Massimi² Mario Fuiano² Stefano Zaffagnini²

¹Laboratory of Nano Biotechnology (NaBi), IRCCS Istituto Ortopedico Rizzoli, Bologna, Italy

²II Clinic of Orthopaedics and Traumatology, IRCCS Istituto Ortopedico Rizzoli, Bologna, Italy

³Department of Orthopaedics and Traumatology, Ospedale Bentivoglio, Bentivoglio, Italy

⁴Department of Orthopaedics and Traumatology, Ospedale Maggiore "Pizzardi," Bologna, Italy

Address for correspondence Alessandro Russo, MD, PhD, Laboratory of Nano Biotechnology (NaBi), IRCCS Istituto Ortopedico Rizzoli, Bologna, Italy (e-mail: a.russo@biomec.iior.it).

Joints 2019;7:25–30.

Abstract

Purpose Piezoelectric and ultrasonic vibrations have been used to cut tissues for three decades, in particular, in periodontics. The increasing use of piezosurgery is based on its clinical advantages such as selective cutting, precision, and low-temperature work rates. The authors applied this concept to a new operative field, the foot and ankle pathology and surgery, such as hallux valgus corrective distal linear osteotomy.

Methods The osteotome equipped was the Surgysonic Moto-II model (Esacrom, Imola, Italy), a system recently developed for cutting bone with microvibrations. Tips used in author's case series were a high-efficiency five teeth piezoelectric saw and a high-efficiency flat scalpel shaped on three edges. Operative technique is described.

Discussion and Conclusion Piezoelectric techniques were developed in response to the need for great precision and safety in bone surgery that was available with other manual and motorised instruments. Piezo-technology allows minimally-invasive and percutaneous surgery, with reduced trauma on periosteum, bone, and soft tissues, reduced healing time of the osteotomy due to the absence of bony necrosis and debris formation and major precision.

Keywords

- ▶ hallux valgus
- ▶ piezoelectric
- ▶ forefoot
- ▶ distal linear osteotomy
- ▶ mini-invasive

Introduction

The term of "hallux valgus" has been introduced by Carl Hueter¹ in 1870 to 1871 to define a static subluxation of the first metatarsophalangeal (MTP) joint and it is clinically correlated with pain, generally due to bursitis and shoes conflict and functional limitation. Prevalence estimated for hallux valgus is 23% in adult population between 18 and 65 years old and 35.7% in elderly people² and represents a deformity characterized by lateral displacement of the great toe and medial displacement of the first metatarsophalangeal joint, associated to lateral displacement of sesamoidal bones.³

The surgical correction of deformities of the first ray of the foot presents more than 130 different well-codified operative techniques.⁴ In this article, authors describe the well-codified distal linear osteotomy of the first metatarsal by Giannini et al³ using piezoelectric tools.

Piezoelectric and ultrasonic vibrations have been used to cut tissues for three decades. It is only in the last years that applications have been used for standard clinical performances. In particular, ultrasounds have been widely used in periodontics with good results for decontamination of root surfaces, mainly because of its efficiency for calculus removal,⁵ dental extraction techniques, maxillofacial bone surgery, and bone block collection for autogenous grafting.^{6,7}

received
 October 9, 2017
 accepted after revision
 November 4, 2019
 published online
 December 13, 2019

DOI <https://doi.org/10.1055/s-0039-3401821>.
 ISSN 2282-4324.

Copyright © 2019 Georg Thieme Verlag
 KG Stuttgart · New York

License terms



The increasing use of piezosurgery is based on its clinical advantages, such as selective cutting (avoiding soft tissues damage), precision (due to the micrometric amplitude of the oscillation), and low-temperature work rates.

Instruments for piezoelectric cutting of bone, developed by Vercellotti in 1988, create microvibrations caused by the piezoelectric effect, first described by Jean and Marie Curie in 1880.⁸ The passage of an electric current across certain ceramics and crystals deform their structures, determining expansion and constriction perpendicular to the polarity of the material.

A frequency of 25 to 29 kHz is usually used because the micromovements created at this frequency (ranging between 60 and 210 μm) cut selectively mineralized tissues. Neurovascular structures and other soft tissues are cut at higher frequencies (more than 50 kHz).⁹

The aim of this study is to describe application of the piezosurgery to the orthopaedic procedures, in particular, the hallux valgus surgical correction using a traditional distal linear osteotomy of the first metatarsal and piezosurgical tools, analyzing and discussing advantages and limits of the technique.

Methods

Instrumentation

The osteotome equipped was the Surgysonic Moto-II model, (Esacrom, Imola, Italy), a system recently developed for cutting bone with microvibrations. The equipment consisted of a piezoelectric handpiece and a foot switch that are connected to a main unit (**►Figs. 1 and 2**), which supplied

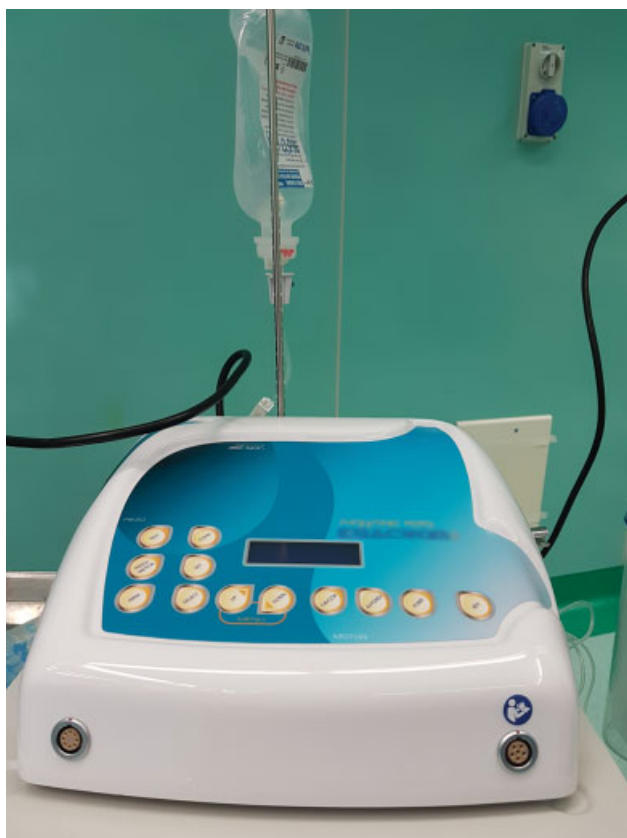

Fig. 1 Main unit, supplying power, and irrigation fluids.

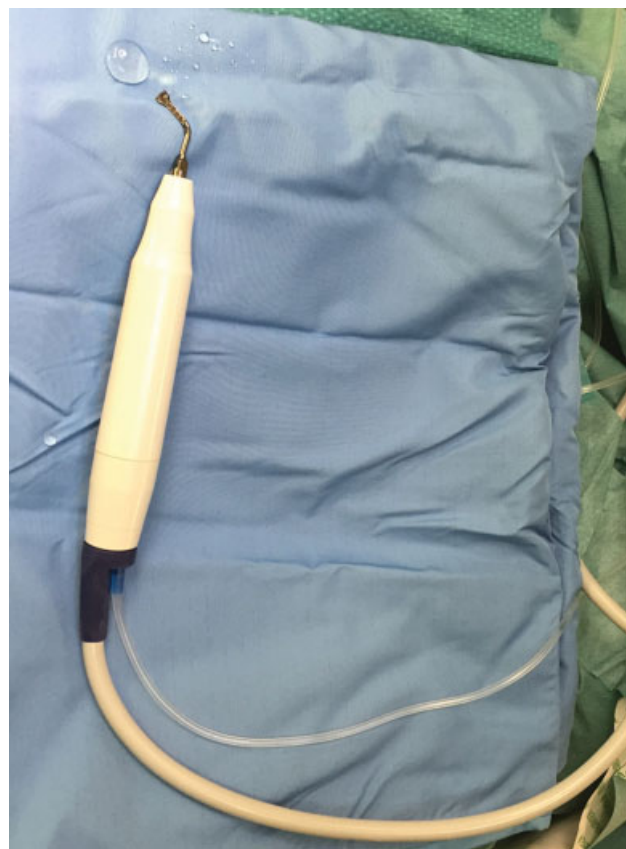

Fig. 2 Sterile piezoelectric handpiece connected to the main unit.

power with sterilizable holders for the handpiece and irrigation fluids. It contained a peristaltic pump for cooling with a jet of saline solution that discharges from the insert with an adjustable flow of 0 to 60 mL/min and removes detritus from the cutting area. This allowed a precise cut and a good visual control of the surgical field. The setting of power and frequency modulation of the device can be selected on a control panel with a digital display. For the handpiece several autoclavable tooltips, called “inserts,” are available (**►Fig. 3**).

Tips used in authors' case series were a high-efficiency five teeth piezoelectric saw (thickness, 0.27 mm; operative length, 20.3 mm) and a high-efficiency flat scalpel shaped on three edges (thickness, 0.27 mm; operative length, 16.3 mm); all tools used had a double nanostructural finishing surface, that could be used to a maximum power of 50 W. These tips are microshaped instead of diamond coated, allowing more resistance and less abrasion.

Distal linear osteotomy used by authors in this article, as described by Giannini et al³ in 2013, had been indicated to correct deformities characterized by a mild severity, with an intermetatarsal (IMT) angle included between 15 degrees and 25 degrees.

Postoperative care is characterized by a functional bandage dressing, aiding the Kirschner wire (K wire) fixation of the osteotomy for 35 days. Patients were allowed to walk with complete weightbearing on the day after the surgical operation with the use of a dedicated footwear with a flat, rigid sole.

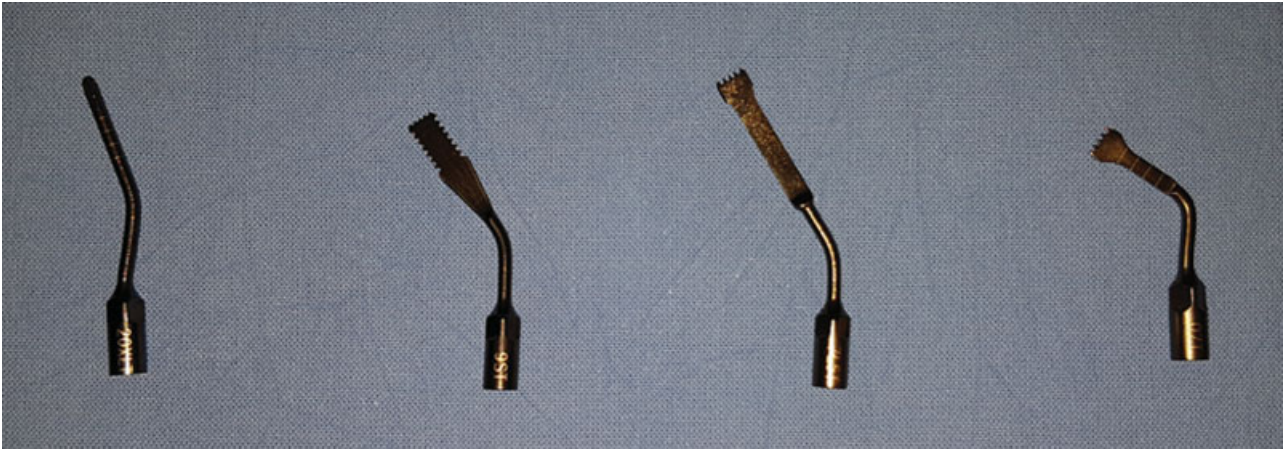


Fig. 3 Autoclavable tooltips, called “inserts.” Tips used in author’s case series were a high efficiency five teeth piezoelectric saw (thickness, 0.27 mm; operative length, 20.3 mm [third one from left]) and a high efficiency flat scalpel shaped on three edges (thickness, 0.27 mm; operative length, 16.3 mm [second one from left]).

Operative Technique

The patients were counselled regarding the surgical procedure and the risk involved, informed consent were obtained.

Under spinal anesthesia, the patient was placed in supine position, with feet at approximately 3 cm from the end of the operating table and a thigh tourniquet was applied and inflated for lower limb exsanguination, following the AORN guidelines (tourniquet inflated intraoperatively to a pressure higher than the limb occlusion pressure).¹⁰

Stretching of the adductor hallucis tendon at its insertion and lateral capsule release were performed after mini-open approach weakening, using a size-15 scalpel.

Medial approach through less than 1 cm skin incision was performed, performed at the level of the neck of the first metatarsal (→**Fig. 4**). The periosteum around the site of the osteotomy was detached first, from 3 to 5 mm just to allow the insertion of piezosteotome. Before proceeding to osteotomy, the site and the direction of the cut could be controlled by intraoperative X-ray. In selected cases, such as first metatarsophalangeal joints free from early-to-moderate osteoarthritic processes, it has been possible to work through a mini-invasive approach without associated articular procedures.

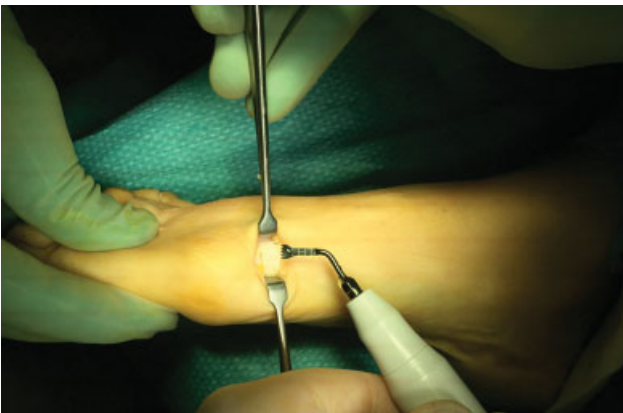

Fig. 4 Medial approach through less than 1-cm skin incision performed at the level of the neck of the 1st metatarsal bone.

The osteotomy was performed through the subcapital region of the first metatarsal using a proper tip. Contrary to the osteotomies with oscillating saw, that needs pushing movement, piezoelectric saw works with gentle sliding movements. The cutting efficiency is linked to the pressure on bone. With a piezoelectric unit, cutting is due to the high frequency vibrations of the tip. Excessive pressure prevents vibration, decreases efficiency, and generates frictional heat. A moderate force (1.5–2 N) is used to allow the tip to vibrate (as comparison, the axial force during handwriting closely corresponds to 1 N).¹¹ A working pressure of 1.5 N has been shown to fulfill the requirements for harmless intraosseous temperature. Beyond 3 N, cutting efficiency was not improved and thermal damage was increased.¹²

The cut was made at approximately 15 degrees of inclination in sagittal plane, under visual control, perpendicular to the axis of the second metatarsal bone (→**Fig. 5**). The mediolateral inclination of the osteotomy in transverse

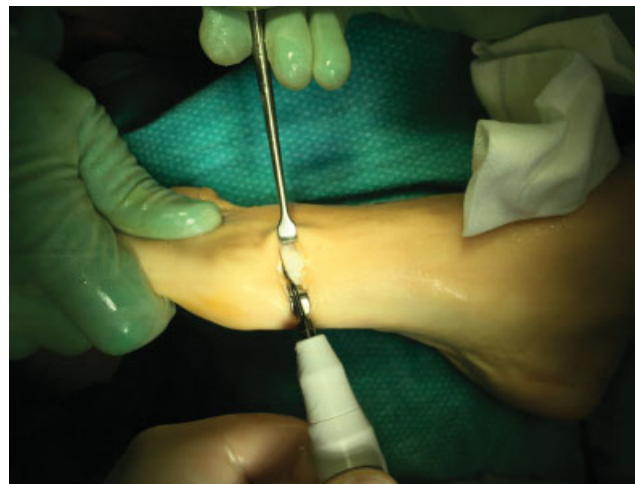

Fig. 5 Cut was made at approximately 15 degrees of inclination in sagittal plane, under visual control, perpendicular to the axis of the second metatarsal bone.

plane makes it possible to lengthen or shorten the metatarsal with lateral displacement of the distal fragment. So, in this way, if decompression of the first metatarsophalangeal joint is required, such as in case of slight stiffness, the osteotomy can be inclined up to 20 degrees. Furthermore, the metatarsal head can be rotated in the axial plane to correct the rotational component of the pathoanatomy of the deformity.

A 2-mm K wire was positioned to stabilize the osteotomy, inserted in the distal direction through the skin incision in a parosteal position along the longitudinal axis of the toe to its tip, 2 or 3 mm from the medial corner of the nail. The wire was withdrawn from the tip of the toe until its proximal end reached the osteotomy site. At this point, the displacement was best achieved using a small grooved lever. With the lever, authors accessed the osteotomy and the K wire was pushed in a retrograde way through the osteotomy into the medullary channel. It was firmly driven as far as the base of the metatarsal bone to improve stability.

If the proximal edge of the osteotomy was prominent, a small resection of bone was performed.

The head can be manipulated in transverse plane or rotated to modify the distal metatarsal articular angle. The plantar or dorsal adjustments of the metatarsal head can be obtained by positioning the K-wire dorsal or plantar in the soft tissues, close to the bone.

Tourniquet was deflated and tourniquet time was recorded. Emostasis was not necessary in any treated case. The skin was closed, being careful of tension, with interrupted absorbable no. 3–0 suture.

Postoperative Care

The postoperative care involves an imbricated bandage, the use of a forefoot off-loading shoe footwear, and progressive-to-full weight bearing for 1 month. The rehabilitative protocol starts at the removal of K wires at 1 month of follow-up and provides active and passive mobilization exercises of the first MTP to recovery articularity and function.

Discussion

Piezoelectric techniques were developed in response to the need for great precision and safety in bone surgery than was available with other manual and motorized instruments. In orthopaedic surgery, piezoelectric devices allow precise cuts during osteotomies. Budd et al reported that bone could be cut precisely at an angle, but the system was less efficient for deep cuts.¹³ As the cutting speed decreased the temperature rose, so it was necessary to pause to allow the system to cool down. In devices used by authors, the peristaltic pump with a jet of saline solution for cooling can be taken in consideration to resolve this problem. Cavitation effect associated with ultrasonic instrumentations, responsible of expansion and contraction of microbubbles of gas dissolved in fluids that violently collapse creating a shock wave.¹⁴ This effect lead to reduction of bony debris at the site of osteotomy that is generally correlated to longer time

of fracture healing. Piezoelectric surgery presents better results regarding to bone healing and radiographic healing time. Piezosurgery is able to allow a favorable bone response, linked to the lack of coagulative necrosis due to heat generation of traditional osteotomy methods and to higher rate of viable bone cells in site. This can lead to a faster formation of bone callus.

Another important point of discussion is represented by bone saving in the osteotomy sites.

Shahid et al¹⁵ demonstrated that the mean bone loss during a linear osteotomy on rigid polyurethane foam blocks (sawbones) was 0.23 g using a 31 mm × 9 mm × 0.51 mm oscillating saw blade and 0.85 g using a 3 mm × 20 mm burr, corresponding to 0.67 and 3.21 mm of cut thickness, respectively. In authors' case series, piezoelectric osteotome had 0.27 mm of thickness, corresponding to real bone loss of 0.3 mm. Anyway different studies in literature,^{16,17} demonstrate that larger bone loss and larger thickness of the cut may lead to shortening of the metatarsal and this, in turn, may result in abnormal transfer lesion to lesser metatarsals due to the change of the biomechanics of the forefoot and the function of the first ray, requiring further surgery.

Furthermore, piezoelectric surgery is safe, especially in tiny small surgery fields. It has been shown that a piezoelectric tool directly applied for 5 seconds on a peripheral nerve with a relatively high working force (1.5 N) did not dissect the nerve but induced some structural and functional damage.¹⁸ Moreover, blood loss during procedures is reduced by 25 to 30%, due to a better visibility and to the sparing effect on soft tissues. .

Precision of the cut is enhanced by the micrometric vibrations of the tips, continuous washing of the osteotomy site, reduced bleeding, and powerful high luminosity LEDs which improves visibility at the surgical site even in deep locations.

Limitations

Limitations of the piezoelectric instrumentation are the speed of osteotomy and the costs. Piezobone surgery is usually considered to be slower than traditional burr and oscillating saw, especially when surgeon is learning this new field of application. In literature, Spinelli et al showed that the whole operative procedure took 35% longer with a piezoelectric tool compared with an oscillating saw.¹⁹ A clinical trial is currently ongoing and preliminary results are comparable to the literature: correction of hallux valgus with SERI (simple, effective, rapid, and inexpensive),³ and oscillating saw took approximately 3 minutes, with piezoelectric saw approximately 10 minutes.

Conclusion

In conclusion, piezotechnology allows minimally-invasive and percutaneous surgery, with reduced trauma on periosteum, bone, and soft tissues, reduced healing time of the osteotomy due to the absence of bony necrosis and debris formation and major precision.

Further development on the piezoelectric percutaneous technologies may include computer-assisted tools and three-dimensional printed mechanical jigs.

Conflict of Interest

None declared.

References

- 1 Hueter C. Klinik der Gelenkkrankheiten mit Einschluss der Orthopädie: Auf Anatomisch-Physiologischen Grundlagen Nach Klinischen Beobachtungen Für Ärzte und Studierende Bearbeitet. Leipzig: Verlag von FOW Vogel;1870
- 2 Nix S, Smith M, Vicenzino B. Prevalence of hallux valgus in the general population: a systematic review and meta-analysis. *J Foot Ankle Res* 2010;3:21
- 3 Giannini S, Faldini C, Nanni M, Di Martino A, Luciani D, Vannini F. A minimally invasive technique for surgical treatment of hallux valgus: simple, effective, rapid, inexpensive (SERI). *Int Orthop* 2013;37(09):1805–1813
- 4 Maffulli N, Longo UG, Marinozzi A, Denaro V. Hallux valgus: effectiveness and safety of minimally invasive surgery. A systematic review. *Br Med Bull* 2011;97:149–167
- 5 Sohn DS, Lee JS, An KM, Choi BJ. Piezoelectric internal sinus elevation (PISE) technique: a new method for internal sinus elevation. *Implant Dent* 2009;18(06):458–463
- 6 Vercellotti T. Piezoelectric surgery in implantology: a case report—a new piezoelectric ridge expansion technique. *Int J Periodontics Restorative Dent* 2000;20(04):358–365
- 7 Danza M, Guidi R, Carinci F. Comparison between implants inserted into piezo split and unsplit alveolar crests. *J Oral Maxillofac Surg* 2009;67(11):2460–2465
- 8 Newman PG, Rozycki GS. The history of ultrasound. *Surg Clin North Am* 1998;78(02):179–195
- 9 Labanca M, Azzola F, Vinci R, Rodella LF. Piezoelectric surgery: twenty years of use. *Br J Oral Maxillofac Surg* 2008;46(04):265–269
- 10 AORN Recommended Practices Committee. Recommended practices for the use of the pneumatic tourniquet in the perioperative practice setting. *AORN J* 2007;86(04):640–655
- 11 Hennes P. Piezoelectric bone surgery: a review of the literature and potential applications in veterinary oromaxillofacial surgery. *Front Vet Sci* 2015;2:8
- 12 Birkenfeld F, Becker ME, Harder S, Lucius R, Kern M. Increased intraosseous temperature caused by ultrasonic devices during bone surgery and the influences of working pressure and cooling irrigation. *Int J Oral Maxillofac Implants* 2012;27(06):1382–1388
- 13 Budd JC, Gekelman D, White JM. Temperature rise of the post and on the root surface during ultrasonic post removal. *Int Endod J* 2005;38(10):705–711
- 14 Landes CA, Stübinger S, Rieger J, Williger B, Ha TK, Sader R. Critical evaluation of piezoelectric osteotomy in orthognathic surgery: operative technique, blood loss, time requirement, nerve and vessel integrity. *J Oral Maxillofac Surg* 2008;66(04):657–674
- 15 Shahid MS, Lee P, Evans S, Thomas R. A comparative study of bone shortening and bone loss with use of saw blades versus burr in hallux valgus surgery. *Foot Ankle Surg* 2012;18(03):195–197
- 16 Tóth K, Huszanyik I, Kellermann P, Boda K, Róde L. The effect of first ray shortening in the development of metatarsalgia in the second through fourth rays after metatarsal osteotomy. *Foot Ankle Int* 2007;28(01):61–63
- 17 Stephens MM. Does shortening of the first ray in the treatment of adolescent hallux valgus prejudice the outcome? *J Bone Joint Surg Br* 2006;88(07):858–859
- 18 Schaeren S, Jaquiéry C, Heberer M, Tolnay M, Vercellotti T, Martin I. Assessment of nerve damage using a novel ultrasonic device for bone cutting. *J Oral Maxillofac Surg* 2008;66(03):593–596
- 19 Spinelli G, Lazzeri D, Conti M, Agostini T, Mannelli G. Comparison of piezosurgery and traditional saw in bimaxillary orthognathic surgery. *J Craniomaxillofac Surg* 2014;42(07):1211–1220