


# Pelvic Bone Deformity and Its Correlation with Acetabular Center-edge Angle\*

## *Deformidade dos ossos pélvicos e sua correlação com o ângulo centro-borda acetabular*

Bruno Dutra Roos<sup>1</sup>  Milton Valdomiro Roos<sup>1</sup> Antero Camisa Júnior<sup>1</sup>  
Ezequiel Moreno Ungaretti Lima<sup>1</sup> Darby Lira Tisatto<sup>1</sup> Marcel Cruz Argoud<sup>1</sup>

<sup>1</sup> Hip Group of the Orthopedic Hospital of Passo Fundo, Faculty of Medicine, University of Passo Fundo, Passo Fundo, RS, Brazil.

Address for correspondence Bruno Dutra Roos, MD, Grupo de Quadril do Hospital Ortopédico de Passo Fundo, Faculdade de Medicina da Universidade de Passo Fundo, Av. Sete de Setembro, 817, Centro, Passo Fundo, RS 99010-121, Brasil (e-mail: brunodroos@gmail.com).

Rev Bras Ortop 2020;55(2):239–246.

### Abstract

**Objective** The purpose of the present study was to evaluate the pelvic bone deformities and its correlation with the acetabular center-edge (CE) angle.

**Methods** Between August 2014 and April 2015, we prospectively evaluated patients aged between 20 and 60 years old. The exclusion criteria were: metabolic disease, previous hip or spine surgery, radiograph showing hip arthrosis  $\geq$  Tönnis two, severe hip dysplasia, global acetabular overcoverage, acetabular crossover sign, hip deformities from slipped capital femoral epiphysis (SCFE) or Leg-Perthes-Calvéé, and bad quality radiographs. At anteroposterior (AP) pelvic radiographs, we have evaluated: the CE angle, the acetabular index (IA), the acetabular crossover sign, the vertical and horizontal superior and inferior pelvic axis (H1: Horizontal line 1, superior pelvic axis; H2: Horizontal line 2, superior pelvic axis; V1: Vertical line, superior pelvic axis; HR: Horizontal line, inferior pelvic axis; VR: Vertical line, inferior pelvic axis). The superior and inferior pelvic axis were considered asymmetric when there was a difference  $\geq$  5 mm between both sides. Patients were divided into two groups: control and group 1.

**Results** A total of 228 patients (456 hips) were evaluated in the period. According to the established criteria, 93 patients were included. The mean age was 39.9 years old (20 to 60 years old, standard deviation [SD] = 10,5), and the mean CE angle in the right hip was 31.5° (20° to 40°), and in the left 32.3° (20° to 40°). The control group had 38 patients, with asymmetric H1 in 4 cases (10.5%), H2 in 5 (13.1%), V1 in 7 (18.4%), HR in 5 (13.1%) and VR in 1 (2.63%). Group 1 had 55 patients, with asymmetric H1 in 24 cases (43.6%), H2 in 50 (90.9%), V1 in 28 (50.9%), HR in 16 (29.09%) and VR in 8 (14.5%). Comparing both groups, there was statistical significance for H1, H2 and V1 asymmetry ( $p < 0.001$ ).

**Conclusion** In the present paper, we observed the correlation between variation in the acetabular CE angle and asymmetry of the superior hemipelvis. The present authors

### Keywords

- ▶ hip dislocation
- ▶ acetabulum
- ▶ femur head

\* Study conducted at the Hip Group of the Hospital Ortopédico de Passo Fundo, Faculdade de Medicina da Universidade de Passo Fundo, Passo Fundo, RS, Brazil.

believe that a better understanding of the pelvic morphologic alterations allows a greater facility in the diagnosis of hip articular deformities.

## Resumo

**Objetivos** O objetivo do presente trabalho é avaliar a deformidade dos ossos pélvicos e sua correlação com ângulo centro-borda acetabular (CE).

**Métodos** Foi realizado um estudo prospectivo caso-controle, entre agosto de 2014 e abril de 2015. Os critérios de inclusão foram pacientes consecutivos com idades entre 20 e 60 anos. Os critérios de exclusão foram: doença metabólica, cirurgia prévia de quadril ou coluna, radiografia evidenciando artrose de quadril  $\geq$  Tönnis 2, displasia do desenvolvimento do quadril (DDQ) severa, sobrecobertura acetabular global, sinal do cruzamento das linhas acetabulares, deformidades decorrentes de epifisiólise ou Legg-Perthes-Calvéé, e radiografia sem qualidade adequada. Foram avaliados na radiografia anteroposterior (AP) de pelve: o ângulo CE, índice acetabular (IA), sinal do cruzamento das linhas acetabulares, mensuração do eixo horizontal e vertical da hemipelve superior e inferior (H1, H2 e V1, HR e VR). As mensurações H1, H2, V1, HR e VR foram consideradas assimétricas quando, na comparação de uma hemipelve em relação ao lado contralateral, evidenciou-se uma diferença  $> 5$  mm. Os pacientes foram separados em dois grupos: controle e grupo 1.

**Resultados** O total de pacientes avaliados no período foi de 228 (456 quadris). De acordo com os critérios estabelecidos, foram incluídos neste estudo 93 pacientes. A idade média foi de 39,9 anos (20 a 60 anos, desvio padrão [DP] = 10,5), e o ângulo CE médio do quadril direito foi de 31,5° (20° a 40°) e do esquerdo de 32,3° (20° a 40°). Um total de 38 pacientes foi incluído no grupo controle, sendo que com relação à H1, foi constatada aferição assimétrica em 4 casos (10,5%), H2 em 5 (13,1%), V1 em 7 (18,4%), HR em 5 (13,1%), e VR em 1 caso (2,63%). No grupo 1, foram incluídos 55 pacientes, sendo que com relação à H1, foi constatada aferição assimétrica em 24 casos (43,6%), H2 em 50 (90,9%), V1 em 28 (50,9%), HR em 16 (29,09%), e VR em 8 casos (14,5%). Na comparação entre o grupo controle e o grupo 1, observou-se diferença estatisticamente significativa para a assimetria das mensurações H1, H2 e V1 ( $p < 0,001$ ).

**Conclusão** No presente trabalho, evidenciou-se correlação entre variação do ângulo CE acetabular e assimetria da hemipelve superior. Os presentes autores acreditam que o melhor entendimento das alterações morfológicas pélvicas permite uma maior facilidade no diagnóstico das deformidades articulares do quadril.

## Palavras-chave

- ▶ luxação do quadril
- ▶ acetábulo
- ▶ cabeça do fêmur

## Introduction

There is growing evidence in the literature of the association of changes in the morphology of the hip bone and the development of symptoms, as well as the possibility of evolution to chondral joint degeneration. These changes may be related to the femur, the acetabulum, or both.<sup>1</sup> On the acetabular side, frequent morphological alterations include overcoverage (Pincer femoroacetabular impingement [FAI]) and coverage deficiency (developmental dysplasia of the hip [DDH]).<sup>2,3</sup>

Acetabular overcoverage can be global or focal. Global overcoverage is defined by anteroposterior (AP) pelvis radiography of the center-edge angle (CE)<sup>4</sup>  $> 40^\circ$  associated with excess femoral head coverage by the anterior and posterior wall of the acetabulum.<sup>5</sup> Focal overcoverage is defined by the presence of acetabular retroversion, which is a morphological

change in which there is structural deviation of the acetabulum in the sagittal plane towards the posterolateral direction. Radiographically, acetabular retroversion is represented by the presence of the sign of the intersection of the acetabular lines.<sup>3,6,7</sup> Both changes have been associated with the dynamic impact between the acetabular edge and the femoral head-neck transition, which may result in acetabular lesions of the posteroinferior cartilage and lip, as well as pain.<sup>8</sup>

In acetabular coverage deficiency, a reduced contact area between the femoral head and the acetabulum generates excessive shear force at the acetabular chondrolabral junction, which may lead to the emergence of symptoms and chondral degeneration in the long run. This deficiency is most commonly anterosuperior in the acetabulum, and the diagnosis of DDH is made when the CE angle<sup>4</sup> is  $< 25^\circ$  on pelvic AP radiography.<sup>4,9</sup>

Some authors have proposed that hip development disorders not only affect the proximal femur and the acetabulum, as

evidenced by pathologies such as FAI and DDH, but throughout the pelvis.<sup>1,10</sup> However, there is no consensus on which pelvic bone deformities correlate with acetabular morphological changes. We believe that pelvic bone structural changes and acetabular abnormalities are not isolated findings but are instead part of a continuum of structural changes in pelvic development.

The aim of the present study is to evaluate the pelvic bone deformity and its correlation with the CE angle.

## Materials and Methods

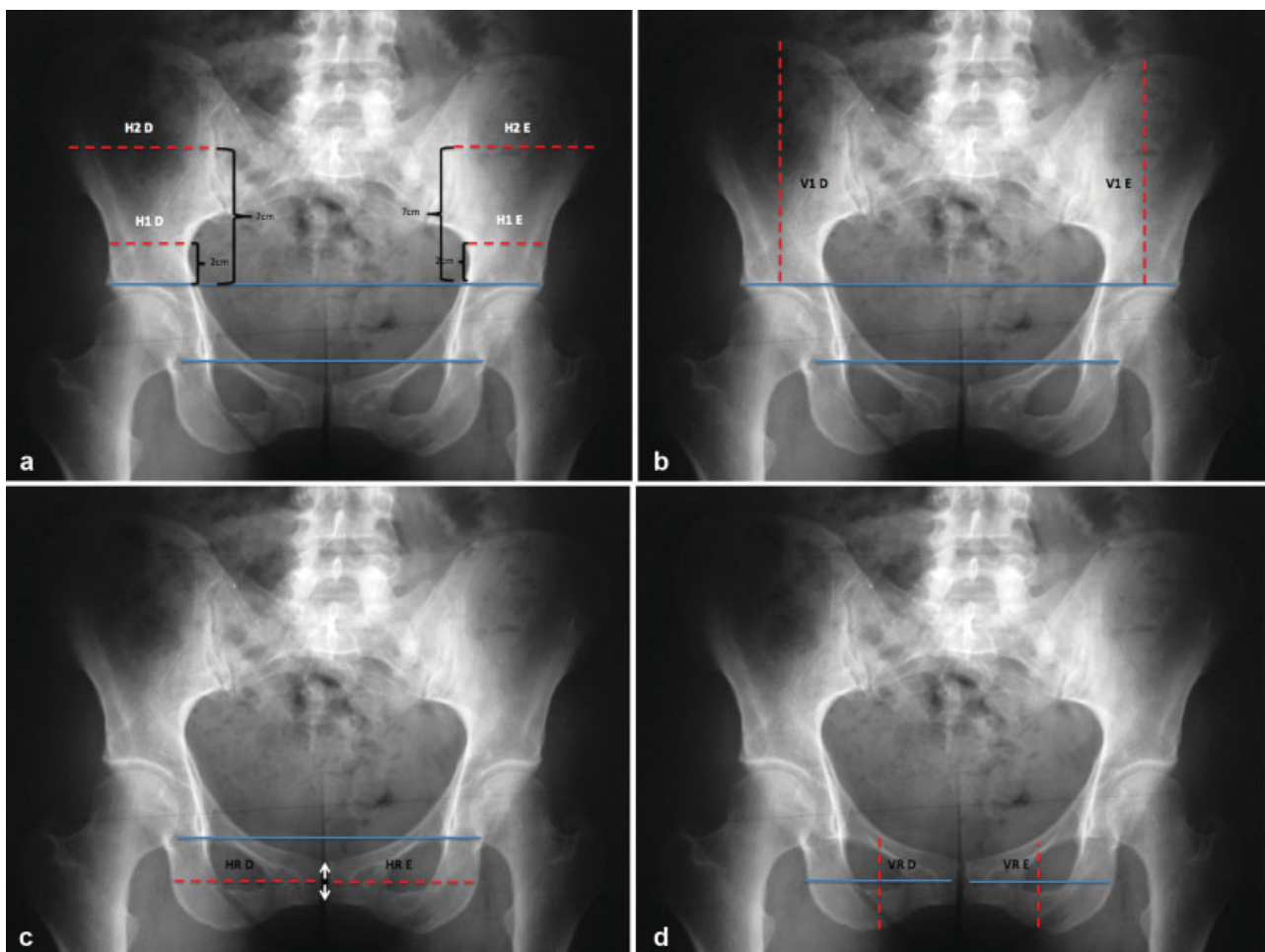
A prospective case-control study was conducted between August 2014 and April 2015. The study was approved by the Research Ethics Committee, and all of the participants signed the informed consent form.

Participants were invited to the study voluntarily. Inclusion criteria were consecutive patients aged 20 to 60 years old. The exclusion criteria were: metabolic disease, previous hip or spine surgery, radiograph showing hip arthrosis  $\geq$  Tönnis two, severe DDH (CE angle  $< 20^\circ$ ),<sup>4,9</sup> global acetabular overcoverage

(CE angle  $> 40^\circ$  and/or acetabular index [AI]  $< \text{zero}^\circ$ ),<sup>5</sup> sign of acetabular lines intersection (suggesting acetabular retroversion), CE angle asymmetry  $< 5^\circ$ , hip deformities from slipped capital femoral epiphysis (SCFE) or Leg-Perthes-Calvée, and bad quality radiographs.<sup>11</sup>

The selected patients underwent pelvic radiography at AP incidence with their feet at  $15^\circ$  of internal rotation, with the tube 120 cm away from the film, and with the radius directed to the center point between the upper edge of the pubic symphysis and a horizontal line connecting both anterosuperior iliac spines. The distance between the coccyx and the pubic symphysis, besides its alignment, were factors considered to evaluate the quality of the radiographs.<sup>11</sup>

The following radiographic studies were evaluated in both hemipelvis: CE angle, AI, sign of intersection of acetabular lines, measurement of horizontal and vertical axis of upper hemipelvis (iliac wings - H1, H2 and V1), measurement of the horizontal and vertical axis of the lower hemipelvis (ischium and ilium pubic branches - HR and VR). The definition of the method for measuring the pelvic axes is exemplified in **Figure 1**.



**Fig. 1** Exemplification of bilateral pelvic axis measurement method. All lines (H1, H2, V1, HR and VR) are referenced to the line between the teardrops. a) H1 and H2 correspond to the measurement of the horizontal axis of the upper hemipelvis. Initially, a line is defined connecting the upper points of the acetabular roofs (supra-acetabular line). H1 is 2cm above it; H2 is 7cm above it. b) V1 corresponds to the measurement of the vertical axis of the upper hemipelvis. It is the measurement from the highest point of the iliac bone to the supra-acetabular line. c) HR corresponds to the measurement of the horizontal axis of the lower hemipelvis, having as reference a midpoint of the pubic symphysis joint. d) VR corresponds to the measurement of the vertical axis of the lower hemipelvis, having as reference a midpoint of the measurement of the HR.

The measurements of the axis of hemipelvis (H1, H2, V1, HR and VR) were considered asymmetrical when, in comparing a hemipelvis in relation to its contralateral side, a difference  $> 5$  mm was found.

The selected patients were separated into two groups: control and group 1.

The control group included patients whose hips had a CE angle with a difference of  $< 5^\circ$ , with no sign of acetabular line intersection. Group 1 included patients with CE angle asymmetry  $\geq 5^\circ$ , comparing one hip to the contralateral side, with no sign of acetabular line intersection.

The aim of the present study is to evaluate the correlation between CE angle variation and pelvic bone deformity (H1, H2, V1, HR and/or VR asymmetry), comparing both groups.

The hypothesis is that the presence of CE angle variation correlates with the upper hemipelvis asymmetry (suggesting rotational change of the upper hemipelvis).

To assess homogeneity between the groups, the chi-squared test was applied for age, gender, CE angle and AI. The Fisher exact test was used to analyze the intergroup qualitative variables (H1, H2, V1, HR and VR). In the present study, differences were considered statistically significant when  $p < 0.05$ . The software PASW Statistics for Windows, Version 18.0 (SPSS Inc. Chicago, IL, USA) was used in the statistical analysis. A total of 50 radiographs were randomly selected to measure the  $\kappa$  coefficient. Two authors, Roos B. D. and Lima E. M. U., evaluated the radiographs at different times, with an interobserver agreement of 0.72.

## Results

The total number of patients evaluated during the period was 228 (456 hips). According to the established criteria, 93 patients were included in the present study, 49 males and 44 females. The excluded patients are represented in **Table 1**. The average age was 39.9 years old (ranging from 20 to 60 years old, standard deviation [SD] = 10.52), the mean right hip CE angle was  $31.5^\circ$  (ranging from  $20^\circ$  to  $40^\circ$ , SD = 5.30) and the left was  $32.3^\circ$  (ranging from  $20^\circ$  to  $40^\circ$ , SD = 5.11). The mean AI was

**Table 1** Description of patients excluded from the study

Exclusion Criteria	Excluded
Previous hip or spine surgery	6
Arthrosis $\geq$ Tönnis 2	12
Severe DDH	8
Global acetabular overcoverage	14
Sign of intersection of acetabular lines	60
Asymmetry of CE angle $1^\circ$ or $2^\circ$	11
Asymmetry of CE angle + unilateral acetabular retroversion	9
SCFE or Legg-Perthes-Calvé	3
Radiography without adequate quality	12
Total	135

Abbreviations: CE, CE angle; DDH, Developmental Dysplasia of the Hip; SCFE, slipped capital femoral epiphysis.

5.14 (ranging from 0 to 10, SD = 2.97) in the right hip and 5.17 (ranging from 0 to 10, SD = 3.09) in the left hip.

There were 38 patients included in the control group, with mean axes measurements of H1, H2, V1, HR and VR presented in **Table 2**. Regarding H1, asymmetric measurement was found in 4 cases (10.5%), 5 cases in H2 (13.1%), 7 cases in V1 (18.4%), 5 cases in HR (13.1%), and 1 case in VR (2.63%).

In group 1, 55 patients were included. The average axis measurements of H1, H2, V1, HR and VR are presented in **Table 3**. Regarding H1, asymmetric measurement was found in 24 cases (43.6%), 50 cases in H2 (90.9%), 28 cases in V1 (50.9%), 16 cases in HR (29.09%), and 8 cases in VR (14.5%) (**Figure 2**).

The groups were considered homogeneous, since they did not differ in relation to gender, age, CE angle and AI ( $p = 0.086$ ). In the comparison between the control group and group 1 (**Table 4**), a statistically significant difference was observed for the asymmetry of the measurements in H1 ( $p < 0.001$ ), H2 ( $p < 0.001$ ) and V1 ( $p = 0.005$ ). For the measures HR and VR, no statistically significant difference was observed ( $p = 0.082$ ;  $p = 0.077$ ).

## Discussion

There is growing evidence in the literature of the association of bone morphological changes in the hip region and the development of symptoms, as well as the possibility of evolution to joint chondral degeneration. These changes may be related to the femur, the acetabulum, or both.<sup>1</sup> Considering the acetabulum, as frequent morphological alterations we can find the overcoverage (FAI) and poor coverage (DDH).<sup>2,3</sup>

Some authors have proposed that hip development disorders not only affect the proximal femur and the acetabulum, as evidenced by pathologies such as FAI and DDH, but throughout the pelvis.<sup>1,10</sup> However, there is no consensus on which pelvic bone deformities correlate with acetabular morphological changes. We believe that a better understanding of these dysmorphisms may lead to easier diagnosis of hip joint pathologies.

Fujii et al<sup>12</sup> performed a study evaluating the axial plane rotational alignment of the iliac bone in CT scans of patients with DDH, and questioned whether rotational deformity was present in the DDH; whether rotation angles were correlated with acetabular version and inclination; and whether the rotation angles were correlated with the acetabulum deficiency region. The results showed that the internal rotation (IR) of the upper third of the hemipelvis (from upper part of the iliac bone to the anterior inferior iliac spine [AIIS]) correlates with the diagnosis of DDH.<sup>12</sup> Iliac bone IR in patients with DDH was also observed by authors as Kumeta et al<sup>13</sup> and Suzuki,<sup>14</sup> and it is believed that, with this deformity, the acetabulum tends to rotate anterosuperiorly, resulting in decreased anterosuperior coverage and increased posterior coverage.

Also, Fujii et al<sup>12</sup> correlated external rotation of the lower third of the hemipelvis (between the iliac bone and the ischiopubic branch) with acetabular retroversion in patients with DDH. This finding is corroborated by Kalberer et al.,<sup>15</sup> who observed the prominence of the ischial spine in patients with acetabular retroversion.

**Table 2** Description of measurement values H1, H2, V1, HR and VR in control group

Groups		H1 R	H1 L	H2 R	H2 L	V1 R	V1 L	HR R	HR L	VR R	VR L
Control	1	71	71	94	93	101	102	67	67	67	68
	2	57	65	91	92	92	91	96	92	55	51
	3	55	58	85	87	103	100	90	88	80	79
	4	51	52	86	89	95	98	93	91	58	57
	5	43	43	90	80	115	115	80	88	55	55
	6	49	49	97	98	112	112	90	90	57	57
	7	66	67	88	88	110	110	76	76	68	69
	8	55	61	92	100	126	124	91	100	66	68
	9	50	50	111	113	134	134	83	84	60	60
	10	73	75	108	106	133	131	91	91	65	67
	11	88	88	106	106	131	139	81	90	77	77
	12	64	62	100	99	131	133	85	85	53	53
	13	72	72	102	100	126	121	76	78	88	90
	13	58	60	105	105	137	137	90	88	51	53
	15	57	60	110	115	105	107	87	85	75	73
	16	55	57	85	87	133	134	85	83	52	50
	17	78	78	108	109	132	127	91	90	69	67
	18	62	60	126	124	137	143	88	87	60	61
	19	72	70	100	100	142	142	80	82	80	80
	20	57	55	105	105	151	141	96	97	59	59
	21	60	60	103	102	112	112	84	82	77	76
	22	58	59	94	92	110	110	94	86	67	66
	23	56	56	98	97	97	98	89	89	77	77
	24	51	53	102	101	110	110	98	98	78	78
	25	50	50	98	98	111	112	89	91	57	56
	26	56	57	88	88	110	110	76	76	69	69
	27	65	68	86	88	104	101	89	88	81	80
	28	50	52	87	90	95	97	93	93	58	56
	29	50	50	112	113	134	134	83	83	60	61
	30	64	65	108	108	132	131	90	89	66	67
	31	64	63	99	98	132	133	85	86	54	53
	32	58	60	105	105	137	137	82	84	53	54
	33	55	57	85	86	130	131	85	85	52	51
	34	82	82	100	100	140	138	81	82	77	77
	35	56	55	103	102	112	112	82	80	76	76
	36	55	54	99	100	97	96	90	90	77	77
	37	63	64	102	101	107	109	95	95	75	75
	38	80	80	100	99	140	142	80	80	82	82
	Mean	60.68	61.53	99.05	119.89	119.84	86.34	86.55	66.61	66.45	98.89
	Standard Deviation	10.212	10.01	9.291	16.256	16.045	6.671	6.5	10.612	10.84	9.282

Abbreviations: L, Left Hip; R, Right Hip.

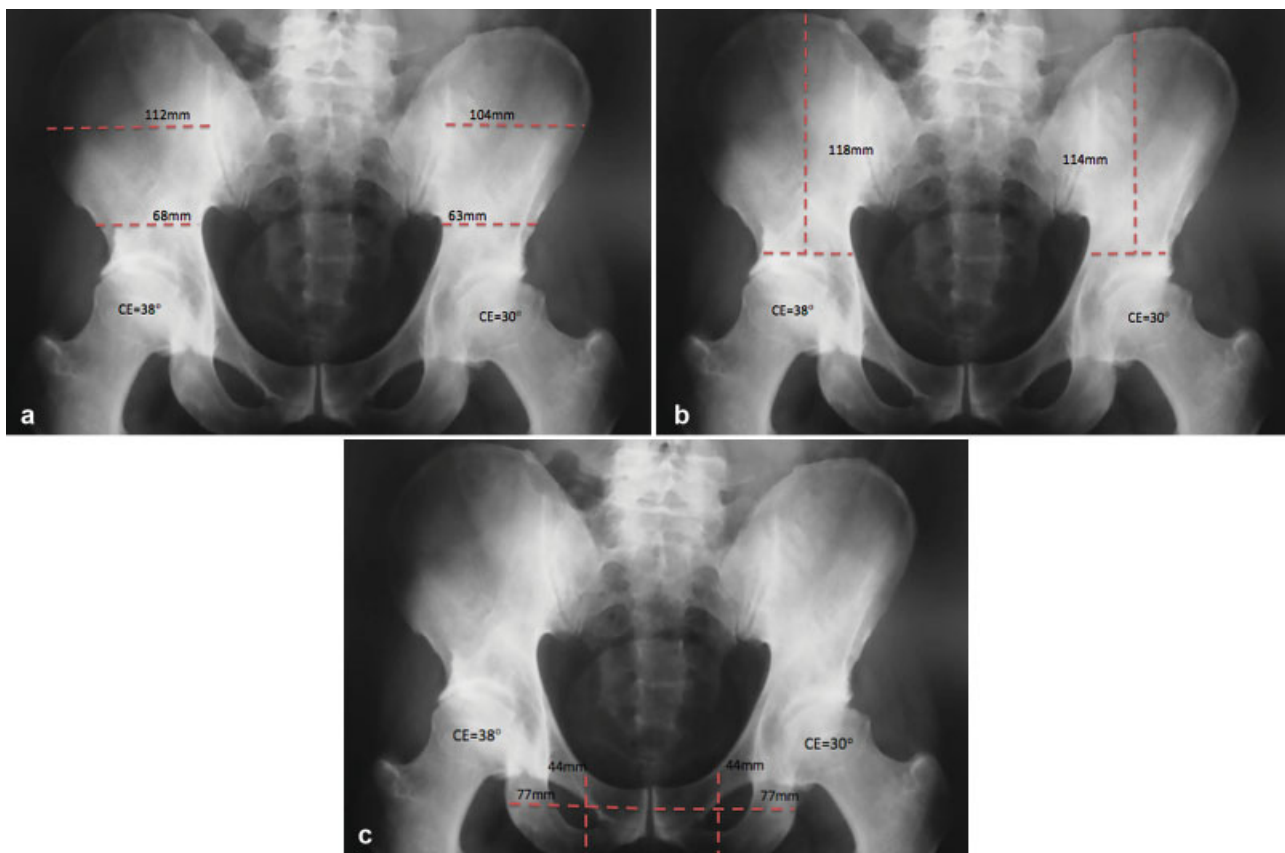
**Table 3** Description of measurement H1, H2, V1, HR and VR in group 1

Groups		H1 R	H1 L	H2 R	H2 L	V1 R	V1 L	HR R	HR L	VR R	VR L
Acetabular inclination	1	45	45	90	80	100	99	105	105	68	66
	2	84	81	90	92	170	170	76	76	72	70
	3	60	50	110	100	100	100	80	80	72	74
	4	50	45	100	94	100	105	96	96	64	63
	5	62	62	107	100	113	115	87	87	72	72
	6	55	50	104	100	102	104	88	88	77	75
	7	53	58	72	89	105	109	75	73	63	70
	8	60	54	92	86	112	110	88	86	67	66
	9	56	57	110	117	110	115	97	107	64	62
	10	50	50	90	98	100	100	70	74	67	65
	11	73	64	107	97	112	112	69	70	65	65
	12	57	51	92	93	107	107	80	79	70	68
	13	50	58	92	97	128	123	90	92	47	47
	13	82	73	114	110	134	139	93	90	77	77
	15	69	69	120	124	138	143	90	80	84	75
	16	55	60	118	128	146	145	88	87	52	50
	17	52	58	76	80	127	124	89	89	59	59
	18	70	70	112	119	135	138	90	90	58	60
	19	55	48	115	100	128	108	85	83	40	42
	20	67	83	116	120	136	136	75	66	55	53
	21	61	62	118	109	135	143	85	75	87	72
	22	51	40	85	92	124	127	83	86	57	57
	23	49	49	148	123	144	146	95	93	60	60
	24	80	82	104	97	119	120	73	75	85	83
	25	47	46	82	88	118	116	86	84	57	55
	26	53	53	101	96	109	132	82	84	75	73
	27	69	69	102	98	138	129	92	90	60	58
	28	62	60	95	94	134	135	95	94	62	61
	29	42	42	94	102	144	149	102	95	72	67
	30	55	55	98	90	145	153	94	92	85	84
	31	60	60	75	81	113	112	82	83	85	73
	32	62	55	104	94	98	104	70	62	66	64
	33	57	61	102	108	108	104	86	88	77	77
	34	60	61	96	102	102	102	68	68	72	72
	35	44	44	83	91	97	97	77	76	65	65
	36	72	72	119	124	137	143	90	82	83	81
	37	55	61	120	128	145	145	87	87	51	45
	38	52	59	75	80	127	123	89	89	72	71
	39	67	67	113	119	135	139	92	90	58	60
	40	56	48	110	100	128	108	85	83	41	42
	41	66	83	116	121	136	136	71	67	54	44
	42	61	63	117	109	136	143	85	76	74	72

**Table 3** (Continued)

Groups		H1 R	H1 L	H2 R	H2 L	V1 R	V1 L	HR R	HR L	VR R	VR L
	43	51	41	86	92	124	127	82	86	60	60
	44	49	48	140	123	144	144	95	95	58	58
	45	80	82	104	96	119	121	73	74	85	83
	46	48	46	82	89	118	116	87	84	55	58
	47	54	53	101	95	109	132	82	84	74	73
	48	70	69	102	98	138	129	92	91	59	58
	49	44	42	94	101	143	149	98	92	65	66
	50	50	50	98	89	145	153	94	93	70	69
	51	60	61	76	81	113	113	83	83	75	73
	52	62	55	104	93	98	104	70	62	62	61
	53	57	62	101	108	108	104	86	86	72	72
	54	61	61	96	101	103	103	68	66	60	63
	55	45	44	83	92	97	96	77	77	60	59
	Mean	58.49	58.04	100.51	122.44	123.62	84.85	83.45	66.8	64.29	100.93
	Standard Deviation	10.011	11.41	13.179	17.359	18.27	9.093	9.867	11.453	10.544	15.608

Abbreviations: L, Left Hip; R, Right Hip.



**Fig. 2** Case example of group 1. a) Asymmetry of the measurements of the horizontal axis of the upper hemipelvis (H1 and H2) is evinced. b) Asymmetry of the vertical axis measurement of the upper hemipelvis (V1) is evidenced. c) Symmetry of the measurements of the horizontal and vertical axes of the lower hemipelves (HR e VR) is evinced.

**Table 4** Description of the results of the comparison of symmetric and asymmetric measurements of H1, H2, V1, HR and VR, in control group versus group 1

	H1		H2		V1		VR		HR		
Asymmetry	Yes	No	Yes	No	Yes	No	Yes	No	Yes	No	Total
Inclination	24	31	50	5	28	27	0	0	16	39	55
Acetabular	85.70%	47.70%	90.90%	13.20%	77.80%	47.40%	0.00%	0.00%	76.20%	54.20%	59.10%
Control	4	34	5	33	8	30	0	0	5	33	38
	14.30%	52.30%	9.10%	86.80%	12.20%	52.60%	0.00%	0.00%	13.80%	45.80%	40.90%
Total	28	65	55	38	36	57	0	0	21	69	88
	100%	100%	100%	100%	100%	100%	100%	100%	100%	100%	100%
Significance	$p = 0.001$		$p < 0.001$		$p = 0.005$		$p = 0.00$		$p = 0.82$		

These observations suggest that pelvic bone structural changes and acetabular abnormalities are not isolated findings, but are instead part of a *continuum* of structural developmental changes.

In our study, correlation between CE angle variation and upper hemipelvis asymmetry was found. Like Fujii et al,<sup>13</sup> we can see that upper hemipelvis dysmorphisms, resulting from bone development disorders, may influence acetabular morphology. However, we sought to analyze these findings in a group of patients without severe DDH (CE angle < 20°).

To our knowledge, this is the first study that seeks to establish correlations between pelvic dysmorphisms and variation of the CE angle, in the 90th percentile, for the CE angle of the general population (20-40°).<sup>16</sup>

## Conclusion

In the present study, a correlation between CE angle variation and upper hemipelvis asymmetry was found. These findings suggest that upper hemipelvis dysmorphism due to bone development disorders may influence acetabular morphology.

### Conflict of Interests

The authors have no conflict of interests to declare.

## References

- Gosvig KK, Jacobsen S, Sonne-Holm S, Palm H, Troelsen A. Prevalence of malformations of the hip joint and their relationship to sex, groin pain, and risk of osteoarthritis: a population-based survey. *J Bone Joint Surg Am* 2010;92(05):1162-1169
- Agricola R, Heijboer MP, Roze RH, et al. Pincer deformity does not lead to osteoarthritis of the hip whereas acetabular dysplasia does: acetabular coverage and development of osteoarthritis in a nationwide prospective cohort study (CHECK). *Osteoarthritis Cartilage* 2013;21(10):1514-1521
- Reynolds D, Lucas J, Klaue K. Retroversion of the acetabulum. A cause of hip pain. *J Bone Joint Surg Br* 1999;81(02):281-288
- Cooperman D. What is the evidence to support acetabular dysplasia as a cause of osteoarthritis? *J Pediatr Orthop* 2013;33 (Suppl 1):S2-S7
- Tannast M, Siebenrock KA, Anderson SE. Femoroacetabular impingement: radiographic diagnosis—what the radiologist should know. *AJR Am J Roentgenol* 2007;188(06):1540-1552
- Dora C, Leunig M, Beck M, Simovitch R, Ganz R. Acetabular dome retroversion: radiological appearance, incidence and relevance. *Hip Int* 2006;16(03):215-222
- Jamali AA, Mladenov K, Meyer DC, et al. Anteroposterior pelvic radiographs to assess acetabular retroversion: high validity of the “cross-over-sign”. *J Orthop Res* 2007;25(06):758-765
- Murphy RJ, Subhawong TK, Chhabra A, Carrino JA, Armand M, Hungerford M. A quantitative method to assess focal acetabular overcoverage resulting from pincer deformity using CT data. *Clin Orthop Relat Res* 2011;469(10):2846-2854
- Jacobsen S, Sonne-Holm S. Hip dysplasia: a significant risk factor for the development of hip osteoarthritis. A cross-sectional survey. *Rheumatology (Oxford)* 2005;44(02):211-218
- Albiñana J, Morcuende JA, Delgado E, Weinstein SL. Radiologic pelvic asymmetry in unilateral late-diagnosed developmental dysplasia of the hip. *J Pediatr Orthop* 1995;15(06):753-762
- Clohisey JC, Carlisle JC, Beaulé PE, et al. A systematic approach to the plain radiographic evaluation of the young adult hip. *J Bone Joint Surg Am* 2008;90(Suppl 4):47-66
- Kumeta H, Funayama K, Miyagi S, et al. Inward wing ilium of adult hip dysplasia, a characteristic cross sectional pelvic anatomy visualized by CT. *Rinsho Seikeigeka*. 1986;21(01):67-75
- Fujii M, Nakashima Y, Sato T, Akiyama M, Iwamoto Y. Pelvic deformity influences acetabular version and coverage in hip dysplasia. *Clin Orthop Relat Res* 2011;469(06):1735-1742
- Suzuki S. Deformity of the pelvis in developmental dysplasia of the hip: three-dimensional evaluation by means of magnetic resonance image. *J Pediatr Orthop* 1995;15(06):812-816
- Kalberer F, Sierra RJ, Madan SS, Ganz R, Leunig M. Ischial spine projection into the pelvis : a new sign for acetabular retroversion. *Clin Orthop Relat Res* 2008;466(03):677-683
- Jacobsen S, Sonne-Holm S, Søballe K, Gebuhr P, Lund B. Hip dysplasia and osteoarthritis: a survey of 4151 subjects from the Osteoarthritis Substudy of the Copenhagen City Heart Study. *Acta Orthop* 2005;76(02):149-158