



Use of the Retrograde Recipient Vein for Additional Outflow in Free Tissue Transfer

Tetsuji Uemura, MD¹ Mamoru Kikuchi, MD² Hidetaka Watanabe, MD¹ Tetsu Yanai, MD¹

¹ Department of Plastic and Reconstructive Surgery, Saga University, Saga, Japan

² Department of Plastic Surgery, Shimokitazawa Hospital, Tokyo, Japan

Address for correspondence Tetsuji Uemura, MD, Department of Plastic and Reconstructive Surgery, Saga University, 5-1-1 Nabeshima, Saga, Saga 8498501, Japan (e-mail: tetsuji.uemura@gmail.com).

J Reconstr Microsurg Open 2020;5:e1–e6.

Abstract

Keywords

- ▶ retrograde limb of vein
- ▶ retrograde venous anastomosis
- ▶ reconstructive microsurgery

Background The selection of appropriate recipient vessels is essential to the successful outcome of free flap transfer. To improve blood perfusion after reconstruction and reduce the risk of postoperative obstruction of flap vessels, multiple vessels should be chosen as candidate recipients.

Methods For certainty of venous drainage, we have been performing venous anastomosis to the distal end of the recipient vein to utilize the reverse venous flow.

Results A total of 48 cases of reconstruction of the head and neck or breast region with free flaps using retrograde venous anastomosis were performed. The method possibly improves flap circulation and the success rate of the free tissue transfer and reduces the need to extend surgery to search for multiple recipient veins.

Conclusion We emphasized that retrograde limb of vein is useful as a second and/or rescued recipient in free tissue transfer. Retrograde venous anastomosis is a fine and reasonable option when appropriate recipient vessels cannot be found near the defect in the head and neck such as frozen neck or breast region.

Free flap transfer is a reconstruction method that often follows tumor resection in head, neck, and trunk region. The selection of appropriate recipient vessels is essential to the successful outcome of the procedure. To improve blood perfusion after reconstruction and reduce the risk of postoperative obstruction of flap vessels, multiple vessels should be chosen as candidate recipients. If multivascular pedicles are present, anastomosis to multiple and distinct venous drainage pathways (e.g., internal and external jugular veins) should be attempted. If multiple venous drainage pathways cannot be secured, several alternatives can be considered. Use of long vein grafts from a site remote to the defect reduces the success rate of free tissue transfer.¹ Yet, seeking another vessel system in the vicinity of the defect can be time consuming, and the vessels may not be of appropriate caliber. When multiple recipient arteries cannot be secured, one option is to anastomose to both the anterograde and retrograde limbs of a recipient artery after cutting the middle of

the artery.^{2,3} The same consideration applies to venous anastomosis, and since the year 2000, we have been performing dual venous anastomoses with this method on selected cases in which intraoperative observation demanded that a second recipient vein must be found. Here, we discuss our experience with the additional venous anastomosis using the retrograde limb of a cut vein as a second and/or rescued recipient for head and neck and for breast reconstruction.

Subjects and Methods

Subjects of this study were 48 patients treated at the Saga University Hospital and its related hospital between April 2000 and March 2018. They underwent retrograde venous anastomosis for head and neck or breast reconstruction, in which free tissue transfer was adopted. The characteristics and outcomes of the patients are summarized in ▶ **Table 1**. Before a venous anastomosis was performed, the recipient vein was cut

received
October 9, 2018
accepted after revision
July 7, 2019

DOI <https://doi.org/10.1055/s-0039-1701031>.
ISSN 2377-0813.

Copyright © 2020 by Thieme Medical Publishers, Inc., 333 Seventh Avenue, New York, NY 10001, USA.
Tel: +1(212) 760-0888.

License terms



Table 1 Characteristics of patients with retrograde venous flow

n	48
Age (mean ± SD)	54.2 ± 13.8
Sex	
Male	24
Female	24
Diagnosis	
Tongue cancer	20
Cancer of the oral floor	5
Maxillary carcinoma	3
Other head and neck	11
Breast cancer	9
Type of flap	
RAMC	24
DIEP	9
Radial forearm	8
ALT	4
Other	5

Abbreviations: ALT, anterolateral thigh flap; DIEP, deep inferior epigastric artery perforator flap; RAMC, rectus abdominis myocutaneous flap; SD, standard deviation.

in the middle and blood flow was checked from both the anterograde and retrograde limbs. In particular, it was important to check if there was any reflux from the retrograde limb prior to anastomosis. The reliability of retrograde venous flow

was determined by intraoperative observation, and the patency of the anastomosis was verified by microscopy. Engorged veins and those with poor patency were excluded as candidate recipients.

Results

To date, we have performed 48 cases of retrograde venous anastomoses (24 men and 24 women; mean age = 54.2 ± 13.8 years). There were 39 cases for the head and neck region, involving 22 rectus abdominis flaps, two deep inferior epigastric artery perforator flaps, eight radial forearm flaps, four anterolateral thigh flaps, and three others. The nine cases of breast reconstruction involved seven deep inferior epigastric artery perforator flaps and two rectus abdominis flaps (►Table 1). Veins selected for ante/retrograde limb anastomosis were as follows: end-to-end type antegrade recipient vein and retrograde recipient vein are 36 cases (13 superior thyroid vein, seven superficial temporal vein, seven thoracodorsal vein, four external jugular vein, two facial vein, and two internal mammary vein), end-to-side type antegrade recipient vein and retrograde recipient vein are 10 cases (nine superior thyroid vein and one facial vein) and only retrograde recipient vein called salvage type are two cases (one facial vein, one cutaneous vein of face; ►Fig. 1A–D).

One of the cases was a salvage operation due to complete venous thrombus without anterograde venous anastomosis. There were six anastomotic complications (five arterial thrombi and one venous thrombus). All five cases of arterial thrombus had received full-dose radiotherapy called “frozen

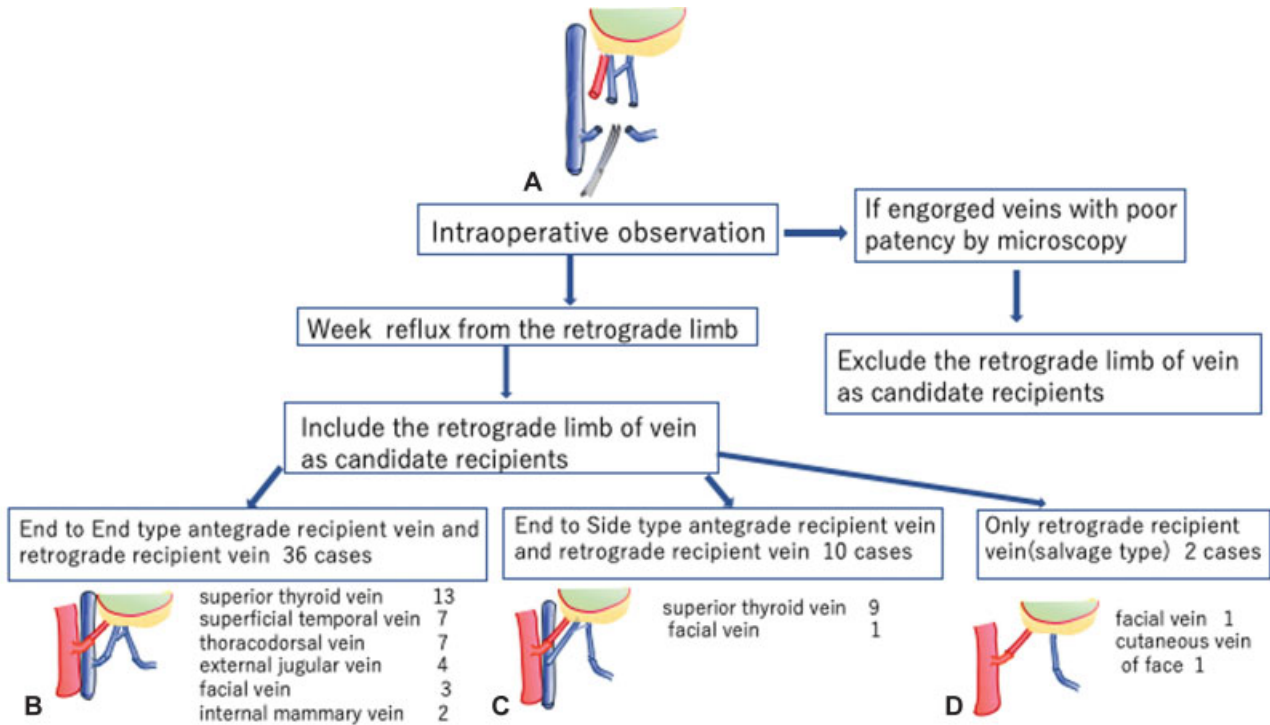


Fig. 1 Selection of the use of retrograde recipient vein and numbers. (A) Multiple veins from a free flap and cutting the recipient vein in the middle. (B) End-to-end type antegrade recipient vein and retrograde recipient vein. (C) End-to-side type antegrade recipient vein and retrograde recipient vein. (D) Only retrograde recipient vein (salvage type).

Table 2 Surgical results

Flap-related complications	n	Percentage
Recipient artery thrombosis	5	10.4
Recipient vein thrombosis	1	2
Partial necrosis	1	2
Complete necrosis	5	10.4

neck” and early postoperative embolization due to severe arterial sclerosis; flaps in these cases were pale but not congestive, and the veins were patent when observed during the salvage operation. All five arterial thrombus cases were totally necrotic, while one venous thrombus showed partial necrosis (►Table 2).

We demonstrate three cases: Case 1 (►Fig. 2A, B), Case 2 (►Fig. 3A, B), and Case 3 (►Fig. 4A–C).

Discussion

Free tissue transfer is a common procedure after resection of malignant tumors. Typically, identifying suitable recipient vessels is not difficult; however, candidate recipient vessels are often limited in number due to a preoperative radiation therapy or radical neck dissection. The internal jugular vein is often selected for anastomosis in the head and neck region despite reports of internal jugular vein occlusion after dissection.^{4–6} Vascular anastomosis to a plurality of vessels is a hedge to increase the success rate of the procedure. While interposition of vein grafts from a remote site is common, long vein grafts reduce the success rate of free tissue transfer.¹ Moreover, seeking another vessel as a second recipient is time consuming and difficult. If an artery bleeds profusely from both ends when cut, and the distal end of the vessel appears to be positionally favorable for anastomosis, retro-

grade flow is a viable option for microvascular recipient anastomoses.^{2,3,7,8} In the same manner, we considered retrograde venous anastomosis a viable option.

Basic research on reverse radial forearm flaps,^{9–12} VAF flap; reverse-flow sural flaps in the lower limbs and other distal pedicle flaps have contributed to the understanding of retrograde venous flow.¹³ Within these flaps, venous drainage occurs in reverse via the venae comitantes against the direction of the valves. This can occur only if the valves are bypassed or rendered incompetent. Lin et al⁹ found that venous blood drained in retrograde fashion when valves were bypassed either by a “cross pattern” of communicating branches between the venae comitantes or a “bypass pattern” of collateral branches that allowed bypassing of valves. Moreover, according to Torii et al¹⁴, “the direction of the valve axis in relation to surrounding tissue aids valve function. Dissection and transfer of the pedicle changes the valve axis.” And Shih et al¹⁵ reported about the use of the retrograde limb of the superficial temporal vein as an alternative option to overcome difficult venous return in head and neck free flap reconstruction.

In our cases, we performed retrograde venous anastomosis with the superior thyroid vein, superficial temporal vein, facial vein, cutaneous vein of the neck, thoracodorsal vein, external jugular vein, and internal mammary vein. Use of the retrograde limb of the internal mammary vein as a second recipient has been previously reported.^{16–21} In the present study, satisfactory outcomes were achieved in all seven cases using the retrograde limb of the thoracodorsal vein. For breast reconstruction in particular, retrograde venous drainage with the internal mammary vein and thoracodorsal vein has turned out to be an excellent option. In contrast, only a few reports exist on the head and neck region. One study reported use of the retrograde limb of the superficial temporal vein as a recipient vein for nine cases of “frozen neck” secondary to prior neck irradiation and surgery, and the nine flaps all survived.¹⁵ In our study, a free rectus abdominis myocutaneous flap in a

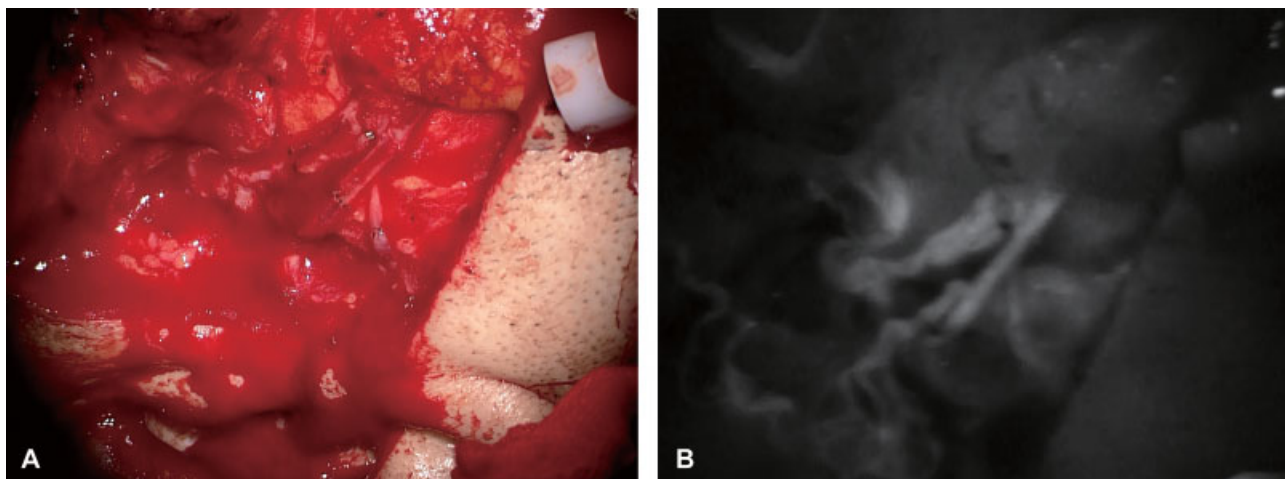


Fig. 2 A 62-year-old male patient with a skull base tumor had his tumor resected by a neurosurgeon; a free rectus abdominis myocutaneous flap was used to reconstruct the defect. The deep inferior epigastric artery was anastomosed with the superior thyroid artery. Both of the anterograde and retrograde limbs of the superior thyroid vein were used as recipients (A). After anastomosis, normal arterial flow and anterograde and retrograde venous flow around the anastomosis site were observed by the empty-refill test using microvascular forceps and microscopic near-infrared fluorescence imaging with indocyanine green, the result suggesting the reconstruction was successful (B; under ICG mode by microscope). The flap showed no sign of congestion postoperatively. ICG, indocyanine green.

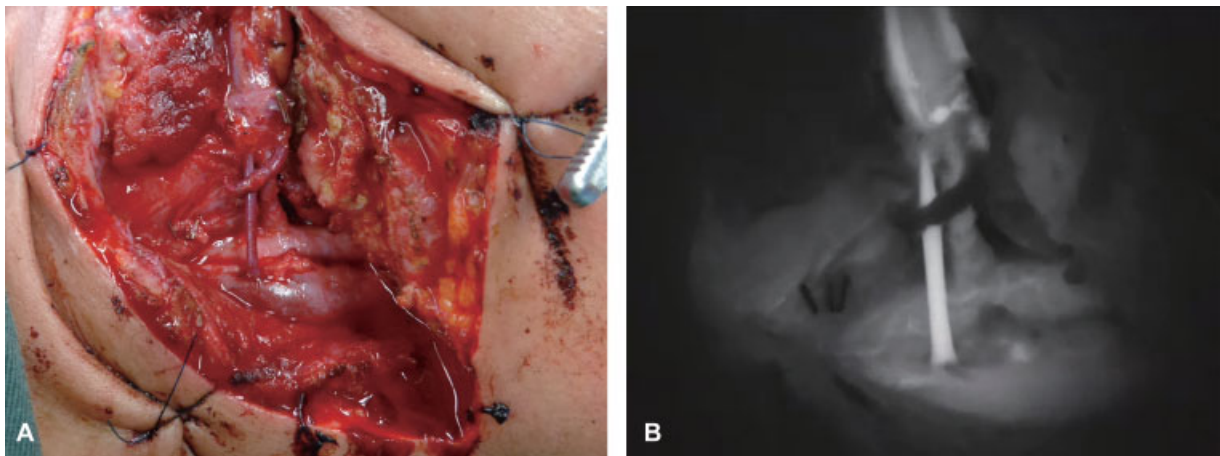


Fig. 3 A 38-year-old male patient with tongue cancer underwent partial glossectomy; free rectus abdominis myocutaneous flap transfer was used to reconstruct the defect. The deep inferior epigastric artery was anastomosed with the superior thyroid artery. The main drainage vein was anastomosed with the internal jugular vein, and the retrograde limb of the superior thyroid vein was used as the second recipient (A). Anastomosis was tested with the empty-refill test using microvascular forceps, with satisfactory results. However, retrograde flow of the superior thyroid vein was not observed by the empty-refill test using microvascular forceps and microscopic near-infrared fluorescence imaging (B under ICG mode by microscope). The flap showed no sign of postoperative congestion. The reconstruction was successful, with no complications. ICG, indocyanine green.

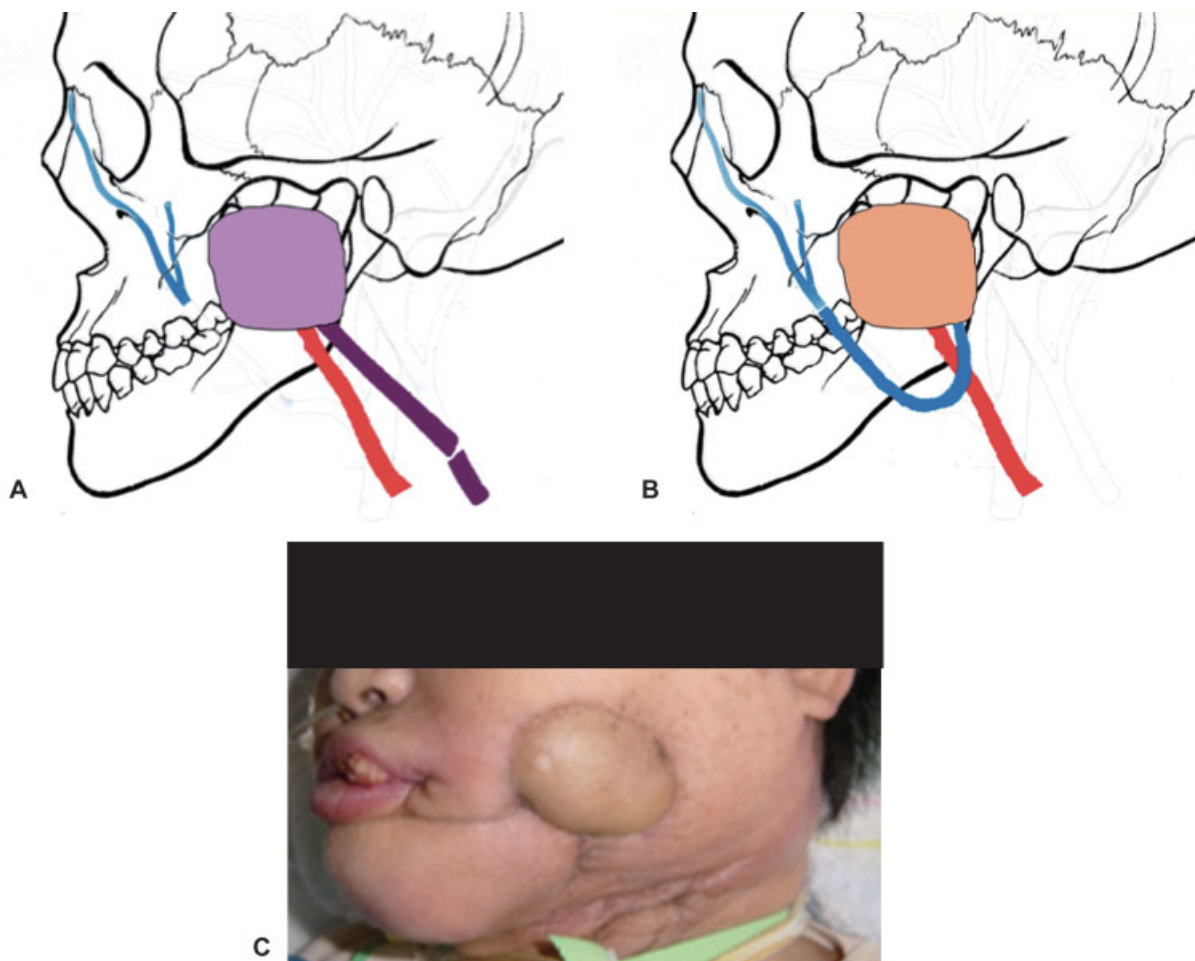


Fig. 4 A 65-year-old female with maxillary carcinoma; free rectus abdominis myocutaneous flap transfer was used to reconstruct the defect in the cheek. The deep inferior epigastric artery was anastomosed with the superior thyroid artery. The main drainage vein was anastomosed with the external jugular vein using end-to-end anastomosis. The internal jugular vein in the left side was sacrificed during primary surgery. Total 6 hours after primary surgery, a sudden congestion of flap occurred. In the emergency exposure, the proximal side of anastomosis in the external jugular vein had total thrombosis (A). This free rectus abdominis myocutaneous flap was salvaged using the retrograde limb of a cutaneous vein of the face as a single recipient after venous thrombus from a previous surgery (B). The flap showed no sign of congestion postoperatively. The flap was salvaged totally and alive (C).

65-year-old female (Case 3) was salvaged using the retrograde limb of a cutaneous vein of the neck as a single recipient after venous thrombus from a previous surgery.

Several reports support the method described herein. On the one hand, anatomical studies of the facial vein,²² external jugular vein,²³ and internal jugular vein²⁴ report a high incidence of valve incompetence in the head and neck region, allowing for bidirectional blood flow.²⁴ On the other hand, the blood from the dermis of the face is collected by the polygonal venous network and enters the loop vein through the cutaneous branches after which blood flows away from the face through the superficial temporal vein, the facial vein, and the communicating branches and eventually enters the deep veins.²⁵ In our recent experience with microscopic near-infrared fluorescence imaging using indocyanine green, no flow was observed by venography despite patency of the anastomosis site in the empty-refill test. This may be due to antegrade anastomosis to a thick vein and retrograde anastomosis to a thinner vein. In such cases, we placed greater value on the results of the empty-refill test and did not reanastomose; no signs of congestion were observed postoperatively.

Although retrograde venous anastomosis is not indicated for all cases, it should nevertheless be considered an option. After retrograde anastomosis, we recommend assessing venous flow with an intraoperative flowmeter or indocyanine green venography. We performed dual venous drainage of the anastomosis to the antegrade and retrograde limbs of the recipient vein. This method enhances the outcome of free flap transfer by anastomosing multiple vein sources, thus requiring less time than searching for a new recipient from other sites. Retrograde recipient vein for additional outflow is a fine and reasonable option when appropriate recipient vessels cannot be found near the defect in the head and neck regions like frozen neck or in the breast region.

Conclusion

In vascular anastomosis for free tissue transfer, while multiple drainage veins may exist in the transferred tissue, there are many cases in which adequate recipient veins cannot be found nearby. In the present study, we performed 48 cases of reconstruction of the head and neck or breast region with free flaps using retrograde venous anastomosis. The method reduces the unnecessary need to extend surgery to search for multiple recipient veins, and possibly ends in improving flap circulation and the success rate of the procedure. While retrograde flow flaps, which have retrograde venous drainage and the distal end elevated as a pedicle, are already in common use, use of the retrograde limb of a cut vein as a recipient is not yet widespread. As a new option for venous drainage to increase the safety of free tissue transfer, we considered herein the potential and safety of retrograde venous anastomosis, and discuss our recipient vessel selection process as well as points of caution.

Conflict of Interest

None declared.

Acknowledgment

The authors thank Prof. Hak Chang in Seoul National College of Medicine, Korea, for critical review about retrograde venous return of the face.

References

- 1 Miller MJ, Schusterman MA, Reece GP, Kroll SS. Interposition vein grafting in head and neck reconstructive microsurgery. *J Reconstr Microsurg* 1993;9(03):245–251, discussion 251–252
- 2 Neligan PC, She-Yue H, Gullane PJ. Reverse flow as an option in microvascular recipient anastomoses. *Plast Reconstr Surg* 1997; 100(07):1780–1785, discussion 1786–1787
- 3 Hölzle F, Hohlweg-Majert B, Kesting MR, et al. Reverse flow facial artery as recipient vessel for perforator flaps. *Microsurgery* 2009; 29(06):437–442
- 4 Kubo T, Haramoto U, Yano K, et al. Internal jugular vein occlusion in head and neck microsurgical reconstruction. *Ann Plast Surg* 2002;49(05):490–494
- 5 Wax MK, Quraishi H, Rodman S, Granke K. Internal jugular vein patency in patients undergoing microvascular reconstruction. *Laryngoscope* 1997;107(09):1245–1248
- 6 Quraishi HA, Wax MK, Granke K, Rodman SM. Internal jugular vein thrombosis after functional and selective neck dissection. *Arch Otolaryngol Head Neck Surg* 1997;123(09):969–973
- 7 Zevallos JP, Urken ML. Reverse-flow scapular osteocutaneous flap for head and neck reconstruction. *Head Neck* 2013;35(06):E171–E174
- 8 Lin CH, Wei FC, Chen CC, Wu WC. Reversed arterial flow in free flap surgery for leg reconstruction. *Ann Plast Surg* 1997;39(06):590–596
- 9 Lin SD, Lai CS, Chiu CC. Venous drainage in the reverse forearm flap. *Plast Reconstr Surg* 1984;74(04):508–512
- 10 Wu TY, Brown RE. Antegrade venous drainage in a reverse radial forearm flap. *Plast Reconstr Surg* 2004;113(02):645–648
- 11 Nakajima H, Imanishi N, Aiso S, Fujino T. Venous drainage of the radial forearm and anterior tibial reverse flow flaps: anatomical and radiographic perfusion studies. *Br J Plast Surg* 1997;50(06):389–401
- 12 Timmons MJ. The vascular basis of the radial forearm flap. *Plast Reconstr Surg* 1986;77(01):80–92
- 13 Imanishi N, Nakajima H, Fukuzumi S, Aiso S. Venous drainage of the distally based lesser saphenous-sural veno-neuroadipofascial pedicled fasciocutaneous flap: a radiographic perfusion study. *Plast Reconstr Surg* 1999;103(02):494–498
- 14 Torii S, Namiki Y, Mori R. Reverse-flow island flap: clinical report and venous drainage. *Plast Reconstr Surg* 1987;79(04):600–609
- 15 Shih HS, Hsieh CH, Feng GM, Feng WJ, Jeng SF. An alternative option to overcome difficult venous return in head and neck free flap reconstruction. *J Plast Reconstr Aesthet Surg* 2013;66(09): 1243–1247
- 16 Kerr-Valentic MA, Gottlieb LJ, Agarwal JP. The retrograde limb of the internal mammary vein: an additional outflow option in DIEP flap breast reconstruction. *Plast Reconstr Surg* 2009;124(03): 717–721
- 17 Venturi ML, Poh MM, Chevray PM, Hanasono MM. Comparison of flow rates in the antegrade and retrograde internal mammary vein for free flap breast reconstruction. *Microsurgery* 2011;31 (08):596–602
- 18 Al-Dhamin A, Bissell MB, Prasad V, Morris SF. The use of retrograde limb of internal mammary vein in autologous breast reconstruction with DIEAP flap: anatomical and clinical study. *Ann Plast Surg* 2014;72(03):281–284
- 19 Mohebbi J, Gottlieb LJ, Agarwal JP. Further validation for use of the retrograde limb of the internal mammary vein in deep inferior epigastric perforator flap breast reconstruction using laser-assisted indocyanine green angiography. *J Reconstr Microsurg* 2010;26(02):131–135
- 20 Salgarello M, Visconti G, Barone-Adesi L, Cina A. The retrograde limb of internal mammary vessels as reliable recipient vessels in

- DIEP flap breast reconstruction: a clinical and radiological study. *Ann Plast Surg* 2015;74(04):447–453
- 21 Gravvanis A, Tsoutsos D, Papalois A, Karabinis A, Dimitriou V, Karakitsos D. The retrograde limb of the internal mammary vein in the swine model: a sufficient outflow option in free tissue transfer. *Plast Reconstr Surg* 2010;125(04):1298–1299, author reply 1299
- 22 Nishihara J, Takeuchi Y, Miki T, Itoh M, Nagahata S. Anatomical study on valves of human facial veins. *J Craniomaxillofac Surg* 1995;23(03):182–186
- 23 Nishihara J, Takeuchi Y, Miyake M, Nagahata S. Distribution and morphology of valves in the human external jugular vein: indications for utilization in microvascular anastomosis. *J Oral Maxillofac Surg* 1996;54(07):879–882
- 24 Akkawi NM, Agosti C, Borroni B, et al. Jugular valve incompetence: a study using air contrast ultrasonography on a general population. *J Ultrasound Med* 2002;21(07):747–751
- 25 Onishi S, Imanishi N, Yoshimura Y, et al. Venous drainage of the face. *J Plast Reconstr Aesthet Surg* 2017;70(04):433–440