


Identification of the Artery of Adamkiewicz Using Multidetector Computed Tomography Angiography (MCTA)*

Identificação da artéria de Adamkiewicz usando angiotomografia computadorizada por multidetectores (ATCM)

Flávio P.F. Piola¹  Marcello H. Nogueira-Barbosa² Daniel A.C. Maranhão¹ Adélson A. Martins³
Maurício F. Barbosa⁴ Carlos F.P. Silva Herrero¹

¹Biomechanics Department, Medicina e Reabilitação do Aparelho Locomotor, Faculdade de Medicina de Ribeirão Preto, Universidade de São Paulo, Ribeirão Preto, SP, Brazil

²Division of Radiology, Faculdade de Medicina de Ribeirão Preto, Universidade de São Paulo, Ribeirão Preto, SP, Brazil

³Instituto de Radiologia Presidente Prudente, Presidente Prudente, SP, Brazil

⁴Faculdade de Medicina de Botucatu, Universidade Estadual de São Paulo, Botucatu, SP, Brazil

Address for correspondence Flávio P.F. Piola, PhD, Departamento de Biomecânica, Medicina e Reabilitação do Aparelho Locomotor, Faculdade de Medicina de Ribeirão Preto, Universidade de São Paulo, Avenida dos Bandeirantes, 3900, Ribeirão Preto, SP, 14048-900, Brazil (e-mail: flaviopfpiola@gmail.com).

Rev Bras Ortop 2020;55(1):70–74.

Abstract

Objective The aim of the present study is to evaluate the artery of Adamkiewicz by multidetector computed tomography angiography (MCTA) in a Brazilian population.

Methods Two independent observers evaluated 86 coronary MCTA examinations. The variables studied included the identification of the artery of Adamkiewicz at its origin level, and its entry side in the spine.

Results The artery of Adamkiewicz was detected in 71 (82.5%) examinations. The origin level was identified between the 9th and 11th thoracic vertebrae (T9 and T11) in 56 (79.2%) patients. In 65 (91.5%) patients, the artery was on the left side. The identification of the artery of Adamkiewicz using MCTA showed high reproducibility.

Conclusions Our results were consistent with the literature regarding the identification of the artery of Adamkiewicz using MCTA, suggesting that this technique should be considered as an option to recognize this structure. In addition, we found that the distribution of the artery of Adamkiewicz in the Brazilian population is similar to that of other populations, that is, its most common origin is at the left side, between the 8th and 12th thoracic vertebrae (T8–T12).

Keywords

- ▶ angiography/ methods
- ▶ arteries/pathology
- ▶ multidetector computed tomography
- ▶ paraplegia
- ▶ spinal cord

Resumo

Objetivo Avaliar a artéria de Adamkiewicz por angiotomografia computadorizada por multidetectores (ATCM) em uma população brasileira.

* Work developed at the Biomechanics Department, Medicina e Reabilitação do Aparelho Locomotor, Faculdade de Medicina de Ribeirão Preto, Universidade de São Paulo, Ribeirão Preto, SP, Brazil.

Palavras-chave

- ▶ angiografia/métodos
- ▶ artéria/patologia
- ▶ tomografia computadorizada multidetectores
- ▶ paraplegia
- ▶ medula espinal

Métodos Dois observadores independentes avaliaram 86 exames de ACTM. As variáveis estudadas incluíram a identificação da artéria de Adamkiewicz no nível de origem e o lado de entrada da artéria na coluna vertebral.

Resultados A artéria de Adamkiewicz foi identificada em 71 (82,5%) exames. O nível de origem foi identificado entre a 9a e a 11a vértebras torácicas (T9 e T11) em 56 (79,2%) pacientes. Em 65 (91,5%) pacientes, a artéria foi identificada no lado esquerdo. A identificação da artéria de Adamkiewicz usando ATCM mostrou elevada reprodutibilidade.

Conclusões Obtivemos resultados consistentes com os da literatura prévia quanto à identificação da artéria de Adamkiewicz utilizando angiotomografia computadorizada por multidetectores. Nossos resultados sugerem que a ATCM pode ser considerada como uma opção para identificar a artéria de Adamkiewicz. Além disso, encontramos uma distribuição da artéria de Adamkiewicz na população brasileira semelhante à de outras populações, com a artéria de Adamkiewicz originando-se mais comumente no lado esquerdo, entre a 8a e a 12a vértebras torácicas (T8–T12).

Introduction

Neurological deficits after vascular and spinal surgical procedures are potentially serious complications due to the involvement and impairment of spinal blood supply.¹ Previous studies have shown an incidence of postoperative paraplegia and paraparesis of 11.3%.² Puertas et al³ reported permanent neurological injury in 4% of the patients surgically treated for idiopathic scoliosis through instrumentation and posterior arthrodesis. The artery of Adamkiewicz (AAK) is the main artery responsible for the blood supply to the spinal cord from the 8th thoracic (T8) level up to the conus medullaris.^{4–6} Therefore, the preoperative identification of the AAK plays a critical role in preventing spinal cord ischemia or infarction.

The rate of identification of the AAK by selective spinal angiography ranges from 65 to 86%.^{1,7} However, selective spine angiography can be time-consuming and technically challenging, in addition of posing potential risks to the patient. Procedure-related complications were reported in 1.2% of the patients.⁸ Multidetector computed tomography angiography (MCTA) is an efficient, noninvasive alternative method for AAK visualization.^{8–10}

Identification of the AAK by current MCTA techniques is feasible.^{8,10–12} However, these methods are expensive, as they often require specific sequences or protocols, in addition to costly and elaborate workstations.¹¹ Thus, in most centers, identification of the AAK is not part of the preoperative routine assessment for spinal and vascular surgeries.

Although AAK demonstrations have been well-documented in Europe, North America, and Asia, its visualization may vary across regions, and few studies in Latin American populations have detailed the location of the AAK.^{8,11–14} Our hypothesis is that the position of the AAK would differ from previously reported data. The current study aims to evaluate AAK location in a Brazilian populational sample.

Materials and Methods

The present study was approved by the Research Ethics Committee from Hospital das Clínicas, Faculdade de Medicina de Ribeirão Preto, Universidade de São Paulo, Ribeirão Preto, SP, Brazil (Opinion Number 957.443, Report dated November 13, 2014). This is a retrospective study consisting of consecutive MCTAs from 96 patients examined for coronary artery disease from January 2015 to January 2016. Subjects with evidence of acute pathology or those with signs of previous spinal surgery were excluded from the study. A total of 86 patients met the inclusion criteria and were considered for our evaluation. Multidetector computed tomography angiography images of 57 men and 29 women were evaluated. The average age of the male patients was 56.9 years (31–82 years), and the average age of the female patients was 59.7 years (18–83 years).

Image Acquisition and Reconstruction

All MCTA data were acquired using the Aquilion Prime 160 sections per rotation computed tomography (CT) scanner (Toshiba Medical Systems Corporation, Otawara-shi, Tochigi, Japan). The scanning parameters were 120 kV, 250 mA (average), 0.50 collimation, and a rotation period of 0.35 seconds (pitch, 0.641). Multiplanar CT reconstructions were performed in the axial plane, with 0.5 mm in thickness, 0.3 mm of reconstruction interval, and field of view ranging from 300 to 340 mm. In addition, 8-mm thick oblique coronal multiplanar reconstructions using the maximum projection intensity (MPI) technique were obtained at a Vitrea workstation (Vital Images, Inc., Minnetonka, MN, USA).

Intravenous Injection and Scanning Protocol

The injection protocol involved the use of the nonionic contrast medium Iopamidol, 755 mg I/m (Iopamiron 370, Patheon, Ferentino, Frosinone, Italy). A dose of 80 mL of contrast medium was administered through a 16 to 18-gauge

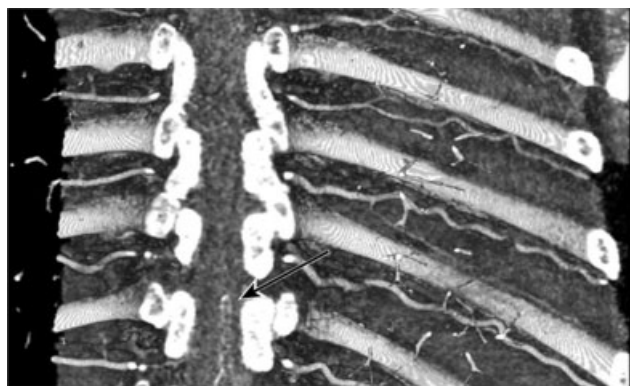


Fig. 1 Typical AAK configuration in hairpin appearance.

intravenous line in the antecubital vein at a flow rate of 5 mL/s and followed by a 40 mL bolus of saline. Scanning started 7 seconds after the contrast medium reached 180 Hounsfield units (HU) in the region of interest (ROI) positioned over the ascending aorta.

Image Analysis

The distal segment of the AAK and the anterior spinal artery typically demonstrate a hairpin configuration (► **Figure 1**). Therefore, the AAK is identified by the following criteria: a continuous, straight vascular structure extending from an intercostal or lumbar artery, which rises on the anterior sagittal medial surface of the spinal cord and presents a characteristic hairpin curve in the anastomosis with the anterior spinal artery. Initially, oblique coronal multiplanar reconstructions obtained with the MIP technique were used to identify the rotation at the junction between the anterior spinal artery and the great anterior radiculomedullary artery. The next step was to identify the AAK source level and location (► **Figure 2**).

Inter- and Intraobserver Reproducibility

Two observers independently assessed CT scans using the same workstation (Vitrea by Vital Images, Inc.). Observer 1 was a radiologist with 15 years of experience in performing and interpreting diagnostic angiography, whereas observer 2 was a spine surgeon with 20 years of practice. Observer 1 performed

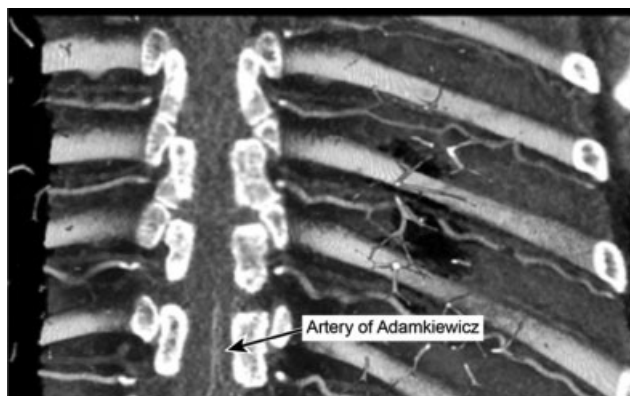

Fig. 2 AAK inlet on the left side at T11 level.

an additional randomized assessment after a 2-month interval to estimate intraobserver reliability.

Statistical Analysis

The AAK identification reproducibility was assessed by calculating the inter- and intraobserver agreement of its detection, source level, and location side using the Cohen kappa coefficient. Agreement was determined as follows: values from 0 to 0.20 indicated poor agreement; from 0.21 to 0.40, small agreement; from 0.41 to 0.60, moderate agreement; from 0.61 to 0.80, substantial or good agreement; and from 0.81 to 1.00, virtually perfect or very good agreement. Statistical analysis was performed using Stata13 (StataCorp, College Station, TX, USA).

Results

Observer 1 identified the AAK in 71 patients (82.5%) when analyzing the first image. As such, the AAK was not detected by observer 1 in 15 patients (17.5%) of the study sample. Regarding the location side, when identified, the AAK originated from the left side of the body in 65 patients (91.5%) and from the right side in 6 patients (8.5%). The segmental level ranged from the sixth thoracic level to the first lumbar intervertebral space. The most frequent origin levels were T10, T9, and T11 in 23 (32.5%), 19 (26.7%) and 14 (20%) scans, respectively. On the other hand, less common source levels included T6 and L1 levels (► **Table 1**). Artery of Adamkiewicz anomalies or ipsilateral or bilateral duplications were not observed. Side and source levels of the AAK are shown in ► **Table 1**. After a random selection of 18 scans (20% of the sample), observer 1 performed a second evaluation. The AAK was identified in 17 scans (95%), but not in 1 scan (5%). The level of origin ranged from T6 to L1, and the AAK originated from the left side in 16 patients (94%) and from the right side in only 1 individual (6%). Intraobserver agreement was perfect (kappa = 1) not only for identification of the AAK but also for side and level of origin. Observer 2 identified the AAK in the same 17 (95%) scans, but not in one scan. In these 17 scans, the level of origin ranged from T6 to

Table 1 AAK origin level and entry side in 71 patients

AAK level of origin	AAK side	
	Left	Right
T5	0	0
T6	1	0
T7	0	0
T8	5	0
T9	17	2
T10	22	1
T11	14	3
T12	5	0
L1	1	0

Abbreviations: AAK, artery of Adamkiewicz; L, lumbar; T, thoracic.

L1, and the AAK originated from the left side in 16 patients (94%) and from the right side in 1 individual (6%). Interobserver agreement was also perfect ($\kappa = 1$) for AAK demonstration and determination of side and level of origin.

Discussion

Our results are consistent with previously reported data and revealed that MCTA is a viable technique for AAK identification.^{8,11–14}

Assuming that the anatomy of the AAK in our population may differ from that of other populations, the anatomical study of its location becomes significant and has potential therapeutic implications, especially in planning procedures that could compromise this artery and result in ischemia to the distal portion of the spinal cord.¹⁵ Since many other anatomical variations are found in different ethnicities, we believe that data from previous studies should be interpreted with caution as they may not apply universally.^{15–17}

Although several imaging studies have addressed AAK recognition, there is no consensus about the best technique for identifying it.¹⁷ Several studies have described procedure-related complications when selective spinal angiography was used.^{1,7} More recent publications have favored less invasive techniques, such as magnetic resonance angiography (MRA) or CT angiography.¹⁰ However, as these methods may require special protocols, intravenous contrast medium administration, time and resources in most centers, AAK identification is not part of the routine clinical analysis. Computed tomography angiography, although not invasive, exposes the patient to a significant dose of ionizing radiation. As such, we decided to evaluate the AAK using MCTA, a well-known scan for coronary vascularization assessment.

Previous MCTA studies on AAK visualization and anatomical features included European, American, and Asian populations.^{8,12–14} Despite the increase in vascular and spinal procedures with implications for spinal cord perfusion changes, there may be distinct anatomical features in the treatment of different ethnic groups. Melissano et al¹⁸ reviewed published data on AAK visualization by MRA or CT angiography throughout the English-based literature and identified a trend for homogeneous outcome, regardless of the technique. The AAK was recognized in 466 out of 555 scans (83.96%). In 384 (83.3%) cases, the AAK originated from a left intercostal artery, and in 77 (16.7%) cases, it originated from a right intercostal artery. Our evaluation showed that MCTA is effective for visualizing the AAK, which was identified in 71 patients (82.5%). Consistent with previous studies, we found that the AAK originated from the left side of the body in 65 patients (91.5%) and from the right side in 6 patients (8.5%). In addition, intra- and interobserver agreement for AAK evaluation using MCTA were perfect ($\kappa = 1.0$).

Another possible concern, the differentiation between the AAK and the anterior radiculomedullary vein, is important, as misinterpretation of these two vessels can lead to critical surgical complications.¹⁸ The anterior radiculomedullary vein is often similar in shape and size to AAK, and both

may follow a similar path. To avoid this misinterpretation, we followed a strict injection and scanning protocol that started 7 seconds after the contrast medium reached 180 HU on ROI. Thus, we agree with Utsunomiya et al¹⁹ that an injection protocol with a high iodine concentration and a high flow rate is adequate for AAK identification. In addition, the anterior radiculomedullary vein usually shows a tortuous course, which may help the distinction between vein and artery.

Some limitations of our study are worth mentioning. First, this is a retrospective evaluation. The second limitation is related to the fact that the patients underwent MCTA for coronary artery disease investigation, and AAK may be located outside the study area. The most proximal and distal levels examined were T4 and L1, respectively.

Conclusions

Our results for AAK identification using MCTA were consistent with the literature. Multidetector computed tomography angiography should be considered an option for AAK identification. In addition, the AAK distribution in Latin American patients was similar to that of other populations, that is, its most common origin is at the left side, between the T9 and T12 levels.

Conflict of Interests

The authors have no conflict of interests to declare.

Acknowledgments

We are grateful to the team from Instituto de Radiologia Presidente Prudente for their assistance with the patients.

References

- Kieffer E, Fukui S, Chiras J, Koskas F, Bahnini A, Cormier E. Spinal cord arteriography: a safe adjunct before descending thoracic or thoracoabdominal aortic aneurysmectomy. *J Vasc Surg* 2002;35(02):262–268
- Schepens M, Dossche K, Morshuis W, et al. Introduction of adjuncts and their influence on changing results in 402 consecutive thoracoabdominal aortic aneurysm repairs. *Eur J Cardiothorac Surg* 2004;25(05):701–707
- Puertas EB, Chagas JC, Oliveira CA, Wajchenberg M, Santos FP, Oliveira VM. Complicações neurológicas no tratamento da escoliose idiopática com instrumentação e artrodese por via posterior. *Acta Ortop Bras* 1998;6(04):168–172
- Adamkiewicz A. Die blutgefäße des menschlichen rückenmarkes. I theil, Sitzungsberichte der Kaiserlichen Akademie der Wissenschaften Mathematisch-Naturwissenschaftliche. Classe 1881; 84:469–502
- Alleyne CH Jr, Cawley CM, Shengelaia GG, Barrow DL. Microsurgical anatomy of the artery of Adamkiewicz and its segmental artery. *J Neurosurg* 1998;89(05):791–795
- Standring S. *Gray's anatomy: the anatomical basis of clinical practice*. 40th ed. Edinburgh: Churchill Livingstone; 2008
- Heinemann MK, Brassel F, Herzog T, Dresler C, Becker H, Borst HG. The role of spinal angiography in operations on the thoracic aorta: myth or reality? *Ann Thorac Surg* 1998;65(02):346–351
- Takase K, Sawamura Y, Igarashi K, et al. Demonstration of the artery of Adamkiewicz at multi-detector row helical CT. *Radio-logy* 2002;223(01):39–45

- 9 Kudo K, Terae S, Asano T, et al. Anterior spinal artery and artery of Adamkiewicz detected by using multi-detector row CT. *AJNR Am J Neuroradiol* 2003;24(01):13–17
- 10 Yoshioka K, Niinuma H, Ohira A, et al. MR angiography and CT angiography of the artery of Adamkiewicz: noninvasive preoperative assessment of thoracoabdominal aortic aneurysm. *Radiographics* 2003;23(05):1215–1225
- 11 Nakayama Y, Awai K, Yanaga Y, et al. Optimal contrast medium injection protocols for the depiction of the Adamkiewicz artery using 64-detector CT angiography. *Clin Radiol* 2008;63(08):880–887
- 12 Uotani K, Yamada N, Kono AK, et al. Preoperative visualization of the artery of Adamkiewicz by intra-arterial CT angiography. *AJNR Am J Neuroradiol* 2008;29(02):314–318
- 13 Fanous AA, Lipinski LJ, Krishna C, et al. The Impact of Preoperative Angiographic Identification of the Artery of Adamkiewicz on Surgical Decision Making in Patients Undergoing Thoracolumbar Corpectomy. *Spine* 2015;40(15):1194–1199
- 14 Nijenhuis RJ, Jacobs MJ, Jaspers K, et al. Comparison of magnetic resonance with computed tomography angiography for preoperative localization of the Adamkiewicz artery in thoracoabdominal aortic aneurysm patients. *J Vasc Surg* 2007;45(04):677–685
- 15 Awai K, Hatcho A, Nakayama Y, et al. Simulation of aortic peak enhancement on MDCT using a contrast material flow phantom: feasibility study. *AJR Am J Roentgenol* 2006;186(02):379–385
- 16 Fleischmann D, Rubin GD, Bankier AA, Hittmair K. Improved uniformity of aortic enhancement with customized contrast medium injection protocols at CT angiography. *Radiology* 2000;214(02):363–371
- 17 Yoshioka K, Niinuma H, Ehara S, Nakajima T, Nakamura M, Kawazoe K. MR angiography and CT angiography of the artery of Adamkiewicz: state of the art. *Radiographics* 2006;26(Suppl 1):S63–S73
- 18 Melissano G, Bertoglio L, Civelli V, et al. Demonstration of the Adamkiewicz artery by multidetector computed tomography angiography analysed with the open-source software OsiriX. *Eur J Vasc Endovasc Surg* 2009;37(04):395–400
- 19 Utsunomiya D, Yamashita Y, Okumura S, Urata J. Demonstration of the Adamkiewicz artery in patients with descending or thoracoabdominal aortic aneurysm: optimization of contrast-medium application for 64-detector-row CT angiography. *Eur Radiol* 2008;18(11):2684–2690