

Evaluation of the Treatment of Patients Subjected to Osteogenesis Induced by Tibia Bone Distraction*

Avaliação do tratamento de pacientes submetidos a osteogênese por distração na tíbia

Henrique Carvalho de Resende¹ Diogo de Vasconcelos Sabido Gomes²
Gabriel Milhomem da Silva Mota² 

¹ Núcleo de Ortopedia e Traumatologia, Lourdes, Belo Horizonte, MG, Brazil
² Hospital Maria Amélia Lins (HMAL), Belo Horizonte, MG, Brazil

Address for correspondence Gabriel Milhomem da Silva Mota, Hospital Maria Amélia Lins (HMAL), Rua dos Otoni, 772, Santa Efigênia, Belo Horizonte, MG 30150-270, Brasil
(e-mail: gabrielmsmota@hotmail.com).

Rev Bras Ortop 2020;55(1):75–81.

Abstract

Objectives To evaluate the management of tibial fractures resulting in bone loss (traumatic or infection-related) and the complications occurring during treatment with external fixator and immediately after apparatus removal.

Methods Forty patients were selected from 2010 to 2017. The mean age of the patients was 33.02 years; 34 subjects were male and 6 were female. All patients had tibial bone regeneration, suffered trauma (mainly related to motorcycle accident) and were followed-up at an outpatient facility.

Results Proximal tibial bones of up to 17 cm in length and distal tibial bones of up to 14 cm in length were obtained. The largest trifocal transport had the same length as the regenerated bone tissues, which was 14.5 cm. Regarding complications, 29 (72.5%) patients had infections in the pin and wire paths. There were 9 (22.5%) cases of de novo fracture, 6 of which were managed with the implantation of a new circular fixator, and 2 cases of infection of the regenerated bone. On average, patients were subjected to 4.72 procedures (ranging from 2–12), had the fixator for 20.75 months (ranging from 7–55 months), and stayed at the hospital for 53.7 days (ranging from 5–183 days), mainly because of soft-tissue complications, intravenous antibacterial therapy, and even social issues. Two (5%) patients presented symptomatic gonarthrosis, and two other patients had symptomatic ankle arthritis. Three of the patients showed lower limb discrepancy of 3.0, 3.7, and 5.0 cm.

Conclusion Despite not being widely available, the Ilizarov method is useful for solving the majority of tibial bone losses, regardless of their etiology.

Keywords

- ▶ bone infection
- ▶ bone regeneration
- ▶ osteogenesis
- ▶ bone distraction
- ▶ Ilizarov technique
- ▶ tibia

Resumo

Objetivo Avaliar o tratamento das fraturas de tíbia que evoluíram com perda óssea (traumática ou secundária a infecção) e as complicações ocorridas durante o tratamento com fixador externo e no período imediatamente após sua retirada.

* Work performed at Hospital Maria Amélia Lins (HMAL), Belo Horizonte, MG, Brazil.

Palavras-chave

- ▶ infecção óssea
- ▶ regeneração óssea
- ▶ osteogênese
- ▶ distração óssea
- ▶ técnica de Ilizarov
- ▶ tibia

Métodos Foram selecionados 40 pacientes tratados entre 2010 e 2017, com a idade média de 33,02 anos, sendo 34 do sexo masculino e 6 do sexo feminino. Todos os pacientes portavam regenerado ósseo da tibia, foram vítimas de trauma (sobretudo motociclístico), e estavam em seguimento ambulatorial.

Resultados Foram obtidos regenerados ósseos da tibia proximal de até 17 cm e da tibia distal de 14 cm. O maior transporte trifocal teve a soma do tamanho dos tecidos dos ossos regenerados, medindo 14,5 cm. Como complicações, 29 (72,5%) pacientes tiveram infecção no trajeto dos pinos e fios. Houve 9 (22,5%) casos de refratura, sendo 6 deles tratadas com novo fixador circular, e 2 infecções no osso regenerado. Os pacientes foram submetidos a uma média de 4,72 procedimentos cirúrgicos (2–12), portaram fixador por 20,75 meses (7–55 m.) e permaneceram internados por 53,7 dias (5–183) devido principalmente a complicações de partes moles, a antibioticoterapia intravenosa, ou até mesmo a questões sociais. Dois (5%) pacientes apresentaram gonartrose sintomática e outros 2 artrite sintomática do tornozelo. Três apresentaram discrepância de membros inferiores de 3,0; 3,7; e 5,0 cm.

Conclusão Apesar de não ser um método de tratamento amplamente disponível, o método de Ilizarov é útil para solucionar a maioria das falhas ósseas da tibia, independente da sua etiologia.

Introduction

The Ilizarov technique is highly successful in bone failures of any etiology.¹ This technique allows the concurrent treatment of pseudarthrosis, major bone defects, shortening, deformities and infection,¹⁻³ without some of the limitations imposed by other methods, such as those developed by Papineau^{4,5} and Masquelet.⁶

The production of a high-quality regenerated bone is critical, and a subperiosteal corticotomy to protect osteogenetic elements and targeted to neovasculogenesis and consequent bone neoformation has a well-established role in the literature.^{1,7,8} Distraction osteogenesis significantly increases blood circulation in the limb,⁸⁻¹⁰ providing a suitable environment for the resolution of infectious conditions, wound closure, and bone healing.

Bone resection in infected pseudarthrosis must be as aggressive as possible, with oncologic-like excision of the entire affected bone segment so that treatment can be successful and with no complications or relapses.^{1,3,9,10} The remaining segment must present active bleeding, which is an important sign of viability.⁸

Bone transport and lengthening processes have an expected complication rate, including infection of the bone regenerate, lack of consolidation at the docking point, absence of bone formation in the regenerated segment, early corticotomy consolidation, fractures, and vascular lesions.⁹ Other complications are more directly related to the early trauma, such as secondary arthritis of adjacent joints.¹¹

The present paper aims to report and evaluate epidemiological aspects, treatment, and complications of tibial fractures requiring bone regenerates produced using the Ilizarov technique.

Materials and Methods

This is a retrospective study approved by our institutional ethics committee under the Certificate of Ethical Presentation and Appreciation (CAAE, in the Portuguese acronym) number 78498817.1.0000.5119 and opinion number 2.322.439. This study included 40 patients who underwent a specialized medical consultation between December 17, 2016 and June 17, 2017; all patients received a steel Ilizarov apparatus for circular external fixation. The study population consisted only of individuals submitted to tibial lengthening or transport, totaling 40 patients. The previous removal of the external fixator was one of the inclusion criteria. Our entire population was composed by trauma victims.

The technique used was segment stabilization associated with bone lengthening or bifocal or trifocal transport, as required by each case. Trifocal transport has the advantage of providing bone neoformation from two foci, reducing the total treatment time.¹² Corticotomy was performed with a Gigli saw or predrilling complemented by chiseling. The rate of regenerate production was 0.5 to 1 mm/day, depending on the quality of the synthesized bone. Docking of the main fragments was performed in a surgical block after edges revitalization and active bleeding visualization.³ Next, after the lengthening process was completed, the patients underwent apparatus dynamization with loosening of one or two from four threaded bars. The fixator removal was based on radiographic images showing bone consolidation in at least three views. After this stage, the patients received a polypropylene brace, which was used until the end of the bone remodeling phase.

Three patients were excluded due to lack of medical records. On the other hand, one patient was included in the study due to the relevance of her case, even though her fixator was removed after the data collection period for the present study.

Results

The predominant trauma mechanism was motorcycle accident, as seen in 26 (65%) patients. In the case of 9 (22.5%) patients, the collision involved a car, while 3 other patients (7.5%) collided with a bus or another motorcycle; 2 patients (5%) were involved in a single motorcycle crash. There was 1 (2.5%) case of collision with a truck and 8 (20%) unspecified motorcycle accidents. Six patients (15%) were run over, including 3 (7.5%) by a truck and one who fell off a bicycle. Another patient (2.5%) was run over by a car and 2 (5%) run overs were unspecified. Another 4 (10%) individuals suffered falls from own height, and 4 (10%) were victims of unspecified motor vehicle accidents.

Males were the most affected group, with 34 (85%) individuals. The average age at the time of trauma was 33.02 years, with a median value of 32.5 years (ranging from 12 to 51 years). The average age of the 6 (15%) females was 27.5 years, with a median value of 24.5 (ranging from 9–52 years). The most affected side was the right side (21 cases or 52.5%).

Primary lesions included tibial shaft fractures in 34 (85%) cases, 2 (5%) tibial plateau fractures, and 4 (10%) tibial pilon fractures. In the shaft subgroup, 10 (25%) cases were urgently classified as AO42C3, and 2 (5%) as AO42C2. There was 1 (2.5%) case of each of the following classifications: AO42B3, AO42B2, AO42B1, and AO42A2. Only two fractures were known to be closed. Open fractures were classified by the Gustilo system; 1 (2.5%) was type G2, 9 (22.5%) were G3A, 5 (12.5%) were G3B, and 2 (5%) were G3C. Two patients (5%) presented local neurological deficit. Twenty (50%) individuals underwent debridement, flap rotation, or skin grafting by the plastic surgery team before external fixation assembly.

Regarding associated injuries, there were 11 (27.5%) cases of floating knees, including 7 (17.5%) due to femoral shaft fractures, 1 due to medial condyle involvement, 1 due to distal femur fracture (AO33C3), 1 distal femur epiphysiolyis (Salter Harris II) and one unspecified fracture in the distal femur of a child. There were three cases of knee dislocation and one isolated anterior cruciate ligament (ACL) injury. There was 1 (2.5%) case of each of the following: toe, cuboid, medial malleolus and calcaneal fractures, and 5th toe traumatic amputation. There were 2 (5%) cases of bilateral tibial fracture, 1 of them in a floating knee. Two patients (5%) presented lumbar spine fracture, 1 (2.5%) had an occipital-cervical dislocation with occipital condyle fracture, and another suffered an unspecified spinal fracture. Associated pelvic lesions were observed in 1 (2.5%) subject, who presented a pubic branch fracture. On the other hand, upper limb injuries were more prevalent, with 3 (7.5%) cases of phalanx fracture and 1 (2.5%) case of each of the following: humeral shaft, distal radius, 2nd metacarpal and 5th metacarpal fractures, mallet finger, scaphoid fracture, and brachial plexus injury.

The patients were allocated in 2 subgroups; the 1st subgroup consisted of patients who underwent lengthening, with 18 limbs, while the 2nd subgroup was comprised by the remaining 22 limbs submitted to bone transport.

Lengthening

Lengthening was performed due to infected pseudarthrosis in 11 (61.1%) individuals, and posttraumatic acute bone failure in 3 (16.6%) patients. In 4 other subjects (22.2%), lengthening was performed for shortening correction and generated during deformity correction after talus resection and tibial bone debridement and resection. In one case, the cause for shortening was not reported in the medical record.

Fifteen (83.3%) patients underwent corticotomy in the tibial proximal metaphyseal region, and bone regenerate production was proximal to the docking point. Its average size was 5.46 cm, with a median value of 5.5 cm (ranging from 1.8–9 cm). Two (11.1%) subjects underwent corticotomy in the tibial distal metaphysis, distal to the docking point. In these cases, the bone regenerate measured 3.5 and 7.5 cm. There was one case of trifocal tandem transport, with both corticotomies proximal to the docking point. The bone regenerates produced measured 3.5 cm and 4.5 cm from proximal to distal. Twelve (66.6%) patients were submitted to a fibulectomy.

During bone distraction, the bone regenerate from two patients had to be accorded due to poor tissue quality. In one patient, lengthening was paused for a while and then resumed, and, in another subject, since lengthening occurred at a much higher rate than recommended, a 15-mm reverse gear was required.

One bone regenerate was curved, whereas another one was flexed; the latter was submitted to surgical correction. There was also the case of a patient who manipulated the fixation apparatus on his own, impairing limb alignment as a whole and requiring a new surgery.

Eleven (61.1%) subjects had infection at the wire or pin paths at some point, and two (11.1%) patients presented bone sequestration. The bone spicula was surgically removed from the subcutaneous tissue, and a new surgery was required due to bone exposure. In one patient, foot component wires were replaced due to pain, and, in another patient, the wire was removed due to the formation of an abscess in its path. One thigh abscess and one ankle septic arthritis were submitted to drainage.

Four (22.2%) subjects suffered fractures, but only one case required a new circular fixator due to ankle arthrodesis refraction. Another patient had a fracture at a pseudarthrosis focus and was submitted to the conservative treatment with brace use and load restriction. Another subject presented an open fracture and underwent an urgent debridement and monoplane fixation, which eventually became the definitive treatment. Finally, there was a case of bone regenerate focus refraction, which was conservatively treated.

After fixator removal, one patient presented severe gonarthrosis, 2nd had symptomatic ankle osteoarthritis, two had knee stiffness, one presented claw fingers, one had a residual shortening of 5 cm and another presented a residual 15° flexion.

In total, 65 surgical procedures were performed in 18 patients, ranging from 2 to 7, with mean and median values of 3.61 and 3 surgeries, respectively. The patients were

hospitalized for 637 days, ranging from 10 to 79 days, for an average period 35.38 days and a median time of 31 days. Total time of external fixator use was 280 complete months, ranging from 7 to 37 months, with a mean time of 15.55 months and a median period of 12 months.

Transport

From the 22 patients undergoing bone transport, 12 (54.5%) cases were due to bone failure after resection of the infected pseudarthrosis focus, 9 (40.9%) cases were caused for post-traumatic acute bone failure (►Figure 1) and 1 (4.5%) case occurred for an unreported reason.

Eleven (50%) patients underwent a corticotomy in the tibial proximal metaphysis region (►Figure 2). The bone regenerate produced had an average size of 8.53 cm, ranging from 4 and 17 cm (►Figure 3), with a median size of 8 cm. There was 1 (4.5%) case of corticotomy distal to the docking point, which resulted in a 14-cm regenerate bone. In 4 (18.1%) cases, there were 2 corticotomies, 1 proximal and 1 distal to the focus of compression (►Table 1). The average sizes of the proximal and distal regenerate bones were 5 cm and 5.6 cm, respectively. Four (18.1%) patients underwent trifocal tandem transport, in which both regenerate bones were proximal to the docking point and had, on average, 3.8 cm and 3.67 cm from proximal to distal. Finally, there were 2 (9%) cases submitted to sequential trifocal transport, but with the compression focus proximal to the lengthening foci, measuring 2.5 and 3.8 cm (proximal regenerate bone) and 12 and 3 cm (distal regenerate bone), respectively. Fifteen (68.1%) cases underwent fibulectomy.

There were two cases of infection in the regeneration focus. In one of them, we tried to surgically terminate the infection, and a cement spacer was maintained in a failed attempt to perform the Masquelet technique. In the other one, antibiotic therapy was sustained for a long period and debridement was performed; the final discrepancy of 3 cm was accepted, and lengthening was terminated.

During the bone neoformation phase, 4 (18.1%) cases presented early corticotomy consolidation, and the procedure was redone. There was a case of transport pause due to poor regenerate production, and 2 cases of reverse gear, including an unspecified one and the other with 5 mm.

Eighteen (81%) cases presented infection in the wire or pin paths at some point during the treatment, and 4 (18.1%) cases of bone sequestration were reported. In 2 cases, the patients were taken to the operating room for removal of the exposed bone spicula, 3 (13.6%) for debridement, and 2 (9%) for skin grafting due to lack of cutaneous coverage at the docking point. There was also one case of foot component assembly due to a proprioceptive deficit recurrence. An ankle deformity in the varus was also observed during treatment and corrected at the outpatient facility.

Five patients (22.7%) presented refraction. Three (13.6%) of these cases occurred at the tibial docking points, including 2 during physical therapy. The other 2 (9%) cases occurred at the femur, 1 in the bone regenerate and the other on the focus of deformity correction. Unlike the group submitted to

lengthening, all these cases required a new circular external fixator. There was also a case of distal fibular fracture with no history of trauma, which was treated conservatively.

After fixator removal, one patient presented severe symptomatic gonarthrosis and another one had symptomatic ankle osteoarthritis. There were one tibiotarsal arthrodesis and one knee arthrodesis during treatment. Two patients presented final discrepancies, measuring 3 cm and 3.7 cm. There was another case of unspecified discrepancy, but with future indication for lengthening. There was also a case of deformity in the recurvatum and varus, and another unspecified one.

In total, 124 surgical procedures were performed in 22 patients, ranging from 3 to 12, with a mean value of 5.63 surgeries and a median value of 5 surgeries. The patients were hospitalized for 1,511 days, ranging from 5 to 183 days, with an average period of 68.68 days and median period of 61.5 days. The total time of external fixator use was 550 complete months, ranging from 8 to 55 months, with a mean time of 25 months and a median time of 25.5 months.

It is worth mentioning that in only one case there is no record of pseudarthrosis or docking focus review; this is the case of transport for uninformed reason.

Discussion

Emergency care is crucial for therapeutic success. Removing all macroscopic debris and instituting an aggressive antibiotic therapy for the appropriate period reduce the infection and pseudarthrosis rates.¹³ In addition, the referral hospitals network seems incapable of dealing with all cases requiring fixation; this inability increases the time between trauma and osteosynthesis, which causes distress and suffering to the patient and impairs treatment.

The present study showed that the Ilizarov apparatus assembly for monofocal lengthening is effective in the treatment of infections and bone defects of limited size; a similar finding is reported by Iacobellis et al.⁹ The shorter use of the external fixator, as well as the lower number of surgeries per patient and lower complication rate made us choose this modality whenever allowed by limb conditions.

Bone transport, although efficient, is difficult to perform because, in addition to the greater number of complications shown, it depends even more on the intellectual capacity and cooperation of the patient.³

A trained, multiprofessional network able to assist case managements is critical to reduce or limit the occurrence of complications inherent to the technique. Two refraction cases occurred during physical therapy, constituting a completely preventable complication.

Large regenerates were produced in both the proximal and distal tibia, with only one case of tibial regenerate refraction, which was 2.5 cm in size. As such, we believe that, more important than the size of the regenerate itself, fractures result from not following the guidelines after apparatus removal and not using the brace.

On the other hand, most of the fractures occurred at the docking/pseudarthrosis point. As such, we have to think about the benefits of delaying the apparatus removal a little further.

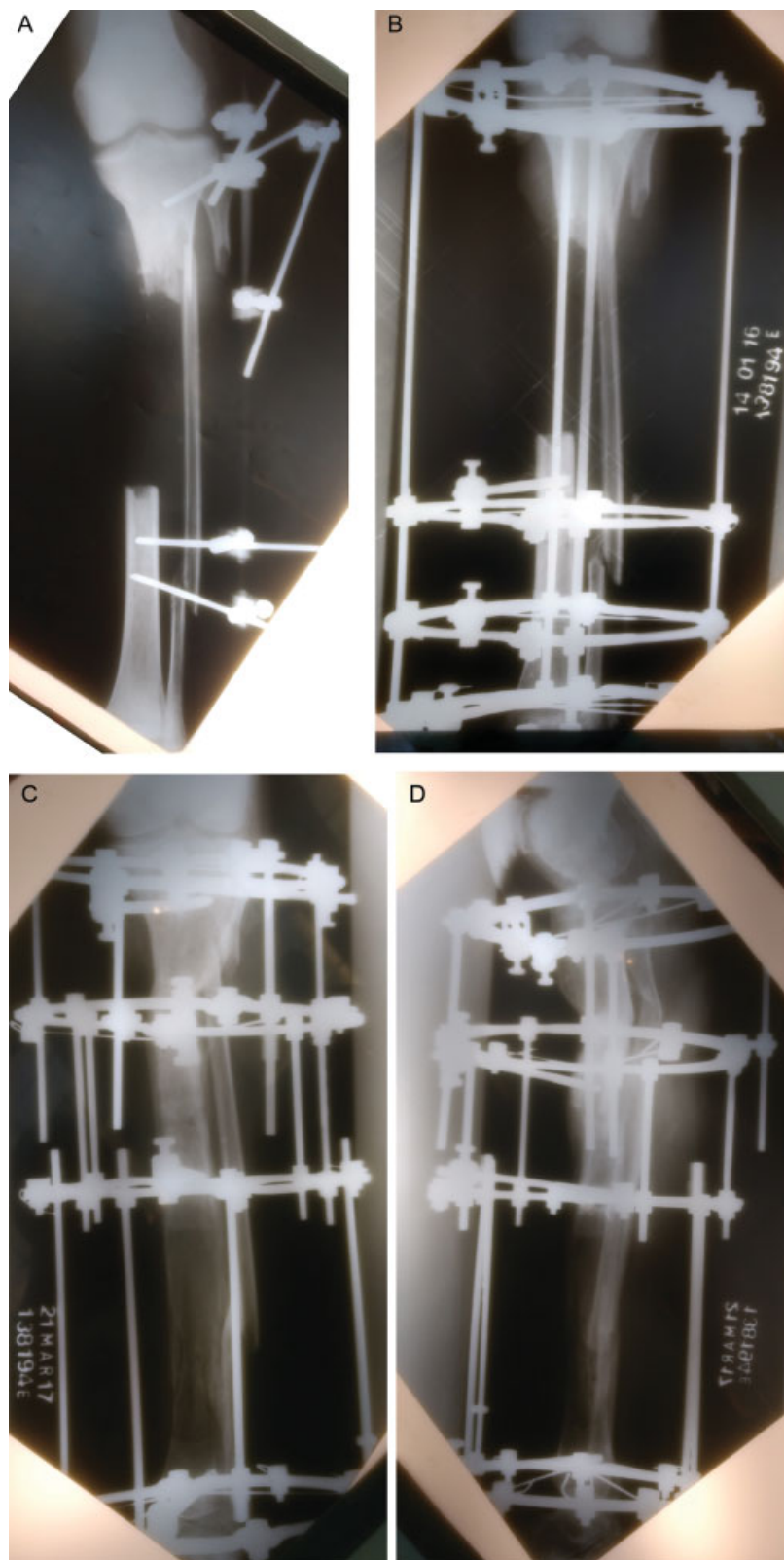


Fig. 1 Patient number 9, male, 30 years old, submitted to retrograde, tandem transport due to acute posttraumatic bone failure (A). Apparatus assembly (B). A 12-cm distal regenerate and 2.5-cm shaft regenerate were obtained. The axes were restored at both anteroposterior (C) and lateral (D) views.

Conclusion

Our data clearly shows that most accidents involve motorcycles and male patients from the economically population, generat-

ing great personal, social, and social security damages. These data help us guide public policies for accidents prevention.

Malnourished patients, smokers, those with no family support or with low intellectual level are a risk factor for

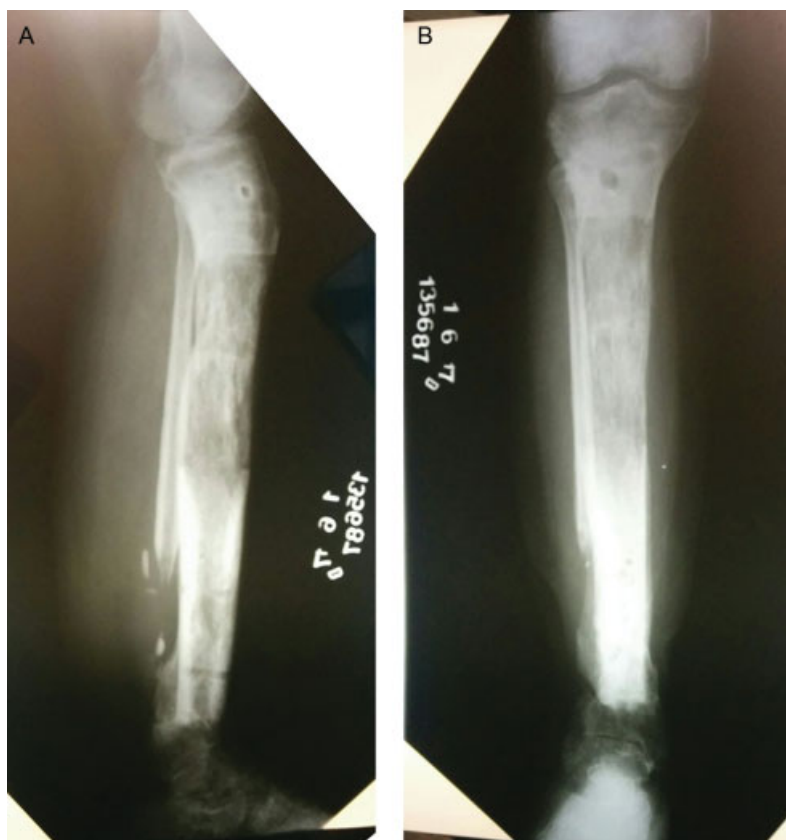

Fig. 2 Outcome from patient TMFM, 52 years-old, who presented a large area of unviable bone due to an infected pseudarthrosis. Anterograde bifocal transport was performed. The final bone regenerate measured 11.3 cm.

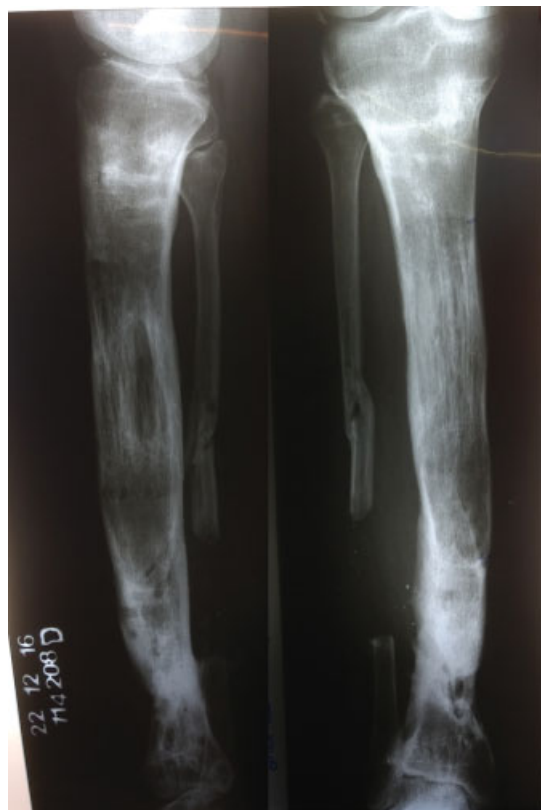

Fig. 3 Outcome from patient FNB, 34 years-old, whose regenerated proximal tibia measured 17 cm after acute posttraumatic bone failure.

Table 1 Trifocal transport: size of the regenerate bone produced and position in relation to the tibial compression focus

Patient	Proximal focus	Intermediate focus	Distal focus
01	6.0 cm	compression	1.5 cm
02	3.0 cm	compression	4.5 cm
03	4.0 cm	compression	9.5 cm
04	7.0 cm	compression	7.0 cm
05	4.5 cm	1.2 cm	compression
06	2.5 cm	7.0 cm	compression
07	3.2 cm	4.0 cm	compression
08	5.0 cm	2.5 cm	compression
09	compression	2.5 cm	12.0 cm
10	compression	3.8 cm	3.0 cm

treatment failure due to the need for multiple surgeries, prolonged use of medication and apparatus corrections. Amputation might be chosen as a treatment in non-collaborative patients or in those who prefer it as a way to shorten the long treatment and start rehabilitation earlier.

Finally, the quality of the medical records is poor, which hindered the information analysis and probably affected negatively the treatment of patients.

Conflict of Interest

The authors have no conflict of interests to declare.

References

- 1 Silva WN, Martins LH, Coutinho EC. Transporte ósseo da tibia com o método de Ilizarov nos casos de pseudartrose com falha óssea. *Rev Bras Ortop* 1998;33(10):805–810
- 2 Tuffi GJ, Franco Filho N, Sbruzzi FC. Tratamento das infecções ósseas pelo método de Ilizarov usando o transporte ósseo e/ou a osteossíntese monofocal. *Rev Bras Ortop* 1997;32(08):583–590
- 3 Catagni MA, Guerreschi F, Lovisetti L, Camagni M. Ricostruzioni diafisarie con apparato di Ilizarov. *GIOT* 2005;31 (Suppl 2):464–469
- 4 Papineau LJ, Alfageme A, Dalcourt JP, Pilon L. Chronic osteomyelitis: open excision and grafting after saucerization (author's transl). *Int Orthop* 1979;3(03):165–176
- 5 Neves J, Carvalho M, Araújo A, et al. Método de Papineau uma opção válida no tratamento da osteomielite e/ou pseudartrose infectada. *Rev Port Ortop Traumatol* 2014;22(04):431–438
- 6 Masquelet AC. Muscle reconstruction in reconstructive surgery: soft tissue repair and long bone reconstruction. *Langenbecks Arch Surg* 2003;388(05):344–346
- 7 Durigan A Junior, Batista LC. Corticotomia. *Rev Bras Ortop* 1997; 32(08):623–629
- 8 Li R, Saleh M, Yang L, Coulton L. Radiographic classification of osteogenesis during bone distraction. *J Orthop Res* 2006;24(03): 339–347
- 9 Iacobellis C, Berizzi A, Aldegheri R. Bone transport using the Ilizarov method: a review of complications in 100 consecutive cases. *Strateg Trauma Limb Reconstr* 2010;5(01):17–22
- 10 Mercadante MT, Santin RAL. Tratamento da pseudartrose da tibia com falha óssea pelo método de Ilizarov. *Rev Bras Ortop* 1997;32 (08):591–599
- 11 Mercadante MT, Santin RAL, Ferreira RC. Análise crítica das técnicas cirúrgicas para artrodese do tornozelo. *Rev Bras Ortop* 2000;35(06):187–193
- 12 Catagni MA, Felici JVN. Alongamento de dois níveis e o método de Ilizarov (trifocal) no tratamento da pseudartrose tibial com perda óssea. *Rev Bras Ortop* 1996;31(08):613–619
- 13 Patzakis MJ, Wilkins J. Factors influencing infection rate in open fracture wounds. *Clin Orthop Relat Res* 1989;(243):36–40