


# Morphometric Study of the Atlas\*

## *Estudo morfológico do atlas*

Narcelio Mendes Ferreira Filho<sup>1</sup>  Ricardo Arantes<sup>1</sup> Anderson Luis do Nascimento<sup>1</sup>  
Carlos Fernando Pereira da Silva Herrero<sup>1</sup>

<sup>1</sup> Department of Biomechanics, Medicine and Locomotive System Rehabilitation, Hospital das Clínicas, Faculdade de Medicina de Ribeirão Preto, Universidade de São Paulo, Ribeirão Preto, SP, Brazil

Rev Bras Ortop 2020;55(1):62–69.

**Address for correspondence** Narcelio Mendes Ferreira Filho, MD, Departamento de Biomecânica, Medicina e Reabilitação do Aparelho Locomotor do Hospital das Clínicas da Faculdade de Medicina de Ribeirão Preto da Universidade de São Paulo, Av. dos Bandeirantes 3900, 11° andar, Ribeirão Preto, SP, 14048-900, Brazil (e-mail: narceliomendes@gmail.com).

### Abstract

**Objective** To determine the anatomical parameters of the atlas (C1) in a sample of the Brazilian population and compare them with the results already presented in the literature for other populations and, thus, to identify and change the indications of implants used in the treatment of the upper cervical spine.

**Methods** We performed a retrospective observational study of a prospective database, including 100 patients seen between January 2012 and December 2013. We used axial and sagittal sections of computed tomography (CT) scans. The parameters studied were; axial: distance from posterior tubercle to the screw entry point (DPT\_EP), safety angle of the axial screw (SA\_AS), ideal axial screw length (\_ASL) and distance of the spinal canal from the transverse foramen (DSC\_TF); Sagittal: ideal sagittal screw length (\_SSL), safety angle of the sagittal screw (SA\_SS) and posterior arch thickness (\_PAT). All of the parameters were divided according to age, gender, and left and right sides.

**Results** The minimum mean point of entry ranged from 20 mm to 22.7 mm. The average security zone ranged from 18.09° to 23.68°. The mean posterior arch thickness ranged from 7.21 mm to 8.95 mm. The lowest averages were found in females. Using an original and reproducible technique of CT evaluation.

**Conclusion** The anatomical parameters of the atlas found in the sample of the studied population were similar to those previously presented in the literature. However, differences between the sexes were observed.

### Keywords

- ▶ cervical spine
- ▶ computed tomography
- ▶ atlas
- ▶ anatomy

### Resumo

**Objetivo** Determinar os parâmetros anatômicos do atlas (C1) em uma amostra da população brasileira, compará-los aos resultados já apresentados na literatura para outras populações e, assim, identificar e alterar as indicações dos implantes utilizados no tratamento das afecções da coluna cervical alta.

**Métodos** Foi realizado um estudo observacional retrospectivo de um banco de dados prospectivo, incluindo 100 pacientes atendidos entre janeiro de 2012 a dezembro de 2013. Foram utilizados cortes axiais e sagitais de tomografias computadorizadas (TCs). Os parâmetros estudados foram; axial: ponto de entrada do parafuso (DTPPE), ângulo

\* Study developed at the Hospital das Clínicas de Ribeirão Preto, Universidade de São Paulo, Ribeirão Preto, SP, Brazil.

de segurança (ADSPA), tamanho ideal do parafuso (TPA) e tamanho da massa lateral entre os forames vertebral e transverso (DCVFT); sagital: tamanho ideal do parafuso (TPS), ângulo de segurança (ADSPS) e espessura do arco posterior (EAP). Todos os parâmetros foram divididos de acordo com a idade, gênero e lado esquerdo e direito.

**Resultados** A média mínima do ponto de entrada variou de 20 mm a 22,7 mm. A zona de segurança média variou de 18,09° a 23,68°. A espessura média do arco posterior variou entre 7,21 mm e 8,95 mm. As menores médias foram encontradas no sexo feminino. Por meio de uma técnica original e reprodutível de avaliação de TC.

**Conclusão** Os parâmetros anatômicos do atlas encontrados na amostra da população estudada foram semelhantes aos apresentados previamente na literatura. No entanto, foram observadas diferenças entre os sexos.

#### Palavras-chave

- ▶ coluna vertebral
- ▶ tomografia computadorizada
- ▶ atlas
- ▶ anatomia

## Introduction

Several diseases can affect the spine. Among them, the most prevalent are degenerative diseases, traumatic injuries, infections and neoplasms. Due to the variation in the clinical presentation of the diseases, treatment modalities may vary from rest and orthosis immobilization up to surgical fixation and arthrodesis of the vertebral segments. Knowledge of the morphology and of the anatomy of the vertebrae, of their adjacent structures, and of their variations are essential for the safe conduct of spinal surgical procedures.<sup>1-3</sup> Among the surgical procedures involved in the surgical treatment are fixation techniques, decompression of neural structures, and arthrodesis.

Several surgical techniques have been described to treat conditions affecting the occipitocervical transition region. The Gallie technique<sup>4</sup> was developed to stabilize the C1-C2 articulation. This posterior arthrodesis method provides flexural strength but offers little rotational stability and extension. Brooks et al<sup>5</sup> described the technique with double-looped wiring, which provided stability in both flexion and extension, but had low rotational stability. In 1987, Magerl et al<sup>6</sup> presented a more rigid method of fixation with the insertion of a C1-C2 transarticular screw. These screws provided greater rigidity, especially in rotation, and better maintenance of reduction than wiring fixation.<sup>6</sup> The technique described by Magerl has some limitations to its use: first, it is necessary a reduction > 50% of the atlanto-axial joint dislocation, and 11% of patients had some anatomical variation that prevented the passage of the screw through one of the joints.<sup>7</sup> In 1994, Goel et al<sup>8</sup> and, later, in 2001, Harms et al,<sup>9</sup> disclosed their technique in which screws were inserted into C1 lateral masses and into C2 pedicles. With the techniques of Magerl and Goel-Harms, the consolidation of arthrodesis reached rates of almost 100%, unlike the techniques of Galli and Brooks et al, in which about 15% of pseudoarthrosis were found.<sup>7,10</sup> For screw placement by C1 lateral mass, there is a high risk of injury of the venous plexus located in this region. Estimated blood loss ranges from 50 to 1,500 mL (average 540 mL), requiring multiple attempts of hemostatic tamponade.<sup>9</sup> In addition, postoperative dysesthesia due to displacement of the primary dorsal branch of C2 is common.<sup>11</sup> In 2003, Tan et al<sup>12</sup> described, evaluating an

Asian population, the possibility of screw insertion through the posterior arch of the atlas, reducing the risk of venous plexus injury and local dysesthesia. In 2006, Lee et al<sup>13</sup> reproduced that study in a North American population. We hypothesized that the morphometric parameters of the atlas of a Brazilian population would differ from those previously reported in the literature. The purpose of our study was to perform a detailed computed tomography (CT) evaluation of the atlas and to determine the interobserver reproducibility of the evaluation method employed.

## Materials and Methods

### Casuistry

This is an observational study of a prospective database that was approved by the Ethics Committee of our institution under the number 14224/2014. The study design was based on the evaluation of tomographic images of the cervical spine at the level of the first vertebra, known as atlas (C1). Retrospectively, we selected cervical tomographic images of 100 individuals (52 female and 48 male), which were obtained from patients treated at the Emergency Unit, from January 2012 to December 2013.

The exclusion criteria used in the present study were age < 18 years old, previous cervical spine surgery, presence of cervical spine diseases such as fractures, tumors, infections, ankylosing spondylitis, and familial hyperostotic disease (DISH). The inclusion criteria were age > 18 years old and absence of previous disease or surgery in the spine.

Imaging exams were performed using a Brilliance CT Big Bore 16-slice CT device (Philips Healthcare, Cleveland, OH, USA).

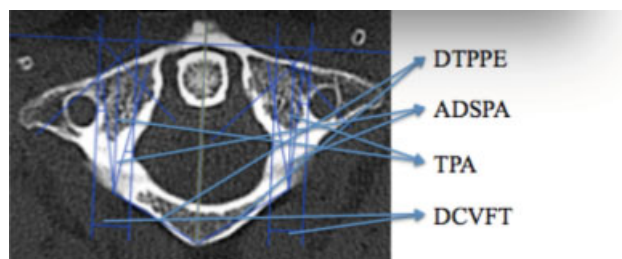
The reconstructions of the images obtained from the CT were performed using cuts with a 2 mm thickness for the axial plane, and 3 mm for the sagittal and coronal planes. The reading and reproduction of the images, as well as their reconstructions, were obtained through the OsiriX MD image program, version 7.0.2 (Pixmeo SARL, Bernex, Switzerland).

Two independent researchers conducted measurements of related parameters using the OsiriX MD image program, version 7.0.2, and investigator 2 evaluated the images of only 20 randomly selected patients (random.org).

The terminology list of all parameters that have been measured with their respective abbreviations and descriptions

**Chart 1** Parameters evaluated in the axial plane on CT images

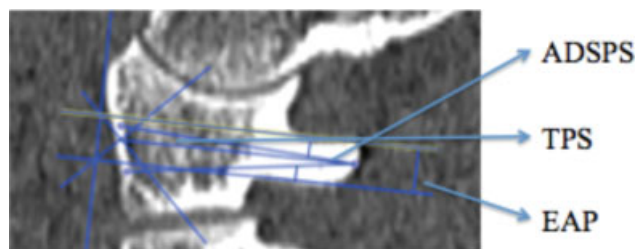
Acronym	Description
DPTLEP	Distance from the posterior tubercle to the left entry point
DPTREP	Distance from the posterior tubercle to the right entry point
SALAS	Safety angle of left axial screw
SARAS	Safety angle of right axial screw
LASL	Left axial screw length
RASL	Right axial screw length
DSCLTF	Distance from spinal canal to left transverse foramen
DSCRTF	Distance from spinal canal to right transverse foramen



**Fig. 1** Computed tomography axial section of the atlas demonstrating measurements of distance from posterior tubercle to the entry point (DPT\_EP), the safety angle of the screw (SA\_AS), screw length (\_ASL) and the distance from the spinal canal to the transverse foramen (DSC\_TF).

**Chart 2** Parameters evaluated in the sagittal plane on CT images

Acronym	Description
LSSL	Left sagittal screw length
RSSL	Right sagittal screw length
SALSS	Safety angle of the left sagittal screw
SARSS	Safety angle of the right sagittal screw
LPAT	Left posterior arch thickness
RPAT	Right posterior arch thickness



**Fig. 2** Sagittal computed tomography scan of the atlas demonstrating the measurements of the screw safety angle (SA\_SS), screw length (\_SSL) and the posterior arch thickness (\_PAT).

is summarized in **Charts 1** and **10**. The methodology used for carrying out the measurements is illustrated in **Figures 1** and **2** (figures obtained from the work itself). Linear parameters were measured in millimeters ( $\pm 1$  mm), and the angular parameters were measured and presented in degrees. Mean and standard deviation (SD) were calculated for all dimensions studied.

We started the evaluation of the images in the axial plane, and the first step was the identification of the C1 image, presenting the foramina and the transverse processes. We then drew a line joining the anterior to posterior tuberosity and called it the main line. From the main line, we placed 4 parallel lines, one at each end of the vertebral canal and one over the medial end of each transverse foramen, thus delimiting the boundaries of the lateral masses of C1. In the next step, we drew a line perpendicular to the previous lines. Then, for each lateral mass, we drew 2 lines at 45° to the main line at its intersection with the perpendicular line, forming an isosceles right triangle. Thus, we obtained the midpoint of the lateral mass on each side. We consider the projection of this point on the posterior arch of C1 the ideal entry point for the screw in the lateral mass of C1. From the ideal entry point, we drew on each side a line joining that point to the posterior atlas tuberosity. We named this distance from the posterior tubercle to the entry point of the screw (DPT\_EP). In the next step, we calculated the screw length (\_ASL)

measuring the distance between the ideal entry point of the screw and the anterior cortex of the lateral mass. After that, we bilaterally measured the distance between the parallel lines that delimit the spinal canal and the transverse foramina (DSC\_TF) and that represented the width of the lateral mass. Then, we calculated the safety angle for screw insertion. We took as a basis the screw of 3.5 mm, which is usually used in the cervical spine. For this purpose, we drew 4 lines of 1.75 mm each (half the diameter of a 3.5 mm screw) and we positioned it in the limits of the spinal canal and the transverse foramen, thus delimiting the security zone. We named the angle formed between the ideal entry point and the inner boundaries of the safety line the safety angle of the screw (SA\_AS).

In the first step in the sagittal plane, we drew a line that touched the posterior arch over the groove of the vertebral artery and, then, a line parallel to this was positioned at the bottom edge of the posterior arch. Like in the axial plane evaluation, we then drew a line perpendicular to the first two and, after that, two lines 45° to the previous lines positioned at the intersection. Thus, we obtained the midpoint of the posterior arch, which we considered the ideal entry point for the lateral mass screw. The next step involved simulating the placement of a 3.5mm screw, so we drew the two security lines emerging from the screw entry point in the posterior arch and located 1.75 mm from the top and bottom edge of the posterior arch in the groove for the vertebral artery. These lines form the safety angle of the screw (SA\_SS). We considered as the screw length (\_SSL) the measure between the posterior arch entry point and the anterior edge of the lateral mass. The distance between the parallel lines represented the posterior arch thickness (\_PAT).

**Table 1** Distance from the Posterior Tubercle to the Entry Point

Parameters	Male (n = 48)		Female (n = 52)	
	Mean ± SD	Variation	Mean ± SD	Variation
DPTLEP(mm)	21.86 ± 1.50	17.9–25.5	20.00 ± 1.40	16.6–22.6
DPTREP(mm)	22.70 ± 1.44	20–26.9	20.24 ± 1.34	17.7–22.7

Abbreviations: DPTLEP, distance from the posterior tubercle to the left entry point; DPTREP, distance from the posterior tubercle to the right entry point; SD, standard deviation.

### Statistical Analysis

A total of 200 lateral masses were evaluated. Means and SDs of linear and angular parameters were calculated for male and female patients separately (► **Table 1**). A total of 1,400 measurements were taken and employed to determine the difference of all dimensional and angular parameters between the genders at the same vertebral level. Means and SDs were calculated for the dimensions studied, and the values of the measurements were compared using the Student t test.

To test the normal distribution of the sample of our study, we employed the Shapiro-Wilk test; we evaluated the histogram format and compared the mean and median of all variables.

Interobserver reliability was estimated using the intraclass correlation coefficient (ICC) for tomographic measurements. A two-way mixed-effects model with consistency agreement was applied. Reliability was considered very poor for values between 0 and 0.2, weak for values between 0.21 and 0.4, moderate for values between 0.41 and 0.6, substantial or good for values between 0.61 and 0.8 and near perfect or very good for values between 0.81 and 1.0.<sup>14</sup> We used a significance level of 5%. The parameters were stored in a spreadsheet and studied through the STATA13 software (StataCorp, College Station, TX, USA).

## Results

Tomographic images from 100 patients were randomly selected, with a mean age of 44 ± 18 years old (range 18 to 85 years old), being 48 (48%) males and 52 (52%) females. The mean age among men was 43 ± 17 years old (range 18 to 83 years old), and among the women it was 46 ± 20 years old (range 21 to 85 years old). For each patient, measurements on the left and right sides were performed.

### Axial Parameters

#### Distance from Posterior Tubercle to the Entry Point

The mean DPT\_EP found in males was 21.86 ± 1.5 mm on the left and 22.7 ± 1.44 mm on the right side; and

20 ± 1.4 mm and 20.24 ± 1.34 mm, respectively, in females (► **Table 1**). It was possible to notice a greater distance found in male patients, on both the left and right sides, and this difference was statistically very significant ( $p < 0.0001$ ).

#### Safety Angle of the Axial Screw

The mean SA\_AS found in males was 23.68 ± 6.12° on the left and 24.0 ± 5.82° on the right; and 18.09 ± 5.46° on the left and 18.57 ± 5.34° on the right in females (► **Table 2**). A safety angle for passage of the larger screw was identified in male patients, on both left and right sides. This difference was statistically very significant ( $p < 0.0001$ ).

#### Axial Screw Length

The mean \_ASL found in males was 29.52 ± 2.95 mm on the left and 29.15 ± 2.9 mm on the right; and 27.81 ± 2.38 mm and 27.85 ± 2.5 mm, respectively, in females (► **Table 3**). We showed a statistical difference when comparing the 2 groups ( $p < 0.001$ ), being the highest \_ASL found in the male group.

#### Distance between Spinal Canal and Transverse Foramen

The mean DSC\_TF found in males was 9.00 ± 1.44 mm on the left and 9.22 ± 1.49 mm on the right. In the female group, the mean DSC\_TF found was 7.71 ± 1.23 mm on the left and 7.77 ± 1.13 mm on the right (► **Table 4**). When we compare the values found, we can notice a statistical difference between the male and female groups ( $p < 0.001$ ).

### Sagittal Parameters

#### Sagittal Screw Length

The mean \_SSL found in the male group was 30.27 ± 2.19 mm on the left and 29.51 ± 1.83 mm on the right, while the means found in the female group were 28.82 ± 1.86 and 28.16 ± 2.03 mm, respectively, on the left and on the right (► **Table 5**). Similarly, we noticed a higher \_SSL, statistically, in the male group. ( $p < 0.001$ ).

**Table 2** Safety Angle of Axial Screw

Parameters	Male (n = 48)		Female (n = 52)	
	Mean ± SD	Variation	Mean ± SD	Variation
SALAS (°)	23.68 ± 6.12	11.7–35.5	18.09 ± 5.46	5.18–31.5
SARAS (°)	24.00 ± 5.82	9.1–35.7	18.57 ± 5.34	5.27–29.7

Abbreviations: SALAS, safety angle of left axial screw; SARAS, safety angle of right axial screw; SD, standard deviation.

**Table 3** Axial Screw Length

Parameters	Male (n = 48)		Female (n = 52)	
	Mean ± SD	Variation	Mean ± SD	Variation
LASL (mm)	29.52 ± 2.95	24.9–46	27.81 ± 2.38	23.3–39.6
RASL (mm)	29.15 ± 2.90	25–46.2	27.85 ± 2.50	22.7–39.6

Abbreviations: LASL, left axial screw length; RASL, right axial screw length; SD, standard deviation.

**Table 4** Distance from Spinal Canal to Transverse Foramen

Parameters	Male (n = 48)		Female (n = 52)	
	Mean ± SD	Variation	Mean ± SD	Variation
DSCLTF(mm)	9.00 ± 1.44	5.5–12	7.71 ± 1.23	4.7–11.5
DSCRTF (mm)	9.22 ± 1.49	5.8–12.6	7.77 ± 1.13	4.6–10.7

Abbreviations: DSCLTF, distance from spinal canal to left transverse foramen; DSCRTF, distance from spinal canal to right transverse foramen; SD, standard deviation.

### Safety Angle of the Sagittal Screw

The mean SA<sub>SS</sub> found in the male group was 15.01 ± 7.86° on the left and 16.68 ± 8.26° on the right. In the female group, means of 15.55 ± 7.04° on the left and 17.56 ± 6.9° on the right were found (►Table 6). We did not find a statistical difference between the male and female groups when comparing SA<sub>SS</sub> values.

### Posterior Arch Thickness

The mean <sub>PAT</sub> found among males was 8.95 ± 1.75 mm on the left and 8.92 ± 2.22 mm on the right. In the female group, <sub>PAT</sub> values of 7.21 ± 1.53 mm on the left and 7.41 ± 1.58 on the right (►Table 7) were found. The statistical analysis showed a higher <sub>PAT</sub> in the male group ( $p < 0.001$ ).

### Interobserver Reliability

The interobserver reliability found was very good for the tomographic measurements related to DPTLEP (0.89), DPTREP (0.96), SALAS (0.97), SARAS (0.91), RASL (0.87),

DSCLTF (0.96), DSCRTF (0.94), SALSS (0.84), good for the measures related to LASL (0.62), LSSL (0.77), RSSL (0.63), SARSS (0.73) and moderate for tomographic measurements related to LPAT (0.55) and RPAT (0.45). Interobserver reliability values are shown in ►Table 8.

### Discussion

Our results showed that the morphometric characteristics of the atlas in the studied population are similar to previously reported data. The few existing studies on the anatomical features of the atlas are based on cadaver specimens.<sup>12,13,15,16</sup> To the best of our knowledge, this is the first study of the morphometric characteristics of the atlas in a sample of a Latin American population and which presents a comparison related to gender.

The anatomy of the atlas of our population may differ from others, thus the anatomical parameters of C1 should be studied to verify if the lateral mass fixation can be performed and accepted as standard technique. As other anatomical

**Table 5** Sagittal Screw Length

Parameters	Male (n = 48)		Female (n = 52)	
	Mean ± SD	Variation	Mean ± SD	Variation
LSSL (mm)	30.47 ± 2.19	25.5–35.1	28.82 ± 1.86	24.3–33.1
RSSL (mm)	29.51 ± 1.83	26–34.3	28.16 ± 2.03	22.9–33.1

Abbreviations: LSSL, left sagittal screw length; RSSL, right sagittal screw length; SD, standard deviation.

**Table 6** Safety Angle of the Sagittal Screw

Parameters	Male (n = 48)		Female (n = 52)	
	Mean ± SD	Variation	Mean ± SD	Variation
SALSS(°)	15.01 ± 7.86	0.8–36.1	15.55 ± 7.04	2.39–29.33
SARSS(°)	16.68 ± 8.26	3.3–33.2	17.56 ± 6.90	2.46–32.6

Abbreviations: SALSS, safety angle of the left sagittal screw; SARSS, safety angle of the right sagittal screw; SD, standard deviation.

**Table 7** Posterior arch thickness

Parameters	Male (n = 48)		Female (n = 52)	
	Mean ± SD	Variation	Mean ± SD	Variation
LPAT (mm)	8.95 ± 1.75	5.8–12.7	7.21 ± 1.53	4.27–10.42
RPAT (mm)	8.92 ± 2.22	4.8–13.5	7.41 ± 1.58	4.1–10.27

Abbreviations: LPAT, left posterior arch thickness; RPAT, right posterior arch thickness; SD, standard deviation.

**Table 8** Intraclass Correlation Coefficients with the respective 95% Confidence Interval for interobserver reliability estimation

Tomographic measurements	ICC	95%CI
DPTLEP	0.89	0.74–0.95
DPTREP	0.96	0.91–0.98
SALAS	0.97	0.94–0.99
SARAS	0.91	0.79–0.96
LASL	0.62	0.51–0.85
RASL	0.87	0.67–0.94
DSCLTF	0.96	0.90–0.98
DSCRTE	0.94	0.85–0.97
LSSL	0.77	0.42–0.91
RSSL	0.63	0.08–0.85
SALSS	0.84	0.61–0.93
SARSS	0.73	0.33–0.89
LPAT	0.55	–0.12 until 0.82
RPAT	0.45	–0.37 until 0.78

Abbreviations: CI, confidence interval; DPTLEP, distance from the posterior tubercle to the left entry point; DPTREP, distance from the posterior tubercle to the right entry point; DSCLTF, distance from spinal canal to left transverse foramen; DSCRTE, distance from spinal canal to right transverse foramen; ICC, intraclass correlation coefficient; LASL, left axial screw length; LPAT, left posterior arch thickness; RASL, right axial screw length; LSSL, left sagittal screw length; RPAT, right posterior arch thickness; RSSL, right sagittal screw length; SALAS, safety angle of left axial screw; SALSS, safety angle of the left sagittal screw; SARAS, safety angle of right axial screw; SARSS, safety angle of the right sagittal screw; .

differences were previously described in the literature when comparing different races and ethnicities,<sup>17</sup> we believe that data from previous studies should be used with caution, as they may not be universally accepted. Although studies on the characteristics of the surgical anatomy of the atlas using cadaveric specimens have been performed, controversy still exists regarding the path and optimal entry point of the C1 lateral mass screw.

Considering the proportion of measurements detected in our analysis, with posterior arch dimensions compatible with the use of the 3.5 mm screw to carry out the fixation of the C1 lateral mass through the point of entry into the posterior arch, preoperative evaluation of the anatomical parameters of the atlas should be performed to evaluate the safety and possibility of inserting the screw through the posterior arch.

The fixation technique through the posterior arch and the atlas lateral mass is similar to the technique of pedicle screw fixation in the subaxial cervical spine, and according to previous studies, it can be performed in most patients.<sup>12,13,16</sup> This technique is different from the Harms technique, in

which the entry point is the lateral mass of C1 itself.<sup>11</sup> The length of the screw portion inserted into the bone is longer in the technique described by Tan et al.<sup>12</sup>

Ebraheim et al<sup>18</sup> described that the measurement of the posterior arch in the narrowest portion of the vertebral artery groove was  $4.1 \pm 1.2$  mm, and the distance from the midline to the medial border of the foramen was  $22.2 \pm 1.3$  mm. The results evidenced in our population showed that the thickness of the posterior arch varied from 4.1 to 13.5 mm, with a mean of  $8.9 \pm 1.7$  mm and  $8.9 \pm 2.2$  mm among males, respectively, on the left and on the right, and the means among females were  $7.2 \pm 1.5$  mm and  $7.4 \pm 1.5$  mm, respectively, on the left and on the right. The distance from the midline to the medial border of the foramen ranged from 16.6 to 26.9 mm, with a mean among males of  $21.8 \pm 1.5$  mm and of  $22.7 \pm 1.4$  mm, respectively, on the left and on the right, and the means for females were of  $20.0 \pm 1.4$  mm and of  $20.2 \pm 1.3$  mm, on the left and on the right. The width of the posterior arch and lateral mass thickness are relatively large to accommodate a screw. The height is much smaller than the thickness of the posterior arch at its narrowest portion, and also smaller than the thickness of the posterior arch at the screw entry point. Thus, the size of the screw is determined by the height of the posterior arch in the groove portion of the vertebral artery.

Tan et al<sup>12</sup> described the entry point with a mean distance located at  $19.0 \pm 1.8$  mm lateral to the midline, and  $2.0 \pm 0.6$  mm superior to the lower edge of the posterior arch. We found higher values. Shown by DPTLEP and DPTREP, the distance from the posterior tuberosity of the atlas to the entry point was found with a mean value of  $21.8 \pm 1.5$  mm and of  $22.7 \pm 1.4$  mm among males, and of  $20.0 \pm 1.4$  mm and of  $20.2 \pm 1.3$  mm among females. One justification for the higher value found in our study is the differences in the methodology of evaluation. While Tan et al<sup>12</sup> drew a line starting from the atlas posterior tubercle, which finds perpendicularly another line that passes through the entry point, we drew a straight line joining the posterior tubercle and the entry point. We believe that the way we carried out this measurement is easier to reproduce and to apply at the time of surgery, but this was not tested in our study. Another methodological difference was the definition of the height of the entry point in the posterior arch. While Tan et al<sup>12</sup> defined that the ideal entry point was in the lower third of the posterior arch of the atlas, and thus suggested a screw trajectory perpendicular to the coronal plane and with  $5^\circ$  of cephalic inclination, we chose to use half of the posterior arch thickness as the ideal point. We did not evaluate the screw direction, but the safety angle for screw insertion. Displayed

in the SALAS and SARAS values, the safety angle of the axial screw found had a mean value of  $23.68 \pm 6.12$  mm and of  $24 \pm 5.82$  mm among males and of  $18.09 \pm 5.46$  mm and of  $18.57 \pm 5.34$  mm for females. In the sagittal plane the safety angle was presented by SALSS and SARSS values, and a mean value of  $15.01 \pm 7.86$  mm and of  $16.68 \pm 8.26$  mm was found for males, just as a mean value of  $15.55 \pm 7.04$  mm and of  $17.56 \pm 6.90$  mm was found for females. Gebauer et al<sup>16</sup> described the axial safety angle as the area covering  $33.6^\circ$  in males and  $29.2^\circ$  in females and the sagittal safety angle of  $3.1 \pm 1.7^\circ$  in males and  $2.4 \pm 1.8^\circ$  in females, suggesting a cephalic inclination. Alternatively, we considered the 3.5 mm diameter of the screw to delimit the safety area, and that may have accounted for the lower value found in the axial safety angle in our study. However, we believe that our methodology is more reliable and representative of the surgical act.

Lee et al<sup>13</sup> described in their article the main reasons that led them to study the morphometry of the atlas. Previously accepted standard techniques (Goel and Harms techniques)<sup>8,9</sup> introduced the C1 screw through the lateral mass. At this location, there is a venous plexus near the major occipital nerve, and injury to this plexus causes massive bleeding (mean of 500 ml)<sup>19</sup> and hinders the passage of the screw. Another complication present with the introduction of the screw by the lateral mass of C1 is the compression and manipulation of the occipital nerve leading to local dyesthesia.<sup>6,13</sup>

In the same article, Lee et al<sup>13</sup> reported that at least 5 mm thickness of the posterior arch of the atlas would be required for safe passage (without breaking the cortical margins) of a 3.5 mm screw. In their article, the authors found that only 13.7% of the population had a thickness  $> 5$  mm. Then they described the notch technique, in which the lower cortex could be violated. By this technique, they demonstrated that 85.2% of the population studied could receive the screw through the posterior arch of the atlas. This article also found a statistically significant difference between genders, with females at a higher risk of vertebral artery injury.<sup>13</sup> In our study, the values found differed from the study of Lee et al,<sup>13</sup> and one of the reasons proposed for such a difference would be the methodology used. In the American study, the posterior arch was measured in the vertebral artery groove in cadaveric specimens by means of a caliper, whereas, in our study, measurements were made by CT, with the posterior arch thickness being found at the screw entry point. Tan et al,<sup>12</sup> in 2003, described the measurements in 50 cadaveric samples of Asian origin. An average of 4.58 mm thickness was found for the posterior arch in the vertebral artery groove, with 8% being  $< 4.0$  mm. We found in our study that the left posterior arch thickness (LPAT) and the right (RPAT) among males were  $8.95 \pm 1.75$  mm and  $8.92 \pm 2.22$  mm, ranging from 4.8 to 13.5 mm. Among females, we found a LPAT of  $7.21 \pm 1.53$  mm and a RPAT of  $7.41 \pm 1.58$  mm, with a variation of  $4.1 \pm 10.42$  mm. A statistically significant difference was found between genders. Although we have not evaluated the measurement of posterior arch thickness in the vertebral artery groove in our study, we took this thickness into account to mark off the screw safety angle when considering

the total thickness of 3.5 mm. Thus, we believe it is possible to perform the technique of screw introduction through the posterior arch in the whole sample studied. Lee et al,<sup>13</sup> to justify the difference found in his study and in the study of Tan et al,<sup>12</sup> hypothesized the shrinkage of cadaveric samples, since the samples from the American study were taken from a museum and were kept for about 50 years and, in addition, the American population is known to be larger than the Asian. It was hypothesized that the population of 50 years ago was smaller than the current population. However, no study was conducted to prove this point.

The usual challenge of translating diagnostic imaging data into surgically useful information involves the difficulty of delineating three-dimensional structures, such as C1 measurements, in two dimensions. To obtain the most clinically applicable data from CT images, we used simultaneous multiplanar (axial, sagittal and coronal) evaluation to measure all parameters.

Our study has limitations that deserve mention. First, this is a retrospective study. The second limitation is the absence of a clinical evaluation of the lateral mass fixation technique in our study, since the use of treatment methods may emphasize the importance of preoperative evaluation by performing a CT scan.

## Conclusion

Through a unique and reproducible technique for evaluating CT scans, the anatomical parameters of the atlas found in the population sample in our study were similar to those previously presented in the literature. However, gender differences were observed. Therefore, we recommend the use of CT scan as a preoperative evaluation method when fixation of the lateral mass by the posterior arch of the atlas is performed.

## Conflict of Interests

The authors have no conflict of interests to declare.

## References

- 1 Constantin P, Lucretia C. Relations between the cervical spine and the vertebral arteries. *Acta Radiol Diagn (Stockh)* 1971;11(01): 91-96
- 2 Hutchinson EC, Yates PO. The cervical portion of the vertebral artery; a clinico-pathological study. *Brain* 1956;79(02):319-331
- 3 Virtama F, Kivalo E. Impressions on the vertebral artery by deformations of the unco-vertebral joints; post-mortem angiographic studies. *Acta Radiol* 1957;48(06):410-412
- 4 Gallie WE. Fractures and dislocations of the cervical spine. *Am J Surg* 1939;46:495-499
- 5 Brooks AL, Jenkins EB. Atlanto-axial arthrodesis by the wedge compression method. *J Bone Joint Surg Am* 1978;60(03):279-284
- 6 Magerl F, Grob D, Seeman P. Stable dorsal fusion of the cervical spine (C2-T1) using hook plates. In: Kehr P, Weidner A, editors. *Cervical spine*. New York: Springer-Verlag; 1987:217-221
- 7 Nogueira-Barbosa MH, Defino HL. Classificação das variações anatômicas do eixo relacionadas com a atlantoaxial artrose. *Coluna* 2006;5(03):171-175
- 8 Goel A, Laheri V. Plate and screw fixation for atlanto-axial subluxation. *Acta Neurochir (Wien)* 1994;129(1-2):47-53

- 9 Harms J, Melcher RP. Posterior C1–C2 fusion with polyaxial screw and rod fixation. *Spine* 2001;26(22):2467–2471
- 10 Sousa CM, Silva LP, Santos C, Silva EJ. Figueiredo Artrodese cervical C1–C2 Pelas Técnicas de Harms e Magerl. *Coluna/Columna* 2010;9(03):287–292
- 11 Hong X, Dong Y, Yunbing C, Qingshui Y, Shizheng Z, Jingfa L. Posterior screw placement on the lateral mass of atlas: an anatomic study. *Spine* 2004;29(05):500–503
- 12 Tan M, Wang H, Wang Y, et al. Morphometric evaluation of screw fixation in atlas via posterior arch and lateral mass. *Spine* 2003;28(09):888–895
- 13 Lee MJ, Cassinelli E, Riew KD. The feasibility of inserting atlas lateral mass screws via the posterior arch. *Spine* 2006;31(24):2798–2801
- 14 Fleiss J, Cohen J. The equivalence of weighted kappa and the intraclass correlation coefficient as measures of reliability. *Educ Meas Psychol.* 1973;33:613–619
- 15 Murakami S, Mizutani J, Fukuoka M, et al. Relationship between screw trajectory of C1 lateral mass screw and internal carotid artery. *Spine* 2008;33(24):2581–2585
- 16 Gebauer M, Barvencik F, Briem D, et al. Evaluation of anatomic landmarks and safe zones for screw placement in the atlas via the posterior arch. *Eur Spine J* 2010;19(01):85–90
- 17 Herrero CF, Luis do Nascimento A, Maranhão DA, et al. Cervical pedicle morphometry in a Latin American population: A Brazilian study. *Medicine (Baltimore)* 2016;95(25):e3947
- 18 Ebraheim NA, Xu R, Ahmad M, Heck B. The quantitative anatomy of the vertebral artery groove of the atlas and its relation to the posterior atlantoaxial approach. *Spine* 1998;23(03):320–323
- 19 Stulik J, Vyskocil T, Sebesta P, Kryl J. Atlantoaxial fixation using the polyaxial screw-rod system. *Eur Spine J* 2007;16(04):479–484