

Free-Hand Pedicle Screw Insertion of Thoracic Spine Using Fennell Technique: Initial Results and Review of Literature

Ayusman Satapathy¹ Chinmaya Dash¹ Arunav Sharma¹ Rabi Narayan Sahu¹

¹Department of Neurosurgery, All India Institute of Medical Sciences Bhubaneswar, Bhubaneswar, Odisha, India

Address for correspondence Chinmaya Dash, MCh, Department of Neurosurgery, All India Institute of Medical Sciences Bhubaneswar, Bhubaneswar 751019, Odisha, India (e-mail: dr.chinu.dash@gmail.com).

Indian J Neurotrauma 2019;16:10–13

Abstract

Aim of the Study This article aims to study the safety and feasibility of Fennell technique of free-hand pedicle screw insertion in thoracic spine.

Methods Consecutive 10 patients in whom 40 thoracic pedicle screw were inserted using Fennell's technique were included in the study. Postoperative computed tomography scan was done in all the patients. Breach in individual pedicle was analyzed using Gertzbein classification.

Results A total of 40 screws were placed in the thoracic spine in 10 patients by free-hand technique described by Fennell et al. Out of 40 pedicle screws, 26 were placed at the D10 to D12 level, 8 screws were placed at the D7 to D9 level, and 6 screws were placed at the D1 to D6 level. There was one pedicle with grade 1 lateral breach and one pedicle with grade 1 medial breach as per Gertzbein classification. All other screws were contained within the pedicle (Gertzbein grade 0). None of the patients had any added deficits or wound complications in the postoperative period.

Conclusion Thoracic pedicle screw insertion is challenging in nature because of the anatomic variability and proximity of critical structures to the pedicles. Our experience suggests that Fennell technique is a reliable technique, which can be used to place thoracic pedicles consistently, with acceptable rates of pedicle breach. A study involving larger number of patients might prove to establish this technique as an easily reproducible and safe technique for free-hand pedicle screw insertion in thoracic spine.

Keywords

- ▶ dorsal spine pedicle
- ▶ Fennell technique for thoracic pedicle
- ▶ freehand
- ▶ free-hand screw technique
- ▶ thoracic pedicle

Introduction

Pedicle screw fixation is commonly used for fixation in thoracic spine surgery for various indications like trauma, scoliosis, infections, and malignancy. Various adjuncts have been described in the literature for increasing the safety, accuracy, and feasibility of pedicle screw insertion. These include intraoperative fluoroscopy, intraoperative computed tomography (CT), and image-assisted navigation. These entail radiation exposure to both the patient as well as staff in the operative room. Various free-hand screw insertion techniques have been described in the literature.^{1–6} Many of the described trajectories, mention various entry points and

medial angulation depending on the level of thoracic spine. Fennell et al¹ described a free-hand pedicle screw insertion technique in the thoracic spine using a uniform entry point and sagittal angulation for all levels in the thoracic spine. The study describes our initial experience with the use of free-hand technique as described by Fennell et al and a review of the literature of various free-hand techniques.

Methods

This is a retrospective study of postoperative CT scan of 10 patients who underwent open thoracic pedicle screw placement. All the cases were performed by a single surgeon (C.D.).

received
September 22, 2019
accepted
September 23, 2019

DOI <https://doi.org/10.1055/s-0039-1700605>
ISSN 0973-0508.

Copyright ©2019 Neurotrauma Society of India

Pedicle screws were placed using the technique described by Fennell et al.¹ A uniform entry point of 3 mm caudal to the junction of the lateral margin of superior articular process and transverse process of the corresponding vertebra (►Fig. 1A). The sagittal angulation was made orthogonal to the curvature of the thoracic spine at the corresponding level. The medial-lateral angulation was approximately 30 degrees for T1 and T2 (►Fig. 1B), whereas it was approximately 20 degrees for T3 to T12 (►Fig. 1C). Preoperative pedicle dimension and estimated length of screw required was calculated for all patients (►Fig. 2). After exposure at the desired level, a high-speed electric drill was used to perforate the cortex at the entry point described above. A straight gear shift probe was used to cannulate the pedicle till the desired level as measured on the preoperative CT image. A ball-ended probe was used to assess breach in all the four quadrants—medial, lateral, superior, and inferior, as well as anterior/floor breach. Intraoperative fluoroscopy was used only twice—once at the beginning to mark the desired level and another at the end of surgery, with anteroposterior and lateral images. Postoperative CT was done for all the patients.

Results

A total of 40 screws were placed in the thoracic spine in 10 patients by free-hand technique as described by Fennell et al. Out of 40 pedicle screws, 26 were placed at the D10 to D12 level, 8 screws were placed at the D7 to D9 level, and 6 screws were placed at the D1 to D6 level. There was one

pedicle with grade 1 lateral breach (►Fig. 3A) and one pedicle with grade 1 medial breach (►Fig. 3B) as per Gertzbein classification.⁷ All other screws were contained within the pedicle (Gertzbein grade 0). None of the patients had any added deficits or wound complications in the postoperative period.

Discussion

Pedicle screw insertion can be challenging in the thoracic region as the thoracic vertebrae tend to have more anatomic variations when considering pedicle angles and attachment to the vertebral body. Rampersaud et al⁷ have shown using a geometric model that the mean maximum permissible translational breach in the thoracic spine is 0.6 mm, while

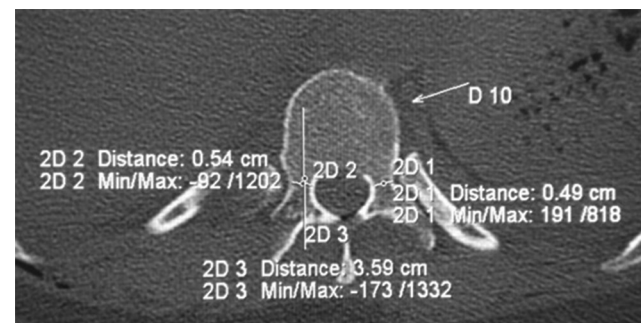


Fig. 2 Preoperative calculation using computed tomography (CT) image.

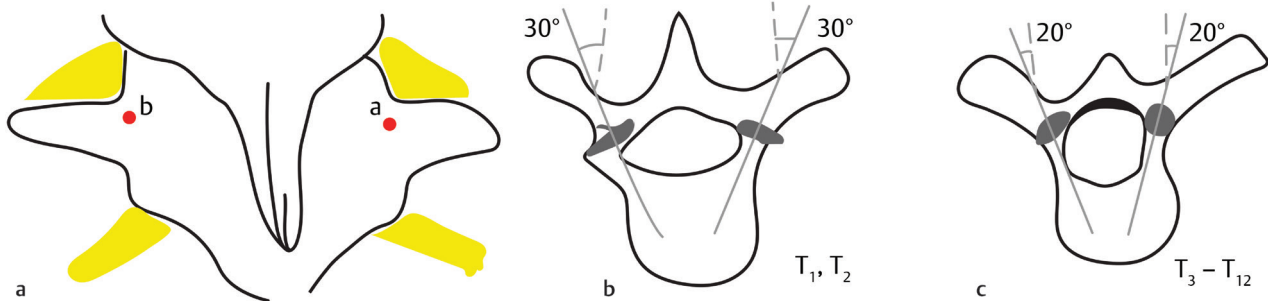


Fig. 1 (A) a and b are entry points on Fennell's technique. (B) Medical-lateral angulation in T1 and T2 using Fennell's technique. (C) Medical-lateral angulation in T3-T12 using Fennell's technique.

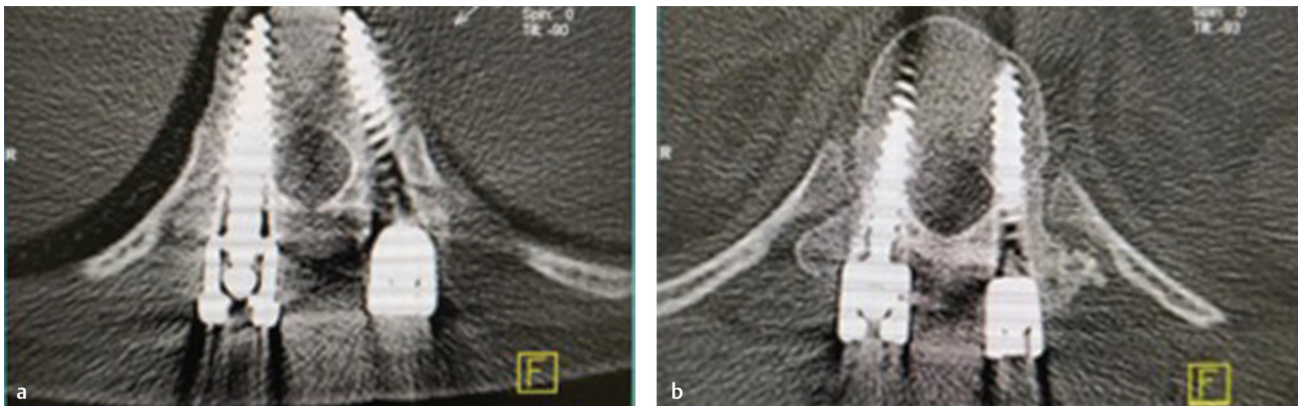


Fig. 3 (A) Lateral breach in left pedicle. (B) Medial breach in right pedicle.

the mean maximum possible rotational breach in the thoracic spine was 2.6 degrees. Compounding the problem is the significant interpatient variability in the anatomy of thoracic spine. Particularly, T4 and T6 have been reported to have the highest incidence of cortical breach, which can be explained by the small pedicles in this region.⁴

Various methods of free-hand insertion of pedicle screw in the thoracic spine have been described. The various techniques described in the literature has been summarized in

► **Table 1.** In this study, the method described by Fennell et al¹ was used. They included 219 thoracic pedicle screws in the study and had 9 lateral breach (4.1%) and no medial breach. This method has a fixed entry point and sagittal angle for all thoracic pedicles. The medial angulation is uniform from T3 to T12 (20 degrees) and 30 degrees for T1 and T2. All pedicle screws were placed after they were tapped with an under-sized tap. It is our belief that this avoids/prevents breach that would have otherwise occurred with a tap of the same

Table 1 Various methods of free-hand insertion of pedicle screw in the thoracic spine as described in literature

Author and year	Number of screws	Entry point	Axial trajectory	Sagittal trajectory
Kim et al (2004)	3,204	Proximal thoracic (T1, T2)–Junction of bisected transverse process and lamina at lateral pars Mid thoracic (T7–9)–The most medial starting point in thoracic spine. Junction of proximal edge of transverse process and lamina, where it meets the lamina and superior facet, just lateral to the midportion of base of superior articular process Lower thoracic (T11–12)–Junction of bisected transverse process and lamina at or just medial to the lateral aspect of pars	Not mentioned	Not mentioned
Karapinar et al (2008)	297	T10, T11, T12–Junction of a vertical line along the lateral pars boundary and a transverse line dividing the transverse process in half	Medial orientation based on preoperative CT images. No defined angulation mentioned	Not mentioned
Modi et al (2009)	854	Junction of the outer third and inner two-thirds of the superior facet joint in all thoracic vertebra	Not mentioned	Not mentioned
Parker et al (2011)	3,513	A triangular bony confluence formed by the superior articular facet, the transverse process, and the pars interarticularis. The center point of this bony confluence was selected as the entry site. This entry site was uniformly medial to the lateral margin of the superior articular process	Depending on the preoperative radiograph. Lateral radiograph was done using pedicle markers and cannulation of pedicles repeated if required using pedicle probe. Mediolateral angulation was done in an attempt to triangulate screw placement from lateral to medial	Rostrocaudal trajectory parallels superior end plate of vertebra
Rivkin et al (2014)	87	T1 (only T1 described in this series)–In the medial-lateral direction, a point one-third of the way between the lateral border of C7 lateral mass and medial border of T1 lamina along the C7/T1 articulation. A high speed burr was used to remove ~3 mm of bone from the inferior aspect of C7 lateral mass until the smooth cortical surface of the superior articular process of T1 is identified	The trajectory parallels the angle between the tip of T1 spinous process and the contralateral starting point	The screw trajectory is perpendicular to the long axis of the T1 lamina
Fennell et al (2014)	219	The same entry point for each level was defined as a point 3 mm caudal to the junction of the transverse process and the lateral margin of the superior articulating process	The medial angulation (axial trajectory) was ~30 degrees at T1 and T2, and 20 degrees from T3 to T12	Orthogonal to the dorsal curvature of spine at that level

Abbreviation: CT, computed tomography.

size as the planned screw for insertion. We also feel that the screw has a stronger purchase if an undersized tap is used. However, there is no scientific literature to definitely support this philosophy. A ball point probe/pedicle feeler was used to feel the bone all around after the use of pedicle finder and tapping it with undersized tap. The fact that there were two breaches (5%), although clinically not significant, prove that this technique of feeling the bone all around with pedicle feeler is not fool proof in preventing pedicle breach. Recent studies have shown that the incidence of cortical breach in the thoracic spine varies between 5.6 and 6.2%.^{3,5} The low incidence (5%) of pedicle breach in this series matches with the available international literature. Free-hand insertion of pedicle screws in the thoracic spine decreases exposure to radiation⁸ and decreases the duration of surgery, which in turn is known to have reduced incidence of surgical site infections.⁹

Conclusion

Thoracic pedicle screw insertion is challenging in nature because of the anatomic variability and proximity of critical structures to the pedicles. Our experience suggests that Fennell technique is a reliable technique, which can be used to place thoracic pedicles consistently, with acceptable rates of pedicle breach. A study involving larger number of patients might prove to establish this technique as an easily reproducible and safe technique for free-hand pedicle screw insertion in thoracic spine.

Conflict of Interest

None.

References

- 1 Fennell VS, Palejwala S, Skoch J, Stidd DA, Baaj AA. Freehand thoracic pedicle screw technique using a uniform entry point and sagittal trajectory for all levels: preliminary clinical experience. *J Neurosurg Spine* 2014;21(5):778–784
- 2 Modi H, Suh SW, Song H-R, Yang J-H. Accuracy of thoracic pedicle screw placement in scoliosis using the ideal pedicle entry point during the freehand technique. *Int Orthop* 2009;33(2):469–475
- 3 Kim YJ, Lenke LG, Bridwell KH, Cho YS, Riew KD. Free hand pedicle screw placement in the thoracic spine: is it safe? *Spine* 2004;29(3):333–342, discussion 342
- 4 Parker SL, McGirt MJ, Farber SH, et al. Accuracy of free-hand pedicle screws in the thoracic and lumbar spine: analysis of 6816 consecutive screws. *Neurosurgery* 2011;68(1):170–178
- 5 Karapinar L, Erel N, Ozturk H, Altay T, Kaya A. Pedicle screw placement with a free hand technique in thoracolumbar spine: is it safe? *J Spinal Disord Tech* 2008;21(1):63–67
- 6 Rivkin MA, Okun JF, Yocom SS. Novel free-hand T1 pedicle screw method: Review of 44 consecutive cases. *J Neurosci Rural Pract* 2014;5(4):349–354
- 7 Gertzbein SD, Robbins SE. Accuracy of pedicular screw placement in vivo. *Spine* 1990;15(1):11–14
- 8 Rampersaud YR, Simon DA, Foley KT. Accuracy requirements for image-guided spinal pedicle screw placement. *Spine* 2001;26(4):352–359
- 9 Weinstein MA, McCabe JP, Cammisa FP Jr. Postoperative spinal wound infection: a review of 2,391 consecutive index procedures. *J Spinal Disord* 2000;13(5):422–426